

Chulalongkorn University

## Chula Digital Collections

---

Chulalongkorn University Theses and Dissertations (Chula ETD)

---

2021

### Histone 3 and Histone 4 acetylation pattern in Well-differentiated thyroid lesions and normal thyroid tissue with their potential in diagnostic implication

Nishal Chhetri  
*Faculty of Medicine*

Follow this and additional works at: <https://digital.car.chula.ac.th/chulaetd>

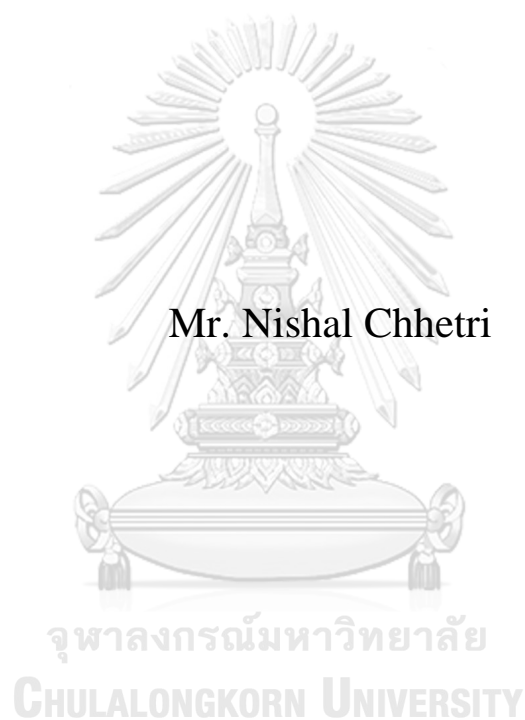
---

#### Recommended Citation

Chhetri, Nishal, "Histone 3 and Histone 4 acetylation pattern in Well-differentiated thyroid lesions and normal thyroid tissue with their potential in diagnostic implication" (2021). *Chulalongkorn University Theses and Dissertations (Chula ETD)*. 4634.  
<https://digital.car.chula.ac.th/chulaetd/4634>

This Thesis is brought to you for free and open access by Chula Digital Collections. It has been accepted for inclusion in Chulalongkorn University Theses and Dissertations (Chula ETD) by an authorized administrator of Chula Digital Collections. For more information, please contact [ChulaDC@car.chula.ac.th](mailto:ChulaDC@car.chula.ac.th).

Histone 3 and Histone 4 acetylation pattern in Well-differentiated thyroid lesions and normal thyroid tissue with their potential in diagnostic implication



A Thesis Submitted in Partial Fulfillment of the Requirements  
for the Degree of Master of Science in Clinical Sciences  
Common Course  
FACULTY OF MEDICINE  
Chulalongkorn University  
Academic Year 2021  
Copyright of Chulalongkorn University

รูปแบบการแสดงออกของอะเซทิลเลชั่น ฮิสโตน 3 และ ฮิสโตน 4  
ในรอยโรคของเนื้องอกต่อมไทรอยด์ชนิด เวลล์ดีฟเฟอเรนซี  
เอทรวมถึงเนื้อเยื่อปกติของต่อมไทรอยด์และความเป็นไปได้ใน  
การใช้เป็นเครื่องมือ สำหรับการวินิจฉัยโรค



นายนิชาล เข็ดทรี

วิทยานิพนธ์นี้เป็นส่วนหนึ่งของการศึกษาตามหลักสูตรปริญญา  
วิทยาศาสตรมหาบัณฑิต  
สาขาวิชาเวชศาสตร์คลินิก ไม่สังกัดภาควิชา/เทียบเท่า  
คณะแพทยศาสตร์ จุฬาลงกรณ์มหาวิทยาลัย  
ปีการศึกษา 2564  
ลิขสิทธิ์ของจุฬาลงกรณ์มหาวิทยาลัย

Thesis Title	Histone 3 and Histone 4 acetylation pattern in Well-differentiated thyroid lesions and normal thyroid tissue with their potential in diagnostic implication
By	Mr. Nishal Chhetri
Field of Study	Clinical Sciences
Thesis Advisor	Associate Professor SOMBOON KEELAWAT, M.D.

---

Accepted by the FACULTY OF MEDICINE, Chulalongkorn University in Partial Fulfillment of the Requirement for the Master of Science

..... Dean of the FACULTY OF  
MEDICINE  
(Associate Professor CHANCHAI  
SITTIPUNT, M.D.)

#### THESIS COMMITTEE

..... Chairman  
(Professor SHANOP SHUANGSHOTI,  
M.D.)

..... Thesis Advisor  
(Associate Professor SOMBOON  
KEELAWAT, M.D.)

..... External Examiner  
(Associate Professor Dr. Nakarin  
Kitkumthorn, Ph.D.)

นิขาล เชิดทรี : รูปแบบการแสดงออกของอะเซทิลเลชัน ฮิสโตน 3 และ ฮิสโตน 4 ในรอยโรคของเนื้องอกต่อมไทรอยด์ชนิด เวลส์ดีฟเฟอเรนซีเอทรวมถึงเนื้อเยื่อปกติของต่อมไทรอยด์และความเป็นไปได้ในการใช้เป็นเครื่องมือ สำหรับการวินิจฉัยโรค. ( Histone 3 and Histone 4 acetylation pattern in Well-differentiated thyroid lesions and normal thyroid tissue with their potential in diagnostic implication) อ.ที่ปรึกษาหลัก : Assoc. Prof.สมบุญ คีลาวัฒน์M.D

งานวิจัยนี้ได้ศึกษาระดับของฮิสโตนอะเซทิลเลชันในรอยโรคของต่อมไทรอยด์ชนิดต่างๆโดยการวัดระดับการติดสีของอิมมูโนฮิสโตเคมีเทียบกับเนื้อเยื่อไทรอยด์ปกติที่อยู่ข้างเคียง ตัวอย่างที่ใช้ในการศึกษาได้จากชิ้นเนื้อที่ฝังอยู่ในพาราฟินของรอยโรคต่างๆ ได้แก่ แพพพิรารี คาร์ซิโนมา ฟอลลิคูลา อะดีโนมา ฟอลลิคูลา คาร์ซิโนมา และ โรคคอพอกชนิด โนดูลา กอยเดอร์ ซึ่งเก็บรวบรวมอยู่ที่ภาควิชาพยาธิวิทยา คณะแพทยศาสตร์ จุฬาลงกรณ์มหาวิทยาลัย ตั้งแต่ปี พ.ศ. 2559 ถึง 2561 โดยนำมาแยกด้วย แอนติอะเซทิลฮิสโตน 3 แอนติบอดี (H3K9/K14ac) และแอนติอะเซทิลฮิสโตน 4 แอนติบอดี (H4K5,8,12 and 16ac) สไลด์ที่ย้อมด้วยอิมมูโนฮิสโตเคมีดังกล่าวจะถูกนำมาสแกนเพื่อเปลี่ยนเป็นไฟล์ดิจิทัล แล้ววัดความเข้มของสีและสัดส่วนของเซลล์ที่ติดสี ด้วยซอฟต์แวร์ที่ชื่อว่า แอพเพอร์ริโอ อิมเมจสโคป ผลการศึกษาพบว่าในจำนวนรอยโรคของต่อมไทรอยด์ทั้งสิ้น 147 ราย ซึ่งในจำนวนนี้มีฟอลลิคูลา อะดีโนมา อยู่ 28 ราย แพพพิรารี คาร์ซิโนมา 50 ราย ฟอลลิคูลา คาร์ซิโนมา 19 ราย และโรคคอพอกชนิด โนดูลา กอยเดอร์ 50 ราย มีแค่โรคคอพอกชนิด โนดูลา กอยเดอร์เท่านั้นที่มี ดีอะเซทิลเลชัน เมื่อนำไปเทียบกับเนื้อเยื่อไทรอยด์ที่อยู่ข้างเคียง(ทั้ง ฮิสโตน 3 และ 4) ( $p=0.0016$  และ  $<0.0001$ ) สำหรับรอยโรคอื่นๆ ที่เหลือ ได้แก่ ฟอลลิคูลา คาร์ซิโนมา แพพพิรารี คาร์ซิโนมา และ ฟอลลิคูลา อะดีโนมา ไม่พบมีความแตกต่างอย่างมีนัยสำคัญทางสถิติของระดับฮิสโตนอะเซทิลเลชันเมื่อเทียบกับเนื้อเยื่อปกติที่อยู่ข้างเคียง ( $p>0.05$ ) เป็นครั้งแรกในโลกที่การศึกษาครั้งนี้ได้ค้นพบว่ารอยโรคโนดูลา กอยเดอร์มีดีอะเซทิลเลชัน เมื่อเทียบกับเนื้อเยื่อไทรอยด์ที่อยู่ข้างเคียง(ทั้ง ฮิสโตน 3 และ 4) อย่างไรก็ตามผู้วิจัยไม่พบการเปลี่ยนแปลงนี้ในรอยโรคชนิดอื่น ได้แก่ ฟอลลิคูลา คาร์ซิโนมา แพพพิรารี คาร์ซิโนมา และ ฟอลลิคูลา อะดีโนมา



สาขาวิชา    เวชศาสตร์คลินิก  
ปี                2564  
การศึกษา

ลายมือชื่อนิสิต .....  
ลายมือชื่อ อ.ที่ปรึกษาหลัก .....

# # 6278009430 : MAJOR CLINICAL SCIENCES

**KEYWORD:** Thyroid histone acetylation immunohistochemical study epigenetics

Nishal Chhetri : Histone 3 and Histone 4 acetylation pattern in Well-differentiated thyroid lesions and normal thyroid tissue with their potential in diagnostic implication. Advisor: Assoc. Prof. SOMBOON KEELAWAT, M.D.

This study estimated the histone modification (hypoacetylation or hyperacetylation) in thyroid lesions, using immunohistochemistry compared with their normal counterpart. FFPE sections of surgically removed PTC, FA, FTC, and nodular goiter samples were collected from the archives of the Department of Pathology, Faculty of Medicine, Chulalongkorn University from 2016-2018 and stained with anti-acetyl histone 3 antibody (H3K9/K14ac) and anti-acetyl histone 4 antibody (H4K5,8,12 and 16ac). The intensity and proportion of immunostaining of the lesions and their normal thyroid tissue counterparts were automatically scored by Aperio ImageScope software. A total of 147 benign and malignant thyroid lesions cases, including 28 FA, 50 PTC, 19 FTC, and 50 nodular goiters, were studied. Deacetylation of both anti-acetyl histone 3 antibody (H3K9/K14ac) and anti-acetyl histone 4 antibody (H4K5,8,12 and 16ac) was detected in nodular goiter ( $p=0.0016$  and  $p= <0.0001$  respectively) compared to their normal counterpart. However, the difference in acetylation status for FTC, PTC, and FA were not statistically significant compared to that of their normal counterpart ( $p \geq 0.05$  in all cases). For the first time, this study demonstrates that nodular goiters have H3 and H4 deacetylation compared with their normal tissue counterpart. In contrast, these epigenetic events are not found in well-differentiated thyroid neoplasms (FA, FTC, and PTC).



Field of Study: Clinical Sciences  
Academic Year: 2021

Student's Signature .....  
Advisor's Signature .....

## ACKNOWLEDGEMENTS

We express our gratitude to Mrs. Jutamas Wongphoom for her excellent technical assistance and Ms. Nutthamon Sanamontre for her contribution. This research was financially supported by the Ratchadapiseksomphot Endowment Fund of the Faculty of Medicine, Chulalongkorn University, Bangkok, Thailand (Grant No. RA61/020).

Nishal Chhetri



# TABLE OF CONTENTS

	<b>Page</b>
ABSTRACT (THAI) .....	iii
ABSTRACT (ENGLISH).....	iv
ACKNOWLEDGEMENTS.....	v
TABLE OF CONTENTS.....	vi
1 Summary.....	1
2 Background and Rationale .....	2
2.1 Background.....	2
2.2 Rationale.....	5
3 Objectives .....	6
4 Literature review .....	7
4.1 Levels of Histone acetylation in thyroid tumors .....	7
4.2 Global histone modification patterns predict risk of prostate cancer recurrence	8
4.3 Histone acetylation and gastrointestinal carcinogenesis .....	9
5 Aperio Imagescope.....	11
6 Research Methodology .....	12
6.1 Research design .....	12
6.2 Sample Size .....	14
6.3 Patient population.....	14
6.4 H&E sections.....	16
6.5 Immunohistochemistry .....	16
6.6 Image acquisition.....	17
6.7 Automated Digital image analysis.....	17
7 Statistical analysis .....	19
8 Results .....	19
9 Discussion.....	21



REFERENCES .....	24
VITA.....	26



## 1 Summary

Thyroid cancer is the most common endocrine malignancy; its incidence is increasing rapidly throughout the world. There has been progress in the identification of genetic changes in thyroid cancer over the past years, nonetheless, the impact of aberrant epigenetic alterations on thyroid cancer remains to be fully understood. Studying the roles of epigenetic changes in thyroid cancer could open possibilities for the identification of innovative molecular targets for novel treatment modalities. The most common epigenetic changes seen in human neoplasms are Histone acetylation and DNA methylation. DNA methylation has been studied in several malignancies including thyroid. However, histone acetylation in thyroid neoplasms have been rarely evaluated, thus, we aim to estimate the histone modification using immunohistochemistry in thyroid lesions and compare them with their normal counterpart. FFPE sections of surgically removed PTC, FA, FTC and nodular goiter samples were collected from the archives of the Department of Pathology, Faculty of Medicine, Chulalongkorn University from the year 2016-2018. Immunostaining with anti-acetyl histone 3 antibody (H3K9/K14ac) and anti-acetyl histone 4 antibody (H4K5, 8, 12 and 16ac). The intensity and proportion of immunostaining were automatically scored by Aperio Imagescope software in both neoplastic and non-neoplastic counterparts. A total of 147 cases of both benign and malignant thyroid lesions including 28 FA, 50 PTC and 19 FTC and 50 nodular goiter were studied. Deacetylation of both anti-acetyl histone 3 antibody (H3K9/K14ac) and anti-acetyl histone 4 antibody (H4K5,8,12 and 16ac) was detected in nodular goiter ( $p=0.0016$  and  $p= <0.0001$  respectively) compared to their normal counterpart. However, the

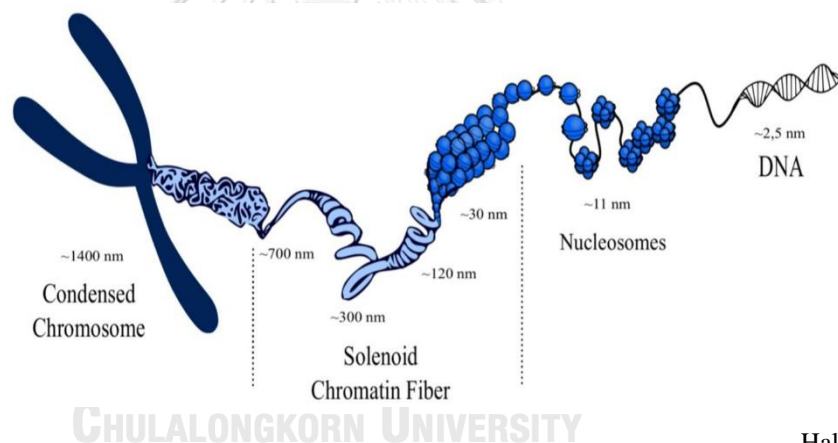
difference in acetylation status for FTC, PTC and FA were not statistically significant compared to that of their normal counterpart ( $p \geq 0.05$  in all cases). Deacetylation in various cancers including PTC and FTC has been found in other studies, however, they compared the tumors with normal counter part of different patients. This could be due to comparison of normal thyroid tissue adjacent to that of the thyroid lesion, which could mean that some form of epigenetic changes might be occurring in the adjacent normal tissue.

## 2 Background and Rationale

### 2.1 Background

Cancer, a pathologic condition that requires genetic and epigenetic events that causes neoplastic transformation[1, 2]. The understanding and studies of human genetics has reformed the sphere of medical oncology ever since the invention of the DNA structure in 1960s. More recently several epigenetic mechanisms of oncogenesis are discovered and studied aggressively. It's now known that epigenetic play a key role in development of cancer [3]. Epigenetics is defined as the study of heritable changes in gene expression (phenotype) that does not consequence into the corresponding change in DNA sequence (genotype). Epigenetic processes ensure the effective packaging of the genetic material to fit within the mammalian nucleus. In eukaryotic cells, DNA is packed as chromatin whose functional units are nucleosomes. Each nucleosome is composed of an octamer of 4 core histones (H3, H4, H2A, and H2B), around which is wrapped 147 base pairs of DNAs [1, 4]. Lysine residues in these histone tails have a positive charge that interacts with negatively

charged phosphate backbone of DNA [5]. N-tail of histones within the nucleosome octamer are considered a well-known target for specific chromatin epigenetic Posttranslational Modifications (PTMs). DNA mutation PTMs affects the nucleic acid and proteins, which is necessary for chromatin structure regulation without changing the DNA sequence. These chromatin modifications have an influence in DNA transcriptional machinery, which affects gene expression. PTMs are involved in oncogenesis as they are able to silence tumor-suppressor genes as well as enhance expression of oncogenesis. The balance between acetylation and deacetylation is crucial for chromatin stability and integrity.



Halasa Marta et.al.2009

Figure 1.0 Nucleosome formed by DNA and histone core

Thyroid cancer is the most common endocrine malignancy, its incidence is increasing rapidly throughout the world [6] . Thyroid cancer is one of the most common cancer in Thai women, and stands at fourth rank by prevalence and seventh rank by incidence [7]. Over the last two decades, there is slow but steady growth of thyroid cancer incidence in both genders. Well-differentiated thyroid cancer (papillary

thyroid cancer and follicular thyroid cancer) accounts for most cases of thyroid cancer and has a relatively good prognosis [8]. Papillary thyroid carcinoma (PTC) is the major histological type, which accounts for about 85% of all thyroid cancers [9]. Even though, there is progress in the identification of genetic changes in thyroid cancer, the impact of aberrant epigenetic alterations on thyroid cancer remains to be fully understood. Studying the roles of epigenetic changes in thyroid cancer could open possibilities for the identification of innovative molecular targets for novel treatment modalities [8]. DNA methylation and post-translational histone modifications play an important role in control of gene expression. These modifications are involved in the determination of chromatin structure: open chromatin structure (euchromatin) is associated to active transcription while closed chromatin structure (heterochromatin) is associated to gene silencing [10]. The approach of understanding histone chromatin appears very promising to predict biological behaviour of human tumors and thus, may be useful in the management of malignancies in near future. In fact, tumors may exhibit different levels of histone modifications and these differences may correlate with clinical parameters. For example, low levels of H3K4me2 and H3K18ac predict high risk of prostate cancer recurrence and reduced survival in patients with lung and kidney cancer [10].

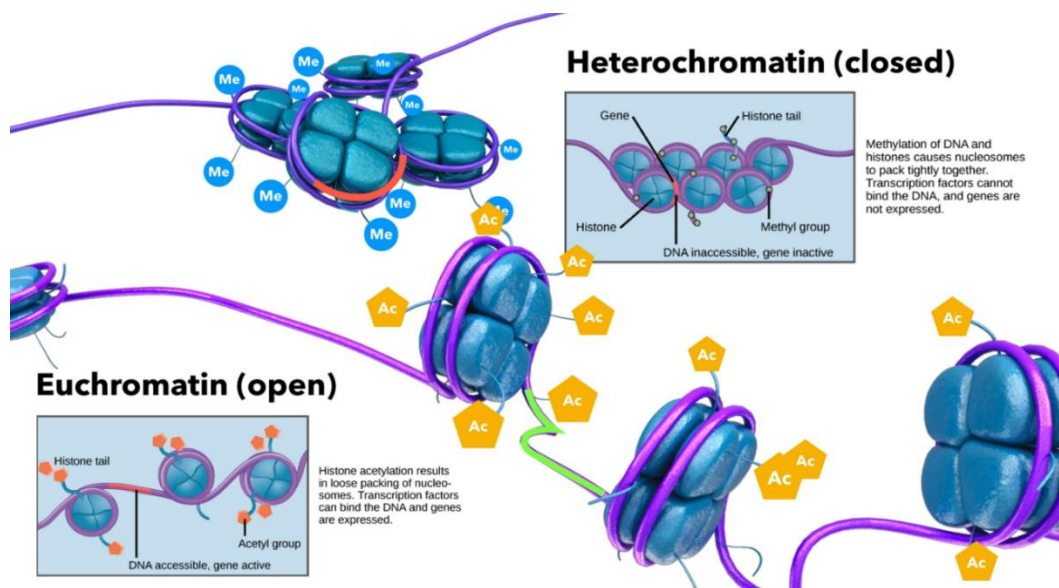


Figure 2.0 Chromatin in an eukaryotic cell during acetylation

Halasa Marta et.al.2009

## 2.2 Rationale

Though there are multiple studies in the acetylation level of various malignancies like Prostate, Breast and Colorectal carcinoma, not many studies have been done till date to estimate the acetylation status in thyroid neoplasm. HDAC the enzyme responsible for deacetylation in eukaryotic cells leads into heterochromatin which is associated with gene silencing. HDAC inhibitors induce growth arrest, apoptosis, and differentiation of a variety of tumor cells. Therefore, HDAC inhibitors are believed to be one of the most promising class of new anticancer agents. To estimate the level of histone acetylation in well-differentiated thyroid neoplasms and goitres we intend to

use immunohistochemical study, which is relatively cost effective and less time consuming. We will compare the level of the histone acetylation of the follicular thyroid carcinoma (FTC), papillary thyroid carcinoma (PTC), and follicular adenoma (FA) with its normal counterparts of the same patient and with that of thyroid goiter obtained from different patients. No studies on acetylation level of thyroid neoplasm in Thai population have been reported in international journals. Also, the previous study done to detect global histone acetylation in thyroid neoplasm was done in a relatively smaller sample size and was compared with normal thyroid tissue sample from different patients [10].

### 3 Objectives

This study has two objectives, The primary objective is to estimate the level of acetylation in well-differentiated thyroid neoplasm including benign (adenoma) and malignant (follicular and papillary carcinomas) and nodular goiter in Thai population using immunohistochemistry, and to compare it with that of normal thyroid tissue obtained from the same patient.

The secondary objective is to see the clinicopathological and demographic correlation with acetylation level in thyroid lesions.

It is with intention that we can understand the differences in the level of histone acetylation between the normal thyroid tissue and both benign and malignant thyroid lesion, by doing so we could be able to contribute to future studies and its application in treatment modalities and aid in development of newer target therapies for various thyroid lesions

## 4 Literature review

### 4.1 Levels of Histone acetylation in thyroid tumors

**Puppin C, et al**, estimated the global histone acetylation level in surgical specimens of 10 follicular adenomas (FA), 30 papillary thyroid carcinomas (PTC) and, 9 follicular thyroid carcinomas (FTC) and 6 undifferentiated thyroid carcinomas (UC). They used immunohistochemistry (IHC) using a rabbit polyclonal anti-histone H3K9–K14ac (Upstate) (1:100 overnight at 4°C) or rabbit polyclonal anti-histone H4K12ac (Abcam) (1:100 overnight at 4 °C), or rabbit polyclonal anti-histone H3K18ac (Abcam). They semi-quantitatively scored each sample using a composite score obtained by multiplying values of the mean staining intensity and the percentage of positive cells (H-score). Staining intensity score was: absent (0), weakly positive (1), moderately positive (2), strongly positive (3). Statistical analysis of H-score was done using Student's t test. Each antibody stained in the tumor cells and the normal thyroid showed a distinct staining pattern. In the case of H3K9–K14ac, all tumor types showed levels significantly higher than those observed in normal thyroid (NT) (for each tumor type  $p < 0.0001$ ). While, H3K18ac levels of FA, PTC and FTC were found to be significantly higher than those detected in NT, no difference was detected between UC and NT. They found an unusual pattern for H4K12ac levels, only FA showed significantly higher levels than NT. Altogether these results suggest that modification of histone acetylation is present in thyroid tumors and is an early event along tumorigenesis, as seen in FA with higher acetylation levels. Also, since the highest levels of H3K18ac were detected in PTC with reversion to normal levels in UC, this histone modification appears to be



switched off in the transition between differentiated and undifferentiated thyroid tumors. When compared to NT, levels of acetylated H3 histone at residue K18 were higher in FA, PTC and FTC, but not modified in UC. Therefore, levels of acetylated H3K18 are lower in UC than in differentiated carcinomas. These data may suggest that acetylated levels of H3 at residue K18 may encounter a reduction during thyroid tumor progression. Reduction of acetylated levels of H3K18 that they observed in thyroid tumors is consistent with data obtained in other tumors.

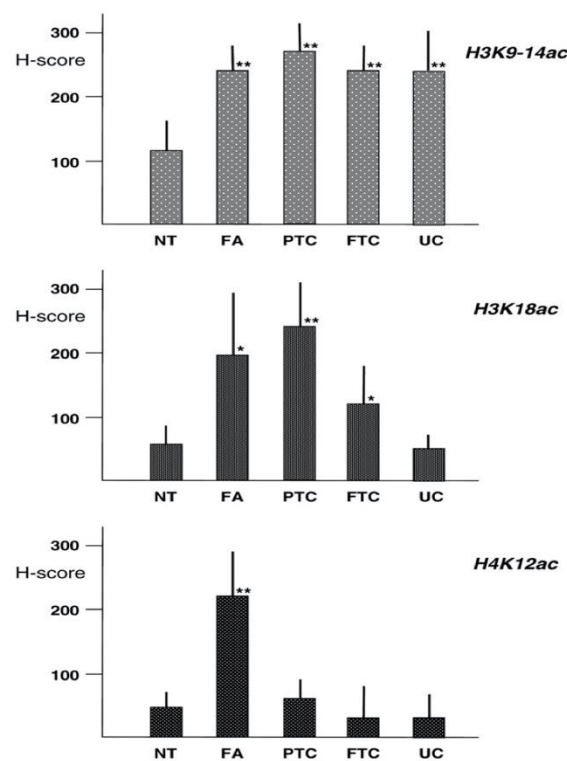


Fig. 3.0 Quantitation of acetylated histone lysine residues in thyroid tissues. H-scores were calculated as described in Section 2. Each bar indicates the mean value  $\pm$  SD of NT, FA, PTC, FTC, UC. P values were obtained by using P values were obtained by using the two-tailed paired t test. /:  $P < 0.001$ ; //:  $P < 0.0001$

## 4.2 Global histone modification patterns predict risk of prostate cancer recurrence

**Seligson B, David, et al** determined the global levels of individual histone modifications in tissues obtained from patients with prostate cancer. To determine the global levels of individual histone modifications in tissues obtained from patients,

they combined immunohistochemistry, a method for detecting the presence of specific antigens in cells, with tissue microarrays (TMAs), for high-throughput analysis of many tissue samples. They then analysed the levels of acetylated (Ac) H3 Lys 9 (K9), K18 and H4 K12, and H3 K4, using highly specific antibodies on 183 primary prostate cancer tissues. The level of staining was assessed independently by two pathologists, who were blinded to all clinico-pathological variables. They concluded that low levels of H3K4me2 and H3K18ac predict high risk of prostate cancer recurrence.

### 4.3 Histone acetylation and gastrointestinal carcinogenesis

**Yusi Wataru, et al** studied the global acetylation status of histones during carcinogenesis by examining the expression of acetylated histone H4 by Western blotting in nonneoplastic gastric mucosa and various stages of gastric tumors. By using antiacetylated histone H4 antibody, the level of acetylated histone H4 expression was shown to be reduced in 70% of gastric carcinomas in comparison with nonneoplastic mucosa, while the total amount of histone did not differ significantly between tumor and normal tissues, indicating global hypoacetylation in gastric cancer. In immunohistochemistry studies using the same antibody, acetylated histone H4 was uniformly expressed in the nuclei of nonneoplastic gastric mucosa in both epithelial cells and stromal cells. The expression of acetylated histone H4 was reduced in about 70% of gastric cancers and 45% of gastric adenomas, respectively. Reduced histone H4 acetylation was also found in some gastric lesions exhibiting intestinal metaplasia, a condition predisposing to gastric cancer. They also analyzed

the relationship between reduced histone acetylation and clinicopathological findings of gastric cancer. Reduced expression of acetylated histone H4 correlated well with advanced tumor stage, deep tumor invasion, and lymph node metastasis. Thus, low levels of global histone acetylation are closely associated with tumorigenesis as well as invasion and metastasis of gastric cancer. From these observations, at least in gastrointestinal cancers, it appears possible that reduced levels of global histone acetylation may participate not only in cancer development, but also in invasion and metastasis. Histone deacetylase (HDAC) reduces acetylation of histone tails. Trichostatin A (TSA), originally used as an antifungal drug, inhibits HDAC activity, induces histone acetylation, and, in general, enhances gene expression. HDAC inhibitors induce growth arrest, apoptosis, and differentiation of a variety of tumor cells. Therefore, HDAC inhibitors are believed to be one of the most promising class of new anticancer agents. Treatment with TSA is followed by increased histone acetylation in the promoters, inducing the expression of negative cell cycle regulators and apoptosis-related molecules. These results suggest that histone deacetylation may participate in invasion and metastasis by modifying expression of a variety of genes. Therefore, histone acetylation should be a promising target for cancer therapy.

**TABLE 1. Expression of acetylated histone H4 in gastric mucosa, adenomas, and adenocarcinomas, and its correlation with clinicopathological parameters**

	Number of cases	Expression of acetylated histone H4 <sup>a</sup>			<i>P</i> value <sup>b</sup>
		Preserved	Reduced	Markedly reduced	
Normal mucosa	65	65 (100%)	0	0	<0.0001
Adenoma	13	7 (54%)	5 (38%)	1 (8%)	
Adenocarcinoma	57	19 (33%)	23 (40%)	15 (26%)	
Histology					0.2465
Well differentiated	40	16 (40%)	15 (38%)	9 (23%)	0.0240
Poorly differentiated	17	3 (18%)	8 (47%)	6 (35%)	
Stage					
1	37	14 (38%)	19 (51%)	4 (11%)	0.0072
2	2	1 (50%)	0	1 (50%)	
3	12	3 (25%)	2 (17%)	7 (58%)	
4	6	1 (17%)	2 (33%)	3 (50%)	
Depth of invasion					0.0006
m, sm	34	14 (41%)	17 (50%)	3 (9%)	
mp, ss	8	1 (13%)	3 (38%)	4 (50%)	
se, si	15	4 (27%)	3 (20%)	8 (53%)	0.0006
Lymph node metastasis					
Negative	38	15 (39%)	19 (50%)	4 (11%)	
Positive	19	4 (21%)	4 (21%)	11 (58%)	

<sup>a</sup>Grades of acetylated histone H4 expression were classified as preserved, reduced, and markedly reduced according to the staining intensity and number of stained cells. Preserved: most cells express acetylated histone H4 at levels equal to stromal cells such as lymphocytes and fibroblasts. Reduced: 5–30% of cells express at lower levels than stromal cells. Markedly reduced: over 30% of cells express at lower levels than stromal cells.

<sup>b</sup>Correlation was analyzed by chi-square, and *P* values are shown.

## 5 Aperio Imagescope

Aperio Imagescope is one of the newest digital image analysis algorithms to estimate the nuclear or cytoplasmic staining in a given tissue using immunohistochemical study. It is a digital image analysis platform developed to perform quantitative analysis of digital slides. In this project we use the Aperio nuclear v9 (version 9, Aperio Technologies, USA) algorithm developed specifically for digital quantification of nuclear staining.

The Aperio membrane algorithm detects nuclear staining of individual cells within manually selected regions of a virtual slide. Both intensity and completeness of the immunohistochemical nuclear staining is quantified, and each cell within the selected area is categorized as 0 (negative), 1+ (weak nuclear staining), 2+ (moderate), and 3+ (strong). The Aperio nuclear algorithm is tuneable, which allows adjustment to local staining and image acquisition characteristics.

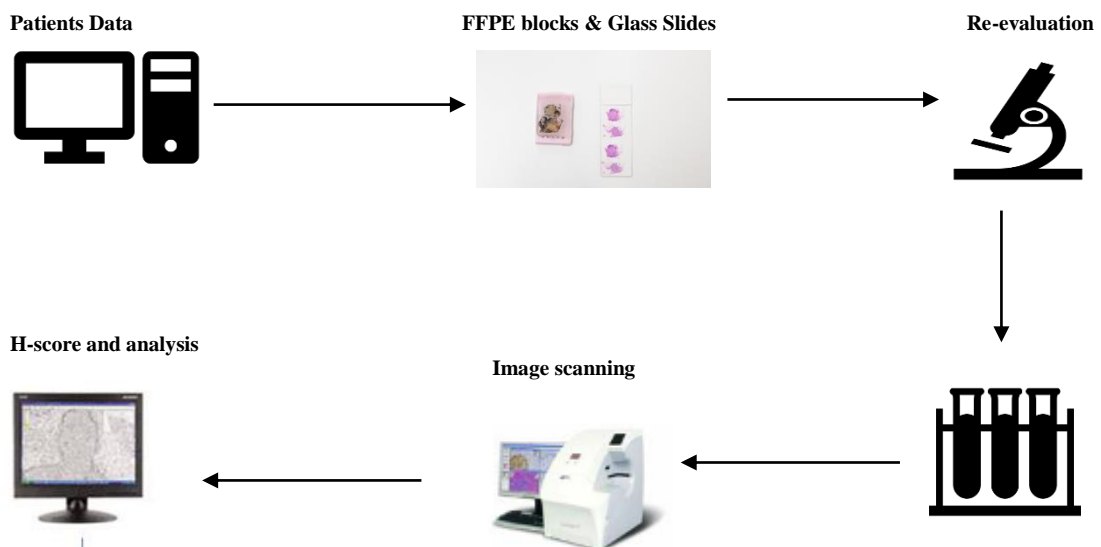
## 6 Research Methodology

The Chulalongkorn University Institutional Review Board has approved the study (IRB No. 411/64).

### 6.1 Research design

The study was designed as a retrospective study with quantitative analysis and correlation test conducted in Department of Pathology, Faculty of Medicine, Chulalongkorn University, 13<sup>th</sup> floor Aor-Por-Ror building (King Chulalongkorn Memorial Hospital (KCMH)). Samples were retrieved from the archives by electronic surgical database search (based on key words Thyroid, papillary thyroid, Follicular adenoma, goiter) from the year 2016-2018. After retrieval of formalin-fixed paraffin embedded samples, samples were sorted out based on exclusion and inclusion criteria, then re-evaluation of the histological samples by a pathologist for validation of diagnosis, establishment of final cohort and immunostaining was done. Followed by slide scanning and image analysis, as depicted in the conceptual framework below.

Figure 4.0 conceptual framework



For informed consent, as it does not directly involve the patient's, informed consent was not required. However, letter to Director of King Chulalongkorn Memorial Hospital for permission to use the archival samples for the study was sent. 147 samples, including 50 cases of goiter, 28 follicular adenoma, 19 follicular thyroid carcinoma and 50 papillary thyroid carcinomas were evaluated for histone acetylation. These cases were selected from a total of 367 cases, after excluding cases with missing demographic data, repeated hospital and surgical number and absent normal thyroid from same patient.

These were the sequential steps of the main research activities:

1. Electronic surgical pathology database search (based on keywords “Thyroid carcinoma, papillary, follicular, adenomas and goiter”) from the year 2016-2018.
2. Exclusion of repeated hospital number, missing demographic and clinical information, absent of normal thyroid tissue
3. Recording of baseline patients' information and final histological diagnosis
4. Retrieval of formalin-fixed paraffin- embedded samples and histological slides of eligible cases from the department archive
5. Establish data collection form (Microsoft excel 2019)
6. Re-evaluate histological specimens and record into data collecting form
7. The selected samples were re-evaluated for validation of the diagnosis and establishment of the final cohort of the cases
8. Immunostaining and slide scanning of the glass slides were done

9. Finally, image analysis with aperio image scope was done and simultaneously H-score was calculated for both thyroid lesion and normal thyroid tissue.

## 6.2 Sample Size

**Initial Sample Size taking the whole sample available in the system: N= 367, 64** Follicular thyroid carcinoma (FTC), **95** Papillary thyroid carcinoma (PTC), **79** Follicular adenoma (FA), and **108** nodular goiter will be analyzed using immunohistochemical study.

**Sample size: N=147 19** Follicular thyroid carcinoma (FTC), **50** Papillary thyroid carcinoma (PTC), **28** Follicular adenoma (FA), and **50** nodular goiter will be analyzed using immunohistochemical study. As we are studying an entire cohort of thyroid neoplasm in King Chulalongkorn Memorial Hospital at a given time (2016-2018), we rationalized that a definite sample size calculation is not warrant. None of the previous studies, that analyzed global histone acetylation had Standard deviation (SD) for H-score, and **Puppini C, et al**, had a relatively smaller sample size compared to us.

## 6.3 Patient population

The only inclusion criterion was presence surgically resected and morphologically verified goiter, FA, PTC and FTC, archived in the department of pathology, KCMH from January 2016 to December 2018. All the biopsies and Fine needle aspiration cytology cases were excluded. Cases with missing demographic and clinical data, repeated Hospital number (HN), Inadequate paraffin block or tissue for IHC staining and no normal thyroid tissue in same patient were excluded. The demographic and clinical data of the selected samples were punched in Microsoft excel (2019), the data

included were age, gender, laterality, and thyroid function test. Slides with previously stained sections from 147 thyroid lesions diagnosed from January 2016 – December 2018 were collected from the archives at the department of pathology, King Chulalongkorn Memorial Hospital. The patient's demographic and clinical data is summarized in table 2.

Variables	n (%)
Age (in years)	48.35 ( $\pm 15.15$ )
<= 20	4 (2.72%)
21-40	40 (27.2%)
41-60	69 (46.9%)
>60	34 (23.1%)
Gender	
Male	26 (17.7%)
Female	121 (82.3%)
Laterality	
Right	56 (47.1%)
Left	44 (29.9%)
Bilateral/ Total.	47 (32%)
Thyroid Function	
Hyperthyroidism	22 (15.0%)
Hypothyroidism	11 (7.5%)
Euthyroidism	85 (57.8%)
Not available	29 (19.7%)

Table 2.0 Clinical and demographic data of the patients is provided ( $n=147$ )



#### 6.4 H&E sections

An H&E section of each tumor was included in the study set. These slides were retrieved from the archive and had been constructed from 3 µm sections from the FFPE tumor sections stained with haematoxylin (DAKO) and eosin (DAKO) in the automated DAKO Cover Stainer according to the manufacturer's recommended protocol (see appendix for full protocol).

#### 6.5 Immunohistochemistry

Formalin-fixed paraffin-embedded sections of all specimens, including lesions and normal thyroid tissues of the same patients, were retrieved from the archive. Three µm-thick sectioned tissues were placed on the positively charged slides (SuperFrost Plus, Menzer- Glaser, and Freiburg, Germany) and deparaffinized with xylene and alcohol. For the immunohistochemical staining method, we follow the protocol recommended by the manufacturer of an automated Ventana BenchMark XT (Ventana Medical Systems, USA). After antigen retrieval, the slides were incubated with anti-acetyl histone H3 and H4 rabbit polyclonal antibody (catalog No. 06-599, Lot No. 3022883 and Catalog No.06-866, Lot No.2459612, respectively, Millipore, Germany) at dilution of 1/200 and 1/3,000 respectively, for 1 hour at 37°C. Thereafter, the UltraView DAB detection kit (Ventana Medical Systems, USA) was used for secondary antigen and chromogen.

## 6.6 Image acquisition

Whole slide images of both H&E slides and Anti-histone antibody IHC slides were acquired by scanning the conventional glass slides, using the Aperio CS2 whole slide scanner (Leica Biosystems, Germany) with a 40x lens and one focus layer without Z-stacking (i.e., several focus planes). The default autofocus mode was used, but in a few cases, the scanning may need manual focus to optimize the sharpness of the picture. The image files (.svs format) were stored on a Windows-based computer running the Aperio Scan Scope software.

## 6.7 Automated Digital image analysis

All slides stained with the two antibodies were digitalized by Aperio CS2 slide scanner (Aperio Technologies, USA). Image analysis was done using the Aperio Imagescope v.12.2.2.5015 software package (Aperio Technologies, USA). Tumor lesions and normal tissue from the same patients were analysed for comparison. To minimize the selection bias, five fields of 0.5x0.5 cm-area were chosen for examination and arbitrarily selected at the superior, inferior, left, right, and centre aspects. At least 5,000 nuclei were scored for each case. The intensity of immunostaining was automatically scored using the commercially available nuclear v.9 algorithm (Aperio Technologies, USA) (Fig.1). The grading scale was quantitatively defined as follows: 0 (negative), 1+ (weak nuclear staining), 2+ (moderate), and 3+ (strong). The number of nuclei in each category was determined simultaneously (Fig. 2, 3). Both intensity and proportion scores were then averaged to

provide an immunohistochemical score representing the degree of histone acetylation for each case according to the following formula:

$$\mathbf{H\ Score} = (\% \text{ of } 3 + \text{nuclei} \times 3) + (\% \text{ of } 2 + \text{nuclei} \times 2) + (\% \text{ of } 1 + \text{nuclei} \times 1)$$

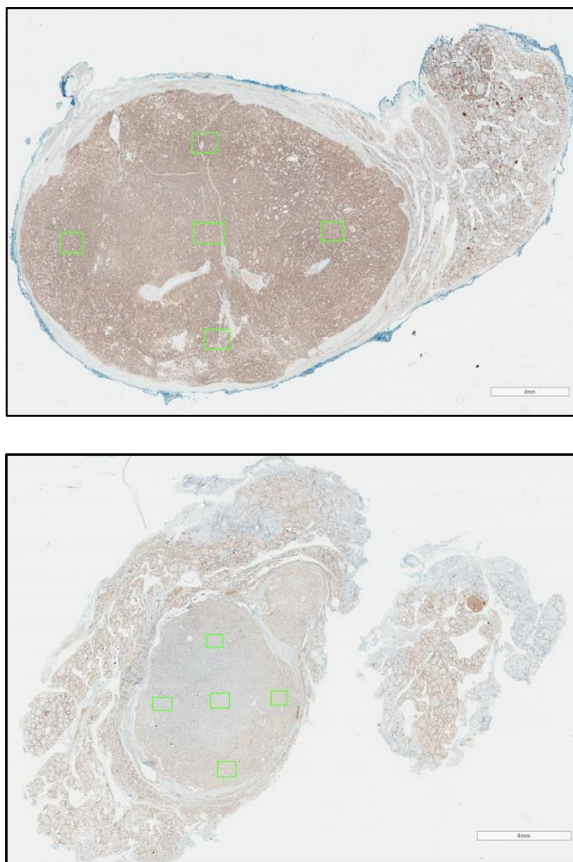


Fig. 5.0 Example of image analysis with five fields of 0.5x0.5 cm-area arbitrarily selected as superior, inferior, right, left and centre aspect.

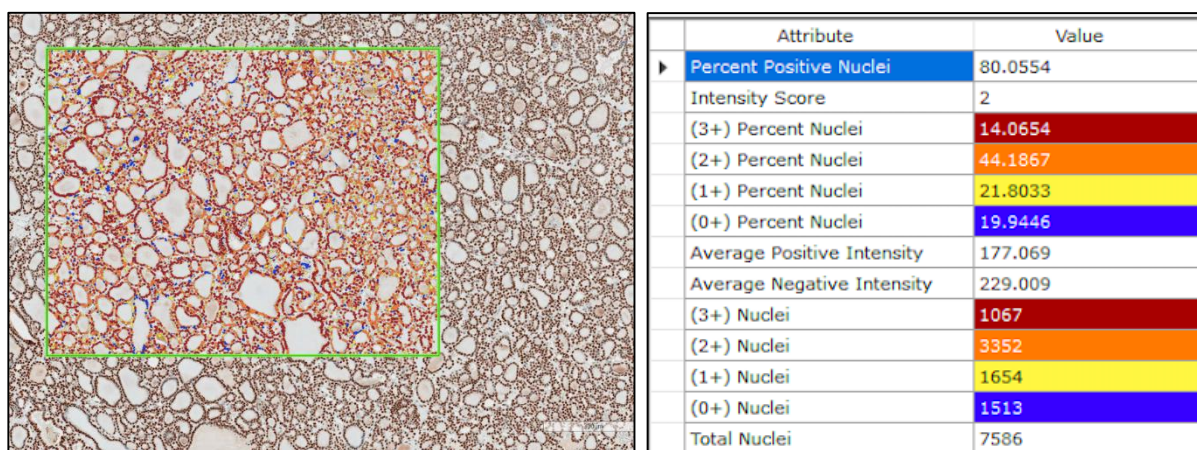


Fig. 6.0 Example of nuclear staining for 5-methylcytidine (A) with image analysis (B) and result of the analysis for the selected field with the grading of nuclear intensity as negative (blue), weakly positive (1+, yellow), moderately positive (2+, orange) and strongly positive (3+, red).

## 7 Statistical analysis

Descriptive statistics was done with Microsoft Office Excel 2016 (Microsoft, CA). Further statistical analysis was performed with Graph pad Prism 9 statistical software package. Students paired t test was used to compare variables, between thyroid lesions and their normal counterparts. Pearson (parametric) correlation was used to determined relationship between the variables. A p value of  $<0.05$  was considered statistically significant in all tests.

## 8 Results

A total of 147 thyroid tumors were enrolled in the study, including 50 PTCs, 19 FTCs, 28 FA and 50 nodular goiter. Clinical and demographic data of the patients is provided in Table 1.0 ( $n=147$ ).

For cases with nodular goiter, the Anti-acetyl histone antibody Score (H score) of their normal thyroid tissue counterpart had significantly higher acetylation level of

98.92  $\pm$  77.33 and 169.05  $\pm$  63.01 (mean  $\pm$  SD) for both anti-acetyl histone 3 antibody (H3K9/K14ac) and anti-acetyl histone 4 antibodies (H4K5,8,12 and 16ac) antibody respectively when compared to the nodular goitres the average scores of which were 80.4  $\pm$  73.5 and 134.5  $\pm$  75.5 respectively. These differences were statistically significant ( $p=0.0016$  and  $p<0.0001$  respectively).

Follicular adenoma (FA) showed a lower level of Anti-acetyl histone 3 and 4 antibody 124.0 $\pm$ 74.4 and 157.9 $\pm$ 74.4 respectively, compared to the adjacent normal thyroid, 1.33 $\pm$ 0.66 and 166.2  $\pm$  53.0. However, the differences were not statistically significant ( $p=0.33$  and  $p=0.533$ , respectively).

In the cases of PTC, the anti-acetyl histone 3 antibody showed slightly lower acetylation level 118.20  $\pm$ 73.99 compared to that of its adjacent normal thyroid tissue, 120.45 $\pm$ 104.12. Nonetheless, the differences were not statistically significant enough ( $p=0.86$ ). The average level of anti-acetyl histone 4 antibody was higher in PTC, 156.13 $\pm$  66.17, in comparison to its normal counterpart, 144.53  $\pm$  113.15. Again, they were not significantly different ( $p=0.46$ ).

For FTC, the acetylation level was slightly higher for both anti-acetyl histone 3 and histone 4 antibody, 106.89  $\pm$  78.27 and 142.30  $\pm$  92.89 compared to that of its normal counterpart 101.77 $\pm$  63.62 and 119.37  $\pm$  73.32. However, none of the differences were statistically significant ( $p=0.82$  and  $p=0.05$  respectively).

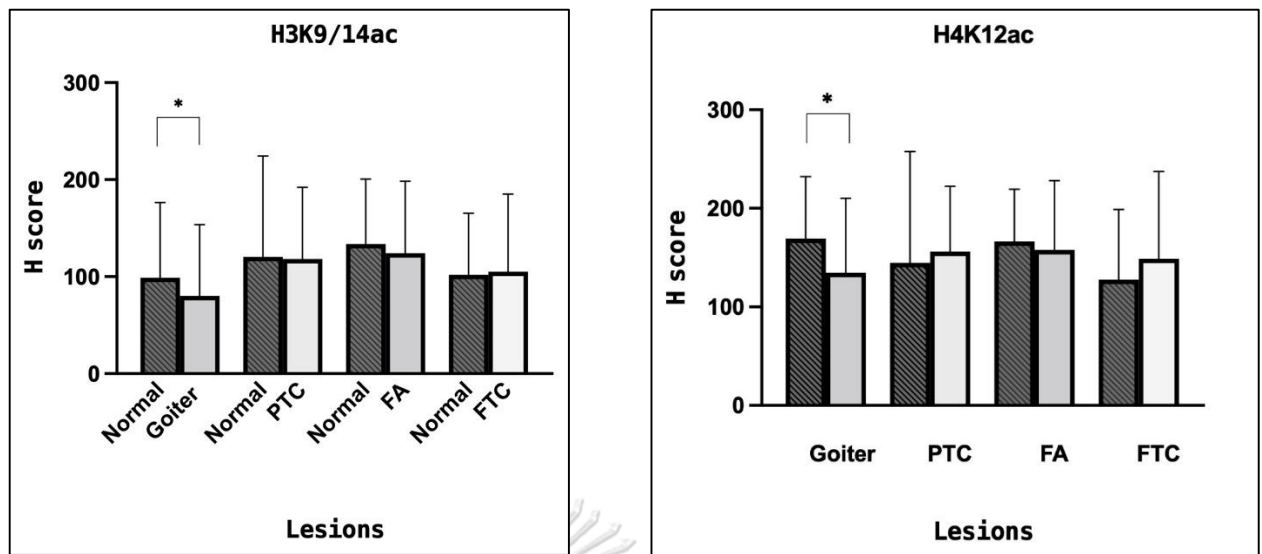


Fig 7.0 Bar Plot of H3K14ac and H4K12ac in Lesions (blank column) and Normal counterpart (pattern). Columns represent means and Standard deviation (SD). Statistically significant differences between the scores are depicted by solid-line brackets with \*p <0.05

## 9 Discussion

Although histones have long been considered simple packaging units for DNA, recent studies have made it clear that histones and nucleosome architecture modifications actively influence transcriptional regulation and thus may actively participate in many pathways involved in the cell cycle [11].

Among the many epigenetic changes known thus far, histone acetylation has been recognized as a fundamental process that strongly affects gene expression regulation. It's now known that any changes/ disruption of this phenomenon has been linked to carcinogenesis [11]. In fact, acetylated histone associates to active gene transcription and deacetylated histones to gene silencing [12, 13]. Variable degrees of expression of HDACs (histone deacetylases) and HATs (histone acetyltransferases) are found in many human malignant tissues. And the histones acetylation seems to influence


different processes, including the progression of the cell cycle, the dynamics of chromosomes, DNA recombination, DNA repair, and apoptosis. Thus, the control of aberrant activity and/or expression of these proteins have been favourable in the treatment of diseases as cancer.

Moreover, the fact that histone acetylation can be manipulated *in vivo* by different anticancer drugs brings in medical interest for its studies[9].

In the present study, we tested whether the levels of acetylated histones are modified in thyroid lesions compared to their adjacent normal counterpart. Compared to normal tissue, levels of acetylated H3 at residues K9/K14 and H4 at residue K12 were lower in nodular goiter and marginally higher in PTC and FTC. These data would suggest that acetylated levels of H3 at residue K9/14 suffer a reduction during thyroid goiter. However, we haven't been able to correlate our findings to other studies since no studies have compared the level of histone acetylation in goiter to that of normal thyroid tissue. Many studies have shown a lower level of H3K18 in various cancers, e.g., prostate cancers. Seligson et al. have demonstrated that lower acetylated H3K18 are associated with cancer recurrence[14]. The same group has also found that reduced levels of acetylated H3K18 are also associated with the poorer clinical outcome in lung and kidney cancer patients [15]. Similar data have been reported by the Nottingham group in studying a large cohort of breast cancer: low levels of acetylated H3K18 are associated with shorter disease-free survival and breast cancer-specific survival [16]. However, the findings in our studies for thyroid neoplasms are not in concordance with other types of tumors from other series. In this study, we used normal thyroid tissue from the same patient for comparison, unlike other studies

[17]. We also minimized possible sources of error by performing image analysis using unbiased field selection with over 5,000 nuclei analyzed in each sample on a standardized and widely used (Aperio) platform. Increased level of H3 at K9-K14 residue was also demonstrated by Puppini. et al. in both PTC and FTC.

In conclusion, this study demonstrates, for the first time, that nodular goitres have H3 and H4 deacetylation compared with their normal tissue counterpart, whereas, according to our results, these epigenetic events are not found in well-differentiated thyroid neoplasms (FA, FTC, and PTC). Further studies in larger scale are warranted to confirm our findings.





## REFERENCES



จุฬาลงกรณ์มหาวิทยาลัย  
**CHULALONGKORN UNIVERSITY**

1. Lakshmaiah, K.C., et al., *Epigenetic therapy of cancer with histone deacetylase inhibitors*. J Cancer Res Ther, 2014. **10**(3): p. 469-78.
2. Daniel, F.I., et al., *The role of epigenetic transcription repression and DNA methyltransferases in cancer*. Cancer, 2011. **117**(4): p. 677-87.
3. Portela, A. and M. Esteller, *Epigenetic modifications and human disease*. Nat Biotechnol, 2010. **28**(10): p. 1057-68.
4. Zhao, Z. and A. Shilatifard, *Epigenetic modifications of histones in cancer*. Genome Biol, 2019. **20**(1): p. 245.
5. Peterson, C.L. and M.A. Laniel, *Histones and histone modifications*. Curr Biol, 2004. **14**(14): p. R546-51.
6. Jung, C.K., et al., *The increase in thyroid cancer incidence during the last four decades is accompanied by a high frequency of BRAF mutations and a sharp increase in RAS mutations*. J Clin Endocrinol Metab, 2014. **99**(2): p. E276-85.
7. Tangjaturonrasme, N., P. Vatanasapt, and A. Bychkov, *Epidemiology of head and neck cancer in Thailand*. Asia Pac J Clin Oncol, 2018. **14**(1): p. 16-22.
8. Zhu, X. and S.Y. Cheng, *Epigenetic Modifications: Novel Therapeutic Approach for Thyroid Cancer*. Endocrinol Metab (Seoul), 2017. **32**(3): p. 326-331.
9. Giordano, T.J., *Genomic Hallmarks of Thyroid Neoplasia*. Annu Rev Pathol, 2018. **13**: p. 141-162.
10. Puppin, C., et al., *Levels of histone acetylation in thyroid tumors*. Biochem Biophys Res Commun, 2011. **411**(4): p. 679-83.
11. .
12. Lehrmann, H., L.L. Pritchard, and A. Harel-Bellan, *Histone acetyltransferases and deacetylases in the control of cell proliferation and differentiation*. Adv Cancer Res, 2002. **86**: p. 41-65.
13. Chrun, E.S., F. Modolo, and F.I. Daniel, *Histone modifications: A review about the presence of this epigenetic phenomenon in carcinogenesis*. Pathol Res Pract, 2017. **213**(11): p. 1329-1339.
14. Ahmad, M., et al., *Understanding histone deacetylases in the cancer development and treatment: an epigenetic perspective of cancer chemotherapy*. DNA Cell Biol, 2012. **31 Suppl 1**: p. S62-71.
15. Ma, X., H.H. Ezzeldin, and R.B. Diasio, *Histone deacetylase inhibitors: current status and overview of recent clinical trials*. Drugs, 2009. **69**(14): p. 1911-34.
16. Seligson, B., David, et al., *Global histone modification patterns predict risk of prostate cancer recurrence*. 2005 June. **435**(10.1038/nature03672).
17. Seligson, D.B., et al., *Global levels of histone modifications predict prognosis in different cancers*. Am J Pathol, 2009. **174**(5): p. 1619-28.

## **VITA**

**NAME** Nishal Chhetri  
**DATE OF BIRTH** 28 October 1992  
**PLACE OF BIRTH** Thimphu, Bhutan  
**INSTITUTIONS ATTENDED** Yangchenphug Higher Secondary School  
Institute of Applied Health Sciences, USTC  
**HOME ADDRESS** Jigme Dorji Wangchuck National Referral  
Hospital, Thimphu Bhutan, 11001

