

1-1-2007

## Full house positive immunohistochemical glomerulonephritis in a child with ventriculoatrial shunt

T. Deekajorndech

S. Boonyasuwat

P. Kingwatanakul

W. Kittikowit

Follow this and additional works at: <https://digital.car.chula.ac.th/clmjjournal>



Part of the [Medicine and Health Sciences Commons](#)

---

### Recommended Citation

Deekajorndech, T.; Boonyasuwat, S.; Kingwatanakul, P.; and Kittikowit, W. (2007) "Full house positive immunohistochemical glomerulonephritis in a child with ventriculoatrial shunt," *Chulalongkorn Medical Journal*: Vol. 51: Iss. 1, Article 5.

Available at: <https://digital.car.chula.ac.th/clmjjournal/vol51/iss1/5>

This Case Report is brought to you for free and open access by the Chulalongkorn Journal Online (CUJO) at Chula Digital Collections. It has been accepted for inclusion in Chulalongkorn Medical Journal by an authorized editor of Chula Digital Collections. For more information, please contact [ChulaDC@car.chula.ac.th](mailto:ChulaDC@car.chula.ac.th).

## Full house positive immunohistochemical glomerulonephritis in a child with ventriculoatrial shunt

Tawatchai Deekajorndech\* Savanuch Boonyasuwat\*

Pornchai Kingwatanakul\* Wipawee Kittikowit\*\*

**Deekajorndech T, Boonyasuwat S, Kingwatanakul P, Kittikowit W. Full house positive immunohistochemical glomerulonephritis in a child with ventriculoatrial shunt. Chula Med J 2007 Jan; 51(1): 43 - 8**

*An immune complex nephritis associated with chronically infected ventricular shunt is known as shunt nephritis. This condition is commonly occurs in children with ventriculoatrial shunt placement for palliation of hydrocephalus. A 6-year-old boy presented with generalized edema, hypertension, proteinuria, hematuria and hypocomplementemia. Renal biopsy findings showed diffuse proliferative glomerulonephritis with a full house positive immunostaining. After shunt removal, antibiotic therapy and steroid therapy, clinical symptoms and laboratory findings include complement levels were normalized although proteinuria and microscopic hematuria persisted.*

**Keywords :** Shunt nephritis, Ventriculoatrial shunt, Full house immunostaining.

Reprint request: Deekajorndech T. Department of Pediatrics, Faculty of Medicine,  
Chulalongkorn University, Bangkok 10330, Thailand.

Received for publication. July 27, 2006.

\* Department of Pediatrics, Faculty of Medicine, Chulalongkorn University

\*\* Department of Pathology, Faculty of Medicine, Chulalongkorn University

ธวัชชัย ตีฆจรเดช, สวนุช บุญญาสุวัฒน์, พรชัย กิ่งวัฒนกุล, วิภาวี กิตติโกวิท.  
ภาวะไตอักเสบจากการติดเชื้อของ ventriculoatrial shunt : รายงานผู้ป่วยเด็ก 1 ราย.  
จุฬาลงกรณ์เวชสาร 2550 ม.ค; 51(1): 43 - 8

การติดเชื้อของ ventriculoatrial shunt เป็นระยะเวลาสั้น ทำให้เกิดการสร้างสารประกอบ  
ภูมิคุ้มกัน (immune complex) และทำให้เกิดภาวะไตอักเสบ เรียกว่า shunt nephritis ภาวะนี้พบได้ไม่  
มาก แต่จะพบได้บ่อยในเด็กที่มีปัญหาเรื่องน้ำคั่งในโพรงสมองและต้องใส่ ventricular shunt

รายงานนี้เป็นตัวอย่างผู้ป่วยเด็กอายุ 6 ปี มีอาการบวม ความดันโลหิตสูง ตรวจปัสสาวะพบ  
ว่ามีโปรตีนและเม็ดเลือดแดง ร่วมกับมีระดับ C3 และ C4 complement ในเลือดต่ำ พยาธิสภาพจาก  
การตรวจเนื้อไตพบเป็น diffuse proliferative glomerulonephritis และพบว่า Immunofluorescence  
เป็น full house immunostaining ซึ่งมีลักษณะคล้ายกับที่พบในโรค systemic lupus erythematosus  
ผู้ป่วยมีอาการดีขึ้นหลังจากรักษาด้วยการเอา shunt ออก ให้ยาปฏิชีวนะ และให้เพรดนิโซโลน แต่ยังไม่  
พบว่าไม่มีโปรตีนในปัสสาวะอยู่

**คำสำคัญ :** Shunt nephritis, Ventriculoatrial shunt, Full house immunostaining.

Shunt nephritis is an immune complex glomerulonephritis associated with chronically infected shunt.<sup>(1,2)</sup> It is an infrequent condition but commonly occurs in children with ventriculoatrial shunt inserted for palliation of hydrocephalus.<sup>(1,3)</sup> This condition presents with no universal clinical features or laboratory findings so the diagnosis is often delayed by a misdiagnosis of urinary tract infection, vasculitis or Henoch-Scholein purpura.<sup>(4)</sup> We report a case of full house positive immunostaining glomerulonephritis associated with *Staphylococcus epidermidis* infection in a ventriculoatrial shunt.

### Case Report

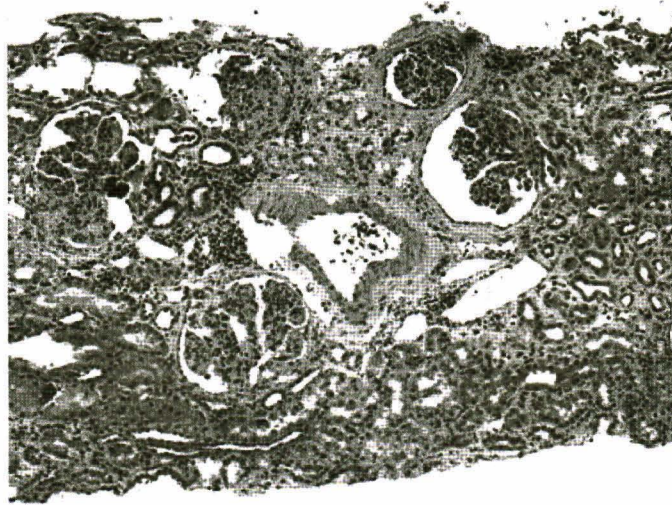A 6-year-old boy was referred to King Chulalongkorn Memorial Hospital due to generalized edema and hematuria for 3 weeks. He had had a right ventriculoatrial (VA) shunt deployed in infancy for Dandy-Walker malformation with hydrocephalus. On admission, he had a temperature of 37.8 C, pulse 122 beats/min and blood pressure 130/80 mmHg. Physical examination showed ascites, scrotal swelling and pretibial edema. He had weakness and hyperreflexia at both lower extremities. The remainder of the physical examination was unremarkable.

Laboratory data were as follows: Hb 11.8 g/dl, white blood cell 28,550/mm<sup>3</sup>, platelet 475,000/mm<sup>3</sup>, blood urea nitrogen 73 mg/dl, creatinine 0.6 mg/dl, sodium 122 mEq/l, potassium 3.1 mEq/l, chloride 94 mEq/l, bicarbonate 18 mEq/l, albumin 1.6 g/dl, total cholesterol 312 mg/dl, ESR 132 mm/hr, C3 51 mg/dl (normal 76-171 mg/dl, C4 6 mg/dl (normal 11-40 mg/dl). Antistreptolysin O, antinuclear antibody, anti-double stranded DNA, anticardiolipin and

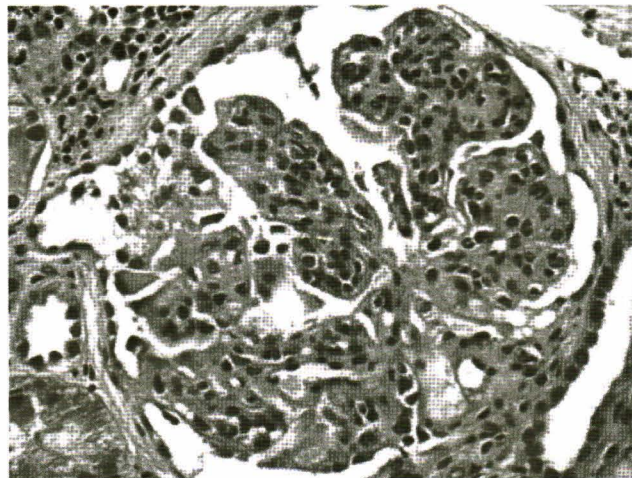
cryoglobulin were negative. Urinalysis showed proteinuria 3+, red blood cell numerous, white blood cell 10-20 /hpf and few granular casts. Urine protein excretion was 168 mg/kg/day and creatinine clearance was 82 ml/min/1.73 m<sup>2</sup>. Hemoculture and ventricular cerebrospinal fluid (CSF) culture grew *Staphylococcus epidermidis*.

Percutaneous renal biopsy was performed on the 3<sup>rd</sup> hospital day. Light microscopy showed marked widening of the mesangial area with marked increase of the mesangial cellularity. Nearly all glomeruli showed accentuation of the lobulation together with global endocapillary proliferation (Figure 1 and 2). There was patchy interstitial fibrosis and tubular atrophy with moderate interstitial infiltrate of the mononuclear cells. Immunofluorescence antibody study showed mild to moderate coarsely granular staining for IgG, IgA, IgM, C3 and C1q in the capillary loops. We diagnosed this case as diffuse proliferative immune complex glomerulonephritis, which was caused by shunt nephritis.

The VA shunt was removal with the simultaneous insertion of ventriculostomy. Vancomycin was administrated intravenously for 4 weeks and oral prednisolone was initiated at 2 mg/kg/day. Hypertension was controlled by hydrochlorothiazide, enalapril and amlodipine. With documentation of sterile CSF and blood culture, a new ventriculoperitoneal (VP) shunt was implanted. Serum levels of complement came to within the normal range in 4 weeks. Despite clinical symptoms were normalized, proteinuria still persisted. We added angiotensin receptor blocker (telmisartan) for reducing proteinuria. After three weeks, urine protein was decreased to 52 mg/kg/day.



**Figure 1.** Light microscopy shows patchy interstitial fibrosis and tubular atrophy with moderate interstitial infiltrate of the mononuclear cells.



**Figure 2.** Light microscopy shows increased mesangial cellularity and accentuation of the lobulation together with global endocapillary proliferation.

## Discussion

Shunt nephritis was first described by Black et al in 1965.<sup>(5)</sup> The incidence has been reported as 0.7 % to 2.25 %.<sup>(6)</sup> It commonly occurs in patients with VA shunt. Nevertheless, it has also been reported infected VP shunt, peritoneovenous Le Veen shunt and ventriculojugular shunt associated with nephritis.<sup>(4)</sup> Time from last shunt operation to the diagnosis of

shunt nephritis varies between 4 weeks to 21 years.<sup>(3)</sup> More than 70 % of these infections occur within 2 months.<sup>(7)</sup> *Staphylococcus epidermidis* and *Staphylococcus aureus* accounts for approximately 70 % and 20 % of the cases, respectively. Other organisms such as *Streptococcus*, *Propionibacterium acnes*, *Listeria monocytogenes*, *Corynebacterium bovis*, *diphtheroids*, *Micrococcus*, *Pseudomonas*

*aeruginosa, Cryptococcus neoformans, Moraxella bovis, Serratia, Bacillus spp* and *Histoplasma capsulatum* have also been described.<sup>(3,4,6)</sup>

Clinical features of patient with shunt nephritis cover a wide range of signs and symptoms, including hematuria (88 – 100 %), fever (88 %), anemia (85 – 100 %), proteinuria (64 -100%), hepatosplenomegaly (55 %), renal failure (41 - 61%), nephrotic syndrome (28 – 43 %), non thrombocytopenic purpura (19 %) and hypertension (15 %). Fever may be low grade associated with malaise, lethargy or anorexia. A few patients develop high fever and chills, low back pain, costovertebral angle tenderness or generalized convulsion. Other symptoms associated with shunt nephritis include urticaria vasculitis, necrotizing cutaneous vasculitis and arthritis.<sup>(6,8)</sup>

Laboratory findings are typical. Urinalysis reveals proteinuria and microscopic hematuria. Different types of renal cast such as granular cast, white and red cell cast, may be present. Anemia is usually presented, probably due to iron deficiency or decreased erythropoietin production. Renal function may vary from mild azotemia to renal failure. Blood and CSF cultures in patients with suspected shunt nephritis is an important clues but negative blood or CSF cultures do not exclude, especially after previous antibiotic therapy.<sup>(3,7)</sup> Tapping from shunt reservoir sites yield positive results in almost 90 % of the cases.<sup>(6)</sup> The plasma levels of C1, C2, C4 and C3 are usually low because of activation of the classic complement pathway.<sup>(7)</sup> The return to normal levels of C3 and C4 complement coincides with the recovery of infection and clinical remission of the glomerulonephritis. Other possible serologic abnormalities include the presence of rheumatoid factor, cryoglobulinemia, antinuclear

antibody, antineutrophil cytoplasmic autoantibody (ANCA), circulating immune complex, elevated sedimentation rate (ESR) and C- reactive protein levels.<sup>(4,7)</sup> In this case, supporting evidence for shunt nephritis were hypocomplementemia, elevated ESR, as is usual for shunt nephritis.

The predominant finding on renal biopsy is membranoproliferative glomerulonephritis. Immunofluorescence reveals granular immunoglobulin and complement deposits with a predominance of IgM, IgG and C3 complement. In this patient, renal biopsy shows diffuse proliferative glomerulonephritis and full house positive immunostaining. The presence of a full house positive immunostaining shows resemblance with lupus nephritis but a diagnosis of lupus nephritis is unlikely due to absence of prior symptoms and negative test for ANA and anti-double stranded DNA.

Treatment of shunt nephritis usually requires removal of the infected shunt.<sup>(3,9)</sup> A temporary extend drainage of CSF should be performed for about 1-2 weeks before a new shunt is reinserted. Antimicrobial chemotherapy directed at the suspected or causative agent should be given intravenously for at least 10 days.<sup>(10)</sup>

Outcomes after removal and antimicrobial treatment of shunt nephritis vary from recovery of renal function to end stage renal disease and fatalities in untreated cases. The prognosis is generally good if the infected shunt is removed early but irreversible renal failure can occur if delayed appropriated therapy.<sup>(3,4)</sup> The patient presented with persistent proteinuria and microscopic hematuria. We used angiotensin converting enzyme inhibitor (ACEI) and angiotensin receptor blocker (ARB) to reduce

proteinuria. Combination therapy with ACEI and ARB has the efficacy to decrease proteinuria in renal disease and result in significant preservation of the renal function.<sup>(11)</sup>

In conclusion, pediatricians should aware of shunt nephritis in any patient with a shunt who develops fever, hematuria, proteinuria and renal dysfunction. Diagnostic procedures should be undertaken immediately to allow a definite diagnosis and immediate treatment, which is effective for preventing irreversible renal damage.

## References

1. Cole BR, Salinas-Madrigal L. Acute proliferative glomerulonephritis and crescentic glomerulonephritis. In: Barratt TM, Avner ED, Harmon WE, eds. Pediatric Nephrology, 4<sup>th</sup> ed. Philadelphia: Lippincott Williams & Wilkins 1997:669-89
2. Kubota M, Sakata Y, Saeki N, Yamaura A, Ogawa M. A case of shunt nephritis diagnosis 17 years after ventriculoatrial shunt implantation. Clin Neurol Neurosurg 2001 Dec; 103(4): 245-6
3. Haffner D, Schindera F, Aschoff A, Matthias S, Waldher R, Scharer K. The clinical spectrum of shunt nephritis. Nephrol Dial Transplant 1997 Jun;12(6):1143-8
4. Balogun RA, Palmisano J, Kaplan AA, Khurshid H, Yamase H, Adams ND. Shunt nephritis from Propionibacterium acnes in a solitary kidney. Am J Kidney Dis 2001 Oct;38(4): E18
5. Black JA, Challacombe DN, Ockenden BG. Nephrotic syndrome associated with bacteremia after shunt operations for hydrocephalus. Lancet 1965 Nov;2(7419): 921-4
6. Rifkinson-Mann S, Rifkinson N, Leong T. Shunt nephritis. Case report. J Neurosurg 1991 Apr; 74(4):656-9
7. Iwata Y, Ohta S, Kawai K, Yamahana J, Sugimari H, Ishida Y, Saito K, Miyamori T, Futami K, Arakawa Y, et al. Shunt nephritis with positive titers for ANCA specific for proteinase 3. Am J Kidney Dis 2004 May;43(5):e11-6
8. Legoupil N, Ronco P, Berenbaum F. Arthritis-related shunt nephritis in an adult. Rheumatology (Oxford) 2003 May;42(5):698 - 9
9. Lee HS, Cha SH, Cho BS, Yang MH. A case of shunt nephritis. J Korean Med Sci 1995 Feb; 10(1): 62-5
10. Noiri E, Kuwata S, Nosaka K, Nakao A, Tanigushi S, Seki J, Uwatoko S, Suzuki K, Fukagawa M, Okuda T. Shunt nephritis: efficacy of an antibiotic trial for clinical diagnosis. Intern Med 1993 Apr;32(4):291-4
11. MacKinnon M, Shurraw S, Akbari A, Knoll GA, Jaffey J, Clark HD. Combination therapy with an angiotensin receptor blocker and an ACE inhibitor in proteinuric renal disease: A systemic review of the efficacy and safety data. Am J Kidney Dis 2006 Jul;48(1):8-20