

7-1-2010

Idiopathic granulomatous mastitis: A case report

J Prueksadee

D Boonjunwetwat

J. Chayakulkheeree

Follow this and additional works at: <https://digital.car.chula.ac.th/clmjjournal>



Part of the [Medicine and Health Sciences Commons](#)

Recommended Citation

Prueksadee, J; Boonjunwetwat, D; and Chayakulkheeree, J. (2010) "Idiopathic granulomatous mastitis: A case report," *Chulalongkorn Medical Journal*: Vol. 54: Iss. 4, Article 6.

Available at: <https://digital.car.chula.ac.th/clmjjournal/vol54/iss4/6>

This Case Report is brought to you for free and open access by the Chulalongkorn Journal Online (CUJO) at Chula Digital Collections. It has been accepted for inclusion in Chulalongkorn Medical Journal by an authorized editor of Chula Digital Collections. For more information, please contact ChulaDC@car.chula.ac.th.

Idiopathic granulomatous mastitis: A case report

Jenjeera Prueksadee*

Darunee Boonjunwetwat* Jatuporn Chayakulkheeree*

Prueksadee J, Boonjunwetwat D, Chayakulkheeree J. Idiopathic granulomatous mastitis: A case report. Chula Med J 2010 Jul - Aug; 54(4): 363 - 8

Idiopathic granulomatous mastitis is an uncommon benign breast disease diagnosed from exclusion. It mimics malignant breast tumor in terms of clinical and imaging features. We hereby report a case of painful lump in the left breast. Mammograms and ultrasound findings could not exclude malignant mass. Wide excision was performed and the final histopathological diagnosis of granulomatous mastitis was concluded. In conclusion, the clinical and imaging findings of granulomatous mastitis are similar to carcinoma. Tissue diagnosis was very important to distinguish these two entities before starting management and avoiding unnecessary mastectomy.

Keywords: *Granulomatous mastitis, Benign, Malignant, Imaging.*

Reprint request: Prueksadee J. Department of Radiology, Faculty of Medicine, Chulalongkorn University, Bangkok 10330, Thailand.

Received for publication. October 15, 2009.

เจนจิรา ปรีกษัติ, ตรุณี บุญยืนเวทวัฒน์, จตุพร ชยะกุลศิริ. Idiopathic granulomatous mastitis: รายงานผู้ป่วย 1 ราย. จุฬาลงกรณ์เวชสาร 2553 ก.ค. - ส.ค.; 54(4): 363 - 8

Idiopathic granulomatous mastitis พบได้ไม่บ่อย และไม่สามารถแยกจากมะเร็ง เต้านมได้ ทั้งจากการตรวจร่างกายหรือภาพแมมโมแกรมและอัลตราซาวด์ รายงานผู้ป่วยหญิงซึ่งมาตรวจรักษา ด้วยอาการคลำพบก้อนเจ็บที่เต้านมข้างซ้าย การตรวจแมมโมแกรมและอัลตราซาวด์พบก้อนมีลักษณะ ขอบไม่เรียบคล้ายมะเร็ง ผู้ป่วยได้รับการผ่าตัดและผลเป็น *Granulomatous mastitis* บทสรุปพบว่า การตรวจร่างกายและการตรวจแมมโมแกรม รวมทั้งอัลตราซาวด์ไม่สามารถแยกแยะระหว่าง *granulomatous mastitis* และมะเร็งได้ การตรวจชิ้นเนื้อมีความสำคัญมากเพื่อการวางแผนการรักษาที่ถูกต้อง และเพื่อ หลีกเลี่ยงการผ่าตัดเต้านมโดยไม่จำเป็น

คำสำคัญ : เต้านมอักเสบจากการติดเชื้อในกลุ่ม *granuloma*, เนื้องอกชนิดธรรมดา, เนื้องอกชนิดร้ายแรง, ภาพถ่าย.

Idiopathic granulomatous mastitis is a rare benign breast disease which was first described by Kessler E. and Wolloch Y. ⁽¹⁾ in 1972. It is characterized by chronic, necrotizing granulomatous lobulitis of unknown etiology, and its clinical and mammographic features mimic those of mammary carcinoma. It usually occurs in women of child-bearing

age; most patients are relatively young parous, < 50 years of age. The lesions are usually unilateral and occurs in every quadrant region except for the subareolar. A definite diagnosis could not be made until examination of excisional biopsy or fine-needle aspiration cytology is done.

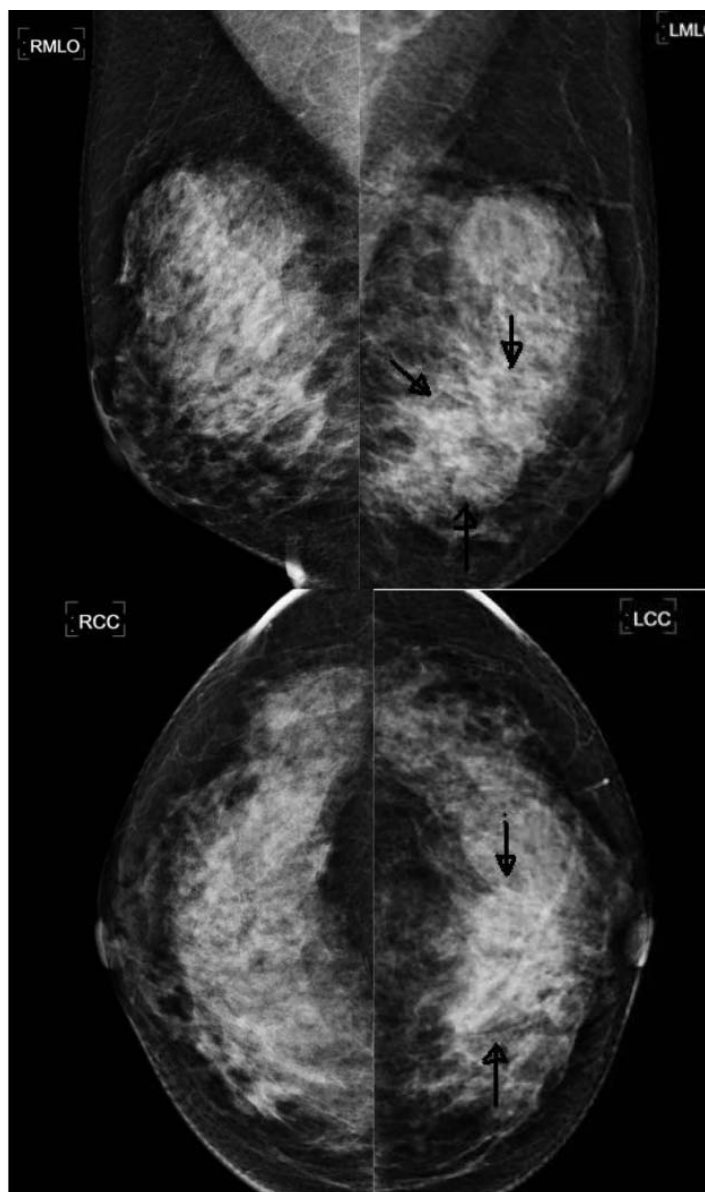


Figure 1. Mediolateral oblique (MLO) and Craniocaudal (CC) views of both breasts. There is an ill-defined slightly hyperdense mass at left lower inner quadrant (arrows).

Case Report

A 41-year-old Thai woman presented with a palpable lump in the left breast with mild tender for two weeks. She had no known underlying disease or long-term medical treatment. She was received bilateral mammography and ultrasound. The mammograms showed an ill-defined slightly hyperdense mass at the lower inner quadrant of her left breast (Figure 1) that ultrasound revealed three irregular hypoechoic/heterogeneous echogenic masses, size ranging 1 to 2 cm (Figure 2). Fine-needle aspiration (FNA) of the masses turned out to be

chronic inflammatory cells. She was treated with antibiotics for two weeks and the clinical outcome did not improve. Finally, she underwent wide excision. Histopathological report verified few granulomatous composed of epithelioid histiocytes and few multinucleated giant cells. There were also organized inflammation noted, with formation of granulation tissue and infiltration of mixed inflammatory cells. These findings were compatible with granulomatous mastitis. No malignancy was detected. Acid Fast Bacilli (AFB) was performed to exclude tuberculosis and it was negative.

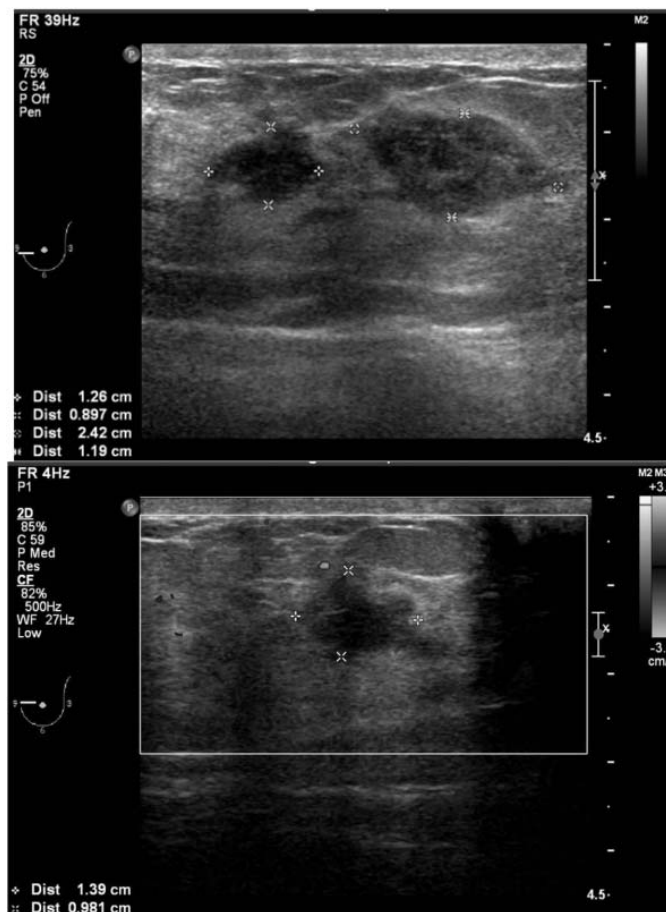


Figure 2. Ultrasound revealed three irregular hypoechoic/heterogeneous echogenic masses in the left lower inner quadrant.

Discussion

Although the exact etiology of idiopathic granulomatous mastitis remains unclear, associations with autoimmune disorders, oral contraceptive use, pregnancy, hyperprolactinemia and alpha-1-antitrypsin deficiency have been suggested.⁽²⁻⁵⁾ The common causes of granulomatous disease such as tuberculosis, sarcoidosis or Wegener's granulomatosis must be excluded before reaching the diagnosis of idiopathic granulomatous mastitis. In our case, the mammograms showed an ill-defined slightly hyper density mass and the ultrasound findings revealed as irregular hypoechoic/heterogeneous echoic masses. These findings were classified as ACR-BIRADS 5 (American College of Radiology, Breast Imaging Reporting And Data System). The mammograms and ultrasound features in our case were shown as in other reports which could not distinguish between malignancy and infection. Therefore, tissue diagnosis was very important to avoid unnecessary mastectomy. The optimal treatment for IGM is unclear. Most patient have been treated with wide surgical excision or total mastectomy, though recurrence is common. High-dose glucocorticoids have been shown to be effective but not without complications, including difficult wound healing, fistula formation and recurrence on withdrawal. Kim and others have reported the use of methotrexate (MTX) in combination with high-dose prednisolone for refractory cases of IGM.^(6,7)

Mammograms reading and ultrasound performing should be carefully done to exclude multifocal or multicentric lesions that altered surgical management. Our case showed multifocal lesions and wide excision was performed. Some patients had

relapses in the form of chronic mastitis after excisional biopsies.^(8,9) Thus, after treatment, a close follow-up must be informed to the patient.

In conclusion, the idiopathic granulomatous mastitis mimics malignant tumor in terms of physical signs and imaging findings. The definite tissue diagnosis should be considered carefully for further appropriate management.

References

1. Kessler E, Wolloch Y. Granulomatous mastitis: a lesion clinically simulating carcinoma. *Am J Clin Pathol* 1972 Dec; 58(6): 642-6
2. Bani-Hani KE, Yaghan RJ, Matalka II, Shatnawi NJ. Idiopathic granulomatous mastitis: time to avoid unnecessary mastectomies. *Breast J* 2004 Jul; 10(4): 318-22
3. Galea MH, Robertson JF, Ellis IO, Elston CW, Blamey RW. Granulomatous lobular mastitis. *Aust N Z J Surg* 1989 Jul; 59(7): 547-50
4. Newnham MS, Shirley SE, McDonald AH. Granulomatous lobular mastitis. A case report and review of the literature. *West Indian Med J* 2001 Sep; 50(3): 236-8
5. Diesing D, Axt-Fliedner R, Hornung D, Weiss JM, Diedrich K, Friedrich M. Granulomatous mastitis. *Arch Gynecol Obstet* 2004 May; 269(4): 233-6
6. Kim J, Tymms KE, Buckingham JM. Methotrexate in the management of granulomatous mastitis. *Aust NZ J Surg* 2003 Apr; 73 (4): 247-9
7. Raj N, Macmillan RD, Ellis IO, Deightom CM. Rheumatogogists and breasts : immuno-suppressive therapy for granulomatous mastitis. *J Rheumatol* 2004 Aug; 43(8) :1055-6

8. Brown KL, Tang PH. Postlactational tumoral granulomatous mastitis: a localized immune phenomenon. *Am J Surg* 1979 Aug;138(2):326-9
9. Salam IM, Alhomsy MF, Daniel MF, Sim AJ. Diagnosis and treatment of granulomatous mastitis. *Br J Surg* 1995 Feb;82(2):214