

11-1-2011

CT appearances of responsive gastrointestinal stromal tumors (GISTs) after imatinib mesylate treatment

S Sriariyametta

V Sriuranpong

K Arjhansiri

B. Chaopathomkul

Follow this and additional works at: <https://digital.car.chula.ac.th/clmjjournal>



Part of the [Medicine and Health Sciences Commons](#)

Recommended Citation

Sriariyametta, S; Sriuranpong, V; Arjhansiri, K; and Chaopathomkul, B. (2011) "CT appearances of responsive gastrointestinal stromal tumors (GISTs) after imatinib mesylate treatment," *Chulalongkorn Medical Journal*. Vol. 55: Iss. 6, Article 4.

Available at: <https://digital.car.chula.ac.th/clmjjournal/vol55/iss6/4>

This Article is brought to you for free and open access by the Chulalongkorn Journal Online (CUJO) at Chula Digital Collections. It has been accepted for inclusion in Chulalongkorn Medical Journal by an authorized editor of Chula Digital Collections. For more information, please contact ChulaDC@car.chula.ac.th.

CT appearances of responsive gastrointestinal stromal tumors (GISTs) after imatinib mesylate treatment

Sukrit Sriariyametta* Virote Sriuranpong**

Kiat Arjhansiri*** Bundit Chaopathomkul*

Sriariyametta S, Sriuranpong V, Arjhansiri K, Chaopathomkul B. CT appearances of responsive gastrointestinal stromal tumors (GISTs) after imatinib mesylate treatment. Chula Med J 2011 Nov - Dec; 55(6): 559 - 70

- Background** : *Gastrointestinal stromal tumors (GISTs) have their specific receptor that allows the use of specific target drug. CT scan is the imaging technique of choice to evaluate the response of the tumor. There are some conflicts about CT parameter such as size and density that confuse radiologists in the evaluation of the tumor response.*
- Objective** : *Our objective is to evaluate CT appearances in patients with GISTs who have response after imatinib treatment by combination of RECIST criteria and density, vascularity, solid nodule and cystic change of the tumor.*
- Design** : *Retrospective study*
- Setting** : *King Chulalongkorn Memorial Hospital, Thai Red Cross Society.*
- Materials and Methods** : *Sixty-five tumors from 14 patients were 33 intrahepatic and 32 extrahepatic lesions. All patients underwent contrast-enhanced MDCT scan in both pre-and post treatment periods. The axial images of CT portovenous phase with 8-mm slice thickness were reviewed by the author and one experienced gastrointestinal radiologist, with consensus.*

* Department of Radiology, King Chulalongkorn Memorial Hospital

** Department of Medicine, Faculty of Medicine, Chulalongkorn University

*** Department of Radiology, Faculty of Medicine, Chulalongkorn University

- Results** : *Significant decrease in size and density of overall tumors were noted. The extrahepatic lesions had statistically significant decrease in both size and density than intrahepatic lesions. On pre-treatment images, solid nodules within the lesions were found in 18 lesions (27.7%), mainly in extrahepatic lesions while tumor vessels were found in 7 extrahepatic lesions (10.8%). There were new cystic-like lesions in the liver of 2 patients on post-treatment images. No new solid mass was seen after treatment.*
- Conclusion** : *Our data supports other studies on the response of GISTs to imatinib treatment. We suggest that in case of mismatch between size and density, size may not be reliable factor. Density, vascularity, solid nodule and cystic change may complement to each other in evaluation of response to treatment in addition to size. Extrahepatic lesions display more definite response in terms of size and density when compared to intrahepatic lesions.*
- Keywords** : *Gastrointestinal stromal tumors, GISTs, CD 117, imatinib, imatinib mesylate, CT.*

Reprint request: Chaopathomkul B. Department of Radiology, King Chulalongkorn Memorial Hospital, Bangkok 10330, Thailand. Email: bchaopathomkul@hotmail.com

Received for publication. March 1, 2011.

สุกฤษฎี ศรีอาริยะเมตตา, วิโรจน์ ศรีอุฬารพงศ์, เกียรติ อาจหาญศิริ, บัณฑิต เจ้าปทุมกุล.
ลักษณะของภาพเอกซเรย์คอมพิวเตอร์ใน Gastrointestinal stromal tumors (GISTs)
ที่ตอบสนองต่อการรักษาด้วย Imatinib Mesylate. จุฬาลงกรณ์เวชสาร 2554 พ.ย. - ธ.ค.;
55(6): 559 - 70

- เหตุผลของการทำวิจัย** : Gastrointestinal stromal tumors (GISTs) มี receptor เฉพาะที่ทำให้สามารถทำการรักษาได้โดยใช้ยาที่มีความจำเพาะต่อ receptor ชนิดนี้ การตรวจด้วยเครื่องเอกซเรย์คอมพิวเตอร์เป็นวิธีการที่นำมาใช้ในการประเมินผลของการรักษา แต่บางครั้งขนาดของเนื้องอกกับการวัด density ของเนื้องอกให้ผลขัดแย้งกันทำให้รังสีแพทย์เกิดความสับสนในการประเมินผลการรักษา
- วัตถุประสงค์** : เพื่อหาลักษณะของภาพเอกซเรย์คอมพิวเตอร์ใน Gastrointestinal stromal tumors (GISTs) ที่ตอบสนองต่อการรักษาด้วย Imatinib Mesylate โดยการใช้ RECIST criteria ร่วมกับ density การเห็นหลอดเลือดในเนื้องอก การเห็น solid nodule และ การเปลี่ยนแปลง density ที่ใกล้เคียงกับถุงน้ำของเนื้องอก
- รูปแบบการวิจัย** : การศึกษาแบบย้อนหลัง
- สถานที่ทำการศึกษา** : โรงพยาบาลจุฬาลงกรณ์ สภากาชาดไทย
- ตัวอย่างและวิธีการศึกษา** : ได้ศึกษาจำนวนก้อนเนื้องอกทั้งหมด 65 ก้อนจากผู้ป่วย 14 ราย โดยแบ่งเป็น ก้อนในตับ 33 ก้อนและก้อนนอกตับ 32 ก้อน ผู้ป่วยทุกรายได้รับการตรวจด้วยเครื่องเอกซเรย์คอมพิวเตอร์ทั้งก่อนและหลังการรักษา โดยได้รับการฉีดสารทึบรังสี ภาพที่นำมาศึกษาเป็นภาพช่วง portovenous ที่มีความหนาของภาพ 8 มิลลิเมตรโดยการศึกษาภาพทำโดยผู้เขียนร่วมกับรังสีแพทย์ที่มีประสบการณ์หนึ่งคนโดยลงความเห็นพ้องกัน
- ผลการศึกษา** : เนื้องอกที่ทำการศึกษาทั้งหมดมีการเปลี่ยนแปลงอย่างมีนัยสำคัญทั้งทางด้านขนาดและ density โดยเนื้องอกนอกตับมีการเปลี่ยนแปลงทั้งทางด้านขนาดและ density มากกว่า เนื้องอกในตับ ก่อนการทำการรักษาพบว่ามี solid nodule ใน 18 lesions (27.7%) โดยมากพบใน extrahepatic lesions ในขณะที่การเห็นหลอดเลือดในเนื้องอกพบใน 7 extrahepatic lesions (10.8%). หลังการรักษาพบลักษณะคล้ายถุงน้ำในตับของผู้ป่วย 2 คนซึ่งไม่พบในการตรวจก่อนการรักษาในการศึกษาครั้งนี้ไม่พบเนื้องอกเกิดขึ้นใหม่หลังได้รับการรักษา

สรุป

: ข้อมูลที่ได้จากการศึกษาครั้งนี้มีความสอดคล้องกันกับการศึกษาที่เคยทำกันมาก่อนหน้านี้ในกรณีที่มีขนาดและ density ให้ผลขัดแย้งกัน ขนาดมีความน่าเชื่อถือน้อยกว่า ลักษณะของ density การเห็นหลอดเลือดในเนื้องอก การเห็น solid nodule และ การเปลี่ยนแปลง density ที่ใกล้เคียงกับถุงน้ำจะเป็นเหตุผลสนับสนุนซึ่งกันและกันในการประเมินผลการรักษานอกจากการอาศัยเพียงแต่เรื่องของขนาดเพียงอย่างเดียว ข้อมูลของเราพบว่าเนื้องอกนอกตับให้การตอบสนองที่ดีกว่าเนื้องอกในตับ ในแง่การประเมินด้วยขนาดและ density

คำสำคัญ

: *Gastrointestinal stromal tumors, GISTs, CD 117, imatinib, imatinib mesylate, เครื่องเอกซเรย์คอมพิวเตอร์.*

The most common mesenchymal tumor of the gastrointestinal tract is gastrointestinal stromal tumors (GISTs)⁽¹⁾

GISTs were actually originated from the interstitial cell of Cajal which is the pacemaker cell of the gastrointestinal tract.^(2, 3) Immunohistochemistry can distinguished GISTs from other mesenchymal tumors of the gastrointestinal tract by expression of the receptor tyrosine kinase, KIT (CD117), a growth factor receptor (also found in interstitial cell of Cajal) or platelet derived growth factor receptor- α (PDGFR α), as a derivative obtained from exon mutation.⁽²⁻⁵⁾ Other marker that can be found in GISTs by immunohistochemistry is CD34 which is seen in approximately 70% of GISTs.⁽⁶⁾

Tumor resection is the first-line of treatment for patients who are considered being resectable. Conventional chemotherapy and radiation have poor outcome for unresectable or metastatic cases.⁽⁷⁾ In these cases, imatinib mesylate, a selective competitive tyrosine kinase inhibitor, a molecular-targeted drug being is proved as the first systemic therapy for metastatic GISTs. Imatinib has a role for treatment in all phases of chronic myelogenous leukemia (CML).^(8,9) The Food and Drug Administration (FDA) has already approved imatinib mesylate for treatment of GISTs in USA since February 2002. In Thailand, imatinib has also been approved to be used in treatment of unresectable or metastatic GISTs since 2002 and also in case of CML.

Multidetector computed tomography (MDCT) is the imaging technique of choice to diagnosis and follow up the treatment response due to its high spatial resolution and available worldwide. Although positron

emission tomography (PET) or PET-CT study with 18-fluorodeoxyglucose demonstrates the early response as 24 hrs following initiation of the treatment but it is limited in cost and accessibility. GIST is highly vascular tumor on MDCT with well-defined margin and it appears as solid, homogeneously enhancing mass on post enhanced MDCT scan. Huge GIST shows less homogeneous enhancement due to necrotic, hemorrhagic or degenerating components. Most primary mass is exophytic from the wall of the gastrointestinal tract with evidence of pressure effect to the adjacent organs. Even though it has a large size, it is not common to cause gastrointestinal tract obstruction⁽¹⁰⁻¹³⁾ The Response Evaluation Criteria in Solid Tumors (RECIST) criteria are now widely used for evaluation of solid tumor after treatment including GISTs after treatment with imatinib mesylate. A RECIST criterion uses the sum of longest dimension of solid tumors to assess response of treatment. MDCT scan is the modality of choice to evaluate the imatinib response of GISTs. However a recent study by *Choi et al.* found that RECIST criteria was not appropriate to evaluate of the response of GISTs after treatment with imatinib mesylate because of the possibility of the increase in tumor size in some lesions despite of its non-uptake on FDG PET study. They suggested that the decrease in tumor density is more important CT criterion than size to identify positive tumor response.⁽¹⁴⁾ *Warakulle et al.* also supported the idea of decrease density as disease response.⁽¹⁵⁾ The conflict of the tumor size and density for evaluation of the tumor response often confuse radiologists in their daily clinical work, so we retrospectively reviewed the CT findings of the GISTs before and after treatment.

Materials and methods

Materials

Medical records were reviewed to obtain a list of patients who were initially prescribed with imatinib mesylate (400 mg/day) from Jan 2003 to June 2006. Then, we selected the patients who were proved of GISTs by immunohistochemistry and had done abdominal CT scan before treatment, within the first 6 months after starting imatinib.

The exclusion criteria include MDCT studies from outside hospital either before or during follow-up treatment, no image data on Picture Archiving and Communication System (PACS), patients who had no immunohistological result to confirm the diagnosis of GISTs, patients who previously received imatinib or other chemotherapy. Finally fourteen patients (7 men, 7 women) were included into this study. We concluded that primary and recurrent tumors were considered extrahepatic lesions.

Imaging techniques

All abdominal MDCT studies were performed with 4- or 16-slice CT scanners (Somatom sensation 4 and 16 slices, Siemens Medical Solution, German). The kVp setting of both scanners was equal at 120 kVp while mAs of both scanners were slightly different; 120 mAs for 4-slice scanner and 140 mAs for 16-slice scanner. Precontrast study was done and followed by intravenous administration of 90-100 ml of low osmolar iodinated contrast medium with concentration of 300 mgI/ml (Iopromide, lobitridol or lopamidol) with the injection rate ranged from 2.0 - 3.0 ml/second at 8-mm slice thickness. The scanning times for portovenous phase study were 80 seconds and 75 seconds for 4 slices and 16 slices scanners, respectively. The axial images of CT portovenous

phase were retrieved from PACS and reviewed by the author and one experienced gastrointestinal radiologist with consensus.

Image analysis

We categorized all lesions into two groups: intrahepatic and extrahepatic lesions that were located in the intraperitoneal or pelvic cavities. The lesions were enrolled to the study by consensus of both reviewers on the basis of the longest diameter not less than 1 cm and chosen up to 10 lesions per location (intrahepatic or extrahepatic) if there were multiple lesions in one location, on the pretreatment images. Sixty-five lesions were enrolled in this study (33 lesions in the liver and 32 lesions in the intraperitoneal and pelvic cavities). Both reviewers together compared the change on appearances of each lesion between pretreatment and post treatment images which included size, density, tumor vessels, solid nodules within the lesions, new solid mass or cystic-like lesion.

Tumor size was measured at the longest dimension of each lesion by electronic caliper on PACS. The tumor density was measured in Hounsfield units (HU) by drawing a region of interest around the margin of each lesion and computed by CT software. The percentage of change in tumor size and density from pretreatment to post treatment evaluations were computed for each lesion as well as the average percentage of change in the sum of tumor size and density from all lesions.

Subjective response of the tumor was determined by consensus both reviewers on the basis of presence or absence of tumor vessels, solid nodules within the lesions including new cystic-like lesion or solid mass for each patient.

Statistical analysis

Comparison of change in tumor size and density between pretreatment and post treatment evaluations of overall lesions was performed using Paired T test. Comparison of percentage of change in tumor size and density between intrahepatic and extrahepatic lesions was performed using of Student's T test. Comparisons with $p < 0.05$ represented statistically significance.

Results

There were 65 lesions from 14 patients with age of 30-84 years old (mean, 59.2 years old). Eight patients had primary tumor before treatment, including non resectable tumor, incomplete tumor removal by surgery and recurrent at primary site after surgery. Six patients did not have primary tumor before treatment. The size ranged from 1.18 to 20.42 cm (mean, 4.00 cm) before treatment and ranged from 0 to 18.07 cm (mean, 3.25 cm) after treatment. The density of these lesions ranged from 16.71 to 104.50 HU (mean, 58.38 HU) before treatment and ranged from 6.60 to 92.61 HU (mean, 37.00 HU) after

treatment [Table1]. Forty-eight of 65 lesions (73.8%) were decrease in both size and density. Among these lesions, three extrahepatic lesions (4.6%) were completely disappeared.

The rest of 17 lesions demonstrated in different findings. Two intrahepatic lesions (3.1%) were no significant change in density (change less than 0.1%) but decrease in size, about 11.2% and 31.2 %. One extrahepatic lesion (1.5%) was unchanged in size but decreased in density, about 48.5%. 8 lesions (12.3%); 4 intrahepatic and 4 extrahepatic lesions, had increase in size (ranged from 3.1% to 50.7%; mean = 20.4%) after treatment despite of decrease in CT attenuation (ranged from 3.2% to 74.4%; mean = 45.4%). Four intrahepatic and 1 extrahepatic lesions (7.7%) demonstrated increase in density (ranged from 5.1% to 74.3%; mean = 29.6%) and decrease in size (ranged from 5.9% to 41.2%; mean = 21.8%) after treatment. There was only one intrahepatic lesion (1.5%) that increase in both size (17.1%) and attenuation (23.9%) on the follow-up CT images.

Table 1. Tumor size and density on CT scan before and after treatment.

Measurement	Intrahepatic (n=33)		Extrahepatic (n=32)		Total (n=65)	
	Mean \pm SD	Range	Mean \pm SD	Range	Mean \pm SD	Range
Size (cm)						
Pretreatment	2.89 \pm 1.55	1.18-6.60	5.14 \pm 4.23	1.50-20.42	4.00 \pm 3.34	1.18-20.42
Post treatment	2.63 \pm 1.59	0.86-6.34	3.89 \pm 3.49	0-18.07	3.25 \pm 2.80	0-18.07
% change	-10.95 \pm 18.77	-49.9 to + 46.6	-26.00 \pm 33.32	-100* to +50.7	-18.36 \pm 27.77	-100* to +50.7
Density (HU)						
Pretreatment	62.88 \pm 18.21	16.71-104.50	53.73 \pm 12.41	29.56-82.32	58.38 \pm 16.17	16.71-104.5
Post treatment	47.57 \pm 18.86	17.26-92.61	26.09 \pm 12.62	6.60-64.64	37.00 \pm 20.00	6.60-92.61
% change	-21.05 \pm 30.19	-74.00 to +74.3	-51.07 \pm 25.67	-100* to +5.1	-35.82 \pm 31.68	-100* to +74.3

*-100 means disappearance of the lesions

Up to 6 months after treatment, decrease in the overall tumor size and tumor density were both statistical significance ($p < 0.001$, Paired T test). Mean CT attenuation was decreased about 21.3 HU (36%). Comparing the two subgroups of lesions, intrahepatic and extrahepatic masses, we found statistical significance in the difference between the percentage of change in decreased tumor density ($p < 0.001$; Student's T test) and tumor size ($p = 0.028$; Student's T test) which more decrease in the extrahepatic lesions than intrahepatic lesions.

On subjective evaluation, solid nodules within the lesions were found in 18 lesions (27.7%): 12 extrahepatic and 6 intrahepatic lesions. After the treatment, 2 of the 6 lesions with internal solid nodules from intrahepatic lesions persisted on both pre- and post-treatment studies. However the solid nodules in

these two lesions became smaller in size during the follow-up study. All the solid nodules within the extrahepatic lesions disappeared after the treatment, reflecting to a good response [Fig.1]. Findings of tumor vessels were seen only in 7 extrahepatic lesions (10.8%) [Fig.2]. All of them disappeared on post-treatment study accompanied by decreased in both size and density of the lesions, indicating good responses. Furthermore, we also found new cystic-like lesions occurring in the liver of 2 patients which was not detected in the pretreatment scan [Fig. 3].

There was one lesion in the pretreatment study that showed homogeneously low density mass in the liver. This low density lesion increased in size with a newly developed intralesional solid nodule after treatment. However, this solid nodule became smaller on follow-up studies [Fig.4].

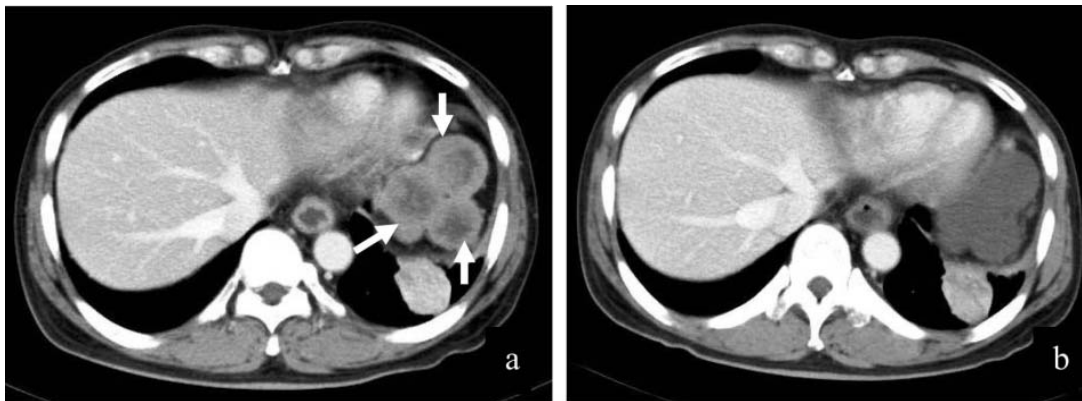


Figure 1. Contrast-enhanced CT scan of a 48-year-old male who had multiple intraabdominal metastatic GISTs, demonstrated three lesions with mural nodules (arrow) on pretreatment scan (a). Complete disappear of all solid nodules in these lesions was noted after 1 month of imatinib treatment (b).

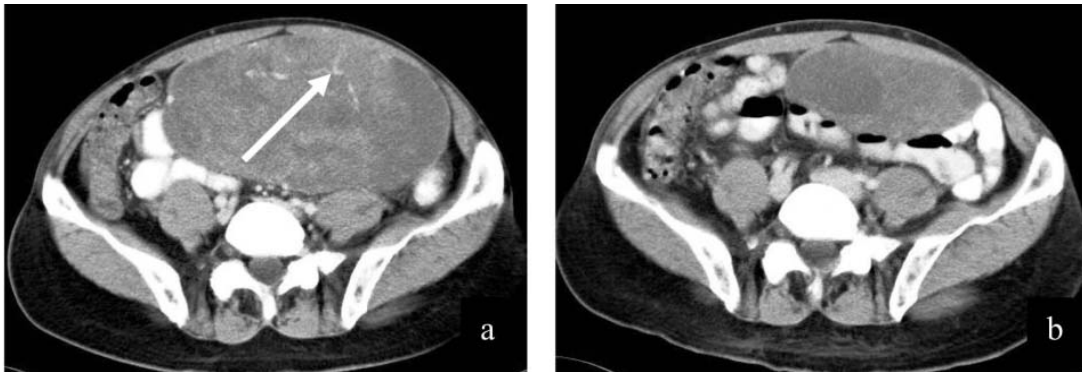


Figure 2. Contrast-enhanced CT scan of a 76-year-old male with large GIST in the mesentery. demonstrated evidence of tumor vessels (arrow) on pretreatment scan (a). After 2.5 months of treatment, tumor vessels were absent together with markedly decreased tumor size (b).

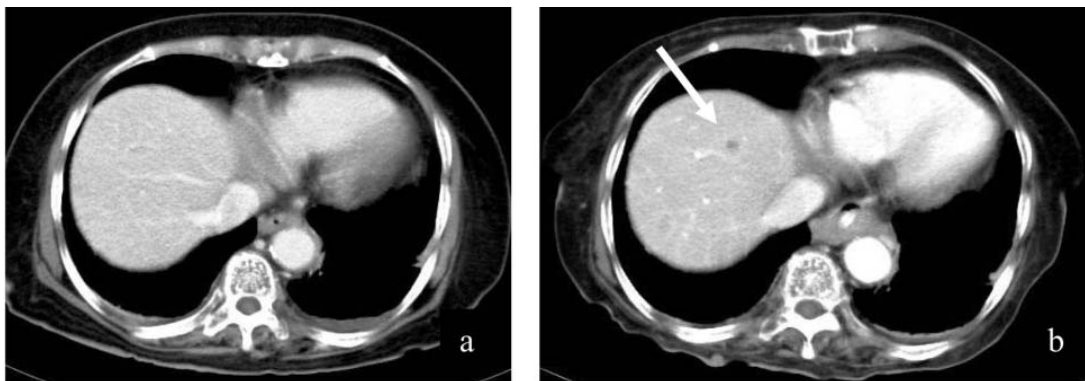


Figure 3. Contrast-enhanced CT scan of a 71-year-old male with advanced GIST, pretreatment scan showed no space-occupying lesion (a). Newly developed cystic lesion (arrow) in superomedial segment of left hepatic lobe was visualized in post treatment image (b).

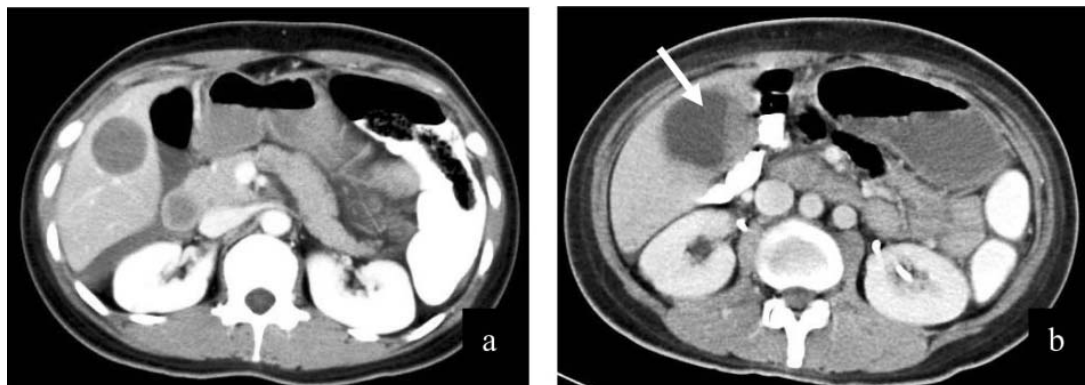


Figure 4. Contrast-enhanced CT scan of abdomen in a 30-year-old woman with metastatic GIST at liver and received imatinib for 1.5 months. Pretreatment image: (a) showed homogeneous low density mass in the liver. There was increase in size of the lesion with a newly developed intralesional solid nodule (arrow) (b).

Discussion

In our study, we found that tumor density decreases significantly, approximately 21.3 HU (36%). Decrease in tumor size and/or attenuation was found more in the extrahepatic lesions than in the intrahepatic lesions with statistically significance. Most lesions decreased in size or even disappeared in some cases, supporting the positive response based on the RECIST criteria. The increase in size of the lesions were associated with the overall decrease in tumor density and was found in 8 lesions (4 intrahepatic and 4 extrahepatic lesions) from 4 patients during 1 to 3.5 months of imatinib treatment. We think that increase in size of these lesions could be secondary to the development of myxoid degeneration of the tumor. ⁽¹⁶⁾

There was one lesion which increased in both size and density. However, this lesion showed slowly decrease in size without significant change of the density on multiple follow-up studies. Most lesions in this patient, except the aforementioned, decreased in both size and density. So, this lesion may be associated with slow tumor response rather than progression of the tumor.

Shankar et al. found that solid nodules within the lesions reflecting the viable tumors. Tumor response should demonstrate disappearance or decrease in size of these solid nodules. ⁽¹⁷⁾ Our study confirmed this result. However, we had a case of solid nodule development within one intrahepatic lesion that increased in size but much of it decreased in HU during the follow-up CT images [Fig.4]. After 2.5 years of observation, this solid nodule gradually decreased in size and the nodule finally disappeared. This is possibly a process of slow tumor response.

The appearance of tumor vessels is also one of the good indicator which is seen on CT images. ⁽¹⁴⁾ Tumor vessels were found less than we expected (10.8%), but when it presents, it can be easily to detected and used as an indicator of response on CT images. The disappearance of these vessels represents positive response to the treatment.

Chen et al. showed that post treatment of the hepatic metastases of GISTs appeared as well-defined near-cystic in attenuation with attenuation around 20 - 25 HU on post contrast enhanced CT after received 8 weeks of imatinib treatment. ⁽¹⁸⁾ This low attenuation allows discriminating the lesion from its surrounding normal liver parenchyma. Our study shows new developed cystic-like lesions in the liver in 2 of 14 patients. This new cystic lesion in the liver after treatment was discussed before in the study of *Ryu et al.* They concluded that a new cystic lesion in the liver after treatment was preexisting isoattenuated solid hepatic lesions which cannot be differentiated from the normal liver background in CT study. Hyaline degeneration from imatinib treatment changes the tumor from solid to cystic component resulting in more well discrimination of the lesion from the normal liver background. ⁽¹⁹⁾

According to the medical records, all patients had good clinical outcome on the follow-up day after receiving post-treatment CT scan. Nobody had to increase the dose of imatinib. The survival outcome is good because almost patients are still alive at the time of December 2007 (survival range 1.5 - 3.5 years), except for one patient who expired due to sepsis after 3 months of imatinib treatment.

The limitations of this study include small sample size, the duration of the first time follow up

which was up- to 6 months (typical duration of the first follow-up CT scan by NCCN guideline V3.2007 was within 3 months from the baseline).

Conclusion

Our study shares similar result with other studies in response of GISTs to imatinib treatment. If the lesion shows mismatch between change in size and density, size may not be reliable. Density, vascularity, present of solid nodule and cystic change may be complementary to each other in evaluation of response to treatment in addition to size only. Extrahepatic lesions display more explicit response in term of size and density when comparison to intrahepatic lesions.

Acknowledgement

We thank Mano Mettanando Laohavanich for his support in correcting grammar in this article.

References

1. Connolly EM, Gaffney E, Reynolds JV. Gastrointestinal stromal tumours. *Br J Surg* 2003 Oct; 90(10):1178-86
2. Kindblom LG, Remotti HE, Aldenborg F, Meis-Kindblom JM. Gastrointestinal pacemaker cell tumor (GIPACT): gastrointestinal stromal tumors show phenotypic characteristics of the interstitial cells of Cajal. *Am J Pathol* 1998 May;152(5):1259-69
3. Torihashi S, Horisawa M, Watanabe Y. c-Kit immunoreactive interstitial cells in the human gastrointestinal tract. *J Auton Nerv Syst* 1999 Jan 15; 75(1): 38-50
4. Heinrich MC, Corless CL, Duensing A, McGreevey L, Chen CJ, Joseph N, et al. PDGFRA activating mutations in gastrointestinal stromal tumors. *Science*. 2003 Jan 31;299 (5607): 708-10
5. Sarlomo-Rikala M, Kovatich AJ, Barusevicius A, Miettinen M. CD117: a sensitive marker for gastrointestinal stromal tumors that is more specific than CD34. *Mod Pathol* 1998 Aug; 11(8):728-34
6. Miettinen M, Lasota J. Gastrointestinal stromal tumors-definition, clinical, histological, immunohistochemical, and molecular genetic features and differential diagnosis. *Virchows Arch* 2001 Jan;438(1):1-12
7. Joensuu H, Fletcher C, Dimitrijevic S, Silberman S, Roberts P, Demetri G. Management of malignant gastrointestinal stromal tumours. *Lancet Oncol*. 2002 Nov; 3(11): 655-64
8. Dagher R, Cohen M, Williams G, Rothmann M, Gobburu J, Robbie G, et al. Approval summary: imatinib mesylate in the treatment of metastatic and/or unresectable malignant gastrointestinal stromal tumors. *Clin Cancer Res* 2002 Oct; 8(10):3034-8
9. Demetri GD, von Mehren M, Blanke CD, Van den Abbeele AD, Eisenberg B, Roberts PJ, et al. Efficacy and safety of imatinib mesylate in advanced gastrointestinal stromal tumors. *N Engl J Med* 2002 Aug 15;347(7):472-80
10. Ghanem N, Althoefer C, Furtwangler A, Winterer J, Schafer O, Springer O, et al. Computed tomography in gastrointestinal stromal tumors. *Eur Radiol* 2003 Jul;13(7):1669-78
11. Lau S, Tam KF, Kam CK, Lui CY, Siu CW, Lam HS, et al. Imaging of gastrointestinal stromal

- tumour (GIST). *Clin Radiol* 2004 Jun;59(6):487-98
12. Lee CM, Chen HC, Leung TK, Chen YY. Gastrointestinal stromal tumor: Computed tomographic features. *World J Gastroenterol* 2004 Aug 15;10(16):2417-8
13. Sandrasegaran K, Rajesh A, Rushing DA, Rydberg J, Akisik FM, Henley JD. Gastrointestinal stromal tumors: CT and MRI findings. *Eur Radiol* 2005 Jul;15(7):1407-14
14. Choi H, Charnsangavej C, de Castro Faria S, Tamm EP, Benjamin RS, Johnson MM, et al. CT evaluation of the response of gastrointestinal stromal tumors after imatinib mesylate treatment: a quantitative analysis correlated with FDG PET findings. *AJR Am J Roentgenol* 2004 Dec;183(6):1619-28
15. Warakaulle DR, Gleeson F. MDCT appearance of gastrointestinal stromal tumors after therapy with imatinib mesylate. *AJR Am J Roentgenol* 2006 Feb;186(2):510-5
16. Hong X, Choi H, Loyer EM, Benjamin RS, Trent JC, Charnsangavej C. Gastrointestinal stromal tumor: role of CT in diagnosis and in response evaluation and surveillance after treatment with imatinib. *Radiographics* 2006 Mar-Apr;26(2):481-95
17. Shankar S, vanSonnenberg E, Desai J, Dipiro PJ, Van Den Abbeele A, Demetri GD. Gastrointestinal stromal tumor: new nodule-within-a-mass pattern of recurrence after partial response to imatinib mesylate. *Radiology* 2005 Jun;235(3):892-8
18. Chen MY, Bechtold RE, Savage PD. Cystic changes in hepatic metastases from gastrointestinal stromal tumors (GISTs) treated with Gleevec (imatinib mesylate). *AJR Am J Roentgenol* 2002 Oct;179(4):1059-62
19. Ryu MH, Lee JL, Chang HM, Kim TW, Kang HJ, Sohn HJ, et al. Patterns of progression in gastrointestinal stromal tumor treated with imatinib mesylate. *Jpn J Clin Oncol* 2006 Jan;36(1):17-24