

10-1-2022

## The coincidence of Abernethy malformation and blue rubber bleb nevus syndrome: A case report

Thipsumon Tangsiwong

Siriwan Wananukul

Panruethai Trinavarat

Follow this and additional works at: <https://digital.car.chula.ac.th/clmjjournal>



Part of the [Medicine and Health Sciences Commons](#)

---

### Recommended Citation

Tangsiwong, Thipsumon; Wananukul, Siriwan; and Trinavarat, Panruethai (2022) "The coincidence of Abernethy malformation and blue rubber bleb nevus syndrome: A case report," *Chulalongkorn Medical Journal*: Vol. 66: Iss. 4, Article 11.

Available at: <https://digital.car.chula.ac.th/clmjjournal/vol66/iss4/11>

This Case Report is brought to you for free and open access by the Chulalongkorn Journal Online (CUJO) at Chula Digital Collections. It has been accepted for inclusion in Chulalongkorn Medical Journal by an authorized editor of Chula Digital Collections. For more information, please contact [ChulaDC@car.chula.ac.th](mailto:ChulaDC@car.chula.ac.th).

## Case report

# The coincidence of Abernethy malformation and blue rubber bleb nevus syndrome: A case report

Thipsumon Tangsiwong<sup>a</sup>, Siriwan Wananukul<sup>b</sup>, Panruethai Trinavarat<sup>c,\*</sup>

<sup>a</sup>Department of Radiology, Buddhachinaraj Phitsanulok Hospital, Phitsanulok 65000, Thailand

<sup>b</sup>Department of Pediatrics, Faculty of Medicine, Chulalongkorn University, Bangkok, Thailand

<sup>c</sup>Department of Radiology, Faculty of Medicine, Chulalongkorn University and King Chulalongkorn Memorial Hospital, Bangkok, Thailand

---

Abernethy malformation was demonstrated in a 10-year-old boy, whose underlying disease of blue rubber bleb nevus syndrome (BRBNS) was achieved first-time-right diagnosis by cutaneous stigmata, presenting with persistent gross hematuria and hemodynamic instability secondary to vesical venous malformation. Abdominal computed tomography (CT) imaging was obtained to explore identifiable and treatable causes of the active bleeding, revealing Abernethy malformation and unusual visceral slow-flow vascular malformations including venous varicosities and splenic lymphangiomas. This is a first case report of the coincidence of Abernethy malformation and BRBNS. Imaging played an important role in detection of clinically occult congenital portal venous anomalies and visceral vascular malformations.

**Keywords:** Abernethy malformation, blue rubber bleb nevus syndrome, congenital absence of portal vein, vascular malformations.

---

Type I Abernethy malformation or congenital absence of the portal vein with total splanchnic venous returns to systemic circulation bypassing the liver is extremely rare, and often associated with other congenital anomalies such as cardiac defects, biliary atresia, renal malformations, and skeletal abnormalities.<sup>(1-7)</sup> Blue rubber bleb nevus syndrome (BRBNS) is another rare entity and mostly occurs sporadically in children. It is characterized by multiple venous malformations commonly affecting skin and gastrointestinal (GI) tract.<sup>(8-11)</sup> In English-language literature, about 200 reported cases published until 2017 have revealed that BRBNS has a diversity of multi-organ involvements in various patterns of slow-flow vascular malformations<sup>(8-9)</sup>; however, anomalies of the portal vein have never been described. Herein this is a first case of Abernethy malformation accompanied by BRBNS.

The informed written consent was obtained from both patient and the legal guardian.

## Case presentation

A 10-year-old boy was transferred to admit in King Chulalongkorn Memorial Hospital, presenting with persistent gross hematuria for 10 days. Before the referral, he had received fluid resuscitation and blood transfusion because of severe anemia and occasional hypovolemic shock. The child denied any history of preceding trauma, easy bruising, foul smelling urine, and recurrent urinary tract infection. He had past medical history of congenital vascular malformations at his extremities and underwent repeated laser treatments but lost to follow-up. At physical examination he presented with multiple bluish nodules at dorsum of all toes, swelling of the dorsum of both feet, and hyperkeratotic purple and black papules at bilateral fourth toes (Figure 1A - B). A patchy area of cutaneous vascular malformations with multiple small thromboses was seen on the right thigh (Figure 1C). His vital signs were stable with a pulse rate of 76 /min and blood pressure of 114/85 mmHg. Neither abdominal mass nor organomegaly was palpable. Neurological examination was unremarkable. On laboratory test, a hemoglobin level

---

\*Correspondence to: Panruethai Trinavarat, Department of Radiology, Faculty of Medicine, Chulalongkorn University and King Chulalongkorn Memorial Hospital, Bangkok 10330, Thailand.

E-mail: pantrinavarat@hotmail.com, panruethai.t@chula.ac.th

Received: November 27, 2021

Revised: March 2, 2022

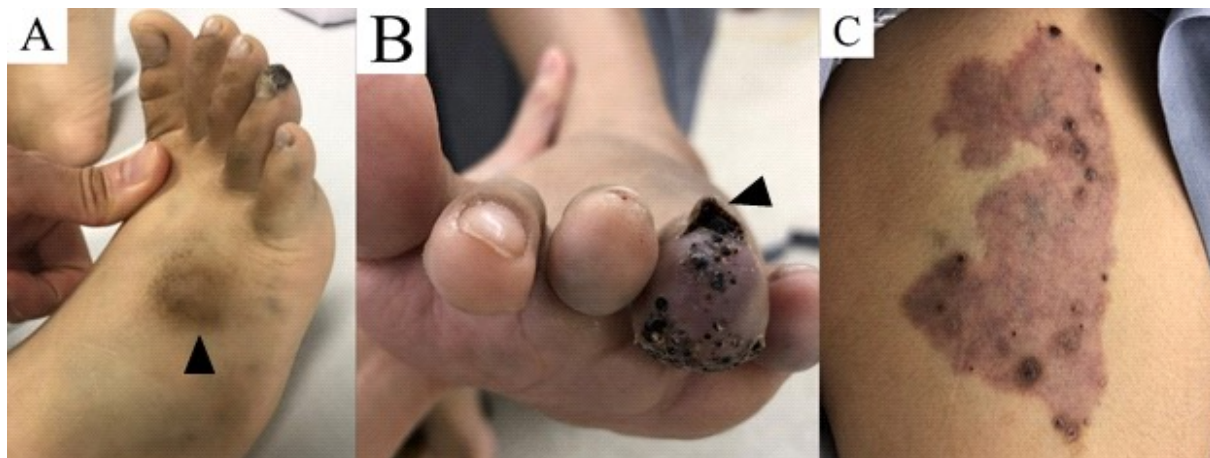
Accepted: April 12, 2022

was 10.7 g/dL with a hematocrit of 32.0%. Urinalysis showed red-colored urine, numerous RBC, 0-1 WBC per high power field, a pH of 8.5, and positive blood 3+. The diagnosis of blue rubber bleb nevus syndrome was first made at this admission by a pediatric dermatologist, with the characteristics of cutaneous stigmata.

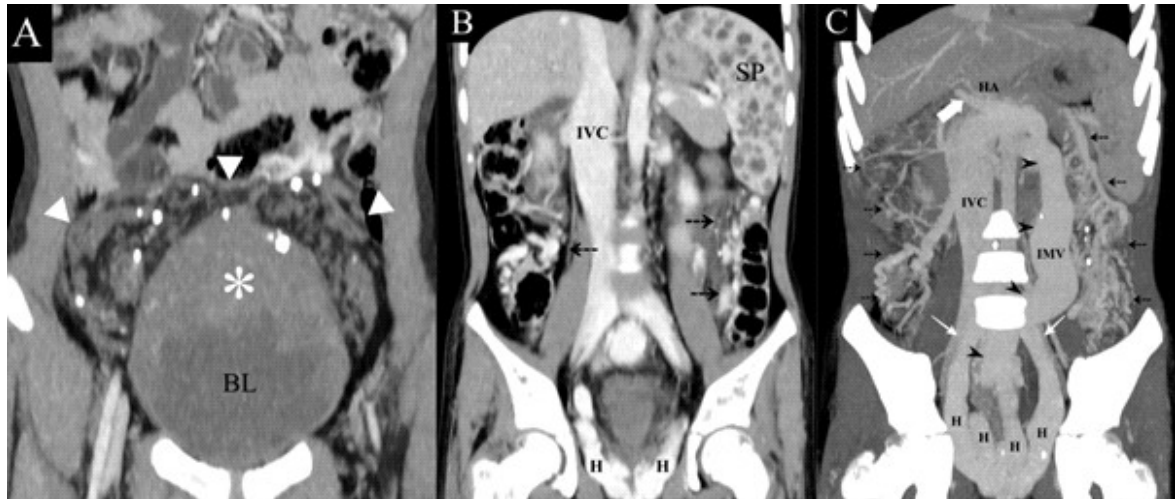
Abdominopelvic computed tomography (CT) was then obtained in pre-contrasted, late arterial, and portal venous phases. The study disclosed a large, lobulated, unevenly circumferential, faintly contrast-enhanced vesical mass particular at superoposterior wall with a few intralesional round calcifications (Figure 2A), compatible with venous malformation with phleboliths. Other sites of slow-flow vascular malformations were detected at the greater omentum seen as multiple small, faintly contrast-enhanced lesions with some millimetric-sized phleboliths (Figure 2A), at the colon and its mesentery shown as extensive venous varicosities and malformations with several punctate calcifications without detectable arterial feeder (Figure 2B - C), and at the spleen consisting of multiple scattered, sub-centimeter-sized, hypodense lesions (Figure 2B). Intrahepatic portal vein could not be

identified. The splenoportal confluence was seen to enter the systemic circulation via the markedly dilated inferior mesenteric vein (about 2 cm diameter) and bilateral gigantic hemorrhoidal veins into internal iliac veins (Figure 2C). The liver mainly received a single blood supply from the enlarged hepatic artery. Inferior vena cava (IVC) and hepatic veins were patent. There was neither portoportal collaterals nor ascites. The mentioned extrahepatic portosystemic shunt was consistent with type I Abernethy malformation.

The cystoscopy demonstrated venous malformations at the urinary bladder. The laparoscopy confirmed the absence of the portal vein, the ectasia of inferior mesenteric vein, multiple extensive anomalous varices and venous malformations at the colon, mesentery, and urinary bladder, and visible splenic lymphangiomas. Sirolimus, an antiangiogenic drug, was initially prescribed following the diagnosis, but the hematuria did not improve. Two weeks later, he underwent re-cystoscopy with fulguration of the vesical venous malformations, yielding a satisfied result of bleeding control. The boy was discharged in a well condition after hospitalization over a month.



**Figure 1.** Focused pictures at right foot (A), left foot (B) and right thigh (C). There were multiple bluish nodules at dorsum of right toes, and hyperkeratotic purple and black papules at both fourth toes (▲) (A - B). Cutaneous vascular malformations with multiple small thromboses was seen on the right thigh (C).



**Figure 2.** Coronal images of the venous-phase abdominopelvic computed tomography with maximum intensity projection using a slab thickness of 4 mm (A), average intensity projection using a slab thickness of 4 mm (B) and maximum intensity projection using a slab thickness of 64 mm (C). There was a faint contrast-enhanced vesical mass (white asterisk) with intralesional round calcifications, along with multiple soft tissue nodules with round calcifications at omentum (white arrow heads) (A). Venous malformations and varicosities (black dash arrows) with scattered calcifications along the colon and its mesentery were depicted (B - C). There were multiple small hypoattenuating lesions throughout the spleen (B). A short extrahepatic portal remnant (thick white arrow) was seen with the splenoportal confluence draining through the ectatic inferior mesenteric vein (black arrow heads) and hemorrhoidal veins into bilateral internal iliac veins (thin white arrows). (Abbreviations: BL = urinary bladder, H = hemorrhoidal vein, HA = hepatic artery, IMV = inferior mesenteric vein, IVC = inferior vena cava, SP = spleen).

## Discussion

Abernethy malformation or congenital extrahepatic portosystemic shunt (CEPS) is an extremely rare condition whereby the splanchnic circulation directly empties into systemic venous system bypassing liver through a complete or partial shunt which defines as type I or II CEPS, respectively. (1-2) From its initial description in 1793 until 2019, only about 90 cases have been reported worldwide with a likelihood of underestimation. (3) Regarding a genetic predisposition, it is unknown due to lack of sufficient information from the literature; however, Goto K, *et al.* (12) have reported one case with familial occurrence of congenital portosystemic shunt. Most cases of the CEPS are incidentally detected and easily diagnosed by imaging; however, the malformation itself has a risk of life-threatening complications such as hepatic encephalopathy, hepatopulmonary syndrome and malignant transformation of hepatic lesions. Due to its having typically no secondary manifestation of portal hypertension such as ascites, cavernous transformation, or splenomegaly; the CEPS is capable of distinguishing disease entity from the acquired. (1,4-6) Abnormalities of the venous pathways and vascular malformations reported in patients

with the CEPS are double superior or inferior vena cava, left sided IVC, interrupted IVC with azygos and hemiazygos continuation, and cutaneous hemangiomas. (6-7)

BRBNS, formerly known as Bean syndrome, is the disease of venous malformations mainly involving skin and GI tract and less commonly involving other visceral organs. It is a rare disease of unknown etiology with an incidence of 1:14,000 births. (8-9) BRBNS occurs sporadically and is caused by somatic activating pathogenic *TEK* gene variants which can be detected by the highly sensitive molecular techniques. (13) The diagnosis is generally made by visual inspection of the characteristic cutaneous and/or GI venous malformations. (8-11) The most common complication of BRBNS is bleeding from the GI lesions, resulting in secondary iron deficiency anemia. Besides the venous malformations, lymphatic malformations in the pancreas, skin, mucosa, GI tract and uterus as well as other vascular lesions included dermal capillary hemangiomas, arteriovenous malformation, cerebral telangiectasia, aneurysmal dilatation of vein of Galen and papillary endothelial hyperplasia within hemangiomatous vessels have rarely been documented in the BRBNS patients. (14)

At between 4 and 10 weeks of embryonic life, the vascular architecture of the liver is developed via a complex sequence of vascular growth, anastomosis, and asymmetric degeneration of three primitive venous structures including vitelline, umbilical, and cardinal veins. <sup>(12, 15)</sup> The portal vein mainly derives from the paired vitelline veins passing through the septum transversum to sinus venosus. <sup>(15)</sup> The selective degeneration of the vitelline veins and persistence of their dorsal anastomosis become extrahepatic portal segment. <sup>(12, 15-16)</sup> Meanwhile the complex intrahepatic venous anastomoses evolve into the portal branches by *de novo* development of left-to-right shunts from left umbilical vein through right hepatocardiac channel and right vitelline vein, respectively, proposed as the “hemodynamic theory” [Lassau & Bastian, 1983]. <sup>(16)</sup> Therefore, the extensive involution of these primitive veins and/or interference of hemodynamic flow during hepatic vascular development can provoke portal and related cardiovascular anomalies. <sup>(12, 15 - 16)</sup> In our opinion, the extensive mesenteric venous malformations and varices uniquely occurred in our case of BRBNS might stimulate a giant inferior mesenteric-caval portosystemic shunt that could influence flow impairment of the fetal liver, subsequently interfere the intrahepatic formation and extrahepatic regression of the portal vein, and eventually progress into type I CEPS. However, we supposed that there was no prior reported case of this coincidence because the most common GI involvement of the published BRBNS is multiple small mucosal venous malformations which could not initiate a significant shunting to affect the portal development.

From the literature review, we came across the reported case of CEPS with cutaneous hemangiomatosis in 2003 by Pohl A, *et al.* <sup>(7)</sup>; we were curious that the cutaneous lesions were potential characteristics of BRBNS. However, this is the first official report of the coexistence of Abernethy malformation and BRBNS, incidentally detected by CT imaging and confirmed by laparoscopy. Urinary tract bleeding as his presenting symptom was unusual in BRBNS because the urinary bladder is an uncommon site of abdominal visceral involvements of the vascular malformations. Likewise, multiple venous varicosities along the colon and its mesentery were identified as atypical imaging appearances mentioned in the previous literature. <sup>(8 - 11)</sup> To our knowledge, the splenic lymphangiomatosis in BRBNS was first described in this study.

## Conclusion

This is a first case report regarding the coincidence of two rare disease entities of vascular malformations. Imaging played an important role for detection of Abernethy malformation, and inspection of slow-flow visceral vascular malformations relating to BRBNS.

## Conflict of interest

The authors declare that there is no conflict of interest.

## References

1. Alonso-Gamarra E, Parrón M, Pérez A, Prieto C, Hierro L, López-Santamaría M. Clinical and radiologic manifestations of congenital extrahepatic portosystemic shunts: a comprehensive review. *Radiographics* 2011;31:707-22.
2. Azad S, Arya A, Sitaraman R, Garg A. Abernethy malformation: Our experience from a tertiary cardiac care center and review of literature. *Ann Pediatr Cardiol* 2019;12:240-7.
3. Kim ES, Lee KW, Choe YH. The characteristics and outcomes of Abernethy syndrome in Korean children: a single center study. *Pediatr Gastroenterol Hepatol Nutr* 2019;22:80-5.
4. Niwa T, Aida N, Tachibana K, Shinkai M, Ohhama Y, Fujita K, et al. Congenital absence of the portal vein: clinical and radiologic findings. *J Comput Assist Tomogr* 2002;26:681-6.
5. Murray CP, Yoo SJ, Babyn PS. Congenital extrahepatic portosystemic shunts. *Pediatr Radiol* 2003;33:614-20.
6. Hu GH, Shen LG, Yang J, Mei JH, Zhu YF. Insight into congenital absence of the portal vein: is it rare? *World J Gastroenterol* 2008;14:5969-79.
7. Pohl A, Jung A, Vielhaber H, Pfluger T, Schramm T, Lang T, et al. Congenital atresia of the portal vein and extrahepatic portocaval shunt associated with benign neonatal hemangiomatosis, congenital adrenal hyperplasia, and atrial septal defect. *J Pediatr Surg* 2003;38:633-4.
8. Jin XL, Wang ZH, Xiao XB, Huang LS, Zhao XY. Blue rubber bleb nevus syndrome: a case report and literature review. *World J Gastroenterol* 2014;20:17254-9.
9. Chen W, Chen H, Shan G, Yang M, Hu F, Li Q, et al. Blue rubber bleb nevus syndrome: our experience and new endoscopic management. *Medicine (Baltimore)* 2017;96:e7792.
10. Senturk S, Bilici A, Miroglu TC, Bilek SU. Blue rubber bleb nevus syndrome: imaging of small bowel lesions

- with peroral CT enterography. *Abdom Imaging* 2011; 36:520-3.
11. Mechri M, Soyer P, Boudiaf M, Duchat F, Hamzi L, Rymer R. Small bowel involvement in blue rubber bleb nevus syndrome: MR imaging features. *Abdom Imaging* 2009;34:448-51.
  12. Goto K, Tsuji K, Honda Y, Takaki S, Mori N, Kakizawa H, et al. Familial Occurrence of a congenital portosystemic shunt of the portal vein. *Hiroshima Journal of Medical Sciences* 2017;66:85-90.
  13. Boon LM, Vikkula M. Multiple Cutaneous and Mucosal Venous Malformations. 2008 Sep 18 [Updated 2018 May 17]. In: Adam MP, Ardinger HH, Pagon RA, Wallace SE, Bean LJH, Gripp KW, et al., editors. *GeneReviews®* [Internet]. Seattle (WA): University of Washington, Seattle; 1993-2022. Available from: <https://www.ncbi.nlm.nih.gov/books/NBK1967/>.
  14. Patel RC, Zynger DL, Laskin WB. Blue rubber bleb nevus syndrome: novel lymphangiomatosis-like growth pattern within the uterus and immunohistochemical analysis. *Hum Pathol* 2009;40:413-7.
  15. Qin Y, Wen H, Liang M, Luo D, Zeng Q, Liao Y, et al. A new classification of congenital abnormalities of UPVS: sonographic appearances, screening strategy and clinical significance. *Insights Imaging* 2021;12: 125.
  16. Hikspoors JPJM, Peeters MMJP, Mekonen HK, Kruepunga N, Mommen GMC, Cornillie P, et al. The fate of the vitelline and umbilical veins during the development of the human liver. *J Anat* 2017;231: 718-35.