

4-1-2022

Age estimation using ankle radiographic examination in a contemporary Thai population

Aekawit Triamkitsawat

Dittapong Songsaeng

Vijarn Vachirawongsakorn

Follow this and additional works at: <https://digital.car.chula.ac.th/clmjjournal>



Part of the [Medicine and Health Sciences Commons](#)

Recommended Citation

Triamkitsawat, Aekawit; Songsaeng, Dittapong; and Vachirawongsakorn, Vijarn (2022) "Age estimation using ankle radiographic examination in a contemporary Thai population," *Chulalongkorn Medical Journal*. Vol. 66: Iss. 2, Article 13.

DOI: 10.14456/clmj.2022.28

Available at: <https://digital.car.chula.ac.th/clmjjournal/vol66/iss2/13>

This Other is brought to you for free and open access by the Chulalongkorn Journal Online (CUJO) at Chula Digital Collections. It has been accepted for inclusion in Chulalongkorn Medical Journal by an authorized editor of Chula Digital Collections. For more information, please contact ChulaDC@car.chula.ac.th.

Original article

Age estimation using ankle radiographic examination in a contemporary Thai population

Aekawit Triamkitsawat^a, Dittapong Songsaeng^b, Vijarn Vachirawongsakorn^{a,*}

^a Department of Forensic Medicine, Faculty of Medicine, Siriraj Hospital, Mahidol University, Bangkok, Thailand

^b Department of Radiology, Faculty of Medicine, Siriraj Hospital, Mahidol University, Bangkok, Thailand

Background: Radiologic evaluation of skeletal maturity is one of the three practical methods to assess age in a living person.

Objective: To assess the average age from the epiphyseal fusion of the distal tibia and fibula in Thai children and young adults.

Methods: Ankle radiographs of 217 Thai patients aged 0 to 22 years who came to Siriraj Hospital from 1 January 2000 to 31 March 2020 were recruited for the study. The development of epiphyseal plate in the distal tibia and fibula was analyzed as a grading system. A composite score was also calculated. The relationship between age, the fusion stage and the composite score was explored.

Results: The results showed that the complete fusion of the distal tibia and fibula in females and males was found as early as 12 and 13 years, respectively. All females exhibited complete fusion by 15 years old in both epiphyses. All males showed complete fusion of distal tibia and fibula by 15 and 16 years, respectively. The fusion stage tended to rise with the increasing age. There was a significant difference between male and female data. The reliability test showed excellent agreement.

Conclusion: Ankle radiographs can essentially be used to assess distal tibia and fibula ossification. The reference values given in this study can be used in age estimation for the Thai population.

Keywords: Age estimation, epiphysis, tibia, fibula, radiograph.

Age assessment is an essential factor in identifying an individual in both living and deceased person. There are legal requirements for age estimating in the living, especially in those who do not have a documented identity. For example, in the Thai labor law, an employer is prohibited from employing a child under 15 years as an employee. The law also provides regulations for the employment of children under 18 years of age. For another example in Thailand, sex-related crime and punishment is entirely based on criminal liability, which depends on the age of the victims. Therefore, a forensic expert needs to have a precise age assessment method in young adults with a probability bordering on certainty.

Practically, a physician can perform age assessment in a living adolescent and young adult in three ways⁽¹⁾: 1) Physical examination by examining the growth and development such as height and the sexual characteristics; 2) Radiographic examination by evaluation of skeletal maturity; and, 3) Dental examination by evaluation of dental formation and eruption. Compared to the other methods, the radiographic analysis provides a quick, accurate, and uncomplicated method of evaluating the living age.⁽¹⁾

At present, various studies are learning more about age estimation of epiphyseal plate formation from different parts of the body, such as the hand-wrist⁽²⁻⁴⁾, medial clavicle⁽⁵⁻⁸⁾, cervical vertebra⁽⁹⁾, mandibular ramus⁽¹⁰⁾, anterior iliac crest⁽¹¹⁻¹²⁾, and the femur.⁽¹³⁾ Also, many studies focus on the skeletal development of the ankle based on radiographic and magnetic resonance imaging.⁽¹⁴⁻¹⁸⁾ However, the studies vary significantly depending on numerous factors such as ethnicity, gender, number of subjects, age-range, and methodology.⁽⁴⁾

*Correspondence to: Vijarn Vachirawongsakorn, Department of Forensic Medicine, Faculty of Medicine, Siriraj Hospital, Mahidol University, Bangkok 10700, Thailand.

E-mail: vijarn.vac@mahidol.ac.th

Received: February 24, 2021

Revised: March 29, 2021

Accepted: April 20, 2021

There are previous studies of the epiphyseal plate evaluation of wrists and knees in Thailand by a radiological examination⁽¹⁹⁻²⁰⁾, but there have never been any studies involving the ankle. Therefore, the purpose of this study is to assess the average age of the epiphyseal plate closure of the distal tibia and fibula from the ankle radiograph in the Thai population among age group from 0 to 22 years.

Materials and methods

This retrospective study has been approved by the ethics committee of the Faculty of Medicine, Siriraj Hospital, Mahidol University (Protocol no.314/2563 (IRB2) on April 15, 2020). The digital standard anteroposterior and lateral view ankle radiographs of Thai patients, ranging between 0 - 22 years, who came to Siriraj Hospital from 1 January 2000 to 31 March 2020, were recruited in this study. The person with the following findings needs to be excluded from this study:

1. Old or new fractures involving the growth plate of the distal tibia or fibula;
2. Medical instruments involving the growth plate of the distal tibia or fibula, such as orthopedic implants, as well as those hinder visibilities of this area, such as casts and slabs;

3. Body height or weight that is less than the 3rd percentile, as well as the medical History of abnormal skeletal development; and,
4. Radiographic evidence of an episodic growth arrest such as Harris lines.

Before collecting information, the first author (AT) and the co-author (VV) had to practice the ankle radiographic interpretation with an expert radiologist (DS). After then, the first author included patients without exclusion criteria. The basic information of all patients such as gender, height and weight, birth date, study date and time, underlying disease, and medical diagnosis, were explored and recorded. It can be assumed that the sample reflects the average composition of the Thai population.

By using SYNAPSE5 program, careful consideration of the anteroposterior and lateral views of the distal tibia and fibula radiographs were performed. During analysis, the researchers did not know the age of the patients. A grading system adapted from Crowder C, *et al.*⁽¹⁵⁾ and Hoerr NL, *et al.*⁽²¹⁾ was used to determine skeletal maturity. The degree of the development of the epiphyseal plate of the distal tibia was separately evaluated as follows (Figure 1):

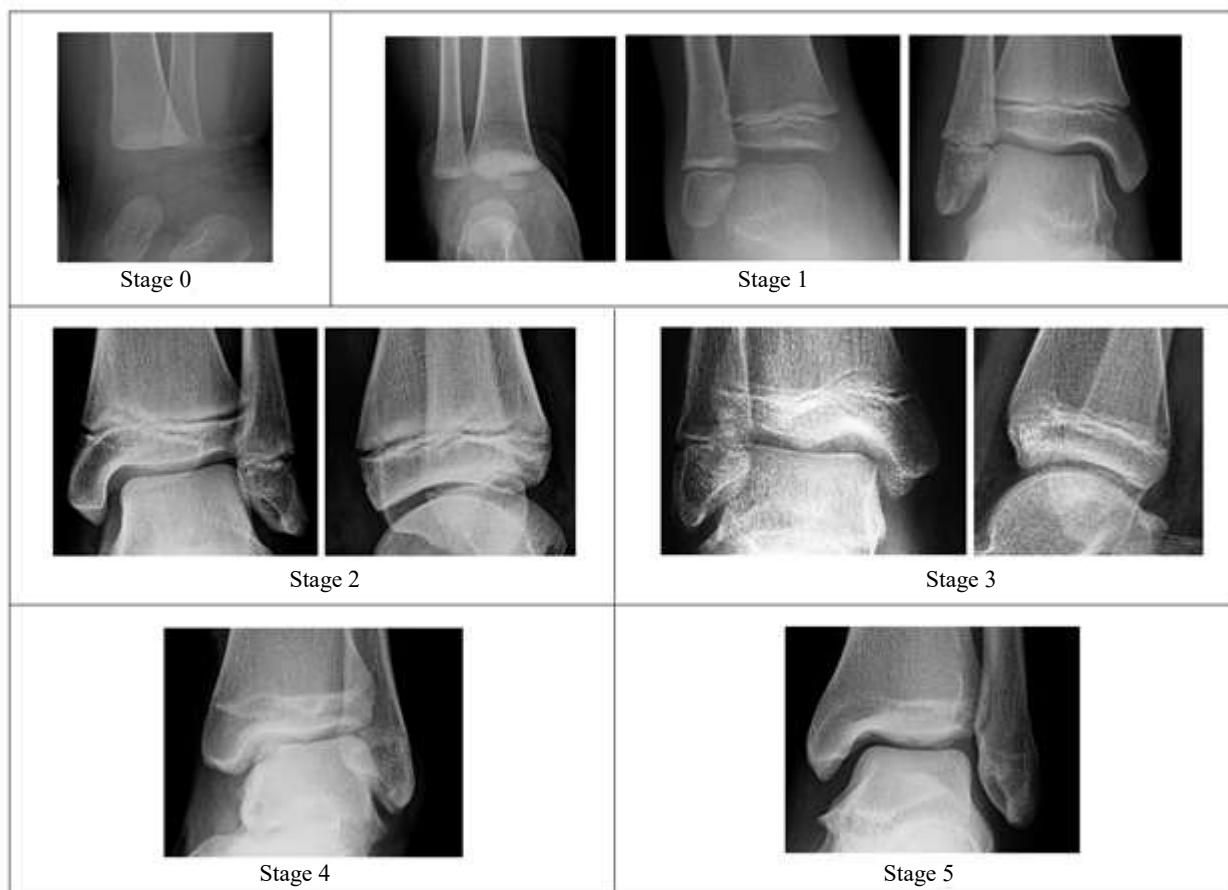


Figure 1. Ossification stages of the distal tibia.

- Stage 0: No ossification center of the epiphysis.
- Stage 1: Separated ossified epiphysis: At the initial phase of this stage, the epiphysis is a rounded-shaped ossification center, while the distal end of the metaphysis remains flattened. During the second phase of this stage, the epiphysis turns to an oval shape, but its articular facet does not conform to the metaphysis. While in the late phase of this stage, the epiphysis becomes cup-shaped, and its articular facet begins to conform to the metaphysis. Furthermore, the medial malleolus formation begins.
- Stage 2: The anteroposterior view shows the partial fusion of the growth plate less than 50.0%. However, the lateral view shows no fusion.
- Stage 3: The anteroposterior view shows the partial fusion of the growth plate less than 50.0%, and the lateral view shows a partial fusion of the growth plate.
- Stage 4: There is a partial fusion of growth plate more than 50.0% in the anteroposterior view. This stage may be confused with stage 5, but it can be separated by the discontinuation of the vertical trabecular lines connecting the epiphysis and metaphysis.
- Stage 5: Complete fusion of the epiphyseal plate.

The developmental status of the distal fibular epiphysis was also evaluated. Different four stages of ossification were determined as follows (Figure 2):

- Stage 0: No ossification center of the epiphysis.
- Stage 1: Ossified epiphysis, non-fused growth plate.
- Stage 2: Partial fusion of growth plate: The vertical trabecular lines connected between the epiphysis and metaphysis are discontinuous.
- Stage 3: Complete fusion of the epiphyseal plate.

After assessing the closure of the distal tibia and distal fibula's growth plate, a composite scoring system adapted from Ruensuk S, *et al.*⁽¹⁹⁾ was calculated. The stages were considered as ordinal number, and therefore they represent sequentially ordered categories (e.g., stage 0 = 0, stage 1 = 1, stage 2 = 2, stage 3 = 3, stage 4 = 4, stage 5 = 5). By combining this set of points of distal tibial and fibular epiphyses, a composite score was calculated.

Statistical analysis

The complete data collections were analyzed using PASW version 18.0. The descriptive analyses, including frequency and percentage, were performed. Sexual differences were investigated using two-way analysis of variance (ANOVA). Comparison of left and right sides was conducted using paired *t* - test. The differences of each developmental stage between both sexes were analyzed using Chi-square test for linear-by-linear association. Considering intra-observer reliability, 22 random radiographs were re-evaluated after 1 week by the same researcher. In addition, inter-observer reliability between the principal researcher and co-researcher was assessed. Weighted kappa (Kw) using quadratic weight was applied to evaluate intra- and inter-observer agreement. *P* - value < 0.05 was considered as statistically significant.

Results

In this study, 181 patients were recruited, consisting of 107 males and 74 females. In 21 out of 181 cases (11.6%), two or more visits to the hospital with repeated radiological examination were found. As a result, a total of 217 ankle radiographs were eligible for the study. As shown in Table 1, the distribution of the subjects by age and sex is present.

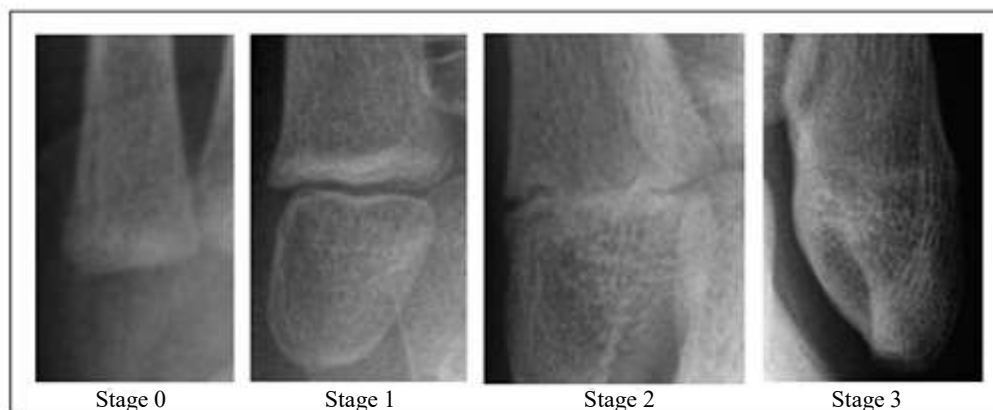

Figure 2. Ossification stages of the distal fibula.

Table 1. The distribution of the radiographic samples by gender and age (n = 217).

Age (years)	Number (%)		Total (%)
	Female	Male	
≤ 11.99	44 (45.4)	45 (37.5)	89 (41.0)
12 - 12.99	5 (5.2)	5 (4.2)	10 (4.6)
13 - 13.99	4 (4.1)	5 (4.2)	9 (4.1)
14 - 14.99	4 (4.1)	4 (3.3)	8 (3.7)
15 - 15.99	4 (4.1)	6 (5.0)	10 (4.6)
16 - 16.99	9 (9.3)	10 (8.3)	19 (8.8)
≥ 17	27 (27.8)	45 (37.5)	72 (33.2)
Total	97	120	217

There were 43 subjects, including 16 males and 27 females, with both sides of ankle radiographs in the same visit. There was no statistically significant difference in maturation of data from left and right sides of tibia ($P = 0.9$) and fibula ($P = 1$). Therefore, the right ankle radiographs were selected to be representative of the population studied.

Tables 2 and 3 present the developmental status of epiphyseal union for each ossification stage divided by sex. In the female group, the complete union of the distal tibia (stage 5) and fibula (stage 3) can be found as early as the age of 12 years, and those findings

can be found in all the female subjects in the age group 15.0 – 16.0 years. The male subjects, however, have a different developmental timetable comparing with the female group. The distal epiphyses of the tibia and fibula of male adolescents have a slower rate of maturation. The complete union of distal tibial and fibular epiphysis was first achieved at the age of 13 years, and those findings can be found in all the male subjects in the age group 15 and 16 years, respectively. In both sexes, stage 1 was first noted during the first year of age. Developmental differences were also observed during early stage of distal tibial

Table 2. Comparison of staging of the distal tibia by age and gender.

Gender	Age (years)	n	Staging of tibia					
			0	1	2	3	4	5
Female	0-0.99	2	1 (50.0)	1 (50.0)	-	-	-	-
	1-9.99	33	-	33 (100.0)	-	-	-	-
	10-10.99	6	-	5 (83.3)	1 (16.7)	-	-	-
	11-11.99	3	-	2 (66.7)	-	1 (33.3)	-	-
	12-12.99	5	-	1 (20.0)	1 (20.0)	1 (20.0)	-	2 (40.0)
	13-13.99	4	-	-	-	-	2 (50.0)	2 (50.0)
	14-14.99	4	-	-	-	-	1 (25.0)	3 (75.0)
	15-15.99	4	-	-	-	-	-	4 (100.0)
	16-16.99	9	-	-	-	-	-	9 (100.0)
	≥ 17	27	-	-	-	-	-	27 (100.0)
Male	0-0.99	6	2 (33.3)	4 (66.7)	-	-	-	-
	1-8.99	24	-	24 (100.0)	-	-	-	-
	9-9.99	6	-	5 (83.3)	1 (16.7)	-	-	-
	10-10.99	5	-	5 (100.0)	-	-	-	-
	11-11.99	4	-	3 (75.0)	1 (25.0)	-	-	-
	12-12.99	5	-	5 (100.0)	-	-	-	-
	13-13.99	5	-	2 (40.0)	1 (20.0)	1 (20.0)	-	1 (20.0)
	14-14.99	4	-	2 (50.0)	1 (25.0)	-	1 (25.0)	-
	15-15.99	6	-	-	-	-	-	6 (100.0)
	16-16.99	10	-	-	-	-	-	10 (100.0)
	≥ 17	45	-	-	-	-	-	45 (100.0)

Table 3. Comparison of staging of the distal fibula by age and gender.

Gender	Age (years)	n	Staging of fibula			
			0	1	2	3
Female	0 - 0.99	2	2 (100.0)	-	-	-
	1 - 11.99	42	-	42 (100.0)	-	-
	12 - 12.99	5	-	2 (40.0)	2 (40.0)	1 (20.0)
	13 - 13.99	4	-	-	3 (75.0)	1 (25.0)
	14 - 14.99	4	-	-	1 (25.0)	3 (75.0)
	15 - 15.99	4	-	-	-	4 (100.0)
	16 - 16.99	9	-	-	-	9 (100.0)
	≥ 17	27	-	-	-	27 (100.0)
Male	0 - 0.99	6	5 (83.3)	1 (16.7)	-	-
	1 - 1.99	1	1 (100.0)	-	-	-
	2 - 12.99	43	-	43 (100.0)	-	-
	13 - 13.99	5	-	3 (60.0)	1 (20.0)	1 (20.0)
	14 - 14.99	4	-	4 (100.0)	-	-
	15 - 15.99	6	-	-	1 (16.7)	5 (83.3)
	16 - 16.99	10	-	-	-	10 (100.0)
	≥ 17	45	-	-	-	45 (100.0)

and fibular epiphyseal union. In female subjects, the minimum age for the distal tibial epiphyseal developmental stage 2 was noted at 10 years old, in male subjects at 9 years. In contrast, the minimum age of the distal fibular epiphyseal development stage 5 was 12 years in female subjects and 13 years in male subjects. Outliers with the extreme age were observed in male subjects. There was significant difference in male and female data at any maturation stage of distal tibia ($P = 0.02702$) and fibula ($P = 0.0002$). In addition, Chi-square test for linear-by-linear association was shown to be significant ($P < 0.001$) and indicated that epiphyseal plate closure tended to rise with the increasing age.

After each stage of the epiphyseal union has been staged accordingly, the scores are combined to create a composite score. Descriptive analyses for age variation within composite scores for male and female radiographs were shown in Tables 4. Both sexes displayed the overall trend of increasing composite score with increasing age. A score of 8 indicated the complete union of both distal tibia and fibula, and was first present in 12 years and 13 years in the female and male subjects, respectively. All the female and male subjects showed complete epiphyseal union of both distal tibia and fibula in 15 and 16 years, respectively.

To determine intra- and inter-observer reliability in grading of distal tibia and fibula, 22 ankle radiographs

were re-evaluated and analyzed. The weighted kappa (K_w) for intra- and inter-observer reliability of both distal tibia and was 1.00 and 0.98, respectively. The weighted kappa for intra- and inter-observer reliability of distal fibula was 1.00. To conclude, the evaluation of the growth plate closure by the same researcher and between the principal researcher and co-researcher was excellent reliability ($K_w = 0.81 - 1.00$).

Discussion

Age estimation of the living has several indicators used to evaluate an age range for a person being investigated. The study focusing on the radiographic evaluation of epiphyseal plate development is considered to be used toward facilitating an age estimation by the court of law all over the world. This study was conducted to investigate the chronological age of epiphyseal union at the ankle joint. Studies carried out previously are also discussed below.^(14 - 18, 21)

The key in age estimation is to assess the age-related to the legal background. In Thailand, the age of 15 years is identified as the age at which a person is considered to engage in a certain legal activity such as marriage, testament and criminal responsibility. In the female subjects in this study, the complete union of all epiphyseal plate of distal tibia and fibula was reported in the age group of 15 - 16 years, whereas

Table 4. Comparison and descriptive statistics of the composite score by age and sex.

Gender	Age	n	Total score										Mean (SD)	Min, Max		
			0	1	2	3	4	5	6	7	8					
Female	≤11.99	44	1(2.3)	1(2.3)	40(90.9)	1(2.3)	1(2.3)	1(2.3)	-	-	-	-	-	-	2±0.48	0,4
	12-12.99	5	-	-	1(20.0)	-	2(40.0)	-	-	-	-	1(20.0)	-	-	5±2.45	2,8
	13-13.99	4	-	-	-	-	-	-	2(50.0)	1(25.0)	-	-	-	-	6.75±0.96	6,8
	14-14.99	4	-	-	-	-	-	-	1(25.0)	-	-	-	-	-	7.50±1.00	6,8
	15-15.99	4	-	-	-	-	-	-	-	-	-	-	-	-	8	8
	16-16.99	9	-	-	-	-	-	-	-	-	-	-	-	-	8	8
	≥17	27	-	-	-	-	-	-	-	-	-	-	-	27(100.0)	8	8
Male	≤11.99	45	2(4.4)	4(8.9)	37(82.2)	2(4.4)	-	-	-	-	-	-	-	-	1.87±0.55	0,3
	12-12.99	5	-	-	5(100.0)	-	-	-	-	-	-	-	-	-	2	2
	13-13.99	5	-	-	2(40.0)	1(20.0)	-	-	1(20.0)	-	-	-	-	-	4±2.55	2,8
	14-14.99	4	-	-	2(50.0)	1(25.0)	-	-	1(25.0)	-	-	-	-	-	3±1.41	2,5
	15-15.99	6	-	-	-	-	-	-	-	-	1(16.7)	-	-	-	7.83±0.41	7,8
	16-16.99	10	-	-	-	-	-	-	-	-	-	-	-	-	8	8
	≥17	45	-	-	-	-	-	-	-	-	-	-	-	45(100.0)	8	8

in the male subjects 100.0% of distal tibia and 83.3% of distal fibula showed the union of their epiphysis in the age group of 15 - 16 years. Therefore, to decide whether or not a Thai adolescent is more than 15 years old, the radiographs of the ankle joint could be helpful.

Several studies investigated the fusion of the epiphyseal plate of the distal tibia and fibula relate to radiographs of living persons with known age.⁽¹⁴⁻¹⁸⁾ The same age range of 15 - 16 years was also observed in the complete fusion of the distal tibia and fibula in the female subjects of Central India.⁽¹⁷⁾ However, the study in the Indian population conducted by Banerjee KK, *et al.*⁽¹⁴⁾ revealed that their results were 1 - 3 years later compared to this study. An American research by Crowder C. and Austin D.⁽¹⁵⁾ demonstrated that the mean age of complete fusion of the distal tibia was 16 years in female subjects and 19 years in male subjects. Hoerr NL. and Pyle SI.⁽²¹⁾ investigated more than 4,500 plain ankle radiographs of the Americans, and they found that all-female subjects showed complete fusion of the distal tibia at the mean age of 14.4 years old. By the mean age of 16.4 years, all-male Americans showed complete fusion of the distal tibia. In sum, the age of fusion of the distal epiphyses of the leg is between 14 - 18 years old in females and between 15 - 19 years old in males.⁽²²⁾ Ethnicity, gender, socioeconomic status and method of examination are factors that play a crucial role in the skeletal maturation.⁽²²⁻²³⁾ The epiphyseal centers in female subjects mature 1 - 2 years earlier than in male subjects. We also noted that the age range for reaching each developmental stage was more advanced for females than for males. These findings are consistent with the previous studies on different periods of bone maturation between males and females, with females usually grow more advanced than males by several months to 1 - 2 years.^(1, 18, 22) These results could explain by the influence of sex hormones. Another factor, which may provide this discrepancy, is the different generations of people used in this study. A secular trend in growth and development resulting in the tendency to mature earlier and an increase in height and weight.⁽²⁴⁻²⁶⁾

Determination of age-at-death by radiographic examination may be used to compare with macroscopic examination when maceration is unavailable.⁽²⁷⁾ However, there is a lack of a standardized methodology to compare gross morphological and radiographic evaluation. A difference between the macroscopic and radiographic

examination of the epiphyseal fusion has been explored in the previous study.⁽²⁴⁾ Radiographic pictures of epiphysis may display a fusion line several months to years before a naked eye can identify it. In addition, an epiphyseal scar of complete fusion on a radiograph can be mistaken for a less advanced stage than that determined by gross morphological technique. Besides, standardized methods using for radiographic and macroscopic examinations cannot be applicable to computed tomographic or magnetic resonance imaging (MRI). The study conducted by Saint-Martin P, *et al.*⁽¹⁸⁾ used MRI to investigate the fusion time of epiphyseal plates of distal tibia and calcaneus. They found a more advanced mean age of complete fusion of distal tibial epiphysis, occurring at 20 years for females and 22 years for males. Theoretically, MRI provides more informative thin slices comparing with a plain radiograph. Therefore, it can detect a tiny area of incomplete fusion of an epiphyseal plate, whereas the study using a plain radiograph cannot detect it.

Some topics should be considered in using a radiographic dataset. The integrity of the radiographic imaging and the experience of the radiographer is important.^(3,15) Proper radiological equipment such as the film type utilized and the radiographic machine's condition is essential to high-quality radiographs. Even though radiographic settings such as the subject position and radiographic exposure are standardized, the individual variability in soft tissue thickness and bone density of the subjects can affect the quality of radiographs.

It is possible to predict the approximate age of a subject by a composite score. The major strength of the composite score is the inclusion of morphological findings of both tibia and fibula into the scores and this score is therefore effective to give an age range of the subject. Our data demonstrate that age is correlated with the composite scores. For example, the composite score of 8 points means that the female and male subjects are at least 12 and 13 years old, respectively. In addition, the score is found in all females at the age of 15 years and all males at the age of 16 years.

The limitation of this study was also recognized. First, there was a lack of precise information, such as socioeconomic status of the subjects. Next, a limited number of subjects led to a relatively small sample size, and this study was only limited to the area of Bangkok. Subsequently, the results may not represent the data of the general Thai population. A multicenter

study with a larger sample size and subjects from different parts of Thailand is necessary. Further studies are needed to address these limitations.

Conclusion

The epiphyseal fusion of the distal tibia and fibula presented in this study essentially appears to be a suitable technique for age estimation in the living as well as in an unidentified corpse. A forensic practitioner can use the result of this study to assess age in Thai people. On radiographic examination of the ankle joint, the age of complete fusion of the distal tibia epiphysis of all subjects is 15 years for females and males, and the age of complete fusion of the distal fibula epiphysis of all subjects is 15 years in females and 16 years in males. The earliest age of complete epiphyseal union of tibia and fibula epiphyses occurs at 12 years in female subjects and 13 years in male subjects. Together with the other age assessment methods, this study constitutes part of a basis for the recommendation of how age estimation should be carried out in Thailand. Finally, for maximum efficiency, the authors recommended that it is advantageous in conjunction with other standardized age assessment methods.

Acknowledgements

The authors are grateful to the staff of the Department of Radiology, Faculty of Medicine, Siriraj Hospital for access to their radiographic images and facilities; also, special thank is passed to Assistant Professor Dr. Chulaluk Komoltri for her help with the statistical tests.

Conflict of interest

The authors, hereby, declare no conflicts of interest.

References

- Black S, Aggrawal A, Payne-James JJ, editors. Age estimation in the living: The practitioner's guide. Hoboken, NJ: Wiley-Blackwell; 2010.
- Santos C, Ferreira M, Alves FC, Cunha E. Comparative study of greulich and pyle atlas and maturos 4.0 program for age estimation in a portuguese sample. *Forensic Sci Int* 2011;212:276.e1-7.
- Schmidt S, Nitz I, Ribbecke S, Schulz R, Pfeiffer H, Schmeling A. Skeletal age determination of the hand: a comparison of methods. *Int J Legal Med* 2013;127: 691-8.
- Darmawan MF, Yusuf SM, Abdul Kadir MR, Haron H. Age estimation based on bone length using 12 regression models of left hand X-ray images for Asian children below 19 years old. *Leg Med (Tokyo)* 2015;17:71-8.
- Schmeling A, Schulz R, Reisinger W, Mühler M, Wernecke KD, Geserick G. Studies on the time frame for ossification of the medial clavicular epiphyseal cartilage in conventional radiography. *Int J Legal Med* 2004;118:5-8.
- Wittschieber D, Ottow C, Vieth V, Küppers M, Schulz R, Hassu J, et al. Projection radiography of the clavicle: still recommendable for forensic age diagnostics in living individuals? *Int J Legal Med* 2015;129:187-93.
- Zhang K, Chen XG, Zhao H, Dong XA, Deng ZH. Forensic age estimation using thin-slice multidetector CT of the clavicular epiphyses among adolescent Western Chinese. *J Forensic Sci* 2015;60:675-8.
- Pattamapaspong N, Madla C, Mekjaidee K, Namwongprom S. Age estimation of a Thai population based on maturation of the medial clavicular epiphysis using computed tomography. *Forensic Sci Int* 2015;246:123.e1-5.
- Cameriere R, Giuliodori A, Zampi M, Galic I, Cingolani M, Pagliara F, et al. Age estimation in children and young adolescents for forensic purposes using fourth cervical vertebra (C4). *Int J Legal Med* 2015;129: 347-55.
- de Oliveira FT, Soares MQ, Sarmento VA, Rubira CM, Lauris JR, Rubira-Bullen IR, Mandibular ramus length as an indicator of chronological age and sex. *Int J Legal Med* 2015;129:195-201.
- Scoles PV, Salvagno R, Villalba K, Riew D. Relationship of iliac crest maturation to skeletal and chronologic age. *J Pediatr Orthop* 1988;8:639-44.
- Wittschieber D, Vieth V, Domnick C, Pfeiffer H, Schmeling A. The iliac crest in forensic age diagnostics: evaluation of the apophyseal ossification in conventional radiography. *Int J Legal Med* 2013;127: 473-9.
- Fan F, Zhang K, Peng Z, Cui JH, Hu N, Deng ZH. Forensic age estimation of living persons from the knee: Comparison of MRI with radiographs. *Forensic Sci Int* 2016;268:145-50.
- Banerjee KK, Agarwal BB. Estimation of age from epiphyseal union at the wrist and ankle joints in the capital city of India. *Forensic Sci Int* 1998;98:31-9.
- Crowder C, Austin D. Age ranges of epiphyseal fusion in the distal tibia and fibula of contemporary males and females. *J Forensic Sci* 2005;50:1-7.

16. Ding KY, Dahlberg PS, Rolseth V, Mosdøl A, Straumann GH, Bleka Ø, et al. Development stages of the knee and ankle by computed tomography and magnetic resonance imaging for estimation of chronological age: a systematic review. Report 2018. Oslo: Norwegian Institute of Public Health; 2018.
17. Patond S, Tirpude BH, Murkey P, Wankhade P, Nagrale N, Surwade V. Age determination from epiphyseal union of bones at ankle joint in girls of central India. *J Forensic Med Sci Law* 2012;21:11-6.
18. Saint-Martin P, Rérolle C, Dedouit F, Bouilleau L, Rousseau H, Rougé D, et al. Age estimation by magnetic resonance imaging of the distal tibial epiphysis and the calcaneum. *Int J Legal Med* 2013; 127:1023-30.
19. Ruensuk S, Vachirawongsakorn V. Age estimation from radiographic analysis of epiphyseal fusion at the knee joint in Thai population. *JFPAT* 2018; 12:21-33.
20. Benjavongkulchai S, Pittayapat P. Age estimation methods using hand and wrist radiographs in a group of contemporary Thais. *Forensic Sci Int* 2018;287: 218.e1-e8.
21. Hoerr NL, Pyle SI, Francis CC. Radiographic atlas of skeletal development of the foot and ankle: A standard of reference. Springfield, IL: Charles C. Thomas;1962.
22. Scheuer L, Black S. Developmental juvenile osteology. Cambridge, MA:Academic Press, 2000.
23. Schmeling A, Reisinger W, Geserick G, Olze A. Age estimation of unaccompanied minors. Part I. General considerations. *Forensic Sci Int* 2006;159 Suppl 1: S61-4.
24. Iscan MY. Age markers in the human skeleton. Springfield, IL:Charles C Thomas;1989.
25. Ousley SD, Jantz RL. The forensic data bank: Documenting skeletal trends in the United States. In: Reichs KJ, editor. *Forensic osteology: Advances in the identification of human remains*. 2nd ed. Springûeld, IL: Charles C Thomas;1999. p. 454-8.
26. Meadows MA, Jantz RL. Allometric secular change in the long bones from the 1800s to the present. *J Forensic Sci* 1995;40:762-7.
27. De Angelis D, Messina C, Sconfienza L, Sardanelli F, Cattaneo C, Gibelli D. Forensic radiology and identification. In: Lo Re G, Argo A, Midiri M, Cattaneo C, editors. *Radiology in forensic medicine: From identification to post-mortem imaging*. Springer Nature Switzerland;2020. p.63-85.