

1-1-2021

Surgical management of anorectal malformations based on Krickenbeck classification: 13 - year experience from a single institute

Sirima Liukitithara

Katawaetee Decharun

Paisarn Vejchapipat

Somboon Roekwibunsri

Dusit Viravaidya

See next page for additional authors

Follow this and additional works at: <https://digital.car.chula.ac.th/clmjjournal>



Part of the [Medicine and Health Sciences Commons](#)

Recommended Citation

Liukitithara, Sirima; Decharun, Katawaetee; Vejchapipat, Paisarn; Roekwibunsri, Somboon; Viravaidya, Dusit; Rajatapiti, Prapapan; and Chittmittrapap, Soottiporn (2021) "Surgical management of anorectal malformations based on Krickenbeck classification: 13 - year experience from a single institute," *Chulalongkorn Medical Journal*: Vol. 65: Iss. 1, Article 5.

Available at: <https://digital.car.chula.ac.th/clmjjournal/vol65/iss1/5>

This Article is brought to you for free and open access by the Chulalongkorn Journal Online (CUJO) at Chula Digital Collections. It has been accepted for inclusion in Chulalongkorn Medical Journal by an authorized editor of Chula Digital Collections. For more information, please contact ChulaDC@car.chula.ac.th.

Surgical management of anorectal malformations based on Krickenbeck classification: 13 - year experience from a single institute

Authors

Sirima Liukitithara, Katawaetee Decharun, Paisarn Vejchapipat, Somboon Roekwibunsri, Dusit Viravaidya, Prapapan Rajatapiti, and Soottiporn Chittmittrapap

Original article

Surgical management of anorectal malformations based on Krickenbeck classification: 13 - year experience from a single institute

Sirima Liukitithara^{a,b}, Katawaetee Decharun^{a,*}, Paisarn Vejchapipat^a, Somboon Roekwibunsri^a, Dusit Viravaidya^a, Prapapan Rajatapiti^a, Soottiporn Chittmittrapap^a

^aDepartment of Surgery, Faculty of Medicine, Chulalongkorn University and King Chulalongkorn Memorial Hospital, Bangkok, Thailand

^bDepartment of Surgery, Hatyai Hospital, Songkhla Province, Thailand

Background: Anorectal malformations (ARMs) represent a wide spectrum of disease with various operative managements. Posterior sagittal anorectoplasty (PSARP) has been developed as the standard technique. However, there are still controversies in the management of ARMs.

Objectives: The objective of this study was to assess the operative managements including associated anomalies and functional outcome of anorectal malformations at King Chulalongkorn Memorial Hospital over a 13-years.

Methods: A retrospective study was conducted at King Chulalongkorn Memorial Hospital between January 2004 and December 2016. Patients' information was classified based on Krickenbeck classification. Statistical analysis was performed using IBM SPSS statics 22.0 version for MAC.

Results: A total of 96 patients underwent repair of ARMs. The most common ARMs in male patients were rectourethral fistulas (32.0%) and in female patients were vestibular fistulas (45.0%). Seventy-five (78.0%) patients had at least one associated anomaly. Thirty-four patients (36.0%) had VACTERL association. There were 74 (77.0%) patients were managed with colostomy as staged procedures. All patients with rectourethral bulbar fistulas underwent PSARP (11/11) while patients with rectourethral prostatic fistulas or rectovesical fistulas underwent abdominoperineal pull-through (12/17), PSARP with laparotomy (4/17) and PSARP (1/17). ARMs with perineal fistulas underwent cut back operation (7/13), PSARP (3/13) and ASARP (3/13) depending on surgeons' preferences. ARMs with vestibular fistulas underwent PSARP (15/21) or ASARP (6/21). Mostly cloacal malformations underwent PSARVUP with laparotomy (6/13). ARMs with no fistula underwent PSARP (13/13). H-type ARMs underwent fistulectomy (4/5) and ASARP with protective colostomy (1/5). Fifty-three patients (61.0%) had no postoperative complications. Continence was achieved in 80.0% of the patients. The median time of follow up is 4.5 years.

Conclusion: In our series, the incidences of ARMs according to Krickenbeck classification are quite similar compared to other studies. Operative managements of ARMs are highly variable depending on types of ARMs. Functional outcome is also comparable to other studies.

Keywords: Anorectal malformations, Krickenbeck classification, posterior sagittal anorectoplasty, posterior sagittal anorectovaginourethroplasty, abdominoperineal pull-through.

Anorectal malformations (ARMs) are congenital anomalies where the anus and rectum do not develop properly. ARMs occurs in one out of every 4,000 to

5,000 newborns and is slightly more common in males.⁽¹⁾ Defects vary from minor lesions to complex anomalies. Previously, anorectal malformations were classified as high, intermediate or low anomalies according to the Wingspread classification in 1984. This classification was widely accepted over the years and was based on detailed embryological, anatomic studies performed and radiographic investigations. However, some details of the Wingspread classification still remained questionable.

*Correspondence to: Katawaetee Decharun, Department of Surgery, Faculty of Medicine, Chulalongkorn University and King Chulalongkorn Memorial Hospital, Bangkok 10330, Thailand.

E-mail: katawaetee@hotmail.com

Received: November 5, 2019

Revised: January 23, 2020

Accepted: February 20, 2020

In 1995, Pena A.⁽²⁾ proposed a classification based on the type of the fistula presented. With this approach, a unique opportunity arose to correlate the external appearance of the perineum with the operative findings and, subsequently, with the clinical results. With the presence of different classification systems, it was difficult to compare the outcome in patients with ARMs between different centers. An International Conference for the Development of Standards for the Treatment of Anorectal Malformation⁽³⁾ was organized at Krickenbeck Castle, Germany, on 2005. The participants developed a new international classification for ARMs and a new grouping for follow-up assessment and standard surgical procedures. This new international classification enables the different operative procedures to be more comparable to each other than with the other classifications. At present, the Krickenbeck classification has become the gold standard for the classification of ARMs. All pediatric surgeons had multiple lessons learned in order to improve the quality of life of children born with all different types of ARMs. The posterior sagittal approach for the treatment of ARMs was performed first in 1980, and its description was published in 1982 according to Pena A, *et al.*⁽⁴⁾ and De Vries P, *et al.*⁽⁵⁾ Posterior sagittal anorectoplasty (PSARP) has developed as a standard technique for numerous surgeons worldwide. However, there are still controversial topics in the management of ARMs, including various diagnoses and operative managements.

In Thailand, most of the studies categorized ARMs based on Wingspread Classification that could not compare the operative techniques and postoperative results between the different centers of pediatric surgery internationally.⁽⁶⁾ The aim of this study was to review the operative management including associated anomalies and functional outcome over 13 years of experience at King Chulalongkorn Memorial Hospital based on Krickenbeck classification.

Materials and methods

A retrospective study was conducted by reviewing of the medical records of patients with ARMs aged 0 -15 years whom were surgically treated at King Chulalongkorn Memorial Hospital between January 2004 and December 2016. The study has been approved by the Ethics Committees of the institute

(COA No.214/2016). Patients' data were collected including demographics, types of ARMs according to the Krickenbeck classification, associated anomalies, operative management, complications and postoperative results. Patients who had redo-operation or incomplete data were excluded. Statistical analysis was performed by using IBM SPSS statistics 22.0 version for MAC.

Results

Demographic data

From January 2004 to December 2016, 96 patients with anorectal malformations were recruited. They were 49 females and 47 males. Types of anorectal malformations were classified according to Krickenbeck classification. In females, the majorities of cases were vestibular fistulas (22 patients, 45.0%). The second most common type was cloacas (13 patients, 27.0%). In males, the most common type of ARMs was recto-urethral fistulas (15 patients, 32.0%). There were 11 patients with recto-urethral bulbar fistulas (23.0%) and 4 patients with recto-urethral prostatic fistulas (9.0%). The second most common was rectovesical fistulas (13 patients, 28.0%)(Table 1). Seventy-five patients (78.0%) had at least one associated malformation or syndrome. The most common associated anomalies were renal anomalies (40 patients, 50.0%). Proximal esophageal atresias with tracheoesophageal fistulas were found in 6 patients (6.0%) and duodenal atresias/stenoses were found in 5 patients (5.0%)(Table 2). VACTERL associations were found in 35 patients (36.0%). Twelve patients (12.0%) were syndromic: Trisomy 21 (10 patients) and Currarino syndrome (2 patients). All patients with Down's syndrome had no fistulas.

Operative managements

The choice of surgical management for ARMs varies depending on the type of ARMs, patient's underlying status and surgeons' preferences. At the initial neonatal evaluation, the patients with perineal fistulas, a few patients with vestibular fistulas and without fistula were identified, and later, definitive operations were usually performed on them. Otherwise colostomy would be the first operative procedure. The flow of operative management is shown in Figure 1.

Two patients died due to severe underlying disease before definitive surgeries were done. Summary of definite surgery is shown in Table 3.

Types and locations of colostomy

The median time for creating a colostomy was 2 days old (1 - 5, 130 days). Seventy-four patients (74/96, 77.0%) had colostomies. Loop colostomies and double end colostomies were performed in 44 patients

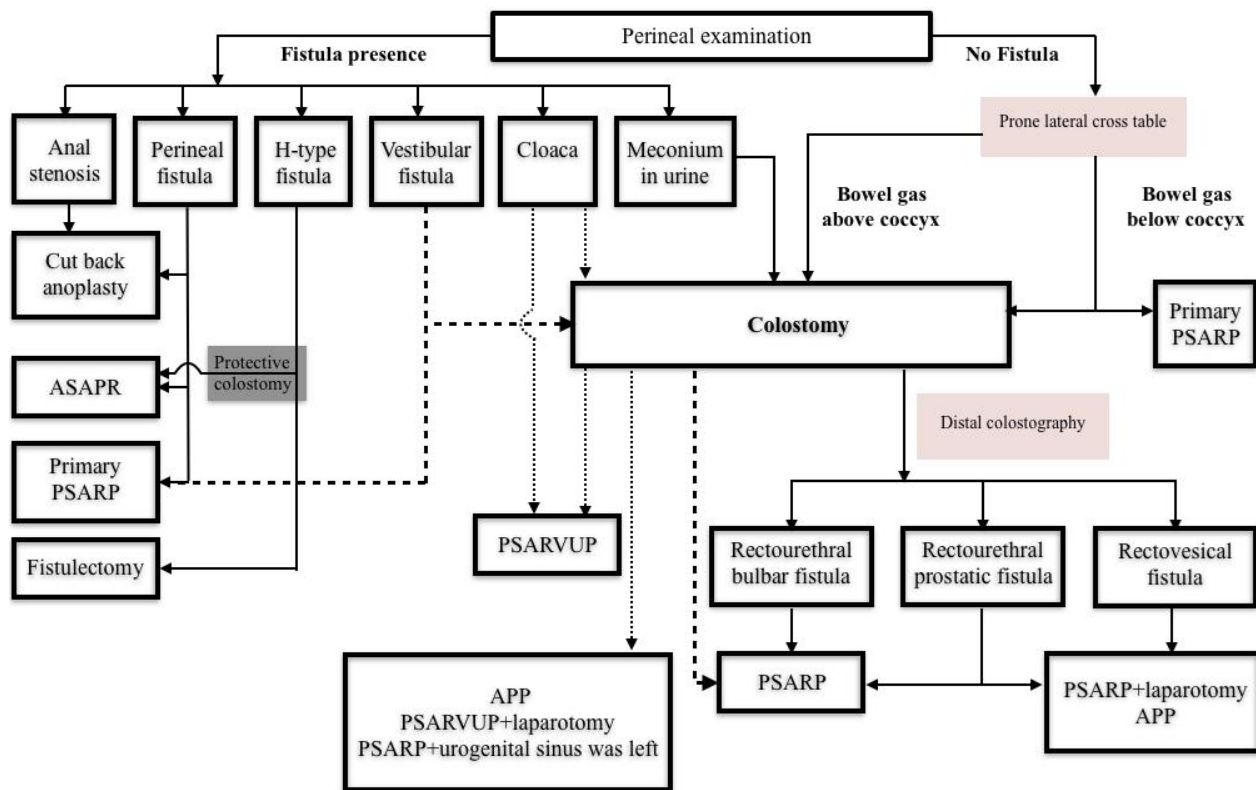
(44/74, 60.0%) and 27 patients (27/74, 36.0%), respectively. Descending-sigmoid colostomies were performed in 61 patients (61/74, 82.0%), while transverse colostomies were performed in 13 patients (13/74, 18.0%).

Table 1. Incidence of type of anorectal malformations according to Krickenbeck classification.

Male	Total (n)	%	Female	Total (n)	%
Perineal fistula	10	21.0	Perineal fistula	4	8.0
Rectourethral fistula	15	32.0	Vestibular fistula	22	45.0
Prostatic	4	9.0	Cloaca	13	27.0
Bulbar	11	23.0	< 3 cm. common channel	4	9.0
Rectovesical fistula	13	28.0	> 3 cm. common channel	9	18.0
No fistula	8	17.0	No fistula	5	10.0
Anal stenosis	1	2.0	Rare: H type fistula	5	10.0
Total (n= 96)	47			49	

Table 2. Frequency of associated anomalies in patients with anorectal malformations.

Type of associated anomalies	Anomaly/Total (n)	%
Vertebral and spinal anomalies	23/80	28.0
Sacrum or coccyx anomalies	13/80	16.0
Tethered cord	9/80	11.0
Vertebral anomalies	8/80	10.0
Syringomyelia	4/80	5.0
Cardiac anomalies	30/96	31.0
PDA	16/96	17.0
VSD	10/96	10.0
ASD	7/96	7.0
Tetralogy of Fallot	3/96	3.0
Esophageal atresia	6/96	6.0
Renal anomalies	40/79	51.0
Renal agenesis	9/79	11.0
Hydronephrosis	16/79	20.0
VUR	17/79	22.0
Dysplastic kidney	7/79	9.0
Genital anomalies	10/47	21.0
Undescended testis	3/47	6.0
Hypospadias	7/47	15.0
Limb anomalies	12/96	12.0
Absence radius	1/96	1.0
Polydactyly	4/96	4.0
Club foot	2/96	2.0
Others	5/96	5.0
Others		
Duodenal atresia/stenosis	5/96	5.0
Hypothyroid	5/96	5.0
Cleft lip/palate	5/96	5.0



FASARP: anterior sagittal anorectoplasty; PSARP: posterior sagittal anorectoplasty; APP: abdominoperineal pull-through; PSARVUP: posterior sagittal anorectovaginoureteroplasty

Figure 1. Flow of operative managements for the anorectal malformations.

Table 3. Definitive surgery for the anorectal malformations.

Procedure	Anomaly/ total (n)	Vestibular fistula (n = 22 ^a)	Perineal fistula (n = 14 ^a)	Anal stenosis (n = 1)	H type fistula (n = 5)	No fistula (n = 13)	Bulbar fistula (n = 11)	Prostatic fistula (n = 4)	Rectovesical fistula (n = 13)	Cloaca (n = 13)
Cut back anoplasty	8/94		7/13	1/1						
Fistulectomy	4/94				4/5					
ASARP	10/94	6/21	3/13		1/5					
PSARP	43/94	15/21	3/13			13/13	11/11	1/4		
PSARP + laparotomy	4/94							1/4	3/13	
APP	15/94							2/4	10/13	3/13
PSARVUP	3/94									3/13
PSARVUP + laparotomy	6/94									6/13
PSARP+ urogenital sinus was left	1/94									1/13

^a: one patient of each group was dead before definite surgery due to irrelevant causes. ASARP: anterior sagittal anorectoplasty; PSARP: posterior sagittal anorectoplasty; APP: abdominoperineal pull-through; PSARVUP: posterior sagittal anorectovaginoureteroplasty

Perineal fistulas and anal stenosis

Cut-back anoplasty was commonly performed in 8 patients (7 patients with perineal fistula and 1 patient with anal stenosis). Anterior sagittal anorectoplasty (ASARP) and limited posterior sagittal anorectoplasty (PSARP) were performed in 6 patients (3/6, 3/6). Most of the procedures (10/13) were performed as a primary surgery in neonatal period. However, some

patients underwent colostomies (3/13) due to severe associated anomalies and delayed diagnosis (1.5 year) (Table 3).

Vestibular fistulas

Most patients (14/21) underwent 3-stage operation (colostomy, definitive surgery and closure of colostomy) due to surgeons' preferences. Protective

colostomies at the same time of definitive surgery were performed in two cases of delayed diagnosis (23 days, 14 years). Some surgeons performed PSARP (5 cases) as a primary surgery in the neonatal period followed by 10 - 14 days of total parenteral nutrition. PSARP were commonly performed in 15 (15/21) (Table 3). ASARP was performed in the other patients. (6/21).

Rectourethral fistulas (bulbar fistulas and prostatic fistulas)

All patients underwent 3-stage operation. Colostomies were done in neonatal period and then distal colostography were usually achieved later within 3 months of age. PSARP was performed in all patients with rectourethral bulbar fistulas (11/11). Abdominoperineal pull-through (APP) was performed in 2 patients with rectourethral prostatic fistulas (2/4) (Table 3). The others underwent in PSARP (1/4) and PSARP with laparotomy (1/4).

Rectovesical fistulas

All patients underwent 3-stage operation. APP was performed in 10 patients (10/13) and PSARP with laparotomy were performed in 3 patients (3/13) (Table 3).

No fistulas

Most patients (12/13) underwent 3-stage operation. Prone cross-table lateral radiographies were investigated 24 hours after birth in all patients (13/13) (Table 3). PSARP was performed as definitive surgery and as a primary surgery in one patient during neonatal period.

H type fistulas

All patients (5/5) had delayed diagnosis (3, 7, 7, 8 and 9 months). Fistulectomy was performed in 4 patients (4/5) while ASARP with protective colostomy was performed in one patient (1/5) (Table 3).

Cloacas

Common channel length of shorter than 3 cm

Posterior sagittal anorectovaginourethroplasty (PSARVUP) with total urogenital mobilization (TUM) was performed in 3 patients (3/4) and PSARP with delayed repair of urogenital sinus in 1 patient (1/4) (Table 3).

Common channel length of longer than 3 cm

PSARVUP with laparotomy was performed in 6 patients (6/9) and APP was performed in 3 patients

(3/9). Vaginal replacements using the rectum as neovagina was performed in 2 patients (2/9).

Operative management of patients with ARMs and associated anomalies

ARMs and duodenal atresias

Five patients had ARMs and duodenal atresias. Duodenoduodenostomy with colostomy was performed in 4 patients (2 no fistula, 1 rectourethral bulbar fistula and 1 cloaca). Duodenoduodenostomy with cut-back anoplasty was performed in 1 patient with perineal fistula.

ARMs and esophageal atresia with tracheoesophageal fistulas (EA with TE fistulas)

Five patients had ARMs and EA with TE fistulas. Esophagoesophagostomy with colostomy were performed in 3 patients with vestibular fistulas and 2 patients with rectovesical fistulas. One patient had ARMs with perineal fistula, duodenal atresia and EA with TE fistula. She underwent cutback anoplasty with duodenoduodenostomy as the first surgery and esophagoesophagostomy seven days later.

Complications

Complications of colostomy

Complication of colostomies occurred in 21.6% (16 /74), including prolapse (5/74), improper length (1/74), incomplete diversion which caused urinary tract infection or fecal impaction (8/74), gut obstruction (1/74) and retraction (1/74).

Postoperative complications

Thirty-five patients (35/94, 37.0%) had postoperative complications (Table 4). The most common complication was wound infection (15/94, 15.9%). Twenty-two patients (22/94, 23.4 %) had redo-operations but only 10 patients (10/94, 10.6%) underwent major operations. The most common redo-operation was mucosectomy for mucosal prolapse (12/94, 12.7%).

Postoperative results

Fifty-two patients were older than 3 years of age and were assessed for functional outcome according to Krickenbeck classification (Table 5). The median time of follow-up is 4.5 years. Total continence had been achieved in 42.0% of all. Constipation occurred in 31.0% of the patients, mostly in perineal fistulas, vestibular fistulas and no fistulas, respectively. Soiling occurred in 27.0%, mostly in cloacas, rectourethral prostatic fistulas and rectovesical fistulas.

Table 4. Post-operative complications.

Types		Wound infection	Mucosal/rectal prolapsed	Anal stricture
Vestibular fistula	(n= 21)	5	0	2
Perineal fistula	(n= 13)	0	0	1
Anal stenosis	(n= 1)	0	0	0
H type fistula	(n= 5)	0	0	0
No fistula	(n= 13)	1	1	1
Rectourethral bulbar fistula	(n= 11)	2	1	1
Rectourethral prostatic fistula	(n= 4)	1	2	0
Rectovesical fistula	(n= 13)	1	6	1
Cloaca	(n= 13)	5	2	2
Total	(n= 94)	15	12	8

Table 5. Functional outcome of the 52 children older than 3 years of age according to the Krickenbeck assessment system.

Type of ARMs	Total continence (%)	Constipation (%)	Soiling (%)	Total (n)
Perineal fistula	50.0	50.0	0.0	4
Vestibular	55.0	45.0	0.0	11
H-type fistula	100.0	0.0	0.0	1
No fistula	29.0	57.0	14.0	7
Rectourethral bulbar fistula	63.0	12.0	25.0	3
Rectourethral prostatic fistula	33.0	0.0	66.0	8
Rectovesical fistula	44.0	28.0	33.0	9
Cloaca	11.0	22.0	66.0	9
Total	42.0	31.0	27.0	52

Discussion

The worldwide incidence, prevalence and presentation of patients with ARMs are heterogeneous. Pena A. reported rectourethral fistula as the most common lesion in males and vestibular fistula as the most common lesion in females.⁽⁷⁾ The first report of the ARM-NET (European consortium on anorectal malformations) reported perineal fistula as the most common lesion both in males (43.0%) and females (41.0%) followed by rectourethral fistula in males (29.0%) and vestibular fistula in females (28.0%).⁽⁸⁾ In our series, rectourethral fistula is the most common lesion in males (32.0%) and vestibular fistula is the most common lesion in females (45.0%). Followed by rectovesical fistula (28.0%) and cloaca (27.0%), respectively. The high incidence of cloacas in our series owing to our institution as a tertiary care center. The incidence of ARMs without fistula in our series was higher from previous reports.⁽⁹⁾ Seventy-five patients (78.0%) had at least one associated anomaly, higher than which has been described

in literatures, they vary between 20.0 to 70.0%.⁽¹⁰⁾ The most common associated anomalies were renal anomalies (50.0%). Associated anomalies in our series show no difference from recent literatures.⁽¹⁰⁻¹⁶⁾

The operative management depends on the types of ARMs. The decision making between a primary repair or staged operation depends on the experience of the surgeon, the condition of the patient and the surrounding circumstances. We usually perform primary repair in most patients with perineal fistulas (10/13), H type fistulas (4/5), in addition, in a patient with vestibular fistula (1/13) and another patient with no fistula (1/13). Colostomy is traditionally performed as part of staged operation. Accordingly, 77.0% of cases had colostomies. We performed both loop colostomies and double end colostomies. It has been suggested that divided sigmoid colostomy may result in better radiological studies and a lower incidence of prolapse.⁽¹⁷⁾ In our series, the incidence of prolapse showed no difference between the two groups but

the incomplete diversion from loop colostomies caused urinary tract infection and fecal impaction more than double end colostomy. Therefore, the authors currently perform divided sigmoid-descending colostomy. Minimal PSARP is the current standard technique for perineal fistulas. However, the alternative technique, anoplasty may not affect the functional or cosmetic outcome.⁽¹⁸⁾ In our series, surgeons also perform cut back anoplasty and ASARP. In vestibular fistulas (17/21) and no fistulas (12/13), we performed staged operation in most of the patients. The surgeon preferred to performed protective colostomy because of the risk of wound infection and wound dehiscence.⁽¹⁷⁻²²⁾ In recent studies, PSARP performed without a protective colostomy have low morbidity and good continence.⁽²³⁾ Our surgeons started to perform PSARP without a protective colostomy (4/21) with post operative total parenteral nutrition for 10 - 14 days in 2014. Also, in no fistulas, the surgeon started to performed PSARP (1/13) as the primary surgery in neonatal period, if prone lateral crossable x-ray film showed rectal gas below the coccyx. Various surgical techniques have been used for H type fistulas.⁽²⁴⁻²⁷⁾ In the majority of H type fistulas (4/5), we performed fistulectomy. This procedure is less invasive, better visualization, and easier to perform, with reliable results.⁽²⁶⁾

The most common postoperative complication in our series was wound infection, mostly in cloacas. Second most common complication was mucosal prolapse, largely in rectovesical fistulas. The length of rectal dissection in the intra-abdominal space may play an important role in developing postoperative rectal prolapse. Longer dissections in rectovesical fistulas may lead to higher rate of rectal prolapse.⁽²⁷⁾ There was no wound infection in perineal fistulas, anal stenosis and H-type fistulas owing to the fact that wound problems after neonatal treatment of low defects are very uncommon and urological complications following surgery as they are unacceptable.⁽²⁸⁾

Postoperative incontinence and constipation remain major problems that impede social and psychological development. We assess the functional outcome according to international classification (Krickenbeck) to evaluate voluntary bowel movement, soiling and constipation. In our series, voluntary bowel movement was presented in 42.0% of patients, comparable to other studies.^(29, 30) Soiling was presented in 27.0% and mainly found in cloacas, rectourethral prostatic fistulas and rectovesical fistulas.

The causes of worst prognosis are the more marked hypoplasia of the voluntary sphincter muscles and the presence of severe sacral anomalies including tethered cord.⁽³²⁾ Constipation was presented in 31.0% and found 50.0% with perineal fistulas, 45.0% with vestibular fistulas, and 57.0% with no fistulas, comparable to the 1995 study of Pena and the others.^(2, 33) The cause of constipation is unclear: colonic motility disorder in patients with low defects and vestibular fistulas.⁽³⁰⁾ Also, rectosigmoid hypomotility and generalized colonic motility disturbance have been suggested.⁽³⁴⁾ Our series didnot establish the relationship between types of surgical procedures and functional outcome due to small sample size in each groups.

Conclusion

In our series, an incidence of types of ARMs according to Krickenbeck classification was quite similar compared to the other studies. Surgical managements were highly variable depending on the types of ARMs and the surgeons' preferences. Functional outcome was consistent with other studies. Prospective study and long-term follow up are needed to provide evidence on the outcome of different surgical procedures.

Conflict of interest

The authors, hereby, declare no conflict of interest.

References

1. Levitt MA, Pena A. Imperforate anus and cloacal malformations. In: Holcomb III GW, Murphy JP, editors. Ashcraft's pediatric surgery. 5th ed. Philadelphia, PA: Saunders Elsevier;2010. p. 468-90.
2. Pena A. Anorectal malformations. *Semin Pediatr Surg* 1995;4:35-47.
3. Holschneider A, Hutson J, Pena A, Beket E, Chatterjee S, Coran A, et al. Preliminary report on the International Conference for the Development of Standards for the Treatment of Anorectal Malformations. *J Pediatr Surg* 2005;40:1521-6.
4. Pena A, De Vries P. Posterior sagittal anorectoplasty: important technical considerations and new applications. *J Pediatr Surg* 1982;17:796-811.
5. De Vries P, Pena A. Posterior sagittal anorectoplasty. *J Pediatr Surg* 1982;17:638-43.
6. Patrapinyokul S, Sujijantararat P. Posterior sagittal anorectoplasty for imperforate anus: a preliminary result. *J Med Assoc Thai* 1993;76:23-8.

7. Pena A. Preface: advances in anorectal malformations. *Semin Pediatr Surg* 1997;6:165-9.
8. de Blaauw I, Wijers CH, Schmiedeke E, Holland-Cunz S, Gamba P, Marcelis CL, et al. First results of a European multi-center registry of patients with anorectal malformations. *J Pediatr Surg* 2013;48:2530-5.
9. Bischoff A, Frischer J, Dickie BH, Pena A. Anorectal malformation without fistula: a defect with unique characteristics. *Pediatr Surg Int* 2014;30:763-6.
10. Stoll C, Alembik Y, Dott B, Roth MP. Associated malformations in patients with anorectal anomalies. *Eur J Med Genet* 2007;50:281-90.
11. Singh S, Wakhlu A, Pandey A, Singh A, Kureel SN, Rawat J, et al. Esophageal atresia associated with anorectal malformation: Is the outcome better after surgery in two stages in a limited resources scenario? *J Indian Assoc Pediatr Surg* 2012;17:107-10.
12. Nah SA, Ong CC, Lakshmi NK, Yap TL, Jacobsen AS, Low Y. Anomalies associated with anorectal malformations according to the Krickbeck anatomic classification. *J Pediatr Surg* 2012;47:2273-8.
13. Balanescu RN, Topor L, Moga A. Anomalies associated with anorectal malformations. *Chirurgia* 2013;108:38-42.
14. Casaccia G, Catalano OA, Bagolan P. Congenital gastrointestinal anomalies in anorectal malformations: what relationship and management? *Congenit Anom* 2009;49:93-6.
15. Cho S, Moore SP, Fangman T. One hundred three consecutive patients with anorectal malformations and their associated anomalies. *Arch Pediatr Adolesc Med* 2001;155:587-91.
16. Ratan SK, Rattan KN, Pandey RM, Mittal A, Magu S, Sodhi PK. Associated congenital anomalies in patients with anorectal malformations - a need for developing a uniform practical approach. *J Pediatr Surg* 2004;39:1706-11.
17. Pena A, Migotto-Krieger M, Levitt MA. Colostomy in anorectal malformations: a procedure with serious but preventable complications. *J Pediatr Surg* 2006;41:748-56.
18. Whyte C, Canty TG, Smith J, Melody K. Anoplasty for low anorectal malformation. *J Pediatr Surg* 2016;51:1602-6.
19. Adeniran JO. One-stage correction of imperforate anus and rectovestibular fistula in girls: Preliminary results. *J Pediatr Surg* 2002;37:E16.
20. Liu G, Yuan J, Geng J, Wang C, Li T. The treatment of high and intermediate anorectal malformations: one stage or three procedures? *J Pediatr Surg* 2004;39:1466-71.
21. Patwardhan N, Kiely EM, Drake DP, Spitz L, Pierro A. Colostomy for anorectal anomalies: high incidence of complications. *J Pediatr Surg* 2001;36:795-98.
22. Levitt MA, Pena A. Anorectal malformations. In: Coran AG, Adzick NS, Krummel TM, Laberge JM, Shamberger RC, Caldamone AA, editors. *Pediatric surgery*. Philadelphia: Saunders Elsevier; 2012. p. 1289-1309.
23. Karakus SC, User IR, Akcaer V, Ceylan H, Ozokutan BH. Posterior sagittal anorectoplasty in vestibular fistula: with or without colostomy. *Pediatr Surg Int* 2017;33:755-9.
24. Lawal TA, Chatoorgoon K, Bischoff A, Pena A, Levitt MA. Management of H-type rectovestibular and rectovaginal fistulas. *J Pediatr Surg* 2011;46:1226-30.
25. Wu YM, Wang CD, Lv F, Zhang C, Yan ZL. The surgical management of H-type rectovestibular fistula: a novel modification. *Eur J Pediatr Surg* 2016;26:336-9.
26. Kelleher DC, Henderson PW, Coran A, Spigland NA. The surgical management of H-type rectovestibular fistula: a case report and brief review of the literature. *Pediatr Surg Int* 2012;28:653-6.
27. Banu T, Hoque M, Laila K, Ashraf Ul H, Hanif A. Management of male H-type anorectal malformations. *Pediatr Surg Int* 2009;25:857-61.
28. Wang ZM, Chen YJ, Zhang TC, Peng CH, Pang WB, Zhang D, et al. Anterior perineal fistulectomy in repairing H-type rectovestibular fistula with a normal anus in female children. *J Pediatr Surg* 2015;50:1425-8.
29. Jung SM, Lee SK, Seo JM. Experience with laparoscopic-assisted anorectal pull-through in 25 males with anorectal malformation and rectourethral or rectovesical fistulae: postoperative complications and functional results. *J Pediatr Surg* 2013;48:591-6.
30. Rintala RJ, Pakarinen MP. Imperforate anus; long- and short-term outcome. *Semin Pediatr Surg* 2008;17:79-89.
31. Pena A. Anorectal malformations. *Semin Pediatr Surg* 1995;4:35-47.
32. Rintala RJ, Lindahl H. Is normal bowel function possible after repair of intermediate and high anorectal malformations? *J Pediatr Surg* 1995;30:491-4.
33. Nam SH, Kim DY, Kim SC. Can we expect a favorable outcome after surgical treatment for an anorectal malformation? *J Pediatr Surg* 2016;51:421-4.
34. Rintala RJ, Marttinen E, Virkola K, Rasanen M, Baillie C, Lindahl H. Segmental colonic motility in patients with anorectal malformations. *J Pediatr Surg* 1997;32:453-6.