

1-1-2021

Anatomical feature and early outcomes of endovascular aneurysm repair from King Chulalongkorn Memorial Hospital

Kritaya Kritayakirana

Natawat Narueponjirakul

Apinan Uthaipaisanwong

Nantiskarn Chanpen

Punthita Aimsupanimitr

Follow this and additional works at: <https://digital.car.chula.ac.th/clmjjournal>



Part of the [Medicine and Health Sciences Commons](#)

Recommended Citation

Kritayakirana, Kritaya; Narueponjirakul, Natawat; Uthaipaisanwong, Apinan; Chanpen, Nantiskarn; and Aimsupanimitr, Punthita (2021) "Anatomical feature and early outcomes of endovascular aneurysm repair from King Chulalongkorn Memorial Hospital," *Chulalongkorn Medical Journal*: Vol. 65: Iss. 1, Article 3. Available at: <https://digital.car.chula.ac.th/clmjjournal/vol65/iss1/3>

This Article is brought to you for free and open access by the Chulalongkorn Journal Online (CUJO) at Chula Digital Collections. It has been accepted for inclusion in Chulalongkorn Medical Journal by an authorized editor of Chula Digital Collections. For more information, please contact ChulaDC@car.chula.ac.th.

Original article

Anatomical feature and early outcomes of endovascular aneurysm repair from King Chulalongkorn Memorial Hospital

Kritaya Kritayakirana^{a,*}, Natawat Narueponjirakul^b, Apinan Uthaipaisanwong^b, Nantiskarn Chanpen^c, Punthita Aimsupanimitr^b

^aDepartment of Surgery, Faculty of Medicine, Chulalongkorn University, Bangkok, Thailand

^bDepartment of Surgery, King Chulalongkorn Memorial Hospital, Bangkok, Thailand

^cDepartment of Radiology, King Chulalongkorn Memorial Hospital, Bangkok, Thailand

Background: Many studies have evaluated anatomy of infrarenal abdominal aortic aneurysm (AAA) and outcomes after endovascular abdominal aneurysm repair (EVAR) but mostly in non-Asian populations. The objective of this study was to evaluate anatomical features and early outcomes for EVAR in the Thai population in a single-center experience.

Objective: Treatment of AAA with suitable anatomy has been trending towards EVAR. This study aimed to analyze anatomical features and early outcomes of EVAR in Thai population at King Chulalongkorn Memorial Hospital (KCMH).

Methods: Retrospective review of 82 patients who underwent EVAR since January 2012 to December 2016. The medical records were analyzed for demographic data, anatomical features of AAA and outcomes in 30 days.

Results: Presentations were asymptomatic 38 cases (46.0%), symptomatic 19 cases (23.0%), ruptured AAA 13 cases (16.0%), and mycotic aneurysm 12 cases (15.0%). Anatomical features of the neck and aortic aneurysms in all groups were similar. Overall mortality was found 7 cases (8.5%). The ruptured group had a significantly higher mortality rate 4 cases (30.0%).

Conclusion: Anatomical features of AAA at KCMH were similar to other Asian populations. Early outcome of EVAR in asymptomatic, symptomatic, and mycotic aortic aneurysm was good. Thirty-day mortality was higher in ruptured AAA patients. Emergency and urgency conditions to treat AAA did not affect procedure-related complications. Iliac limb stent graft occlusion tends to occur in distal landing zone in the external iliac artery.

Keywords: Abdominal aortic aneurysm, anatomical feature, Asian population, endovascular aneurysm repair.

Treatment of infrarenal abdominal aortic aneurysm (AAA) has shifted towards endovascular abdominal aneurysm repair (EVAR) over the past two decades since the first report from Parodi JC, *et al.* in 1991.⁽¹⁾ EVAR is increasingly used for elective repair and other indications such as ruptured AAA⁽²⁾ and mycotic aortic aneurysm.⁽³⁾ Many studies have evaluated the anatomy of AAA and outcomes after EVAR,⁽⁴⁾ but mostly in non-Asian populations. The objective of this study was to evaluate anatomical features and early outcomes

for EVAR in the Thai population in a single-center experience.

Materials and methods

Symptomatic AAA patient was defined as patient presenting with abdominal or back pain without evidence of rupture from imaging.⁽⁵⁾

Ruptured AAA (rAAA) patient was defined as an AAA with evidence of the Presence of blood or hematoma outside the aneurysm wall (abdominal aorta, common iliac artery, or both) on computed tomography.⁽²⁾

Mycotic aortic aneurysm was defined as a patient with clinical evidence of infection or positive blood culture. In cases with negative blood culture, the diagnosis was confirmed by characteristics on radiologic appearance (rapidly growing or saccular aneurysm).⁽⁶⁻⁸⁾

*Correspondence to: Kritaya Kritayakirana, Department of Surgery, Faculty of Medicine, Chulalongkorn University, Bangkok 10330, Thailand.

E-mail: kritaya.k@chula.ac.th

Received: November 5, 2019

Revised: February 3, 2020

Accepted: March 15, 2020

Ninety-one patients who underwent EVAR from January 2012 to December 2016 in the Vascular Unit, Department of Surgery, King Chulalongkorn Memorial Hospital (KCMH) were retrospectively reviewed. Nine patients were excluded from the study due to fenestrated endovascular aneurysm repair (4 cases), reintervention from previous EVAR from outside hospitals (3 cases) and lack of data (2 cases). The patients were classified into four groups following indications for EVAR as asymptomatic, symptomatic, ruptured and mycotic aortic aneurysm.

Primary outcomes of this study were anatomical features, 30-day mortality, systemic and procedure related complications and mortality. Secondary outcomes were operative time, intensive care unit (ICU) and length of stay. Risk factors associated with each complication were analyzed. Demographic and clinical characteristics of patients was analyzed with Cchi-square. Risk factors associated with complication and mortality were analyzed with univariate analysis and assessed using Mann-Whitney U test for continuous variables. Statistical analysis was performed with the statistical package for social sciences, version 22.0 (SPSS Inc, Chicago, Illinois, USA). A P -value ≤ 0.05 was considered significant difference.

Results

Patient mean age was 74.0 ± 9.0 years. Predominantly male, there were 65 cases (79.3%)

with hypertension as the most common co-morbidity as described in Table 1. Indications for EVAR were asymptomatic 38 cases (46.0%), symptomatic AAA 19 cases (23.0%), ruptured AAA 13 cases (16.0%), and mycotic aneurysm 12 cases (15.0%). Three cases had previous open aortic operation. The first case had delayed aortic dilatation after 10-year follow up. The two other cases had para-anastomosis pseudoaneurysm and saccular aneurysm, respectively. Graft configuration for EVAR were bifurcated graft 71 cases (87.0%), aorto uni-iliac (AUI) 7 cases (8.0%) and straight tube graft 5 cases (4.0%). Stent grafts that were used Zenith Flex® 51 cases (6.0%) and Endurant® II 31 cases (38.0%).

Outcomes in terms of intraoperative data and postoperative hospital and ICU length of stay are reported in Table 2. Operative times were longer in rAAA and more contrast was used but was not statistically significant among the groups. The estimated blood loss in rAAA group was significantly higher (1003.8 ml vs. 279.5 ml; $P \leq 0.001$). Intraoperative blood transfusions were also higher in ruptured group (3.0 unit vs. 0.2 unit; $P \leq 0.001$). In the postoperative period, the ruptured group had longer length of stay in ICU than asymptomatic group (3.6 days vs. 21.2 days; $P = 0.03$). For postoperative length of hospital stay, the rupture group had a longer period than elective group, however, it did not reach statistical significance (41.3 days vs. 11.4 days; $P = 0.088$).

Table 1. Demographic data and comorbidities.

	N (%) (38)	Asymptomatic (19)	Symptomatic (12)	Mycotic (13)	Rupture	P-value
Sex (male)	65 (79.3)	30 (78.3)	15 (78.9)	11 (91.7)	9 (69.2)	0.503
Age (years)	74.2 ± 9.0	75.0	75.5	68.6	75.2	0.721
Comorbidity						
Hypertension	61 (74.4)	31 (81.6)	13 (68.4)	10 (83.3)	7 (53.8)	0.048
Dyslipidemia	30 (36.6)	17 (44.7)	8 (42.1)	3 (25.0)	2 (15.4)	0.059
Ischemic heart disease	17 (20.7)	6 (15.8)	8 (42.1)	0 (0.0)	3 (23.1)	0.552
CKD (Cr > 2.0 mg/dl)	10 (12.2)	2 (5.3)	3 (15.8)	1 (8.3)	4 (30.8)	0.014
DM	9 (11.0)	2 (5.3)	2 (10.5)	3 (25.0)	2 (15.4)	0.241
COPD	8 (9.8)	5 (13.2)	1 (5.3)	0 (0)	2 (15.4)	0.840
CVD	8 (9.8)	3 (7.9)	3 (15.8)	2 (16.7)	0 (0)	0.296
CHF	6 (7.3)	1 (2.6)	3 (15.8)	2 (16.7)	0 (0)	0.555
ESRD	4 (4.9)	0 (0)	0 (0)	1 (8.3)	3 (23.1)	0.002

CKD: chronic kidney disease, DM: diabetes mellitus, COPD: chronic obstructive pulmonary disease, CVD: Cardiovascular disease, CHF: Chronic heart failure, ESRD: end stage renal disease.

Table 2. Intraoperative and postoperative data.

	Mean ± SD	Asymptomatic	Symptomatic	Mycotic	Rupture	P- value
Operative time (min)	157.0±60.0	160.0	146.3	145.0	181.5	0.221
Contrast dose (ml)	64.3±40.3	60.8	66.8	46.7	90.8	0.014
Estimated blood loss (ml)	367.4±476.8	279.5	258.9	200.0	1003.8	≤0.001
Intraoperative blood transfusion (unit)	0.7±1.6	0.2	0.4	0.2	3.0	≤0.001
ICU stay (days)	8.3±26.2	3.6	7.6	10.1	21.2	0.03
Postoperative hospital stay (days)	18.8±41.9	11.4	15.1	19.3	41.3	0.088

Aortic anatomical features are reported in Table 3. Anatomical features of the neck and aortic aneurysms in all groups were similar with an exception in mycotic patients who had smaller neck diameter (20.0 mm vs. 24.4 mm; $P = 0.009$) and distal aortic diameter (20.9 mm vs. 26.3 mm; $P = 0.022$) compared with asymptomatic group. Length of aorta from lowest renal artery to aortic bifurcation was also similar in all groups. Iliac length and diameter were slightly longer and larger in left common iliac artery but not statistically significant.

Mycotic aneurysms were 12 cases (15.0%). Mean age was 68.6 ± 13.7 (range 33 - 83) years old. Ten cases (83.0%) were male. Comorbidities were hypertension ($n = 10, 83.0\%$), diabetes mellitus (DM)

($n = 4, 33.0\%$), end stage renal disease (ESRD) ($n = 1, 8.3\%$), human immunodeficiency virus (HIV) ($n = 1, 8.3\%$). One case had coexisting ascending cholangitis due to common bile duct (CBD) stone. All cases had abdominal or back pain with computerized tomographic angiography (CTA) morphology as pseudo aneurysm. Other presenting symptoms were fever ($n = 9, 75.0\%$), diarrhea and arthritis. Mean leukocyte counts were $10,352 \pm 3,388$ per μl (range 5,410 - 18,450 per μl). Pathogens were identified in 7 cases (58.3%). Five cases had positive culture for Salmonella species, other pathogens were staphylococcus aureus and mycobacterium tuberculosis.

Table 3. Anatomical characteristic of EVAR patients.

	Mean ± SD	Asymptomatic (38)	Symptomatic (19)	Mycotic (12)	Rupture (13)	P- valve
Neck						
Diameter (mm)	23.7±4.8	24.4	25.5	20.0	22.6	0.244
Length (mm)	22.9±8.9	23.4	19.6	25.7	23.9	0.893
Angulation (degree)	48.5±27.2	49.4	54.6	31.3	53.5	0.754
Aneurysm						
Diameter (mm) distal aortic	59.4±13.3	59.2	62.3	53.9	60.5	0.808
Diameter (mm)	26.3±18.3	25.7	31.5	20.9	24.6	0.82
Length (mm)	110.8±16.6	111.0	114.6	109.4	106.2	0.26
Right common iliac artery						
Diameter (mm)	17.4±8.9	19.1	17.0	16.5	13.9	0.042
Length (mm)	38.0±12.9	38.9	35.6	40.3	36.7	0.812
Left common iliac artery						
Diameter (mm)	18.6±12.5	18.5	16.3	23.8	17.2	0.762
Length (mm)	39.3±14.5	39.4	35.5	44.8	39.9	0.705

Thirty-day morbidity and mortality are reported in Table 4. The mortality rate was statistically significant in rAAA group. The most common complication was acute kidney injury (AKI) in 13 cases (15.9%). AKI prevalence was statistically significant in mycotic and ruptured groups comparing to asymptomatic group. Abdominal compartment syndrome (ACS) occurred in 5 cases (6.1%); 4 cases were ruptured AAA; and, 1 case was symptomatic. All required decompressive laparotomy. One case developed spinal cord ischemia in symptomatic group. Other complications such as myocardial infarction and bowel ischemia also were reported. Myocardial infarction was higher in symptomatic group compared to asymptomatic group. Type Ia endoleak was observed in 9 cases (11.0%). One case was detected by CTA one week after EVAR and resolution of endoleak was achieved after undergoing aortic cuff extension. Eight cases were detected intraoperatively by angiogram. Three cases underwent immediate aortic cuff extension. Resolution of Ia endoleak were immediately achieved in two cases. The other five cases were managed by follow up CTA at 1 week after EVAR; 3 cases showed resolution of endoleak; and, 2 cases still had persistent Ia endoleak. One case of persistent endoleak underwent aortic cuff extension and another case denied reintervention.

Iliac limb stent graft occlusion occurred in 6 cases (7.3%). Five iliac limbs occluded from 22 limbs that landed in external iliac artery. One limb occluded from 60 limbs landing in the common iliac artery. Risk factors were cases that underwent distal landing zone in the external iliac artery ($P = 0.001$). The occurrence of iliac occlusion was reported from the immediate postoperative period until 2 weeks after EVAR. Five cases were treated by surgical intervention (femoro-femoral bypass). Another case was treated by endovascular intervention (balloon angioplasty).

Thirty-day overall mortality was 7 cases (8.5%) as described in Table 4. The ruptured group had higher 30-day mortality compared with elective group (30.8 vs. 2.6; $P < 0.05$). There was no difference in 30-day mortality for symptomatic group (5.3%; $P = 0.611$) and mycotic group (8.3%; $P = 0.383$) compared with elective group (Table 4).

Discussion

Demographic data of EVAR patients from KCHM was similar to other Asian populations. From the Korean EVAR Registry (KER)⁽⁴⁾, 87.1% of the patients were male with mean age of 74.8 ± 7.3 years with hypertension as the most common comorbidity (87.1%) which was comparable to 74.4% from our study.

Table 4. 30-day morbid and mortality in EVAR patients.

Complication	Number (%)	Asymptomatic (n = 38)	Symptomatic (n = 19)	P - valve	Mycotic (n = 12)	P - valve	Rupture (n = 13)	P - valve	P - value
Acute kidney injury	13 (15.9)	2 (5.3)	2 (10.5)	0.463	5 (38.5)	0.009	4 (30.8)	0.003	< 0.05
Abdominal compartment syndrome	5 (6.1)	0 (0)	1 (5.3)	0.154	0 (0)	..	4 (30.8)	< 0.05	< 0.05
Myocardial infarction	3 (3.7)	0 (0)	2 (11.8)	0.042	0 (0)	..	1 (7.7)	0.842	0.16
Bowel ischemia	2 (2.4)	0 (0)	1 (5.3)	0.154	0 (0)	..	1 (7.7)	0.842	0.36
Spinal cord ischemia	1 (1.2)	0 (0)	1 (5.3)	0.154	0 (0)	..	0 (0)	..	0.34
Endoleak type									
Ia	9 (11)	3 (7.9)	4 (21.1)	0.154	2 (16.7)	0.315	0 (0)	0.438	0.25
Ib	2 (2.4)	2 (5.3)	0 (0)	0.309	0(0)	0.128	0 (0)	0.394	0.49
IIa	34 (41.5)	19 (50)	5 (26.3)	0.088	7 (53.8)	0.417	3 (25)	0.813	0.16
IIIa	1 (1.2)	0 (0)	0 (0)	..	0 (0)	..	1 (7.7)	0.842	0.14
Iliac limb occlusion	6 (7.3%)	3 (7.9)	1 (5.2)	0.741	2 (16.7)	0.375	0 (0)	..	0.83
Death	7 (8.5%)	1 (2.6)	1 (5.3)	0.611	1 (8.3)	0.383	4 (30.8)	0.003	< 0.05

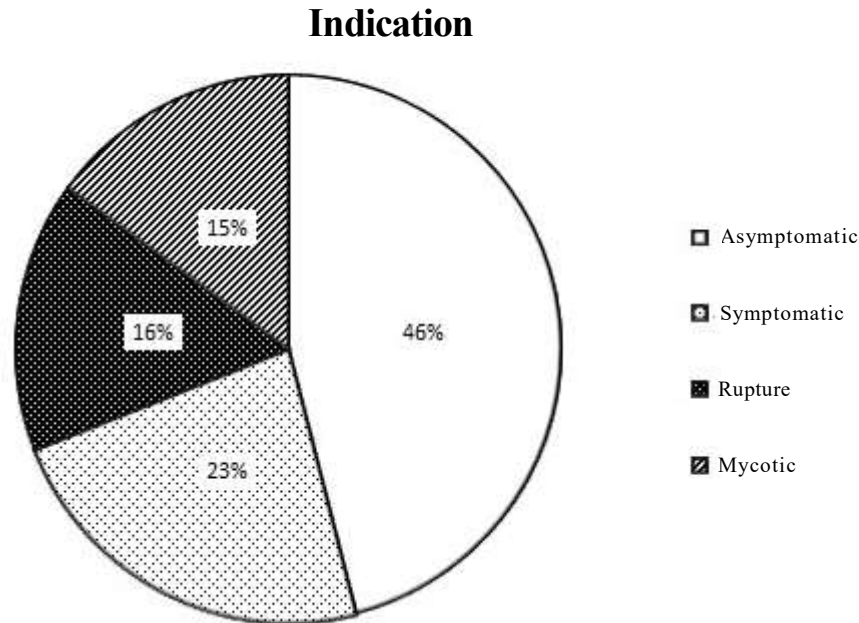


Figure 1. Indication for EVAR

Few studies have evaluated the anatomy of AAA and outcomes after EVAR in Asian populations. Regarding to anatomical features of AAA, aneurysmal diameter was almost the same as The KER (59.4 ± 13.3 mm vs. 57.2 ± 14.2 mm) in other previous studies. ⁽⁹⁾ In our study, we focused on patients who had suitable anatomy for standard EVAR. Anatomical features of neck of aneurysm; diameter 23.7 ± 4.8 mm, length 22.9 ± 8.9 mm and angulation 48.5 ± 27.2 degrees, were similar among Asian populations. Common iliac arteries, right and left, in our study were 17.4 ± 8.9 mm and 18.6 ± 12.5 mm in diameter, respectively. Length of right and left common iliac arteries were 39.3 ± 14.5 mm and 39.3 ± 14.4 mm. The anatomical features of CIA were also similar among the Asian population. ^(4, 9) We reported the mycotic aneurysm having small size of aorta. The neck diameter (20.0 mm vs. 24.3 mm; $P = 0.009$) and distal aortic diameter (20.9 mm vs. 26.3 mm; $P = 0.022$) was compared with asymptomatic group. Anatomical features are advantageous for the stocking of EVAR devices in hospitals due to increased cases of EVAR, however, since all current implant devices studied and designed for non-Asians with different anatomical features, future development of implant devices designed specifically for Asian populations should be considered.

In symptomatic group, many studies showed higher complication and mortality rates than in elective group. The American College of Surgeons National Surgical Quality Improvement Program showed a higher rate of postoperative myocardial infarction

(1.2% in asymptomatic group vs. 2.9% in symptomatic group; $P = 0.02$).⁽⁵⁾ Our study showed the same result. Myocardial infarction was the only complication that was higher in symptomatic group compared with elective group (0.0% vs. 11.8% ; $P = 0.042$). Symptomatic group may require more urgency to perform EVAR than elective group; therefore there is limited time to perform a complete preoperative cardiac evaluation and cardiac intervention prior to EVAR. The 30-day mortality rate in our study was the same between elective and symptomatic groups. Nowadays, EVAR is a new trend for treatment of mycotic aneurysm. ⁽³⁾ In our report, 25.0% of the patients had DM which was higher than 8.6% in nonmycotic patients but had no statistical significance. Technical success was 100.0% . All of our cases were nonfistula patients. Presentations were abdominal pain in almost all cases (83.0%) and other symptoms such as diarrhea. Pathogen identification in our data was 58.3% compared with other studies at $50.0 - 65.0\%$. ^(3, 6) Salmonella species were the most common pathogen. Staphylococcus aureus and mycobacterium tuberculosis were also reported as pathogens. Anatomical features in mycotic group had smaller aortic neck and distal aorta than other groups. This result may be due to most mycotic aneurysms having secular morphology which involves only the affected part. Outcomes were good with 30-day mortality in 1 case (8.3%) compared with prior results reported at 6.0% . ⁽⁶⁾ No postoperative requirement of explantation endovascular stent graft occurred.

Since EVAR is frequently used to treat ruptured AAA in cases with suitable anatomy, the ruptured group required more intraoperative blood transfusions and longer length of stay in the ICU when compared to the asymptomatic group. The mortality rate was higher. AKI was also higher. Abdominal compartment syndrome was reported in 30.8% of the ruptured group which was higher compared with the asymptomatic group.

Acute kidney injury was the most frequent systemic complication. Current data reported incidence of AKI was 2.9% – 18.0% in elective cases.^(10, 11) Our data showed AKI 15.9% of overall cases and 5.3% of elective cases. Incidence of AKI in mycotic and ruptured groups were 38.5% and 30.8%, respectively and were significantly higher than asymptomatic group. The overall 30-day mortality was high in our study (8.5%) because our data included elective and emergency conditions. In 38 elective cases, mortality occurred in only 1 case. The patient was an 81-year-old female with hypertension, ischemic heart disease and chronic kidney disease (Cr > 2 mg/dL). After EVAR, she developed acute kidney injury requiring hemodialysis and died in day 30 after EVAR. In symptomatic cases, our mortality rate (5.2%) was slightly higher when compared with 3.8% from the data of the American College of Surgeons National Surgical Quality Improvement Program.⁽⁵⁾ The rupture AAA patients had highest mortality of 30.7% which was near the 35.4% reported from the IMPROVE trial.⁽²⁾

Type Ia endoleak is typically corrected when recognized in the operating room. Bastos Goncalves F, *et al.* reported 8 of the 15 primary type-Ia endoleaks disappeared spontaneously on the first postoperative computed tomographic angiography (CTA) obtained within 1 week of EVAR.⁽¹²⁾ According to our data, Type Ia endoleak may resolve spontaneously. Type Ib endoleak was detected in 2 cases. One case was detected intraoperatively after EVAR with aortic tube graft for saccular aneurysm then converted to aorto-uni-iliac (AUI) with femero-femoral bypass. Another case was detected on computed tomographic angiography (CTA) postoperative at one week after EVAR. Then re-intervention with ipsilateral internal iliac artery embolization and iliac extension to landing in external iliac artery was performed successfully. Type II endoleak was reported at 20.0%.⁽⁸⁾ In our study, type II endoleak (41.5%) was observed on postoperative imaging. Although our study had high

incidence of type II endoleak, they did not required re-intervention at the early period.

Type III endoleak was detected in one case by postoperative day 1 duplex ultrasound at iliac limb in a mycotic aneurysm of left common iliac aneurysm case. Computer tomography 1 week after EVAR showed disappearance of endoleak, no further intervention was required. Iliac limb occlusion was reported at 2.3 - 3.7%.⁽⁸⁾ Faure *et al.* reported the predictors for iliac limb occlusion were distal landing zone on the external iliac artery, external iliac artery diameter ≤ 10 mm, and kinking.⁽¹³⁾ Daoudal A, *et al.* reported occurrence of distal landing zones in the external iliac artery (15.4% vs. 2.1%, $P = 0.006$).⁽¹⁴⁾ In our study, we reported iliac limb occlusion occurred in 6 cases (7.3%). Risk and risk factors were cases undergoing distal landing zone at external iliac artery ($P = 0.001$). Timing for detection or symptomatic occurrences were immediate postoperative period until 2 week after EVAR. Treatment of an occluded limb includes thrombectomy or lytic therapy with secondary endovascular or surgical intervention. One case was treated by balloon angioplasty. Four cases were treated with femorofemoral bypass. Another, case of AUI with femerofemoral bypass, was treated by axillofemoral bypass.

Our study has limitations due to the retrospective nature of the study and the decision to perform EVAR or open AAA repair was made by physician and not compared. We reported only early (30 days) outcomes and management.

Conclusion

Anatomical features of AAA in patients at KCMH were similar to other Asian populations. The mycotic aneurysm had smaller size of aorta. Early outcomes of EVAR in asymptomatic, symptomatic and mycotic aortic aneurysm were good. Thirty-day mortality was high in ruptured AAA patients. Complication such as AKI and myocardial infarction were lower in the asymptomatic group. Emergency and urgency conditions to treat AAA did not affect procedure related complications. Iliac limb stent graft occlusion tends to occur in distal landing zone in external iliac artery.

Acknowledgements

Part of the study was presented as a poster at the 18th Congress of Asian Society for Vascular Surgery and the 12th Asian Venous Forum 2017.

Conflicts of interest

The authors, hereby, declare no conflict of interest.

References

1. Parodi JC, Palmaz JC, Barone HD. Transfemoral intraluminal graft implantation for abdominal aortic aneurysms. *Ann Vasc Surg* 1991;5:491-9.
2. Investigators IT, Powell JT, Sweeting MJ, Thompson MM, Ashleigh R, Bell R, et al. Endovascular or open repair strategy for ruptured abdominal aortic aneurysm: 30 day outcomes from IMPROVE randomised trial. *BMJ* 2014;348:f7661.
3. Sorelius K, Wanhainen A, Furebring M, Bjorck M, Gillgren P, Mani K, et al. Nationwide study of the treatment of mycotic abdominal aortic aneurysms comparing open and endovascular repair. *Circulation* 2016;134:1822-32.
4. Kwon H, Lee DY, Choi SJ, Park KH, Min SK, Chang JH, et al. Anatomical features and early outcomes of endovascular repair of abdominal aortic aneurysm from a Korean Multicenter Registry. *Vasc Specialist Int* 2015;31:87-94.
5. Soden PA, Zettervall SL, Ultee KH, Darling JD, Buck DB, Hile CN, et al. Outcomes for symptomatic abdominal aortic aneurysms in the American College of Surgeons National Surgical Quality Improvement Program. *J Vasc Surg* 2016;64:297-305.
6. Kritpracha B, Premprabha D, Sungsiri J, Tantarattanapong W, Rookkapan S, Juntarapatin P. Endovascular therapy for infected aortic aneurysms. *J Vasc Surg* 2011;54:1259-65.
7. Clough RE, Black SA, Lyons OT, Zayed HA, Bell RE, Carrell T, et al. Is endovascular repair of mycotic aortic aneurysms a durable treatment option? *Eur J Vasc Endovasc Surg* 2009;37:407-12.
8. Moll FL, Powell JT, Fraedrich G, Verzini F, Haulon S, Waltham M, et al. Management of abdominal aortic aneurysms clinical practice guidelines of the European society for vascular surgery. *Eur J Vasc Endovasc Surg* 2011;41(Suppl 1):S1-58.
9. Cheng SW, Ting AC, Ho P, Poon JT. Aortic aneurysm morphology in Asians: features affecting stent-graft application and design. *J Endovasc Ther* 2004;11:605-12.
10. Zarkowsky DS, Hicks CW, Bostock IC, Stone DH, Eslami M, Goodney PP. Renal dysfunction and the associated decrease in survival after elective endovascular aneurysm repair. *J Vasc Surg* 2016;64:1278-85 e1.
11. Saratzis A, Nduwayo S, Sarafidis P, Sayers RD, Bown MJ. Renal function is the main predictor of acute kidney injury after endovascular abdominal aortic aneurysm repair. *Ann Vasc Surg* 2016;31:52-9.
12. Bastos Goncalves F, Verhagen HJ, Vasanthanathan K, Zandvoort HJ, Moll FL, van Herwaarden JA. Spontaneous delayed sealing in selected patients with a primary type-Ia endoleak after endovascular aneurysm repair. *Eur J Vasc Endovasc Surg* 2014;48:53-9.
13. Faure EM, Becquemin JP, Cochenec F, collaborators E. Predictive factors for limb occlusions after endovascular aneurysm repair. *J Vasc Surg* 2015;61:1138-45 e2.
14. Daoudal A, Cardon A, Verhoye JP, Clochard E, Lucas A, Kaladji A. Sealing zones have a greater influence than iliac anatomy on the occurrence of limb occlusion following endovascular aortic aneurysm repair. *Vascular* 2016;24:279-86.