

4-1-2020

## Total thyroidectomy as a treatment of acute suppurative thyroiditis

Pasurachate Samorn

Follow this and additional works at: <https://digital.car.chula.ac.th/clmjournal>



Part of the [Medicine and Health Sciences Commons](#)

---

### Recommended Citation

Samorn, Pasurachate (2020) "Total thyroidectomy as a treatment of acute suppurative thyroiditis," *Chulalongkorn Medical Journal*: Vol. 64: Iss. 2, Article 11.

DOI: <https://doi.org/10.58837/CHULA.CMJ.64.2.11>

Available at: <https://digital.car.chula.ac.th/clmjournal/vol64/iss2/11>

This Case Report is brought to you for free and open access by the Chulalongkorn Journal Online (CUJO) at Chula Digital Collections. It has been accepted for inclusion in Chulalongkorn Medical Journal by an authorized editor of Chula Digital Collections. For more information, please contact [ChulaDC@car.chula.ac.th](mailto:ChulaDC@car.chula.ac.th).

## Case report

# Total thyroidectomy as a treatment of acute suppurative thyroiditis

Pasurachate Samorn\*

*Department of Surgery, King Chulalongkorn Memorial Hospital, Faculty of Medicine, Chulalongkorn University, Bangkok, Thailand*

---

Acute suppurative thyroiditis is a rare life-threatening disease. The patient presented in this clinical report was immunocompromised and poorly responded to medical interventions. She subsequently needed surgical treatment. The selected procedure was total thyroidectomy because the abscess was multiloculated and distributed in both lobes of the thyroid gland.

**Keywords:** Acute suppurative thyroiditis, thyroid abscess, thyroidectomy.

---

Acute suppurative thyroiditis is a rare disease. It is caused by congenital anatomical abnormality, hematogenous spreading, underlying thyroid disorders, penetrating neck trauma or post-procedural infection. Patients usually present with fever and neck pain which is similar to deep neck infection. Rarely, this disease causes vocal cord paralysis resulted from recurrent laryngeal nerve involvement.<sup>(1)</sup>

Immunodeficiency, especially acquired immune-deficiency syndrome (AIDS), increases risk and severity of the disease. It also results in abscess caused by opportunistic pathogens those are not susceptible to given antibiotics.<sup>(2)</sup>

Delay in diagnosis and treatment increased risk of life-threatening condition including airway obstruction and septicemia. Ultrasonography helps physician to distinguish this disease from other neck infections and initially determines the severity. Its treatment is varying from antibiotics only to thyroidectomy depending on the severity of the disease. This describes a patient with AIDS who had vocal cord paralysis and needed to undergo total thyroidectomy from this condition.<sup>(1)</sup>

## Case report

A 46 year-old-female patient who had been diagnosed as human immunodeficiency virus HIV

positive and admitted to King Chulalongkorn Memorial Hospital because of a painful neck mass. The thyroid function test resulted in thyroid stimulating hormone was lower than normal at 0.01  $\mu$ IU/mL, elevated free T4 at 2.26 pg/mL and normal free T3 at 3.45 ng/dL. Her CD4 count was 72 cell per cubic millimeter. Ultrasonography revealed multiloculated lesions in both lobes of the thyroid gland. Aspiration of the largest cyst returned pus. Gram-negative bacilli found in Gram stain and the attending physician immediately started intravenous Ceftriaxone.

Later, culture for organism resulted in group D Salmonella which was sensitive to the given antibiotic. But her condition did not respond well, and the thyroid mass was continuously growing. A week after the admission, the physician requested computed tomography of the neck, and it showed heterogeneously enhancing thyroid masses with mixed solid-cystic component and internal septation. The most significant mass was 11.8 cm in diameter and mildly compressed the trachea as shown in Figure 1. The intervention radiologist performed ultrasonography-guided aspiration and left an 8 Fr. catheter in the abscess on that day, the abscess became smaller after the procedure but returned to the previous size in 3 days, and the patient developed hoarseness of voice. Fiber-optic laryngoscopy diagnosed she had left vocal cord paralysis, and she difficultly breathed when she was lying down. The intervention radiologist found from ultrasonography that the catheter drained well, but there were other enlarging abscesses.

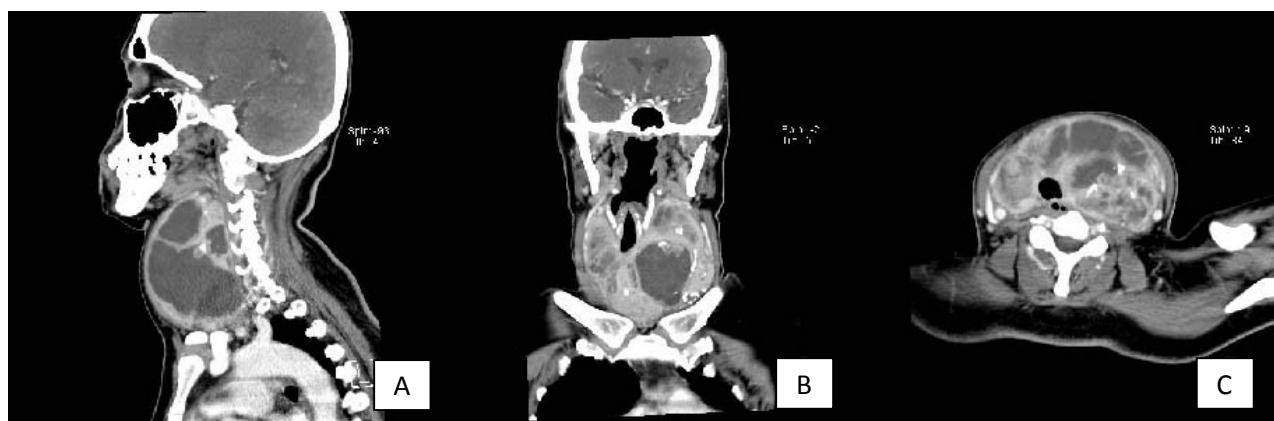
---

\*Correspondence to: Pasurachate Samorn, Department of Surgery, King Chulalongkorn Memorial Hospital, Faculty of Medicine, Chulalongkorn University, Bangkok 10330, Thailand. Email : Pasurachate.S@chula.ac.th

Received: March 11, 2019

Revised: June 12, 2019

Accepted: July 14, 2019



**Figure 1.** Computed tomography of the neck showed multiloculated thyroid abscess.

The attending physician consulted our team about surgical planning for this patient who did not respond to medical treatment and, we decided to perform total thyroidectomy urgently since the thyroid abscess was multiloculated and distributed all over both lobes. Intra-operatively, the thyroid gland was severely inflamed and adhered to the adjacent tissues. The right recurrent laryngeal nerve could be easily identified and preserved. The left one clung to the abscess, but it was also protected. We were not able to locate any parathyroid gland because of inflammation of the tissue, and we had to ligate both of inferior thyroid arteries very proximally.

The operative blood loss was 200 ml. A vacuum drain was placed in the surgical space and removed four days later. The anesthesiologist extubated the patient immediately after the procedure, and she was observed in the surgical ICU for 20 hours.

She recovered well but suffered postoperative hypoparathyroidism, and got oral Calcium carbonate and Calcitriol. The attending physician changed intravenous Ceftriaxone to oral Sulfamethoxazole-Trimethoprim. There was no other complication. The patient was discharged ten days after the operation.

The pathologist reported abscesses and organizing thyroiditis of both lobes, and five-millimeter papillary carcinoma of the right portion.

Her voice became better when she came to follow up, and fiber-optic laryngoscopy demonstrated improvement of the left vocal cord movement.

## Discussion

Suppurative thyroiditis is a rare condition with incidence at 0.1 – 0.7% of thyroid disease because the thyroid gland is very low susceptibility to infection.<sup>(1)</sup> Immunodeficiency is one of the risks in

addition to anatomic abnormalities and previous thyroid surgery.<sup>(2)</sup> Most of the clinical presentations are fever, neck pain or painful neck mass.<sup>(1, 2)</sup>

Important investigations consist of two parts, microbiology and imaging. Aspiration of the abscess to get some specimen for Gram stain and culture will guide the physician selecting a proper antibiotic. Initial imaging modality of choice is ultrasonography since it provides significant information about the disease such as multi-loculated abscess which is tough to treat with percutaneous aspiration or drainage. Computed tomography (CT) is rarely necessary as the first radiologic investigation, but it is helpful in patients who do not improve after receiving medical treatment. CT is also able to show airway compression and substernal extension which is the limitation of ultrasonography. There is limited use of magnetic resonance imaging (MRI). It is useful in patients who are suspected anatomical abnormality like pyriform sinus fistula.<sup>(3)</sup>

The dominant causative organism (39 percent) in western countries are Gram-positive aerobes, but Gram-negative aerobes especially *Salmonella* species are more common in developing countries. Ceftriaxone or fluoroquinolones is the initial antimicrobial therapy if an identified organism is Gram-negative.<sup>(1)</sup>

In most cases, the patients respond to proper antimicrobial therapy after aspiration of the abscess.<sup>(4)</sup> Rarely, the patients need more aggressive surgical interventions such as open drainage, lobectomy or thyroidectomy. Open drainage of the abscess is an ideal operation if the lesion is feasible because it is low risk for recurrent laryngeal nerve injury and postoperative hypoparathyroidism, but it cannot remove multiloculated abscess or bilateral disease well.<sup>(5)</sup>

Percutaneous catheter drainage is an alternative to surgical drainage and its efficacy is comparable to the open procedure. Their limitation for multiloculated disease is the same.<sup>(6)</sup>

Lobectomy is a more radical option for unilateral disease which is multiloculated, and thyroidectomy plays a part in bilateral lesions. These operations are more difficult in acute suppurative thyroiditis since the procedures always encounter area with inflammation. There are higher risks of recurrent laryngeal nerve injury and postoperative hypoparathyroidism.<sup>(7)</sup>

In summary, thyroidectomy for acute suppurative thyroiditis is the last option of treatment in patients who do not respond well to medical interventions because the procedure endangers the patients to suffer from long-term complications including recurrent laryngeal nerve injury and permanent hypoparathyroidism.

## References

1. Paes JE, Burman KD, Cohen J, Franklyn J, McHenry CR, Shoham S, et al. Acute bacterial suppurative thyroiditis: a clinical review and expert opinion. *Thyroid* 2010;20:247-55.
2. N'gattia KV, Kacouchia NB, Vroh BT, Kouassi-Ndjeundo J. Suppurative thyroiditis and HIV infection. *Eur Ann Otorhinolaryngol Head Neck Dis* 2015;132:371-2.
3. Masuoka H, Miyauchi A, Tomoda C, Inoue H, Takamura Y, Ito Y, et al. Imaging studies in sixty patients with acute suppurative thyroiditis. *Thyroid* 2011;21:1075-80.
4. Ilyin A, Zhelonkina N, Severskaya N, Romanko S. Nonsurgical management of thyroid abscess with sonographically guided fine needle aspiration. *J Clin Ultrasound* 2007;35:333-7.
5. Singla M, Gaba S, Bhinder K. Suppurative thyroiditis. *Clin Case Rep* 2018;6:951-2.
6. Ravi KS, Bhat VS. Outcome of ultrasound guided closed drainage of acute suppurative thyroid abscess as definitive treatment modality. *Int J Otorhinolaryngol Head Neck Surg* 2017;3:486-90.
7. Su DH, Huang TS. Acute suppurative thyroiditis caused by *Salmonella typhimurium*: a case report and review of the literature. *Thyroid* 2002;12:1023-7.