

7-1-2020

## Outcomes of hyperbaric oxygen therapy for central retinal artery occlusion in Somdech Phra Pinklao Hospital (P. 307)

Chatchadaporn Kraisornpornsan

Thosporn Vimolkej

Napang Kedkovid

Follow this and additional works at: <https://digital.car.chula.ac.th/clmjjournal>



Part of the [Medicine and Health Sciences Commons](#)

---

### Recommended Citation

Kraisornpornsan, Chatchadaporn; Vimolkej, Thosporn; and Kedkovid, Napang (2020) "Outcomes of hyperbaric oxygen therapy for central retinal artery occlusion in Somdech Phra Pinklao Hospital (P. 307)," *Chulalongkorn Medical Journal*: Vol. 64: Iss. 3, Article 11.

Available at: <https://digital.car.chula.ac.th/clmjjournal/vol64/iss3/11>

This Article is brought to you for free and open access by the Chulalongkorn Journal Online (CUJO) at Chula Digital Collections. It has been accepted for inclusion in Chulalongkorn Medical Journal by an authorized editor of Chula Digital Collections. For more information, please contact [ChulaDC@car.chula.ac.th](mailto:ChulaDC@car.chula.ac.th).

## Original article

# Outcomes of hyperbaric oxygen therapy for central retinal artery occlusion in Somdech Phra Pinklao Hospital

Chatchadaporn Kraisornpornsan<sup>a</sup>, Thosporn Vimolkej<sup>b,\*</sup>, Napang Kedkovid<sup>c</sup>

<sup>a</sup>*Institute of Maritime, Naval Medical Department, Royal Thai Navy, Bangkok, Thailand*

<sup>b</sup>*Preventive and Social Medicine, Faculty of Medicine, Chulalongkorn University, Bangkok, Thailand*

<sup>c</sup>*Department of Ophthalmology, Somdech Phra Pinklao Hospital, Bangkok, Thailand*

**Background:** Central retinal artery occlusion (CRAO) is an emergency condition of the eye. Patients with CRAO will present with painless sudden visual loss. The condition requires timely management for reversal of vision. Currently, there are no approved treatments of choices that provide highly reliable outcome. Examples of current available treatments are hyperbaric oxygen therapy (HBOT), decreasing intraocular pressure (IOP), vasodilatation and thrombolytic agent. HBOT is recommended for acute non-arteritis CRAO by the Undersea and Hyperbaric Medical Society (UHMS) and the European Committee for Hyperbaric Medicine.

**Objective:** To evaluate the outcome of central retinal artery occlusion (CRAO) treatment by hyperbaric oxygen therapy (HBOT) and its complications at the Somdech Phra Pinklao Hospital.

**Method:** This is a retrospective descriptive study. The subjects included forty-one patients with central retinal artery occlusion (CRAO) who received hyperbaric oxygen therapy (HBOT). Data was collected retrospectively from medical records and analyzed using Fisher's exact test to compare the visual acuity between pre-HBOT and post final HBOT.

**Results:** The finding showed that 19 (46.3%) patients with CRAO had visual improvement after HBOT. Fifteen (60.0%) of patients underwent HBOT within 24 hours following visual loss and 4 (25.0%) of patients underwent HBOT after 24 hours following visual loss had improved visual outcomes. Moreover, 12 patients (29.3%) experienced complications from HBOT; 11 patients (26.8%) with the middle ear barotrauma and 1 patient (2.4%) with pulmonary oxygen toxicity.

**Conclusion:** HBOT is an effective treatment for non-arteritis CRAO. Visual acuity was improved by HBOT especially in those who were treated with HBOT within 24 hours from the visual loss onset.

**Keywords:** Acute central retinal artery occlusion, hyperbaric oxygen therapy, acute visual loss.

Central retinal artery occlusion (CRAO) is an ophthalmological condition that is found in the elderly patients aged 60 – 64 years. The incidence is estimated to be 0.85 in 100,000 people.<sup>(1)</sup> Central retinal artery occlusion is mainly caused by occlusion of retinal artery (emboli) or arteritis. It is characterized by painless sudden visual loss without any precedent symptoms and visual acuity usually decreases to finger counting or light perception level. Fundoscopic examination found narrower retinal vessel, slightly

pale retina due to ischemia, and darker macula (cherry red spot).<sup>(2)</sup> The retina consumes oxygen at the rate of 13 ml / 100 gm / min, hence is considered as an organ with the highest oxygen consumption in the body and highly sensitive to ischemia.<sup>(3)</sup> Previous studies in animal models demonstrated that after retina artery was completely occluded for 90 – 100 minutes, there would be an irreversible damage of retina tissue.<sup>(4)</sup> Acute retinal artery occlusion is ophthalmic emergency and considered to be “stroke of the eyes”. Risk factors of the central retinal artery occlusion are hypertension, diabetes mellitus, dyslipidemia and abnormal blood clotting; including platelet and factor abnormalities, using oral contraceptive, sickle cell anemia, autoimmune diseases such as lupus or giant cell arteritis.<sup>(1)</sup> Currently there is no treatment of choice for CRAO. However, there are various treatment modalities, for examples; hyperbaric oxygen therapy,

\*Correspondence to: Thosporn Vimolkej, Department of Preventive and Social Medicine, Faculty of Medicine, Chulalongkorn University, Bangkok 10330, Thailand.

E-mail: vthospor@yahoo.com

Received: April 18, 2019

Revised: April 30, 2019

Accepted: June 14, 2019

reducing intraocular pressure by intraocular pressure-lowering drugs or paracentesis and blood rheology by Pentoxifylline or carbogen inhalation.<sup>(2)</sup> Hyperbaric oxygen therapy (HBOT) is one of the treatment options for CRAO according to American academy of ophthalmology recommendation.<sup>(5)</sup> HBOT increases oxygen partial pressure in the choroid layer. This resulted in extensively oxygen diffusion from choroid layer to adjacent affected retina layer.<sup>(6)</sup> In 2008, the Undersea and Hyperbaric Medical Society (UHMS) recognized Hyperbaric Oxygen Therapy as one of the treatments for acute central retinal artery occlusion. The American Heart Association regarded HBOT for CRAO as Level IIb from retrospective case series showing fair to good results but no prospective randomized controlled trials. HBOT is considered to be a safe, acceptable and reliable treatment despite lack of the level 1 empirical evidence of treatment. No harmful effect has been reported and visual outcomes are improved and no other treatments are considered as effective when compared to HBOT.<sup>(7)</sup> HBOT is a safe, non-invasive intervention that should be considered in CRAO patients, especially when treatment is given timely and properly. The aim of this study was to evaluate the treatment outcomes of CRAO with HBOT and study the complications occurred during HBOT at Somdech Phra Pinklao Hospital.

### Materials and methods

This is a retrospective descriptive study. The target population included the CRAO patients treated by HBOT at Somdech Phra Pinklao Hospital, Naval Medical Department from October 1, 2015 to June 30, 2018. The data was collected retrospectively from medical records. Statistical analysis was done by the Statistical Package for the Social Science (SPSS) v.22 software. This research has been approved by the Central Research Ethics Committee, Naval Medical Department, Project Code RP022 / 61 and the Central Research Ethics Committee, Faculty of Medicine, Chulalongkorn University, IRB No. 480/61.

### Inclusion criteria

The non-arteritis permanent CRAO patients with complete HBOT were included in this study. The visual loss onset, baseline characteristics, HBOT protocol, pre-HBOT and post-HBOT visual acuity, and complications (if any) from medical data were recorded.

### Exclusion criteria

Arteritis CRAO, branch retinal artery occlusion (BRAO), CRAO with patent cilioretinal artery, iatrogenic CRAO, combined CRAO and central retinal vein occlusion (CRVO), CRAO patients with severe risks or underlying diseases that were at risk of complications from HBOT, for examples; untreated pneumothorax, acute severe bronchospasm, hypertensive urgency or hypertensive emergency were excluded.

### Samples and Selection

From 61 cases of patients with retinal artery occlusion receiving HBOT; 41 subjects were included in the study. 20 subjects were excluded as following; 3 arteritis CRAO, 6 iatrogenic CRAO, 2 BRAO, 2 combined CRAO and CRVO, 3 CRAO with patent cilioretinal artery, 2 CRAO with high risk of complications from HBOT, 2 CRAO with incomplete HBOT sessions.

### Results

#### Baseline characteristics of the patients

There are sixty-one patients with CRAO treated with HBOT and 20 patients were excluded. Demographically, of a total of 41 patients, they were 22 females (58.5%) and 17 males (41.5%). The median interval time from the onset of visual loss to HBOT was 18 hours (8.00, 31.50), the minimum time to HBOT was 3 hours and the maximum time to HBOT was 504 hours. Categorized by time to HBOT; 25 patients underwent HBOT within 24 hours following visual loss (early group) with the median interval time from visual loss to HBOT of 9 hours (min 3 - max 24); 15 females (60.0%) and 10 males (40.0%) while 16 patients underwent HBOT after 24 hours following visual loss (late group) with median interval time from visual loss to HBOT of 37.5 hours (min 26 - max 504); 9 females (56.3%) and 7 males (43.8%). The average age of all patients was 64.5 years (SD = 13.1); the youngest was 30 years old and the oldest was 82 years old. In the early group, the average age of the patients were 62.2 years (SD = 14.3) while the late group had an average age of 67.6 years (SD = 10.8). Both groups were comparable in age characteristic. Regarding the side of the eye with CRAO, 26 cases (63.4%) developed CRAO in the right eye and 15 cases (36.6%) in the left eye. In the early group, 18 cases (72.0%) developed CRAO in the right eye and 7 cases (28.0%)

in the left eye, while in the late group, 8 cases (50.0%) developed CRAO in the right eye and 8 cases (50.0%) in the left eye. There were 32 cases (78.0%) with underlying disease at the time CRAO was diagnosed, of which 21 cases were in the early group and 12 cases in the late group. Most common underlying diseases were hypertension (28 cases, 87.5%), dyslipidemia (14 cases, 43.8%), diabetes mellitus (8 cases, 25.0%) and other chronic diseases; such as chronic kidney disease, coronary artery disease, heart arrhythmias (17 cases, 53.1%). On the subject of smoking, 38 cases (92.7%) were non-smokers and 3 cases (7.3%) were smokers. In the early group, there were 24 cases (96.0%) of non-smokers and 1 case (4.0%) of smoker. In the late group, there were 13 cases (81.3%) of non-smokers and 3 cases (87.5%) of smokers, as shown in Table 1.

**Treatment information on patients with CRAO**

In term of the medical treatment before HBOT, there were 25 (61.0%) patients who received initial treatments by the ophthalmologists before their

referral for HBOT. There were 12 cases (48.0%) in the early group and 4 cases (25.0%) in the late group who had not received any initial treatments. Regarding the types of treatments given by the doctors before HBOT; there were anterior chamber paracentesis (9 cases, 10.0%), ocular massage (7 cases, 17.1%), oral acetazolamide (5 cases, 12.2%), rt-PA (2 cases, 4.9%), and 1 case each received Aspirin, Bevacizumab, Enoxaparin, Brimonidine and Timolol eye drops (2.4%). About half of all cases (21 cases, 51.2%) had received normobaric oxygen therapy with 13 cases (52.0%) were in the early group while 8 cases (50.0%) were in the late group. Average treatment of HBOT was 8 sessions, minimum treatment was 1 session and maximum treatments were 39 sessions, with an average of 9 sessions in the early group and 8 sessions in the late group. Initial maximum pressure of hyperbaric oxygen therapy was 2.8 atmosphere absolute (ATA) in 39 patients (95.1%) with 24 cases (96.0%) in the early group and 15 cases (93.8%) in the late group, as shown in Table 2.

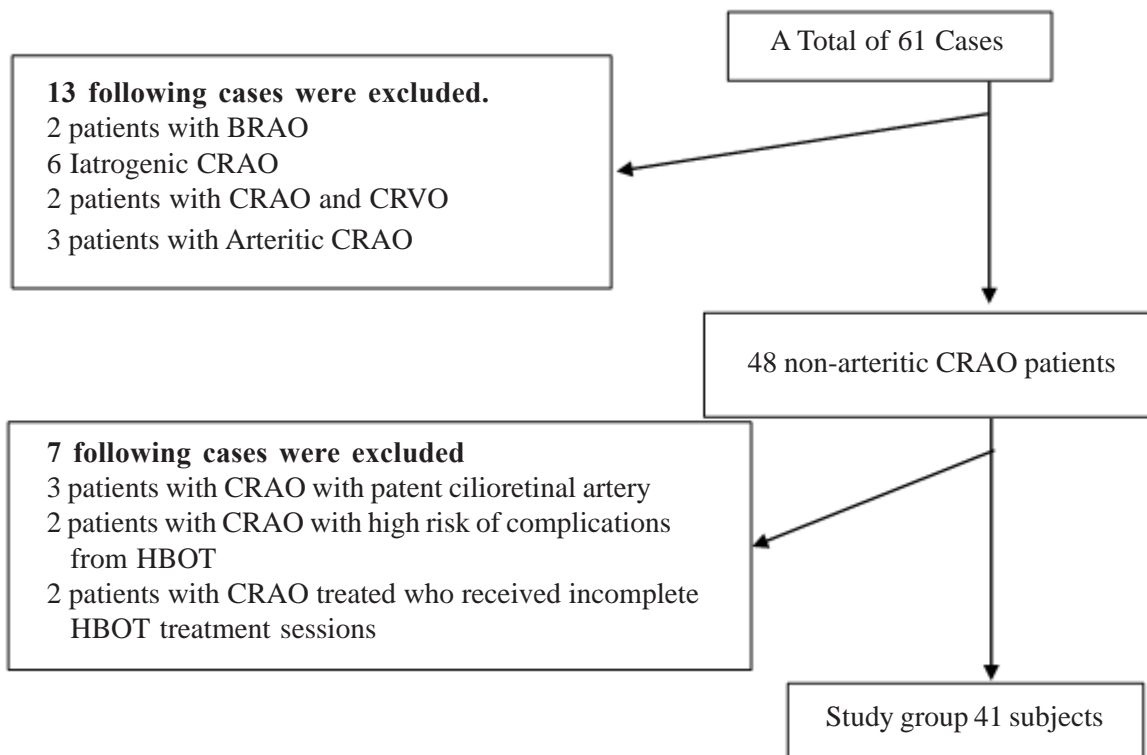


Figure 1. Sample selection by inclusion and exclusion criteria.

**Table 1.** Baseline characteristics of the patients.

Data	Onset within 24 hours (n = 25) (%)	Onset greater than 24 hours (n = 16) (%)	Total (n = 41) (%)
<b>Sex</b>			
Male	10 (40.0%)	7 (43.8%)	17 (41.5%)
Female	15 (60.0%)	9 (56.3%)	22 (58.5%)
<b>Age (Year)</b>			
Mean ± SD	62.2 ± 14.3	67.6 ± 10.8	64.5 ± 13.1
Max - Min	30 - 82	4 - 82	30 - 82
<b>The side of affected eye</b>			
Right eye	18 (72.0%)	8 (50.0%)	26 (63.4%)
Left eye	7 (28.0%)	8 (50.0%)	15 (36.6%)
<b>Initial time of visual loss to HBOT</b>			
Median (Q1, Q3)	9 (6.0, 16.0)	37.5 (29.3, 96.0)	18 (8.0, 31.5)
Min - Max	3 - 24	26 - 504	3 - 504
<b>Underlying diseases</b>			
Yes	4 (16.0%)	4 (25.0%)	9 (22.0%)
No	21 (84.0%)	12 (75.0%)	32 (78.1%)
Hypertension	17 (81.0%)	11 (91.7%)	28 (87.5%)
Dyslipidemia	10 (47.6%)	4 (33.3%)	14 (43.8%)
Diabetes	4 (19.1%)	4 (33.3%)	8 (25.0%)
Other diseases	14 (66.7%)	3 (25.0%)	17 (53.1%)
<b>Smoking history</b>			
Smoker	1 (4.0%)	3 (18.8%)	3 (7.3%)
Non-smoker	24 (96.0%)	13 (81.3%)	38 (92.7%)

**Table 2.** Treatment information on patients with CRAO.

Data	Onset within 24 hours (n = 25) (%)	Onset greater than 24 hours (n = 16) (%)	Total (n = 41) (%)
<b>Initial treatment by Ophthalmologist</b>			
Yes	12 (48.0%)	4 (25.0%)	16 (39.0%)
No	13 (52.0%)	12 (75.0%)	25 (61.0%)
<b>Type of medication</b>			
Anterior chamber paracentesis	7 (28.0%)	2 (12.5%)	9 (22.0%)
Ocular massage	6 (24.0%)	1 (6.4%)	7 (17.1%)
Oral Acetazolamide pill	4 (16.0%)	1 (6.3%)	5 (12.2%)
rt-PA	1 (4.0%)	1 (6.3%)	2 (4.9%)
Aspirin	1 (4.0%)	0 (0.0%)	1 (2.4%)
Bevacizumab	1 (4.0%)	0 (0.0%)	1 (2.4%)
Enoxaparin	1 (4.0%)	0 (0.0%)	1 (2.4%)
Brimonidine and Timolol ED	1 (4.0%)	0 (0.0%)	1 (2.4%)
0.5% Timolol ED	1 (4.0%)	0 (0.0%)	1 (2.4%)
HBO is given	13 (52.0%)	8 (50.0%)	21 (51.2%)
Average number of HBOT times	9	8	8
Min. - Max	1 - 33	3 - 39	1 - 39
<b>Hyperbaric pressure at initial treatment</b>			
2.0 ATA	1 (4.0%)	0 (0.0%)	1 (2.4%)
2.4 ATA	0 (0.0%)	1 (6.3%)	1 (2.4%)
2.8 ATA	24 (96.0%)	15 (93.8%)	39 (95.1%)

ATA (Atmosphere absolute pressure)

**Treatment outcomes of central retinal artery occlusion with HBOT**

Visual acuity (VA) was evaluated with the Snellen eye chart. If the patients could not read the Snellen eye chart, then low vision categories were used for evaluation i.e. counting fingers, hand movement (HM), light projection (PJ), light perception (PL), and no light perception. Clinically significant visual improvement was defined as improvement of reading Snellen chart at least 2 levels after discharge from the last HBOT session, for example, VA was HM before HBOT and VA was 1/60 after HBOT or VA was 6/60 before HBOT and 6/24 after HBOT were considered significant visual improvement. Overall there were 19 cases (46.3%) of improvement in VA after HBOT, with 15 cases (60.0%) in the early group and 4 cases (25.0%) in the late group. The average improvement of visual acuity was 2 levels, with an average of 3 levels visual improvement in the early group and an average of 1 level visual improvement in the late group, as shown in Table 3.

**Analysis of the relationship between relevant factors and treatment outcomes**

The relationship between the relevant factors and treatment outcomes were analyzed using Multiple

logistic regression to determine the crude odds ratio of the period of time from visual loss to HBOT intervention. The relationship between time from visual loss to HBOT intervention and treatment outcome was found. Group with undergoing HBOT within 24 hours following visual loss (early group) showed 4.5 times improved treatment outcomes, (95% CI = 1.1 – 18.0, Crude odds ratio = 4.5) when compared to those undergoing HBOT after 24 hours of visual loss (late group), as shown Table 4.

**Complications of HBOT**

In this study, complications from HBOT were found in 12 cases (29.3%) including middle ear barotrauma (11 cases, 26.8%), and pulmonary oxygen toxicity (1 case, 2.4%). There were 7 cases (28.0%) of middle ear barotrauma, 1 case (4.0%) of pulmonary oxygen toxicity in the early group and 4 cases (25.0%) of middle ear barotrauma in the late group. One middle ear barotrauma patient needed tympanoplasty, the others were given conservative treatments. The treatment for pulmonary oxygen toxicity was adjust treatment protocol to reduce pulmonary oxygen toxicity. None of them had any permanent damage or life-threatening conditions from HBOT, as shown in Table 5.

**Table 3.** Treatment outcomes of central retinal artery occlusion with HBOT.

Treatment outcome	Onset within 24 hours (n = 25) (%)	Onset greater than 24 hours (n = 16) (%)	Total (n = 41) (%)
Not improved	10 (40.0%)	12 (75.0%)	22 (52.7%)
Improved	15 (60.0%)	4 (25.0%)	19 (46.3%)
Average improved level vision	3	1	2
Min - Max	0 - 10	0 - 7	0 - 10

**Table 4.** The relationship between from the onset of visual loss to HBOT and treatment outcomes (in percentage).

Onset of visual loss	Improved	Not improved	Crude OR (95% CI)
Within 24 hours (n = 25)	15 (60.0%)	10 (40.0%)	4.5 (1.1 – 18.0)
After 24 hours (n = 16)	4 (25.0%)	12 (75.0%)	1.0



**Table 5.** Complications of HBOT among patients with CRAO by pathogenesis period.

Complications	Onset within 24 hours (n = 25) (%)	Onset greater than 24 hours (n = 16) (%)	Total
Middle ear barotrauma	7 (28.0%)	4 (25.0%)	11 (26.8%)
Pulmonary oxygen toxicity	1 (4.0%)	0 (0.0%)	1 (2.4%)
Total	8 (32.0%)	4 (25.0%)	12 (29.3%)

## Discussion

In this study, 19 (46.3%) of 41 CRAO patients at Somdech Phra Pinklao Hospital showed visual improvement outcomes after HBOT, of which 15 patients (60.0%) underwent HBOT within 24 hours following visual loss had an average of 3 level visual improvement while 4 patients (25.0%) underwent HBOT after 24 hours following visual loss had an average of 1 level visual improvement. The result was comparable with previous studies, Mark et al found improved treatment outcomes in 23 (74.2%) of 31 cases<sup>(8)</sup> while Hadanny et al. showed improvement by 67.2% in CRAO with HBOT.<sup>(9)</sup> There was also a relationship between time from visual loss to HBOT intervention and treatment outcomes. Patients undergoing HBOT within 24 hours following visual loss showed better treatment outcomes compared to those patients undergoing HBOT after 24 hours following visual loss. This result was consistent with a study from the Hennepin County Medical Center, Minneapolis, Minnesota, USA that lesser the time to HBOT the better visual acuity gains.<sup>(10)</sup>

The common underlying disease found in this study were hypertension, dyslipidemia and diabetes mellitus which concurred in the literature review that majority of CRAO were caused by platelet fibrin thrombi and emboli as a result of atherosclerotic disease. This risk factors had been found to be significantly more common in patients with CRAO than in the general population.<sup>(1)</sup>

Patients undergoing HBOT after 24 hours following visual loss had poor visual outcomes. The major restrictions were unrecognized decline vision in elderly and the limited number of hospitals providing HBOT services. Some patients in both groups also did not receive normobaric oxygen therapy prior transportation to HBOT department as a pre hyperbaric oxygen treatment resulted in delay HBOT session. This can be amended by knowledge sharing among health care personnel.

Other CRAO treatments are ocular massage, anterior chamber paracentesis, or carbogen inhalation.

None of them has been demonstrated to be as effective as observation in a high-level study. More aggressive treatment, such as thrombolysis or transluminal neodymium yttrium aluminium garnet (Nd:YAG) laser embolysis have accompanying risks and are controversial in the absence of a strong evidence-based recommendation.<sup>(11,12)</sup> Intra-arterial and intravenous thrombolytics have also been investigated<sup>(13,14)</sup> and still remains strong controversy regarding the best management strategy. The EAGLE study shown local intra-arterial fibrinolysis (visual improvement 57.1%) has similar efficacy as conservative standard treatment (visual improvement 60.0%) with significantly higher rate of adverse reaction (37.1%) and the EAGLE study investigators recommendation is not to use local intra-arterial fibrinolysis to treat patients with acute nonarteritic CRAO.<sup>(15)</sup>

The purposed role for hyperbaric oxygen in CRAO is an increase the partial pressure of oxygen delivery to ischemic tissue until spontaneous reperfusion occurs. Retinal circulation consists of dual blood supply from central retinal artery and choriocapillaris. When retinal artery is obstructed, increased oxygen partial pressure in choroidal arteries by HBOT will resulted in oxygen diffusion from outer retina supplied by choriocapillaris to affected inner layer of the retina formerly supplied by central retinal artery, enabling some degree of oxygen to ischemic retinal tissue.<sup>(6)</sup> Hyperoxic oxygen is well-known to cause vasoconstriction<sup>(16)</sup> and had led some authors theorized that there was a decrease in retinal oxygenation under hyperoxic conditions.<sup>(17)</sup> But this is not the case, retinal venous hemoglobin oxygen saturation has been shown to increase from 58.0% in room air to 94.0% when choriocapillaris is supplying enough oxygen to offset any decrease in oxygen supply caused by retinal vasoconstriction at elevated partial pressure of oxygen.<sup>(18)</sup> According to Henry's Law, the solubility of gas is directly proportionate to the pressure of the gas exerting above the surface of the solution,<sup>(19)</sup> and when blood oxygen level increases,

the oxygen passing from the choroid layer to the inner layer of the retina will rise. As the result, HBOT can efficiently maintain the level of vision in the patients with CRAO. Undersea and Hyperbaric Medicine Society suggested that CRAO with 8 – 24 hours of onset can be visual recovered by HBOT.<sup>(6)</sup> However, HBOT facilities in Thailand are limited to tertiary hospitals or large-scale private hospitals because of its cost and administration is necessarily needed to be provided by certificated specialists only. The referral system is therefore a very important concern to support patient accessibility to HBOT facility in a short period of time.

Hyperbaric oxygen therapy (HBOT) is beneficial in CRAO patients. However, there were complications of HBOT as well, for instances, pressure injury (barotrauma) to middle ear, nasal cavity, dental cavity, lungs, pulmonary and CNS oxygen toxicity. The most common complication found in this study group was middle ear barotrauma. In spite of it, the patient level of vision improved. Thus, the HBOT was decided to be continued. In addition, one of the patients with visual loss onset less than 24 hours presented with cough and heart burn after HBOT and was diagnosed with pulmonary oxygen toxicity, if cumulative lung exposure to oxygen measured in the Unit Pulmonary Toxicity Dose (UPTD) is  $\geq 1425$ , vital capacity is expected to be decreased by about 10.0%. In this case, the patient UPTD was 2350. The intervention schedule was adjusted to reduce the oxygen toxicity to the lungs. Therefore, it is important to have patients assessed by Diving Medical Officers before HBOT and during the follow-up period for complication detection before, during and after treatments. Once complications are detected, this will require multidisciplinary team to support in collaborative planning, assessments, and interventions for the best possible treatment outcome and mitigate all the complications.

This study has some limitations related to the fact that data were collected retrospectively and there was no control group. Regarding the strengths, this is the first study about CRAO and HBOT in Thailand. Nevertheless, future randomized control trials should be performed to elevate the optimal protocol of HBOT in CRAO patients.

### Conclusion

HBOT is an effective treatment for non-arteritis CRAO. The visual acuity can be improved by HBOT especially in those patients who receive treatment

within 24 hours of visual loss onset. There are a few patients who had minor complications from HBOT. HBOT is a safe, non-invasive intervention that should be considered in patients with non-arteritis CRAO.

### Acknowledgements

The authors gratefully acknowledge the nurses and medical staff of the Center of Hyperbaric Medicine in Somdech Phra Pinklao Hospital for their support during the study.

### Conflict of interest

The authors declare no conflict of interest.

### References

1. Schachat AP, Wilkinson CP, Hinton DR, Sadda SVR, Wiedemann P. Ryan's retina e-book. 6<sup>th</sup>ed. London: Elsevier Health Sciences; 2017.
2. Varma DD, Cugati S, Lee AW, Chen CS. A review of central retinal artery occlusion: clinical presentation and management. *Eye (Lond)* 2013;27:688-97.
3. Hayreh SS, Zimmerman MB, Kimura A, Sanon A. Central retinal artery occlusion. Retinal survival time. *Exp Eye Res* 2004;78:723-36.
4. Menzel-Severing J, Siekmann U, Weinberger A, Roessler G, Walter P, Mazinani B. Early hyperbaric oxygen treatment for nonarteritic central retinal artery obstruction. *Am J Ophthalmol* 2012;153:454-9.
5. Sim S, Ting DSW. Diagnosis and management of central retinal artery occlusion. *Retina Ophthalmic Pearls*. (Internet). 2017(cited 2018 Jun 15). Available from: <https://www.aaao.org/eyenet/articlediagnosis-and-management-of-crao>
6. Murphy-Lavoie H, Butler F, Hagan C. Central retinal artery occlusion treated with oxygen: a literature review and treatment algorithm. *Undersea Hyperb Med* 2012;39:943-53.
7. Murphy-Lavoie H, Butler F, Hagan C. Central retinal artery occlusion. In: Gesell LB, editor. *Hyperbaric oxygen therapy indications*. 12<sup>th</sup> ed., Durham, NC: Undersea & Hyperbaric Medical Society; 2008. p.57-66.
8. Elder MJ, Rawstron JA, Davis M. Hyperbaric oxygen in the treatment of acute retinal artery occlusion. *Diving Hyperb Med* 2017;47:233-8.
9. Hadanny A, Maliar A, Fishlev G, Bechor Y, Bergan J, Friedman M, et al. Reversibility of retinal ischemia due to central retinal artery occlusion by hyperbaric oxygen. *Clin Ophthalmol* 2017;11:115-25.
10. Masters T, Westgard B, Hendriksen S, Walter J,



- Logue C. Central retinal artery occlusion treated with hyperbaric oxygen. A retrospective review. Paper presented at UHMS Annual Scientific Meeting 2015 June 18 – 20, Montreal, Canada.
11. Biousse V. Thrombolysis for acute central retinal artery occlusion: is it time?. *Am J Ophthalmol* 2008; 146:631-4.
  12. Opremcak E, Rehmar AJ, Ridenour CD, Borkowski LM, Kelley JK. Restoration of retinal blood flow via transluminal Nd: YAG embolysis/embolectomy (TYL/E) for central and branch retinal artery occlusion. *Retina* 2008;28:226-35.
  13. Feltgen N, Neubauer A, Jurklies B, Schmoor C, Schmidt D, Wanke J, et al. Multicenter study of the European Assessment Group for Lysis in the Eye (EAGLE) for the treatment of central retinal artery occlusion: design issues and implications. EAGLE Study report no. 1. *Graefes Arch Clin Exp Ophthalmol* 2006;244:950-6.
  14. Hattenbach LO, Kuhli-Hattenbach C, Scharrer I, Baatz H. Intravenous thrombolysis with low-dose recombinant tissue plasminogen activator in central retinal artery occlusion. *Am J Ophthalmol* 2008;146: 700-6.
  15. Schumacher M, Schmidt D, Jurklies B, Gall C, Wanke I, Schmoor C, et al. Central retinal artery occlusion: local intra-arterial fibrinolysis versus conservative treatment, a multicenter randomized trial. *Ophthalmology* 2010;117:1367-75.
  16. Yu DY, Cringle SJ, Yu PK, Su EN. Intraretinal oxygen distribution and consumption during retinal artery occlusion and graded hyperoxic ventilation in the rat. *Invest Ophthalmol Vis Sci* 2007;48:2290-6.
  17. Herbstein K, Murchland JB. Retinal vascular changes after treatment with hyperbaric oxygen. *Med J Aust* 1984;140:728-9.
  18. James PB. Hyperbaric oxygen and retinal vascular changes. *Med J Aust* 1985;142:163-4.
  19. Rettich TR, Battino R, Wilhelm E. Solubility of gases in liquids. 22. High-precision determination of Henry's law constants of oxygen in liquid water from T = 274 K to T = 328 K. *J Chem Thermodyn* 2000;32:1145-56.