

3-1-2018

Intraosseous schwannoma of mandible: A case report

Wattawan Wongpattaraworakul

Laddawun Sununliganon

Watcharee Kliangkaeo

Nakarin Kitkumthron

Follow this and additional works at: <https://digital.car.chula.ac.th/clmjournal>



Part of the [Medicine and Health Sciences Commons](#)

Recommended Citation

Wongpattaraworakul, Wattawan; Sununliganon, Laddawun; Kliangkaeo, Watcharee; and Kitkumthron, Nakarin (2018) "Intraosseous schwannoma of mandible: A case report," *Chulalongkorn Medical Journal*: Vol. 62: Iss. 2, Article 5.

DOI: 10.58837/CHULA.CMJ.62.2.3

Available at: <https://digital.car.chula.ac.th/clmjournal/vol62/iss2/5>

This Clinical Report is brought to you for free and open access by the Chulalongkorn Journal Online (CUJO) at Chula Digital Collections. It has been accepted for inclusion in Chulalongkorn Medical Journal by an authorized editor of Chula Digital Collections. For more information, please contact ChulaDC@car.chula.ac.th.

Intraosseous schwannoma of mandible: A case report

Wattawan Wongpattaraworakul* Laddawun Sununliganon**

Watcharee Kiangkaeo* Nakarin Kitkumthron***

Wongpattaraworakul W, Sununliganon L, Kiangkaeo W, Kitkumthron N. Intraosseous schwannoma of mandible: A case report. Chula Med J 2018 Mar – Apr; 62(2): 167 - 74

Schwannoma is a benign tumor derived from Schwann cell which is the myelinated nerve sheath. This tumor usually occurs in the head and neck region but intraosseous schwannoma in this region is extremely rare, i.e. less than 1% of the benign tumors of jaws. This article reports a case of unusual intraosseous schwannoma in the mandible. A 22-year-old male patient revealed facial swelling at the right side of the chin with occasional sharp shooting pain and numbness on pressing. The radiographic examination showed a well-defined round shaped unilocular heterogeneous radiolucency with sclerotic border and buccal bone expansion at the right side of the mandible. Histological finding demonstrated spindle-shaped cells arranged in Antoni A and B patterns. The tumor was totally enucleated under general anesthesia. The patient was followed up for 6 months after surgery and showed no recurrence.

Keywords: Mandible, nerve sheath tumors, neurilemmoma, neurinoma, schwannoma.

Correspondence to: Sununliganon L. Department of Oral Surgery, Faculty of Dentistry, Rangsit University, LakHok, MueangPathumThani District, PathumThani 12000, Thailand. Email: laddawun.s@rsu.ac.th, suladdawan@hotmail.com

Received for publication. September 19, 2017.

* Discipline of Oral Maxillofacial Surgery, Faculty of Dentistry, Thammasat University

** Discipline of Oral Diagnostic Science, Faculty of Dentistry, Thammasat University

***Department of Oral Biology, Faculty of Dentistry, Mahidol University

วรรณวรรณ วงศ์พัทธวรกุล, ลัดดาวัลย์ สุนันท์ลิگانนท์, วัชรีย์ เกลี้ยงแก้ว, นครินทร์ กิตกำธร.
ชวานโนมาในกระดูกขากรรไกรล่าง: รายงานผู้ป่วย 1 ราย. จุฬาลงกรณ์เวชสาร 2561
มี.ค. – เม.ย.;62(2): 167 – 74

ชวานโนมาเป็นเนื้องอก โดยมีต้นกำเนิดจากเซลล์ชวานน์ ซึ่งเป็นปลอกหุ้มประสาทไม่อินลิน เนื้องอกชนิดนี้มักพบบริเวณศีรษะและลำคอ แต่ชวานโนมาที่พบในกระดูกบริเวณดังกล่าวพบได้น้อยกว่าร้อยละ 1 ของเนื้องอกไม่ร้ายบริเวณขากรรไกร บทความนี้รายงานกรณีศึกษาของชวานโนมาในกระดูกขากรรไกรล่างที่พบได้น้อย ผู้ป่วยชายไทย อายุ 22 ปี มีอาการบวมบริเวณคางด้านขวา ร่วมกับเจ็บแปล็บและชาเมื่อถูกกด ภาพถ่ายรังสีปรากฏลักษณะเงาโปร่งรังสีขอบเขตชัดเจน ทรงกลม ที่ความโปร่งรังสีไม่สม่ำเสมอถูกล้อมรอบด้วยขอบที่บดสีขาว และพบการขยายของกระดูกด้านแก้มที่บริเวณขากรรไกรล่างด้านซ้าย ลักษณะทางจุลพยาธิวิทยาปรากฏเซลล์รูปกระสวยเรียงเป็นลักษณะแอนโทนี เอ และบี โดยเนื้องอกนี้ถูกควักออกภายใต้การดมยาสลบ หลังจากผ่าตัดผู้ป่วยได้มาติดตามผลการรักษาเป็นระยะเวลา 6 เดือน และไม่พบการกลับเป็นซ้ำ

คำสำคัญ: ขากรรไกรล่าง, เนื้องอกปลอกหุ้มประสาท, ชวานโนมา.

Schwannoma known as neurilemmoma is a benign tumor derived from Schwann cell which is a myelinated nerve sheath.⁽¹⁻⁴⁾ The cause of the tumor is unknown.⁽⁵⁾ This tumor commonly occurs in the flexor of surface of the upper and lower extremities^(2, 3, 6, 7) and also the head and neck region.^(1,2,8) However, an occurrence of schwannoma in the oral cavity is rare.⁽⁹⁾ If the tumor occurs, it is mostly found in soft tissue especially on the tongue. Interestingly, intraosseous schwannoma is extremely rare. It is reported as less than 1% of benign tumors of jaws which the most common region is located at posterior mandible.^(1, 2, 4) It usually presents radiolucency^(3,4) with sclerotic border.^(4,10) This article reported a case of unusual presentation intraosseous schwannoma that occurred close to the root apex and showed the heterogeneous radiolucency. These features resemble to odontogenic cysts and tumors. Therefore, intraosseous schwannoma may be unconsidered in this case.

Case Report

A 22-year-old male came to the dental clinic, Thammasat Hospital due to swelling at the right side of the chin for 2 months. He complained of occasional sharp shooting pain on the lesion, with numbness on pressing. His medical status was unremarkable. Extraoral examination revealed facial swelling at the right side of the chin at approximately 5 cm. in diameter with normal skin color and texture (Figure 1), firm in consistency and no tenderness on palpation.

Intraorally, the oral hygiene appeared to be fair in general with two retained roots on the right and

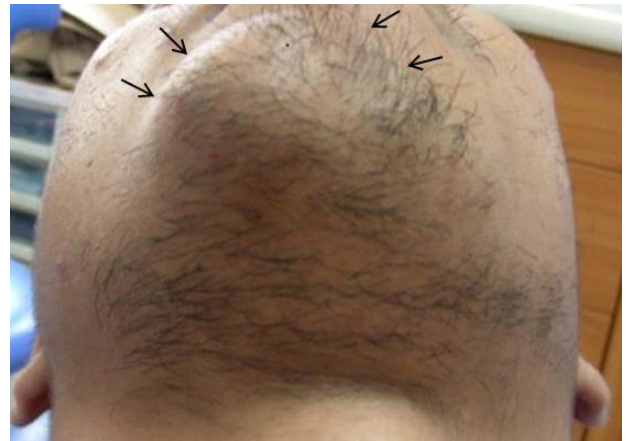

Figure 1. Round shaped mass on the right side of the chin.

left lower first molars. The swelling started at a right buccal vestibule extending from the lower first premolar to the second premolar on the right side. The mucosa was intact and normal in color. It was soft to firm in consistency. No fluid discharge, tenderness or paresthesia were noted. Teeth above the lesion were unremarkable, no tender on percussion, no mobility and no pocket formation, and they were positive to electrical pulp test (EPT).

The panoramic radiograph showed a well-defined round shaped unilocular heterogeneous radiolucency with sclerotic border on the basal bone region below the lower central incisor to second premolar on the right side of the mandible (Figure 2). The tumor was approximately 5 cm. in diameter. The lesion appeared lower radiodensity on the distal part than the mesial part. Also, the inferior border of mandible evidenced mild expansion inferiorly. The occlusal radiograph revealed buccal bone expansion on the right premolar which the sclerotic border of expanded bone cannot be traced along the lesion in the front (Figure 3).

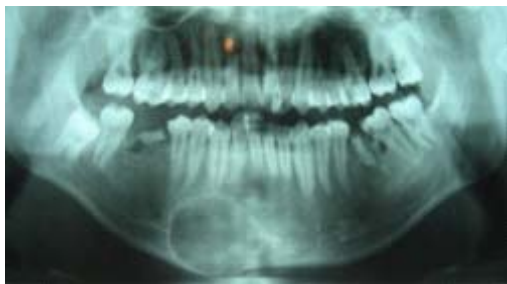

Figure 2. The lesion in panoramic radiograph illustrated a round shaped unilocular heterogeneous radiolucency on the basilar part of the mandible from right lower central incisor to right lower second premolar region. It was surrounded by a sclerotic border which expanded to the inferior border of mandible.

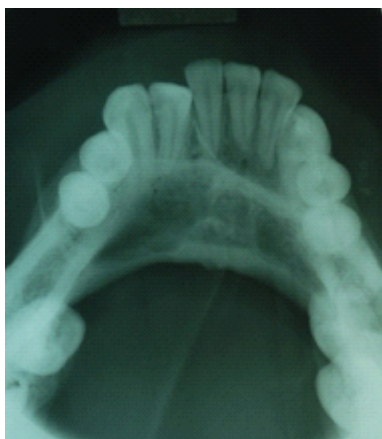

Figure 3. The lesion was surrounded by discontinuous sclerotic border showing bone perforation and there was bone expansion at buccal surface of the right side of the mandible.

The patient underwent needle aspiration but the result yielded negative finding. Then, the lesion was excised by incisional biopsy under local anesthesia. The histopathology revealed a schwannoma. The treatment plan was enucleation under general anesthesia. A buccal flap was reflected, then the tumor was totally enucleated. Grossly, the lesion composed of two soft tissue masses. Each mass was 3 cm. in diameter with fat-like texture, pale yellow in color and soft to firm in consistency. The

first mass was uniform but the latter was separated into central and peripheral parts. The mesial peripheral part had unclear margin. The tumor was sent for pathological examination to confirm the diagnosis.

Serial sections from hematoxylin and eosin (H & E) staining revealed the tumor tissue was partially surrounded by a dense fibrous capsule. The tumor tissue demonstrated spindle-shaped cells arranged in Antoni A and Antoni B patterns (Figure 4 and 5). Areas of hemorrhage, blood clot and granulation tissue were frequently presented. After the operation for 2 days, the patient had paresthesia at the lower lip. The patient was followed up for 6 months after the surgery and showed no recurrence. However, he was lost to follow up after then.

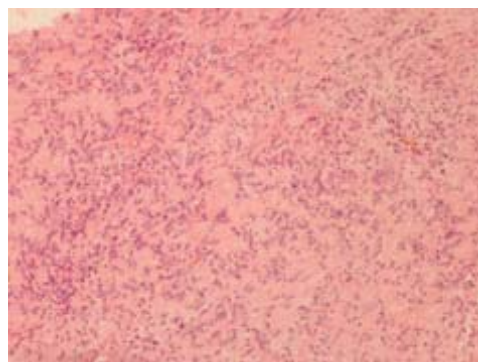


Figure 4. Photomicrograph revealed spindle shaped cells arranged in Antoni A and Antoni B (H & E; original magnification X 100).

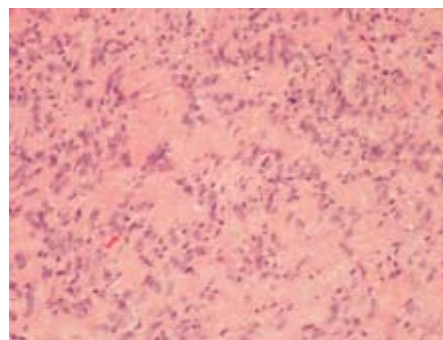


Figure 5. The Antoni A was spindle cells with palisading nuclei and these cells surrounded acellular eosinophilic zone called "Verocay bodies" (H & E; original magnification X 200)

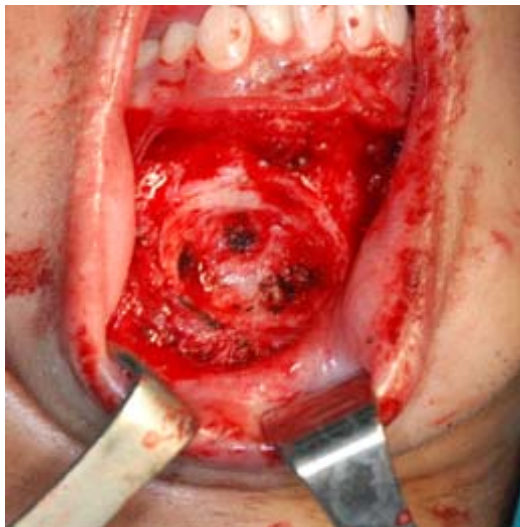

Figure 6. After enucleation, the bone was cupping indicating that the tumor was intraosseous lesion.

Discussion

The intraosseous schwannoma is extremely rare^(1, 2); mostly common in the mandible due to long intraosseous path of the inferior alveolar nerve.^(1, 2, 4) DeLeonibus A, *et al.*⁽¹¹⁾ reviewed 49 cases of intraosseous schwannoma in the mandible and classified the area of mandible into anterior, posterior and both regions. The posterior area of the mandible is the most common affected area (61.22%) and the least common site is both regions (8.16%). In this case, the tumor located from the right lower central incisor to the right lower second premolar, which considered as both anterior and posterior areas. The intraosseous schwannoma can be found in any age⁽⁹⁾ from 8 to 72 years old^(5, 12) and the female is slightly predilection.⁽⁸⁾ In Thailand, however, only one case was reported in 2006.⁽¹³⁾

The swelling is the most common clinical finding of intraosseous schwannoma^(2, 5, 6, 8, 12) and half of patients have pain or paresthesia.^(3, 6, 8, 10, 14-16)

Therefore, these symptoms shouldn't be criteria for diagnosis of schwannoma. Moreover, some cases reported tooth mobility^(3, 5, 12, 17) and displacement.^(9, 10, 12) In this case, the patient came due to a swelling and sometimes, he complained both pain and paresthesia. His symptoms may indicate that the tumor invades adjacent to nerves and affects the inferior alveolar nerve.^(5, 12)

On radiograph, the presentation of intraosseous schwannoma is varied. It may be unilocular or multilocular radiolucency^(3, 4) with sclerotic border.^(4, 10) Dystrophic calcification⁽⁸⁾, root resorption^(4, 12, 17) and cortical expansion^(4, 17, 18) may be found in the lesion. In this case, the panoramic radiograph might lead a misunderstanding because it showed unilocular heterogeneous radiolucency resembling radiopaque foci at mesial part. However, the distal part which appeared more radiolucency suggests that this area of the tumor presented more expansive growth pattern than the mesial part. Since the lesion in this case located near the root apex, the periapical radiograph may require, apart from EPT, in order to determine the relationship between the lesion and tooth. Additionally, cone beam computed tomography may also be required in most of the pathology cases so that the clinician can obtain further detail of the tumor such as dimensions, content, margin as well as the infiltration of the surrounding structures.^(3, 9)

Based on the clinical and radiographic findings, the primary impression was odontogenic and non-odontogenic cysts and tumors. However, cystic lesions were excluded because nothing could be aspirated with the needle aspiration. Therefore, differential diagnosis prior to incisional biopsy that

involved central ossifying fibroma, adenomatoid odontogenic tumor and calcifying epithelial odontogenic tumor. However, schwannoma was not considered in this case as the occurrence is rare.

On the operation, the lesion was well encapsulated and sunk into the bone causing the cupping appearance (Figure 6). This appearance might lead to a misunderstanding that the lesion was extraosseous tumor causing bone penetration. However, the discontinuous of the expanded sclerotic border surrounding the lesion on occlusal radiograph, especially on the second premolar area, suggests that the tumor arose in the bone, expanded and perforated buccal bone in the frontal area.

The histopathological feature of schwannoma is composed of spindle cells, which arrange in two patterns, namely: Antoni A shows streaming fascicles of spindle-shaped cell form a palisaded arrangement surround by central acellular, eosinophilic areas (Verocay bodies),^(9, 14, 15, 17, 19) another pattern, the spindle cells randomly arranged is called Antoni B.^(9, 10, 14) In this case, the pathognomonic of Antoni A and Antoni B were observed that fulfilled to the requirement of schwannoma. Therefore, the definite diagnosis of schwannoma was established. However, many cases showed predominantly Antoni A.^(1, 4, 19) In addition, there is no dystrophic calcification, microscopically. Thus, this feature corresponds with the radiographic interpretation suspecting that showed no radiopaque foci. These cases might be a misunderstanding with leiomyoma because its histopathologic findings consisting of spindle shaped cells arranging in rows and exhibiting a palisading effect resembles Antoni A of schwannoma. Thus, in some cases, the immunohistochemistry technique is necessary.^(5, 7) The schwannoma is diffuse strong positive staining

for S-100 protein⁽⁷⁾ which is a marker for neural tissue.⁽⁵⁾

DeLeonibus A, *et al.*,⁽¹¹⁾ reported the treatment of intraosseous schwannoma that ranges from enucleation to surgical resection. There is still controversy whether implicated nerve should be resected.⁽¹⁹⁾ In many cases, the nerve connected to the tumor was resected in order to avoid recurrence.^(5, 10, 12) However, a complication of paralysis might occur and cause trouble to patient in some situations. Therefore, the implicated nerve should be preserved if the tumor is encapsulated⁽¹⁹⁾ because the recurrence is rare.^(1, 2, 19) Also, the malignant transformation is extremely rare^(3, 7, 15) and there was no reports of malignancy changes in intraosseous schwannoma.⁽⁴⁾ In this case, the enucleation seems to be the proper treatment because the tumor was encapsulation. Although the recurrence and malignant transformation is unusual, the regular follow-up is still necessary.^(4, 5)

Conclusion

Intraosseous schwannoma is extremely rare. Its clinic finding is usually asymptomatic swelling. Moreover, the radiographic features vary. Therefore, histological examination is necessary for the diagnosis and management. Although the occurrence is rare, schwannoma should be considered as a differential diagnosis when a tumor is obviously not odontogenic origin.

Acknowledgements

The authors appreciate kind assistance for radiographic interpretation from Assistant Professor Somporn Prapanpoch and Assistant Professor Dr. Sumroeng Ingram, Discipline of Oral Radiograph, Faculty of Dentistry, Thammasat University.

References

1. Gallego L, Junquera L, Rodriguez-Recio C, Fresno MF. Intraosseous mandibular schwannoma mimicking an odontogenic keratocyst, with a postsurgical pathological fracture. *J Laryngol Otol* 2009;123:560-2.
2. Martins MD, Taghloubi SA, Bussadori SK, Fernandes KP, Palo RM, Martins MA. Intraosseous schwannoma mimicking a periapical lesion on the adjacent tooth: case report. *Int Endod J* 2007;40:72-8.
3. Zainab H, Kale AD, Hallikerimath S. Intraosseous schwannoma of the mandible. *J Oral Maxillofac Pathol* 2012;16:294-6.
4. Chi AC, Carey J, Muller S. Intraosseous schwannoma of the mandible: a case report and review of the literature. *Oral Surg Oral Med Oral Pathol Oral Radiol Endod* 2003;96:54-65.
5. Hsieh MY, Chen CM, Lin LM, Chen YK. Intraosseous Neurilemmoma (Schwannoma) of the Mandible - Report of a Case. *Cases Journal TAOMFR* 2009;1-6.
6. Jahanshahi G, Haghighat A, Azmoodeh F. Intraosseous neurilemmoma of the mandible: report of a rare ancient type. *Dent Res J (Isfahan)* 2001;8:150-3.
7. Buric N, Jovanovic G, Pesic Z, Krasic D, Radovanovic Z, Mihailovic D, et al. Mandible schwannoma (neurilemmoma) presenting as periapical lesion. *Dentomaxillofac Radiol* 2009;38:178-81.
8. Minowa K, Sakakibara N, Yoshikawa K, Ohmori K, Kitagawa Y, Inoue N, et al. CT and MRI findings of intraosseous schwannoma of the mandible: a case report. *Dentomaxillofac Radiol* 2007;36:113-6.
9. deLacerda SA, Brentegani LG, Rosa AL, Vespucio MV, Salata LA. Intraosseous schwannoma of mandibular symphysis: case report. *Braz Dent J* 2006;17:255-8.
10. Kargahi N, Razavi SM, Hasheminia D, Keshani F, Safaei M, Hashemzadeh Z. Mandibular intraosseous schwannoma in a child: Report a rare case. *Dent Res J (Isfahan)* 2012;9:119-22.
11. DeLeonibus A, Bassiri Gharb B, Papay F, Zins JE, Rampazzo A. Surgical management of mandibular intraosseous schwannomas. *J Craniofac Surg* 2017;28:e307-11.
12. Patil K, Mahima V, Srikanth H, Saikrishna D. Central schwannoma of mandible. *J Oral Maxillofac Pathol* 2009;13:23-6.
13. Pimkhaokham A, Piriyaupong P, Swasdison S, Pimkhaokham S, Tung P. Central neurilemmoma of the jaw in concurrence with radicular cyst: a case report. *Oral Surg Oral Med Oral Pathol Oral Radiol Endod* 2006;102:e34-6.
14. Ito S, Mandai T, Ishida K, Deguji H, Hata T, Irei I, et al. Intraosseous schwannoma of the mandible: A case report. *Kawasaki Med J* 2009;35:249-52.
15. Kawasaki G, Yanamoto S, Yoshida H, Mizuno A, Fujita S, Ikeda T. Intraosseous schwannoma of the mandibular symphysis: Report of a case. *Oral Science International* 2010;7:76-9.
16. Agarwal K, Umarji HR, Tupkari JV, Chaudhary S, Avadhani A, Agrawal N. Slowly growing swelling on body of the mandible with paresthesia on lower lip. *Oral Surg Oral Med*

- Oral Pathol Oral Radiol 2012;114:677-82.
17. Liu CC, Chen JK, Kuo SB. Intraosseous ancient schwannoma of the mandible - A case report. Taiwan J Oral Maxillofac Sur 2015;26:76-83.
18. Shetty SR, Rao PK, Chatra L, Shenai P. A case of a massive mandibular schwannoma. J Neurosci Rural Pract 2011;2:65-7.
19. Suga K, Ogane S, Muramatsu K, Ohata H, Uchiyama T, Takano N, et al. Intraosseous schwannoma originating in inferior alveolar nerve: A case report. Bull Tokyo Dent Coll 2013;54:19-25.