

1-1-2019

## Combination of a non-ablative 1,927 nm thulium fiber fractional laser and autologous platelet-rich plasma in treatment of male androgenetic alopecia: A pilot study

Narisa Brownell

Ratchathorn Panchaprateep

Ruangrong Glinhom

Follow this and additional works at: <https://digital.car.chula.ac.th/clmjjournal>



Part of the [Medicine and Health Sciences Commons](#)

---

### Recommended Citation

Brownell, Narisa; Panchaprateep, Ratchathorn; and Glinhom, Ruangrong (2019) "Combination of a non-ablative 1,927 nm thulium fiber fractional laser and autologous platelet-rich plasma in treatment of male androgenetic alopecia: A pilot study," *Chulalongkorn Medical Journal*: Vol. 63: Iss. 1, Article 4.

Available at: <https://digital.car.chula.ac.th/clmjjournal/vol63/iss1/4>

This Article is brought to you for free and open access by the Chulalongkorn Journal Online (CUJO) at Chula Digital Collections. It has been accepted for inclusion in Chulalongkorn Medical Journal by an authorized editor of Chula Digital Collections. For more information, please contact [ChulaDC@car.chula.ac.th](mailto:ChulaDC@car.chula.ac.th).

## Original article

# Combination of a non-ablative 1,927 nm thulium fiber fractional laser and autologous platelet-rich plasma in treatment of male androgenetic alopecia: A pilot study

Narisa Brownell, Ratchathorn Panchaprateep\*, Ruangrong Glinhom

Department of Medicine, Faculty of Medicine, Chulalongkorn University and King Chulalongkorn Memorial Hospital, Bangkok, Thailand

**Background:** Platelet-rich plasma (PRP) is composed of multiple essential growth factors which can stimulate hair growth by promoting cell proliferation, prolonging cell survival and the anagen phase of hair follicles. Fractional laser can create proper wounding which results in subsequent platelet activation and might promote hair growth. Nevertheless, clinical trials related to the efficacy and safety of the combination of fractional laser and PRP have not been established.

**Objectives:** To investigate the efficacy and safety of the combination of non-ablative fractional laser and platelet-rich plasma for the treatment of male androgenetic alopecia (AGA).

**Methods:** A total of nine men were recruited for a pre- and post- treatment study. Three sessions of fractional 1,927 nm Thulium-doped fiber laser (Lasemd, Lutronic Inc, South Korea) followed by PRP injections on the affected area were performed at 1-month intervals. Non-activated PRP was prepared using a Ycellbio-kit (Ycellbio Medical Co., Ltd., South Korea). Hair growth was evaluated by using: (i) standardized global photographs; (ii) hair mass index (Hair check system®); (iii) target area hair counts (Trichoscale, Fotofinder); and, (iv) patient self-assessment questionnaires at baseline, then 3 and 6 months after the last treatment.

**Results:** Nine men with Norwood-Hamilton classification of grade II-IV, and a mean age of 41.3 years old (range 32 - 55) completed the study. At 6 months after completing the three treatment sessions, the terminal hair density significantly increased from baseline by 28.1% (99.1 to 127 = 27.9 hairs/cm<sup>2</sup>,  $P = 0.011$ ). The increased percentage of total hair density was 9.7% (149.7 to 164.2 = 14.5 hairs/cm<sup>2</sup>,  $P = 0.015$ ). The hair mass index was increased from baseline by 26.4% (16 to 20.2,  $P = 0.024$ ). The global photography showed improvement in almost all patients: 3 moderate (41 - 70%); 4 slight improvement (1 - 40%) and 2 no change as compared to baseline. The treatment was fair tolerated and the mean visual analog scale (VAS) for pain was 0.8 (0 - 2) and 4.2 (2 - 6) for laser treatment and PRP injections, respectively. Adverse effects were transient erythema and a mild burning sensation on the treated areas.

**Conclusion:** A combination of a 1,927 nm fractional Thulium-doped fiber laser and PRP is considered safe, and an effective strategy for the treatment of male AGA. However, to determine the efficacy of this combination therapy, larger sample sizes and longer follow-up durations, randomized, placebo-controlled trials are suggested.

**Keywords:** Androgenetic alopecia, platelet-rich plasma, fractional laser.

Androgenetic alopecia (AGA) is a common hair disorder in male and female populations causing hair miniaturization by multiple factors, mainly, androgens, and genetic backgrounds.<sup>(1)</sup> In Thai populations, 40%

of men develop hair thinning by the age of 50 years old.<sup>(2)</sup> Men who suffer from hair thinning lose their self-confidence resulting in anxiety, depression and impaired quality of life.

At present, the US Food and Drug Administration (FDA) approved treatment for AGA includes topical minoxidil, oral finasteride and low-level laser therapy.<sup>(3)</sup> Due to some standard treatment dissatisfaction, new alternative treatments such as fractional laser therapy, autologous platelet-rich plasma

\*Correspondence to: Ratchathorn Panchaprateep, Department of Medicine, Faculty of Medicine, Chulalongkorn University and King Chulalongkorn Memorial Hospital, Bangkok 10330, Thailand.

Received : March 25, 2018

Revised : May 16, 2018

Accepted : June 12, 2018

(PRP) and hair transplantation are used more frequently in clinical practices.

Platelet-rich plasma (PRP) is composed of multiple essential growth factors secreted from platelet granules, namely vascular endothelial growth factor (VEGF), platelet-derived growth factor (PDGF), transforming growth factor- $\beta$  (TGF- $\beta$ ), insulin-like growth factor 1, 2 (IGF-1, 2), epidermal growth factor (EGF), hepatocyte growth factor (HGF) and fibroblast growth factor (FGF).<sup>(4)</sup> These growth factors can stimulate hair growth by promoting cell proliferation, and prolonging cell survival and the anagen phase of hair follicles. PRP has not only been used in hair disorders, but also in other medical purposes, e.g., gingival regeneration<sup>(5)</sup>, bone and cartilage healing, tenosynovitis<sup>(6)</sup>, chronic wounds<sup>(7)</sup> and aesthetics.<sup>(8-10)</sup> Previous *in vitro* studies demonstrated the effects of activated PRP on dermal papilla cells cultured which comprised upregulation of extracellular signal-regulated kinases (ERK), Akt (protein kinase B), bcl-2, beta-catenin activity and FGF-7 expression. All of the aforementioned actions resulted in hair growth stimulation.<sup>(11, 12)</sup> Fractional non-ablative lasers, either Erbium/glass or thulium lasers with optimum settings, have been found to stimulate hair growth by upregulating Wnt/beta-catenin pathway and have become one of the new effective treatments of androgenetic alopecia.<sup>(13, 14)</sup> However, the mechanism of fractional laser induced hair growth is not well established, some authors postulated the hypothesis of the trauma-induced wound healing effecting hair epithelial proliferation.<sup>(14)</sup> Currently, autologous PRP has been used as a single or combination therapy with either fractional laser or microneedling in treating AGA. Nevertheless, a clinical trial investigating the efficacy and safety of the combination therapy has not been reported. Our trial aimed to investigate the efficacy and safety of a combination of non-ablative fractional laser and platelet-rich plasma (PRP) for the treatment of mild-to-moderate severity of male androgenetic alopecia (AGA). We hypothesized that fractional laser could create proper wounding which results in subsequent platelet activation and might synergize with PRP in promoting hair proliferation.

## Methods

This is a pilot, open-label, prospective, pre- and post-treatment study approved by the institutional review board of Chulalongkorn University. Nine Thai men with androgenetic alopecia, Norwood-Hamilton

classification II-IV, aged between 18 - 60 years old were recruited. Exclusion criteria were as follows: 1) history of drugs use that effected hair growth within the 6 months prior to the study (finasteride, dutasteride, minoxidil, cyproterone acetate, spironolactone, ketoconazole, anabolic steroids, cyclosporine, diazoxide, phenytoin, psoralens); 2) underlying systemic disease; and, 3) previous hair transplantation.

Fractional 1,927 nm Thulium-doped fiber laser (Lasemd, Lutronic Inc, South Korea) with parameters of 3 - 5 Watts, 5 - 10 mJ/spot, 0.5 - 20 ms, and 3 - 5 passes followed by a PRP injection were used on hair thinning area. PRP was extracted using a Ycellbio-kit (Ycellbio Medical Co., Ltd., South Korea) with the in-house protocol using a centrifuge machine (Eppendorf 5804R, Germany). Whole blood was drawn by venipuncture into a syringe containing an anticoagulant citrate dextrose solution formula A (ACD-A) with blood: ACD-A solution = 9:1. A small amount of blood samples (0.05 mL) before and after centrifugation from nine male patients were collected and sent to a hematology laboratory for complete blood count analysis. The total volume of blood (30 mL) was divided into two tubes (15 mL each) which were then centrifuged at 3,000 rpm for 15 minutes single spin, accelerator 7, brake 0, at 21°C to provide buffy coat layer. The Buffy coat (containing numerous platelets and white blood cells) was then carefully aspirated (3 mL from each tube) using a 18G needle under sterile conditions. The total of 6 mL of PRP was injected by 30G needle, 0.1 mL/cm<sup>2</sup>, 3 - 5 mm. in depth over the affected area. Three sessions of this combined treatment were performed at 1-month intervals.

Standardized global photographs assessment, hair mass index (Hair check system®), targeted area hair counts (Trichoscale, Fotofinder) and patient self-assessment questionnaires were taken to evaluate hair growth. Photographs of the frontal and vertex scalp areas were taken by a DSLR camera (Nikon d7200, Japan) using manual mode in the same environment and camera settings at baseline, 3 and 6 months after the last treatment. Three blinded dermatologists performed expert panel global photographic assessments comparing between each visit using a 7-point scale: -3 = greatly decreased (-100% to -71%), -2 = moderately decreased (-70% to -41%), -1 = slightly decreased (-40% to -1%), 0 = no change, 1 = slightly increased (1% to 40%), 2 = moderately increased (41% to 70%), 3 = greatly increased (71%

to 100%). Hair mass index, measuring a small change in hair density and hair diameter by cross-sectional trichometry (Haircheck®), was used at baseline and 6 months after the last treatment on the same scalp area. Targeted area hair counts, hair thickness and average hair per unit were evaluated on the same scalp area at each visit at baseline, and 3 and 6 months after the last treatment by using the Trichoscale system (FotoFinder®). The selected vertex area was tattooed with temporary black tattoo ink at first visit and a 1 cm<sup>2</sup> diameter scalp area with a center tattoo marking was shaved during each visit.

All patients completed written informed consent before their enrollment. The study was conducted at the Division of Dermatology, King Chulalongkorn Memorial Hospital. Participants were asked to assess their pain scores in the laser treatment, and PRP injection measured by in visual analog scale (VAS) scores (rating 1 - 10) and adverse effects including erythema, burning sensation, folliculitis, erosion and hair shaft breakage after every treatment.

#### Statistical analysis

Continuous, ordinal and categorical data are reported as mean ± standard deviation, mode and percentage, respectively. Wilcoxon signed-rank tests

were tested using SPSS statistical software (version 22.0 IBM, Chicago, IL, USA) to evaluate hair changes between baseline, 3 and 6 months after the last treatment. A *P*-value considering statistical significant was < 0.05.

## Results

### Demographic data

The mean age of the patients was 41 years (range 32 - 55). The Norwood-Hamilton grades of hair loss were stage II, III and IV in 2, 3 and 4 patients, respectively. The mean duration of hair loss was 8.6 years (range 3 – 20 years). A summary of patients' characteristics are shown in Table 1.

### Complete blood count analysis

The mean platelet concentration in PRP of all patients was 5.9 (739.4 × 10<sup>3</sup>/mm<sup>3</sup>) times higher than whole blood (113.4 × 10<sup>3</sup>/mm<sup>3</sup>). Leukocyte concentrations in PRP increased approximately 3 times higher than whole blood. The proportion of differential leukocyte counts in whole blood was neutrophils: lymphocytes = 66: 25 (%), where as in PRP it was neutrophils: lymphocytes = 29: 68 (%). The mean hematocrit in plasma was 5% after centrifugation by our in-house protocol. (Table 2)

**Table 1.** Demographic data (total 9 patients).

<b>Age, mean ± SD (range), years</b>	<b>41.3 ± 7.9 (32 - 55)</b>
Family history of hair loss, n (%)	7/9 (78%)
NH grades of hair loss, n (%)	
II	2/9 (22%)
III	4/9 (45%)
IV	3/9 (33%)
Duration, mean ± SD (range), years	8.6 ± 4.9 (3 - 20)
Previous treatment	
Topical minoxidil	4/9 (44%)
Oral finasteride	1/9 (11%)

NH: Norwood Hamilton.

**Table 2.** Complete blood count results of whole blood and PRP.

	<b>Platelet (x10<sup>3</sup>/mm<sup>3</sup>)</b>	<b>Leukocyte (x10<sup>3</sup> mm<sup>3</sup>)</b>	<b>Neutrophil (%)</b>	<b>Lymphocyte (%)</b>	<b>Hematocrit (%)</b>
Whole blood	113.4 ± 38.7	5.2 ± 1.2	66.4 ± 6.2	29.4 ± 6.4	42.4 ± 4.5
PRP	739.4 ± 869.0	18.1 ± 14.4	24.5 ± 28.2	67.5 ± 25.4	5.3 ± 6.4

PRP: Platelet rich plasma.

### Dermoscope evaluation

The parameters of hair growth that were assessed by trichoscale software, Fotofinder with manual correction at baseline, 3 months after the 3<sup>rd</sup> treatment, and 6 months after the 3<sup>rd</sup> treatment are summarized in Table 3. A significant improvement of total and terminal hair density was observed by trichoscale analysis. The percentage increase of total hair density was 9.7% (149.7 to 164.2 = 14.5 hairs/cm<sup>2</sup>,  $P = 0.015$ ). The terminal hair density significantly increased from baseline by 28.1% (99.1 to 127 = 27.9 hairs/cm<sup>2</sup>,  $P = 0.011$ ). The improvements of hair density in two participants are shown in Figure 1.

Mean thickness, cumulative thickness and hair per unit at 3 and 6 months after last treatment did not differ from baseline except cumulative thickness at 6 months after last treatment ( $P = 0.015$ ).

### Hair mass index results

Hair mass index (HMI) at 6 months after the last treatment, demonstrated in Figure 2, revealed a significant increase from baseline by 26.4% (16 to 20.2,  $P = 0.024$ ). Improvement of hair mass index was observed in all patients.

### Photographic assessments

The global photographic assessment (GPA) of the frontal area at 3 and 6 months after last treatment showed an improvement of 89% (8/9 patients; 1 moderated, 7 slight improvement and 1 no change)

and 67% (6/9 patients; 1 moderated, 5 slight improvement and 3 no change), respectively. The GPA of the vertex area at 3 and 6 months after last treatment showed an improvement of 78% (7/8 patients; 3 moderated, 4 slight improvement and 2 no change) and 78% (7/8 patients; 3 moderated, 4 slight improvement and 2 no change), respectively. The worsening of clinical outcome was not observed in our patients. (Figure 3)

Patient self-assessment at 3 and 6 months after last treatment revealed satisfaction in most of the patients, the results were as follows: at 3 months after last treatment; marked improvement, 11% (1/9); moderate improvement 33% (3/9); slight improvement 34% (3/9); no change 22% (2/9). At 6 months after last treatment; marked improvement 11% (1/9); moderate improvement 33% (3/9); slight improvement 22% (2/9); no change 34% (3/9). (Figure 4)

### Safety profiles

Regarding the safety profile, none of the patients reported of serious adverse effects. Some patients complained about transient erythema and mild pain on the treated area. Both of erythema and pain sensation resolved spontaneously within 1 - 2 days. No dryness, dandruff or folliculitis was reported after any treatment. This combined treatment was tolerated and the mean visual analog scale (VAS) for pain was 0.8 (0 - 2) and 4.2 (2 - 6) for laser treatment and PRP injection, respectively.

**Table 3.** Summary hair growth parameters from Trichoscale analysis.

Parameters	Time	Mean (SD)	P - value
Total hair density (hairs/cm <sup>2</sup> )	Baseline	149.7(23.6)	
	3 months after 3 <sup>rd</sup> treatment	166.4(23.9)	$P = 0.011^*$
	6 months after 3 <sup>rd</sup> treatment	164.2(29.1)	$P = 0.015^*$
Terminal hair density (hairs/cm <sup>2</sup> )	Baseline	99.1(33.5)	
	3 months after 3 <sup>rd</sup> treatment	117.6(30.2)	$P = 0.028^*$
	6 months after 3 <sup>rd</sup> treatment	127.0(25.3)	$P = 0.011^*$
Mean thickness (micron)	Baseline	45.3(7.2)	
	3 months after 3 <sup>rd</sup> treatment	45.0(6.7)	$P = 0.888$
	6 months after 3 <sup>rd</sup> treatment	48.4(6.8)	$P = 0.058$
Cumulative hair thickness (mm/cm <sup>2</sup> )	Baseline	6.8(1.8)	
	3 months after 3 <sup>rd</sup> treatment	7.5(1.7)	$P = 0.074$
	6 months after 3 <sup>rd</sup> treatment	8.0(1.9)	$P = 0.015^*$
Average hair per unit (hairs/FU)	Baseline	1.6(0.2)	
	3 months after 3 <sup>rd</sup> treatment	1.7(0.2)	$P = 0.286$
	6 months after 3 <sup>rd</sup> treatment	1.7(0.2)	$P = 0.213$

\* $P < 0.05$



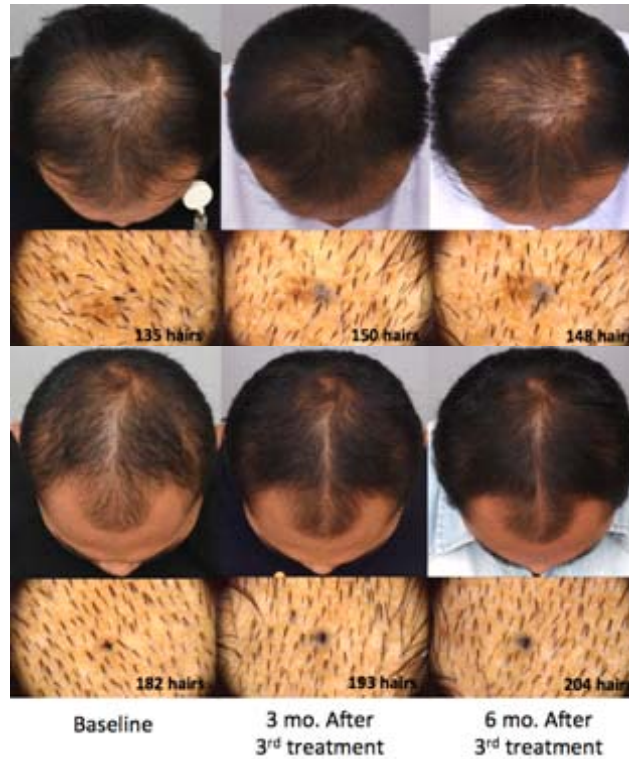

Figure 1. Clinical and Dermoscope photos of representative patients.

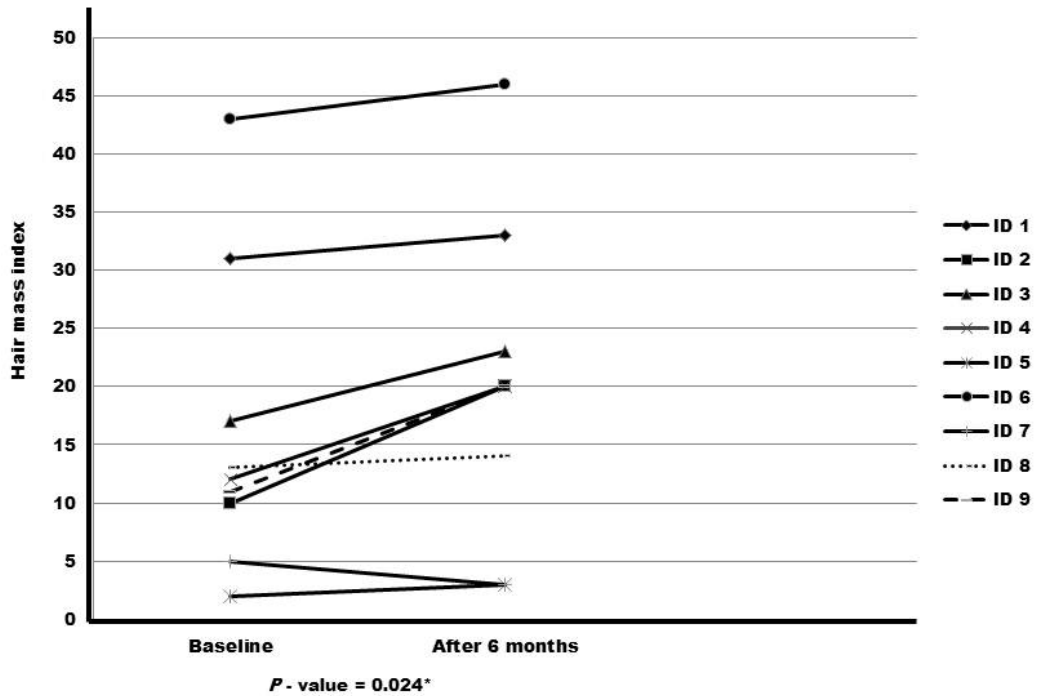


Figure 2. Hair mass index at baseline and 6 months after last treatment.

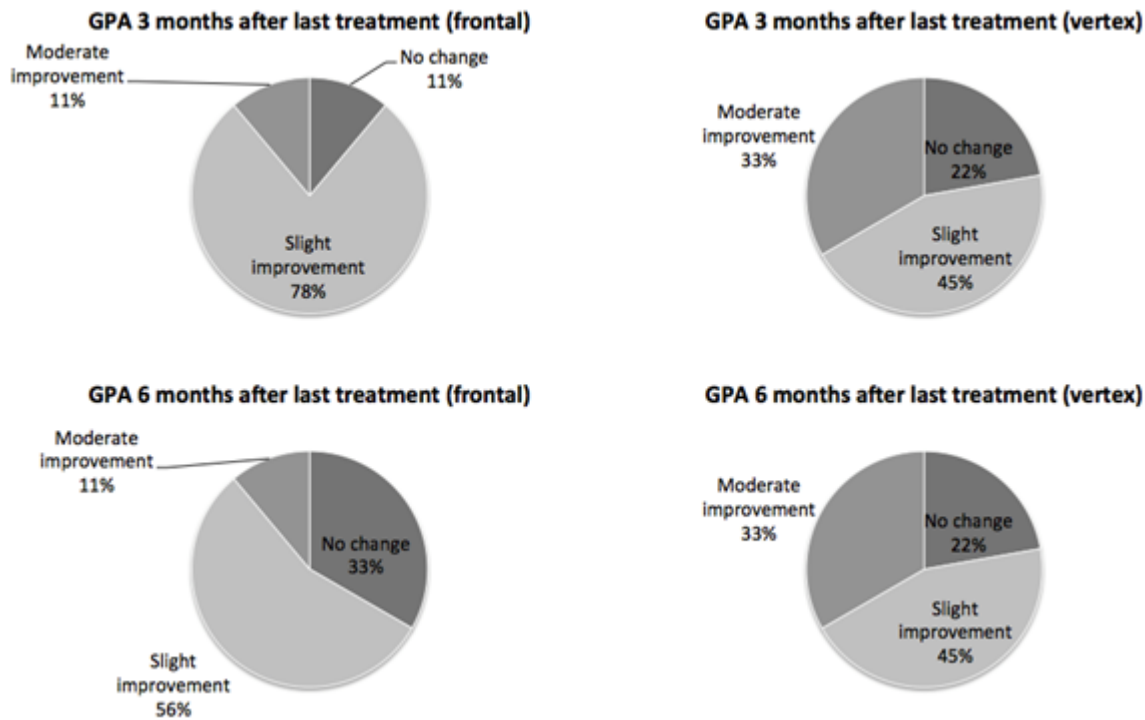


Figure 3. Global photographic assessment (GPA) of frontal and vertex area at 3 and 6 months after last treatment.

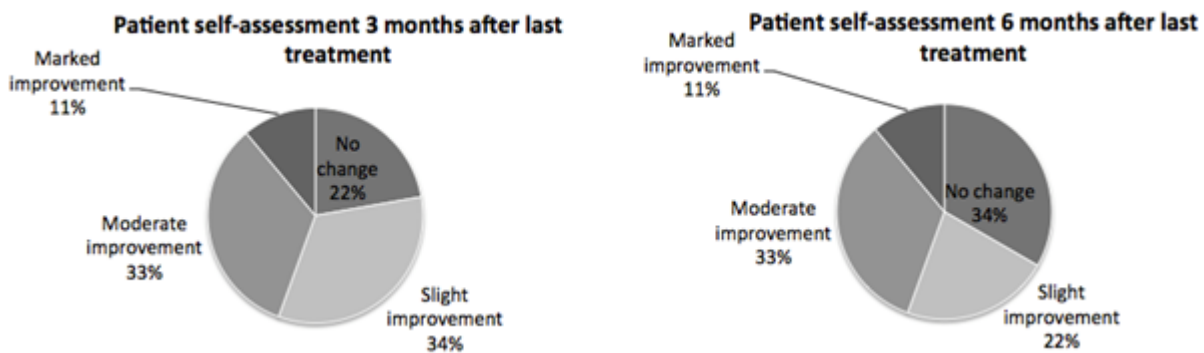


Figure 4. Patient self-assessment at 3 and 6 months after last treatment.

**Discussion**

Platelet rich plasma is proven by several clinical trials to help increase hair density, particularly in androgenetic alopecia. (11, 15) Multiple factors may contribute to the efficacy of PRP treatment such as number of platelets, number of leukocytes, use of platelet activators, treatment schedule, and injection technique.

The proper concentration of platelets in PRP ranges between 4 - 7 times higher when compared to baseline. A higher number of platelets results in the increased amount of growth factors that in turn correlated with the better efficacy of PRP treatment.

Our study prepared PRP by using a Ycellbio-kit (Ycellbio Medical Co., Ltd., South Korea) and the in-house centrifuge protocol to create a Buffy coat layer. The mean platelet concentration in our study was 5.9 times higher compared to baseline which is considered a proper concentration. In terms of the process of centrifugation, some authors recommend avoiding high rotation speed, longer centrifuged time and multiple spins to prevent early platelet activation. (16) Plasma rich in platelets that is extracted from Buffy coat layer after centrifugation also contains varying amounts of leukocytes depending upon the technique of collection. In the present study, we found that the

amount of total leukocytes in PRP was increased 3 fold compared to whole blood and the percentage of the differential leukocyte count in PRP also shifted towards an increased proportion of lymphocytes and decreased proportion of neutrophils. Castillo TN, *et al.*<sup>(17)</sup> compared the differences of growth factor concentrations between leukocyte-rich PRP and leukocyte-poor PRP. The results demonstrated that the concentrations of PDGF and VEGF were higher in leukocyte-rich PRP compared to leukocyte-poor PRP. Moreover, apart from the total number of leukocytes, the efficacy of PRP might be effected by particular types of leukocyte as well. Some studies found negative effects of neutrophils on platelets by down regulating platelet activities.<sup>(18, 19)</sup> According to previous studies, the high amount of leukocytes and the decreased proportion of neutrophils after PRP extraction in our study could result in the increase of the total amount of essential growth factors. Orliac S, *et al.*<sup>(20)</sup> evaluated the effects and local toxicity of repeated subcutaneous PRP injection (weekly for a total of 5 months) on hair growth in a hairless mouse model and found that platelet rich plasma that contained some amount of leukocytes improved hair density in hairless mice, presumably via growth factor activation without local tissue toxicity. This study abandoned the finding in a previous study regarding inflammatory cytokines toxicity caused by PRP containing leukocytes.<sup>(18)</sup> Therefore, further studies about the exact effects of different numbers of leukocytes in PRP on hair growth are suggested.

From several reported trials, in order for PRP to release growth factors, platelets activation using platelet activators, such as calcium or thrombin, have been suggested.<sup>(21)</sup> However, Gentile P, *et al.* compared the levels of growth factors between calcium treated PRP and untreated PRP and found that there was no significant different regarding growth factor concentrations between the two groups.<sup>(4)</sup> A previous study suggested that both activated PRP and non-activated PRP could be used effectively for AGA patients.<sup>(4)</sup> After mixing PRP with platelet activators, the viscosity of PRP increases due to clot formation making scalp injection more difficult compared to non-activated PRP. Therefore, we chose non-activated PRP because of its effectiveness and appropriate texture for scalp injection.

Treatment schedules of PRP protocols among published studies vary since there is no established

guidelines.<sup>(15)</sup> The most widely used treatment duration is 3 sessions every 4 - 6 weeks. Alves R, *et al.*<sup>(22)</sup> conducted a randomized, double-blinded study in twenty-five patients with AGA using 3 sessions of PRP at 1-month intervals. At six months after the first treatment, it showed a significant increase in hair counts of 12.8 hairs/cm<sup>2</sup> in the PRP group compared to a decrease in hair counts of 2.1 hairs/cm<sup>2</sup> in the control group. According to the efficacy of this trial, in the present study, we also used the same treatment duration as Alves's study and the increasing hair counts at six months after the last treatment showed a similar improvement of 14.5 hairs/cm<sup>2</sup>. Regarding the same treatment duration between the two studies, however, terminal hair density in our study was higher than the previous study. The increase of terminal hair density at six months after the last treatment was 27.9 hairs/cm<sup>2</sup> compared to 5.9 hairs/cm<sup>2</sup> in Alves's study. This finding might be explained by the increasing efficacy of a combination therapy, PRP and fractional laser in our study.

The injection technique is also important. Most authors recommended subdermal or below subdermal injection in order to gain a better bulb region diffusion of injected PRP. The suggested volume of PRP per area was 0.1 - 0.15 mL/cm<sup>2</sup>. We used the injection techniques as in the literature reviews to achieve the most effective outcome.<sup>(13, 15)</sup> Several types of light and laser therapy such as low level laser, He-Ne laser and excimer laser have been used to treat hair loss. Fractional lasers also have been reported to increase hair growth, however, the exact mechanism is not yet fully understood. Kim WS, *et al.*<sup>(23)</sup> conducted C3H/HeN in a mouse model to evaluate the effects of 1,550-nm fractional erbium-glass laser on hair growth. An increase in the Wnt 5a, beta-catenin signaling pathway which resulted in anagen conversion of the hair cycle was found in irradiated mice. The hair growth stimulation effects depend directly on proper laser settings and treatment intervals, too much of laser energy and too frequent treatment intervals might induce fibrosis of dermal tissue and worsening of the course of alopecia. A study in animals by Bae JM, *et al.*<sup>(24)</sup> supported similar findings as in another previous study that ablative fractional laser affects hair cycle changes via Wnt10b and beta-catenin activation. Another proposed mechanism is that new hair follicle formation occurs after wound healing following photothermolysis-induced minor trauma.<sup>(25, 26)</sup> Thulium laser, wavelength 1,927 nm,



is considered a fractional non-ablative laser used in dermatological fields on various purposes. Sung et al. reported the effects of fractional thulium laser on hair growth in mice and androgenic alopecia patients. The results showed increasing hair density and thickness after the laser treatment similar to those observed in erbium glass laser.

Although the effect of PRP on hair regeneration is well established, some studies reported negative effects of PRP monotherapy for AGA patients. Several new trials have used a combination technique of micro-needling or fractional lasers with PRP to enhance efficacy.<sup>(27 - 29)</sup> Our study was intended to determine the effects of a combination of non-ablative fractional laser and non-activated PRP on patients with mild to moderate severity male androgenic alopecia. The results of the present study showed a significant increase in hair counts and hair density at both 3 months and 6 months after the last treatment. We hypothesize that fractional thulium laser not only helps stimulate hair proliferation and prolonging anagen phase by itself, but also creates proper wounding which resulted in subsequent platelet activation and further release of multiple growth factors. This synergistic effect of fractional lasers and PRP might help promote hair growth.

Regarding the safety, the adverse effects that we found were mild and temporary as transient erythema and a mild burning sensation over the treated area. The PRP injection was more painful compared to laser but within acceptable limits. The treatment was considered fairly tolerated by most patients. A small sample size was considered our limitation. Moreover, we cannot indicate whether the major effects of hair growth stimulation resulted mainly from PRP or fractional lasers or needling effects since there was no control group in this study. Another limitation is that we did not evaluate long-term follow up at 12 months after the last treatment.

### Conclusions

Our preliminary study supports that a combination of a 1,927 nm fractional Thulium-doped fiber laser and PRP is a safe and effective adjunctive treatment for male AGA. However, larger and longer, randomized, placebo-controlled trials are needed.

### Conflict of interest

None of the authors has any potential conflict of interest to disclose.

### References

- Olsen EA, Messenger AG, Shapiro J, Bergfeld WF, Hordinsky MK, Roberts JL, et al. Evaluation and treatment of male and female pattern hair loss. *J Am Acad Dermatol* 2005;52:301-11.
- Pathomvanich D, Pongratananukul S, Thienthaworn P, Manoshai S. A random study of Asian male androgenetic alopecia in Bangkok, Thailand. *Dermatol Surg* 2002;28:804-7.
- Adil A, Godwin M. The effectiveness of treatments for androgenetic alopecia: A systematic review and meta-analysis. *J Am Acad Dermatol* 2017;77:136-41.
- Gentile P, Cole JP, Cole MA, Garcovich S, Bielli A, Scioli MG, et al. Evaluation of not-activated and activated PRP in hair loss treatment: role of growth factor and cytokine concentrations obtained by different collection systems. *Int J Mol Sci* 2017;18: pii: E408.
- Martinez-Zapata MJ, Marti-Carvajal A, Solà I, Bolibar I, Angel Expósito J, Rodriguez L, et al. Efficacy and safety of the use of autologous plasma rich in platelets for tissue regeneration: a systematic review. *Transfusion* 2009;49:44-56.
- Hamilton BH, Best TM. Platelet-enriched plasma and muscle strain injuries: challenges imposed by the burden of proof. *Clin J Sport Med* 2011;21:31-6.
- Cho JW, Kim SA, Lee KS. Platelet-rich plasma induces increased expression of G1 cell cycle regulators, type I collagen, and matrix metalloproteinase-1 in human skin fibroblasts. *Int J Mol Med* 2012;29:32-6.
- Cervelli V, Palla L, Pascali M, De Angelis B, Curcio BC, Gentile P. Autologous platelet-rich plasma mixed with purified fat graft in aesthetic plastic surgery. *Aesthetic Plast Surg* 2009;33:716-21.
- Sclafani AP. Applications of platelet-rich fibrin matrix in facial plastic surgery. *Facial Plast Surg* 2009;25: 270-6.
- Na JI, Choi JW, Choi HR, Jeong JB, Park KC, Youn SW, et al. Rapid healing and reduced erythema after ablative fractional carbon dioxide laser resurfacing combined with the application of autologous platelet-rich plasma. *Dermatol Surg* 2011;37:463-8.
- Li ZJ, Choi HI, Choi DK, Sohn KC, Im M, Seo YJ, et al. Autologous platelet-rich plasma: a potential therapeutic tool for promoting hair growth. *Dermatol Surg* 2012;38:1040-6.
- Rastegar H, Ahmadi AH, Aghaei M, Ehsani A, Barikbin B. Combination of herbal extracts and platelet-rich plasma induced dermal papilla cell proliferation: involvement of ERK and Akt pathways. *J Cosmet*

- Dermatol 2013;12:116-22.
13. Perper M, Aldahan AS, Fayne RA, Emerson CP, Nouri K. Efficacy of fractional lasers in treating alopecia: a literature review. *Lasers Med Sci* 2017;32: 1919-25.
  14. Cho SB, Goo BL, Zheng Z, Yoo KH, Kang JS, Kim H. Therapeutic efficacy and safety of a 1927-nm fractionated thulium laser on pattern hair loss: an evaluator-blinded, split-scalp study. *Lasers Med Sci* 2018;33:851-9.
  15. Picard F, Hersant B, Niddam J, Meningaud JP. Injections of platelet-rich plasma for androgenic alopecia: A systematic review. *J Stomatol Oral Maxillofac Surg* 2017;118:291-7.
  16. Fukaya M, Ito A. A new economic method for preparing platelet-rich plasma. *Plast Reconstr Surg Glob Open* 2014;2:e162.
  17. Castillo TN, Pouliot MA, Kim HJ, Dragoo JL. Comparison of growth factor and platelet concentration from commercial platelet-rich plasma separation systems. *Am J Sports Med* 2011;39:266-71.
  18. Kobayashi Y, Saita Y, Nishio H, Ikeda H, Takazawa Y, Nagao M, et al. Leukocyte concentration and composition in platelet-rich plasma (PRP) influences the growth factor and protease concentrations. *J Orthop Sci* 2016;21:683-9.
  19. Valles J, Santos MT, Marcus AJ, Safier LB, Broekman MJ, Islam N, et al. Downregulation of human platelet reactivity by neutrophils. Participation of lipoxygenase derivatives and adhesive proteins. *J Clin Invest* 1993; 92:1357-65.
  20. Orliac S, Serfaty JM, Perozziello A, Zurlinden O, Louedec L, Dallaudiere B. Efficacy of subcutaneous injection of platelet-rich plasma in alopecia: A clinical and histological pilot study on a rat model with a six-month long-term follow-up experience. *J Cosmet Dermatol* 2018;17:214-9.
  21. Cervelli V, Gentile P, Scioli MG, Grimaldi M, Casciani CU, Spagnoli LG, et al. Application of platelet-rich plasma in plastic surgery: clinical and in vitro evaluation. *Tissue Eng Part C Methods* 2009;15: 625-34.
  22. Alves R, Grimalt R. Randomized placebo-controlled, double-blind, half-head study to assess the efficacy of platelet-rich plasma on the treatment of androgenetic alopecia. *Dermatol Surg* 2016;42:491-7.
  23. Kim WS, Lee HI, Lee JW, Lim YY, Lee SJ, Kim BJ, et al. Fractional photothermolysis laser treatment of male pattern hair loss. *Dermatol Surg* 2011;37:41-51.
  24. Bae JM, Jung HM, Goo B, Park YM. Hair regrowth through wound healing process after ablative fractional laser treatment in a murine model. *Lasers Surg Med* 2015;47:433-40.
  25. Ansell DM, Kloepper JE, Thomason HA, Paus R, Hardman MJ. Exploring the “hair growth-wound healing connection”: anagen phase promotes wound re-epithelialization. *J Invest Dermatol* 2011;131:518-28.
  26. Chuong CM. Regenerative biology: new hair from healing wounds. *Nature* 2007;447:265-6.
  27. Fertig RM, Gamret AC, Cervantes J, Tosti A. Microneedling for the treatment of hair loss? *J Eur Acad Dermatol Venereol* 2018;32:564-9.
  28. Jha AK, Udayan UK, Roy PK, Amar AKJ, Chaudhary RKP. Original article: Platelet-rich plasma with microneedling in androgenetic alopecia along with dermoscopic pre- and post-treatment evaluation. *J Cosmet Dermatol* 2017 Aug 3. doi: 10.1111/jocd.12394.
  29. Strazzulla LC, Avila L, Lo SK, Shapiro J. An overview of the biology of platelet-rich plasma and microneedling as potential treatments for alopecia areata. *J Invest Dermatol* 2017 Nov 3. pii: S0022-202X(17)32751-3.