

7-1-2019

CT appearance of acute pancreatitis using multiphase Multidetector Computed Tomography and correlation between CT Severity Index and clinical outcomes

Busaba Jiruppabha

Follow this and additional works at: <https://digital.car.chula.ac.th/clmjjournal>



Part of the [Medicine and Health Sciences Commons](#)

Recommended Citation

Jiruppabha, Busaba (2019) "CT appearance of acute pancreatitis using multiphase Multidetector Computed Tomography and correlation between CT Severity Index and clinical outcomes," *Chulalongkorn Medical Journal*. Vol. 63: Iss. 3, Article 4.

Available at: <https://digital.car.chula.ac.th/clmjjournal/vol63/iss3/4>

This Article is brought to you for free and open access by the Chulalongkorn Journal Online (CUJO) at Chula Digital Collections. It has been accepted for inclusion in Chulalongkorn Medical Journal by an authorized editor of Chula Digital Collections. For more information, please contact ChulaDC@car.chula.ac.th.

Original article

CT appearance of acute pancreatitis using multiphase Multidetector Computed Tomography and correlation between CT Severity Index and clinical outcomes

Busaba Jiruppabha*

Bangkok Metropolitan Administration General Hospital, Bangkok, Thailand.

Background: Pancreatitis is one of the most complicated and clinically challenging of all abdominal disorders. Computed tomography (CT) is highly accurate and sensitive in both diagnosing and demonstrating its extent. In Thailand, in spite of the importance of the disease, there are a few studies of acute pancreatitis (AP), which mainly focus on its management. Currently, the 2012 revision of the Atlanta classification including new terminology and clinical assessment of the severity of AP is used.

Objective: To describe CT findings of AP using the 2012 revision of the Atlanta classification and association between CT severity index (CTSI) with clinical outcomes.

Methods: The multiphase multidetector computed tomography (MDCT) imaging (nonenhanced, hepatic arterial and portovenous phases) and relevant clinical data of 53 AP patients were reviewed. The diagnosis of AP met two of the three diagnostic criteria (abdominal pain, a serum amylase level three times higher than the upper limit of normal and pancreatitis documented by CT).

Results: The most common CT findings were extrapancreatic inflammatory changes (fat stranding and/or acute pancreatic necrosis; ANC) 87%, involving anterior pararenal space 85%, left anterior pararenal space 51%, pancreatic enlargement 77%, focal enlargement of the pancreas 43%, necrotizing pancreatitis 60%, combined necrosis 34%, bilateral pleural effusion 44%, local complication 55%, ANC 49%, gastrointestinal wall thickening 32%, involving duodenum 23%, and Balthazar CTSI significantly associated with intervention/drainage, surgical debridement and death ($P < 0.05$). No association was detected between Balthazar CTSI and organ failure. The revised Atlanta classification severity grading was associated with all clinical outcomes. Death was only seen in severe grading scores according to the revised classification.

Conclusion: The most common CT findings of AP at Bangkok Metropolitan Administration General Hospital were extrapancreatic inflammatory changes including fat stranding and/or ANC at the anterior pararenal space, prominent on the left side, pancreatic enlargement especially focal pancreatic enlargement, pancreatic necrosis mainly combined necrosis, bilateral pleural effusion and duodenal wall thickening. The higher incidence of pancreatic necrosis in this study was due to the new definition according to the 2012 revision of the Atlanta classification. There was no association between Balthazar CTSI and organ failure. The revised Atlanta classification severity grading was associated with all clinical outcomes, especially death.

Keywords: Acute pancreatitis, multiphase MDCT, CT appearance of acute pancreatitis, CTSI.

Pancreatitis is one of the most complicated and clinically challenging of all abdominal disorders.⁽¹⁾ The disease exhibits variable involvement of other regional tissues and remote organ systems.⁽²⁾ Imaging plays an important role in the diagnosis and management of pancreatic disease. Modalities for imaging the

pancreas range from plain x-ray to ultrasonography (USG), endoscopic retrograde cholangiopancreatography (ERCP), computed tomography (CT) and magnetic resonance imaging (MRI). CT is not only highly accurate but also more sensitive than USG in both diagnosing and demonstrating the extent of the disease.⁽³⁾ Several authors have indicated that CT can help determine the prognosis of acute pancreatitis (AP).^(1, 4 - 6)

The Atlanta classification of 1992 offered a global consensus and universally applicable classification system for AP.⁽²⁾ Although it is useful and widely accepted, some of the definitions are still confusing.

*Correspondence to: Busaba Jiruppabha, Bangkok Metropolitan Administration General Hospital, Bangkok 10100, Thailand. E-mail: busaba12@yahoo.com

Received: October 1, 2018

Revised: December 11, 2018

Accepted: December 13, 2018

The 2012 revision of the Atlanta classification includes clinical assessment of the severity of AP. This classification of acute pancreatitis should avoid the confusion in terminology seen over the last 20 years. ⁽⁷⁾

In Thailand, in spite of the importance of the disease, there are few studies of acute pancreatitis (AP), which mainly focus on its management. ^(8 - 11) This study, therefore, aimed to describe the CT findings of AP patients in Bangkok Metropolitan Administration (BMA) General Hospital using the 2012 revision of the Atlanta classification and study the correlation between CT severity index (CTSI) and clinical outcomes.

Materials and methods

This retrospective study recruited 123 patients admitted to BMA General Hospital, Bangkok, Thailand with the diagnosis of acute pancreatitis (AP) by the online medical database between January 2014 and June 2017. The present study has been approved by the ethical committee of BMA General Hospital.

All of the 123 diagnosed with AP patients met two of the three diagnostic criteria (abdominal pain, a serum amylase level that rises three times higher than the upper limit of normal and pancreatitis documented by CT). There were 53 AP patients who underwent multiphase multidetector CT (MDCT) of the upper or whole abdomen and were finally recruited in this study.

CT Technique

All scans were obtained using a 40-MDCT scanner (Somatom Sensation 40, Seimens Medical, Erkangen, Germany). The IV contrast media (any of 1. Ultravist 370, Iopromide, Bayer Schering, Korea; 2. Xenetix 350, Iobitridol, Guerbet, France; 3. Optiray 350, Guerbet, Canada), was given intravenously 80 - 100 ml, at the antecubital vein by a power injector (MC PLUS; Medrad, Pittsburgh) at the rate of 3 mL/sec. 500 mL of water was administered orally just before the CT of the upper abdomen examination and 1,000 mL of 0.5% iodinate contrast (diluted 1. Xenetix 350 or 2. Optiray 350) was applied orally in divided dose of 250 ml each at 30 mins intervals for CT of the whole abdomen examination. The scanning parameters were: collimation 1.2 mm; reconstruction interval 8 mm; pitch 0.8; gantry rotation time 0.37 second; 120 kV and 250 mAs. The scan sequences were nonenhanced or

NECT, arterial or HAP (25 - 45 sec after IV contrast injection) and portal venous or PVP (80 - 90 sec after IV contrast injection) phases in the craniocaudal direction from the lung base to the lower pole of the kidneys on CT of the upper abdomen or to pubic symphysis on CT of the whole abdomen. ⁽¹²⁾

Imaging analysis

MDCT images were retrospectively reviewed by the author.

1. The CT findings were recorded as enlargement of the pancreas, pancreatic enhancement, local complications, extrapancreatic extension of the inflammatory process, GI involvement, vascular complications, pleural effusion and ascites. The terminology used followed the 2012 revision of the Atlanta classification. ⁽⁷⁾

- Pancreatic parenchymal necrosis: lack of pancreatic parenchymal enhancement by intravenous contrast agent.
- Peripancreatic necrosis: present of acute pancreatic necrosis (ANC) or walled off necrosis adjacent to pancreas
- Acute peripancreatic fluid collection (APFC): homogeneous collection with fluid density, confined by normal peripancreatic fascial planes, no definable wall encapsulating the collection, adjacent to pancreas, seen within 4 weeks after onset of AP.
- Acute pancreatic necrosis (ANC): heterogeneous and non-liquid density of varying degrees in different locations, no definable wall encapsulating the collection, intrapancreatic and/or extrapancreatic in location, seen within 4 weeks after onset of acute necrotizing pancreatitis.
- Pseudocyst: well circumscribed, round or oval, homogeneous fluid density, well defined wall, seen after 4 weeks of onset of AP.
- Walled off necrosis (WON): heterogeneous with liquid and non-liquid density with varying degrees of loculations (some may appear homogeneous), well defined wall, intrapancreatic and/or extrapancreatic in location, seen after 4 weeks of onset of acute necrotising pancreatitis.
- Infected pancreatic necrosis: an extraluminal gas in the pancreatic/peripancreatic tissue on CECT or fine needle aspiration (FNA) is positive for bacteria and/or fungi.
- Local complication: APFC, ANC, pseudocyst, WON.

2. Assessment of the severity of AP was done by:

2.1 Balthazar CTSI scoring. ⁽⁴⁾

Each case was assigned points from 0 - 4 as follows: 0 = normal pancreas, 1 = focal or diffuse pancreatic enlargement; 2 = inflammation of pancreas or peripancreatic fat or both; 3 = single ill-defined fluid collection; 4 = two or multiple, poorly defined fluid collections.

The presence and extent of necrosis was classified into four categories and awarded points from 0 - 6 as follows: 0 = necrosis absent; 2 = < 30% necrosis; 4 = 30 - 50% necrosis; 6 = > 50% necrosis.

The Balthazar CTSI was calculated by adding the above points in each case and the total score was then categorized as: CTSI score 0 - 3 = mild pancreatitis; CTSI score 4 - 6 = moderate pancreatitis; CTSI scores 7 - 10 = severe pancreatitis.

2.2 The 2012 revision of the Atlanta classification ⁽⁷⁾ is classified into three categories based on clinical and morphologic findings: Mild: no organ failure and no local or systemic complications; Moderate: presence of transient organ failure < 48 hours and/or presence of local complications; Severe = persistent organ failure > 48 hours.

Outcome parameters

Clinical outcomes were collected in the terms of the following parameter: 1. Percutaneous intervention/drainage; 2. Surgical debridement; 3. Organ failure-respiratory, cardiovascular and renal system; 4. Death. The clinical outcomes were compared with Balthazar CTSI and revised Atlanta classification in all cases.

Statistical analysis

The numerable results were presented as range, mean and percent. The Chi-square for trend was used to analyze the relationships between clinical outcomes and CTSI. *P*-value < 0.05 was considered to be statistically significant.

Results

There were 53 AP patients of BMA general hospital recruited in this review. Thirty-three (62%) were male and 20 (38%) were female. Their age ranged from 20 to 89 years old (mean = 52 years). CT imaging was performed in the range of 1 - 60 days after the onset of AP, 50 patients (94%) were within 4 weeks and 3 patients (6%) were after 4 weeks.

Table 1. CT findings of acute pancreatitis.

	CT findings	No. of cases	%
Pancreas	Normal	12	22
	Diffuse enlargement	18	34
	Focal enlargement	23	43
Extrapaneatic inflammatory change	Anterior pararenal space	45	85
	Lt anterior pararenal space	27	51
	Rt anterior pararenal space	5	9
	Both anterior pararenalspace	13	25
	Lesser sac	8	15
	Mesentery	14	26
	GI wall thickening	17	32
	Lt Gerota's fascia	19	36
	Rt Gerota's fascia	3	5
	Lt lateroconal ligament	5	9
Associated CTfindings	Rt lateroconal ligament	1	2
	Venous thrombosis	2	4
	Pseudoaneurysm	0	0
	Lt pleural effusion	6	11
	Rt pleural effusion	3	5
	Bilateral pleural effusion	20	41
	Ascites	13	25

The most common CT findings were extrapancreatic inflammatory changes which included fat stranding and/or local complications (APFC, ANC, Pseudocyst, WON) found in 46 cases (87%), (Figure 1). The most common site at the anterior pararenal space was found in 45 cases (85%), at the left anterior pararenal space 27 cases (51%), and both the right and left pararenal spaces 13 cases (25%) (Table 1). The other frequent site was the mesentery in 14 cases (26%). The second most common finding was pancreatic enlargement seen in 41 cases (77%): focal enlargement of the pancreas was seen in 23 cases (43%) while in the other 18 cases (34%) the entire gland was involved, (Figure 1b). Limited

enlargement to the pancreatic tail was presented in 9 cases and the enlargement of the body and tail were found in 7 cases. Thickened left Gerota's fascia was seen in 19 cases (36%), (Figure 1a and 2a), gastrointestinal (GI) wall thickening was presented in 17 cases (32%) involving duodenum 12 cases, colon 5 cases and stomach 1 case, (Figure 2a).

Bilateral pleural effusion was the most common associated CT finding seen in 20 cases (41%) while left pleural effusion was seen in 6 cases (11%).

Thirty – two (60%) patients had necrotizing pancreatitis, and 18 cases (34%) had combined necrosis, (Figure 3 and 5). Peripancreatic necrosis was found in 8 cases (15%) (Table 2).

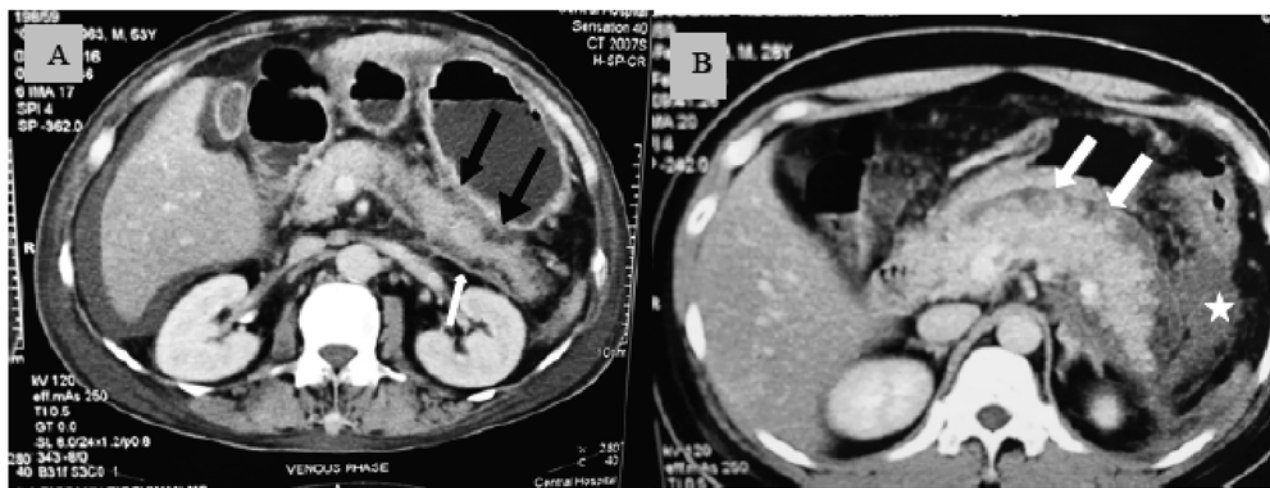


Figure 1. CECT: Extrapaneatic inflammatory change: A) normal pancreas with left anterior pararenal fat stranding (black arrows) and thickened left anterior Gerota's fascia (white arrow), minimal ascites. B) diffusely enlarged pancreas with homogeneous fluid collection at the anterior pararenal space just anterior to the pancreatic body (APFC) (white arrows), ill-defined heterogeneous fluid collection at the left anterior pararenal space (ANC) (star)

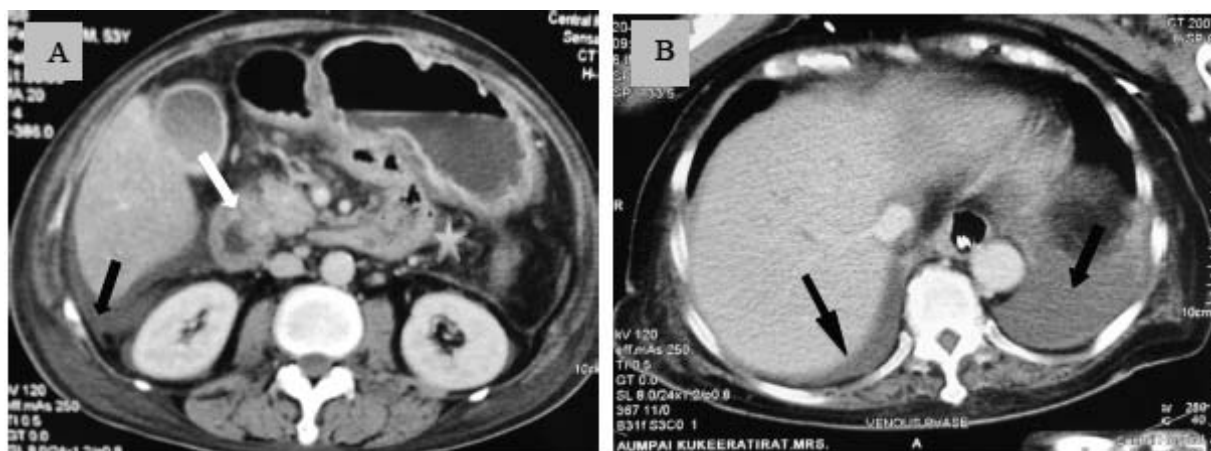


Figure 2. CECT: A) Concentric duodenal wall thickening (white arrow) adjacent to normal enhancing pancreatic uncinata process, fat stranding at the left anterior pararenal space (white star), thickened left Gerota's fascia, minimal ascites (black arrow). B) Minimal bilateral pleural effusion in acute pancreatitis (black arrows).

Table 2. Necrotizing pancreatitis and local complications of acute pancreatitis.

Necrotizing pancreatitis	No. of cases	%
Total	32	60
Parenchymal necrosis	6	11
Peripancreatic necrosis	8	15
Combined necrosis	18	34
Local complication		
Total	29	55
APFC	1	2
ANC	26	49
Pseudocyst	0	0
WON	2	4

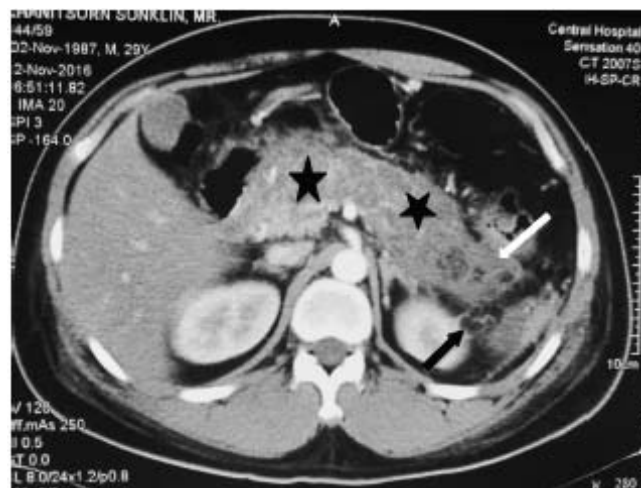

Figure 3. CECT, HAP: Combined pancreatic necrosis; diffusely enlarged pancreas with nonenhancing hypodense pancreatic head, neck, body and tail (parenchymal necrosis) (stars), ill-defined heterogeneous fluid collection at the left anterior pararenal space (peripancreatic necrosis or ANC) (white arrow), minimal fat stranding at the left perinephric space (black arrow).

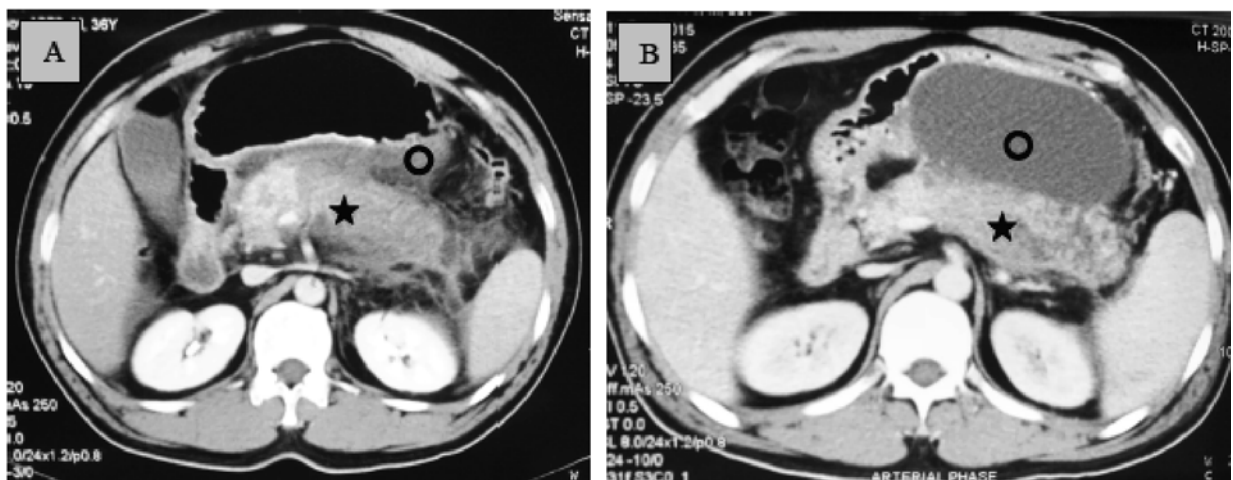


Figure 4. CECT, PVP: A 38-year-old male presented with epigastrium for 3 days:
 A) diffuse enlarged pancreas with nonenhancing pancreatic body and tail (star), ill-defined homogeneous fluid collection at the lesser sac (APFC) (ring), fat stranding at the left anterior pararenal and left perinephric spaces; parenchymal necrosis. B) 4 weeks f/u necrotic pancreatitis at the body and tail (star), a well defined homogeneous fluid collection at the lesser sac (pseudocyst) (ring)

Twenty-nine (55%) patients had local complications; there were 26 ANC cases (49%), Figure 1b, 3 and 5, 2 WON cases (3.8%) and 1 APFC case (1.9%), (Figure 4a). There was one case of

infected necrotic pancreatitis which showed gas containing ANC at the right anterior pararenal space, (Figure 6).

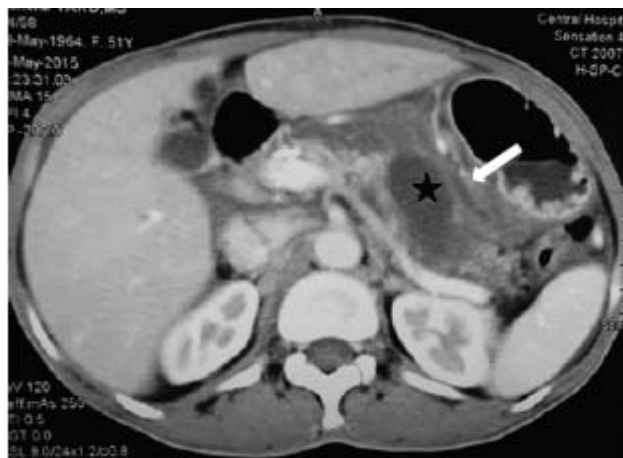

Figure 5. CECT, HAP: A 53-year-old male with acute necrotizing pancreatitis and local complication (ANC): ill-defined wall, heterogeneous fluid collections at the pancreatic body, tail (star) and lesser sac (white arrow).

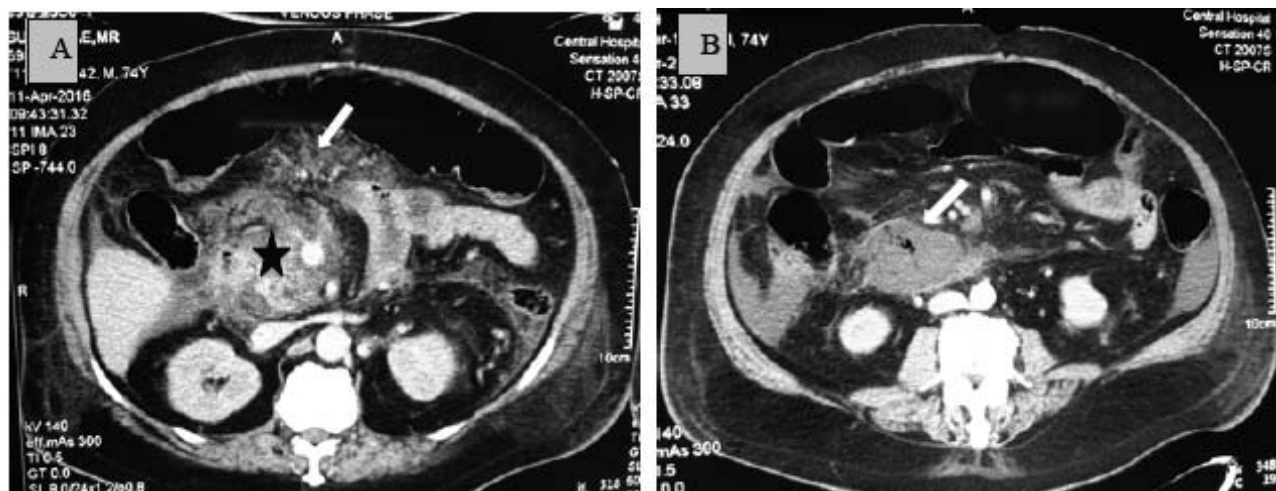


Figure 6. A 69-year-old male presented with abdominal pain for 2 weeks: CECT: A) Enlarged and heterogeneous enhancing pancreatic head (star), fat stranding at the mesentery (white arrow); parenchymal pancreatic necrosis. B) 1cm below a) a fluid collection containing fat streak (ANC) and gas bubbles at the right anterior pararenal space (white arrow) just inferior to the pancreatic head: infected necrotic pancreatitis; peripancreatic necrosis.

Table 3. Grading severity of acute pancreatitis according to Balthazar CTSI score.

Severity	Score	No. of patients	%
Total		53	100
Mild	0-3	25	47
Moderate	4-6	16	30
Severe	7-10	12	23

Table 4. Grading severity of AP according to the 2012 revised Atlanta classification.

Severity	No. of patients	Organ failure	No. of death
Mild	24	0	0
Moderate	25	5	0
Severe	4	4	3

Table 5. Patient outcomes using Balthazar CTSI scores.

Outcome parameter/ No. of patients	Total (n = 53)		Mild (n = 25)		Moderate (n = 16)		Severe (n = 12)	
	No.	%	No.	%	No.	%	No.	%
Intervention/drainage	4	8	0	0	1	2	3	6
Surgical debridement	3	6	0	0	1	2	2	4
Organ failure	9	17	2	4	1	2	6	11
Death	3	6	0	0	1	2	2	4

Chi-square for trend, significant at $P < 0.05$

Table 6. Patient outcomes using 2012 revised Atlanta classification.

Outcome parameter/ No. of patients	Total (n = 53)		Mild (n = 24)		Moderate (n = 25)		Severe (n = 4)	
	No.	%	No.	%	No.	%	No.	%
Intervention/drainage	3	6	0	0	2	4	1	2
Surgical debridement	2	4	0	0	1	2	1	2
Organ failure	9	17	0	0	5	9	4	8
Death	3	6	0	0	0	0	3	6

Chi-square for trend, significant at $P < 0.05$

The majority of the cases were categorized as mild pancreatitis according to their Balthazar CTSI scores (Table 3).

According to their 2012 revised Atlanta classification, the majority of the cases were categorized as moderate pancreatitis (Table 4).

Balthazar CTSI was associated with intervention/drainage, surgical debridement and death ($P = 0.01$, 0.04 and 0.04 , respectively). There was no association between Balthazar CTSI and organ failure ($P = 0.07$) (Table 5).

The revised Atlanta classification severity grading was associated with intervention/drainage, surgical debridement, organ failure and death ($P = 0.04$, 0.04 , 0.05 and < 0.01 , respectively). Death is seen in only severe grading in the revised classification (Table 6).

Discussion

The recent 2012 revision of the Atlanta classification is used for the classification of AP. The

present study is one of a few studies that used the definition and severity evaluation of AP according to the revised Atlanta classification to described CT findings of AP and study correlations between CT severity index (CTSI) with clinical outcomes. The study group consisted of 33 males and 20 females. These data are similar to those of the patients in the previous studies.^(13, 14)

In the present study, extrapancreatic inflammatory changes were the most common CT findings seen in 87% of AP comparable to Mendez G, *et al.*, who found these findings in 87.5%⁽¹⁵⁾, which included fat stranding and/or ANC. The most frequent sites of involvement were the left anterior pararenal space (51%), both the right and left anterior pararenal spaces (25%) and the mesentery (26%), whereas Mendez G, *et al.* showed the most common sites as the lesser sac (62.5%), the left anterior pararenal space (40.6%) and the posterior pararenal space (25%).⁽¹⁵⁾ The second most common finding in this study was

pancreatic enlargement, which was found in 77%. Silverstein W, *et al.* found enlargement of the pancreas in 68% as in this study⁽¹⁴⁾ and similar findings were concluded in the study of Banday IA, *et al.*⁽¹⁶⁾ However, this study found focal pancreatic enlargement (43%) more than diffuse enlargement (34%) which was different from Silverstien W, *et al.*⁽¹⁴⁾ Nineteen patients (83%) of focal pancreatic enlargement in this study had pancreatic tail or combine body and tail enlargement which was the reason of the predominate left anterior pararenal extrapancreatic inflammatory change.

The most common associated CT finding was pleural effusion seen in 57%, bilateral and left pleural effusion being commoner, similar to Balthazar EJ.⁽¹⁷⁾ who found pulmonary infiltration or pleural effusion in 15 - 55% and an increased predictive value with bilateral or left pleural effusion.

Left Gerota's fascia and GI wall thickening were also common findings in the present study seen in 19 patients (36%) and 17 patients (32%), respectively. A study by Banday IA, *et al.* has reported GI involvement in 13 patients (26%).⁽¹⁶⁾ The authors found duodenal wall thickening (71%) was the most common GI involvement in this study. This can be explained by the location of the 2nd part of duodenum itself which abuts the pancreatic head in the anterior pararenal space. Ascites was presented in 13 patients (25%) in this study, however, the incidence seems lower than that of 36% studied by Banday IA, *et al.*⁽¹⁶⁾ Venous thrombosis was seen in 2 patients (4%).

Thirty-two patients (60%) in this study had pancreatic necrosis (NP), parenchymal, peripancreatic and combined necrosis in 6 (11%), 8 (15%) and 18 (34%) patients, respectively, where as Balthazar EJ. detected pancreatic necrosis for 22%.⁽¹⁷⁾ This discordance could be explained by the definition of NP according to the revised Atlanta classification 2012 using by this study. Including parenchymal and/or peripancreatic necrosis in the revised Atlanta classification 2012, but not in Balthazar's classification, would step up treatment for the patients of peripancreatic necrosis.⁽⁷⁾

There were 55% of the patients in this study who had local complications. ANC was the most common finding found in 49% of patients and WON was seen in 4%, this was due to most patients (94%) undergoing CT examination within 4 weeks after onset of AP. Only one case (2%) of infected necrotizing pancreatitis in this study showed combined necrosis, which was comparable to 2.9% studied by Silverstien W, *et al.*⁽¹⁴⁾

Along with Balthazar CTSI scores, AP was graded as mild AP in 25 (47%), moderate AP in 16 (30%) and severe AP in 12 (23%) patients in this study. The study of Banday IA, *et al.* showed the majority of patients were classified as mild AP in 22 (44%) patients which was comparable to this study. However, a smaller number of patients were placed as moderate AP in 11(22%) and much larger number of patients as severe AP 17/50 (34%).⁽¹⁶⁾

As compared with the 2012 revised Atlanta classification, the number categorized as moderate AP increased to be 25 cases (47%), and of severe AP decreased to be 4 cases (8%). This demonstrated the patients without organ failure or with transient organ failure were reclassified to moderate AP and a patient classified as mild AP with local complications was reclassified as moderate AP.

Balthazar CTSI associated with intervention/drainage, surgical debridement and death. There was no association between Balthazar CTSI and organ failure. The revised Atlanta classification severity grading was associated with all clinical outcomes. Organ failure and death were more associated with the 2012 revised Atlanta classification as compared to Balthazar CTSI. The revised Atlanta classification seems to be a good predictor for clinical outcomes of AP.⁽¹⁸⁾

The limitation of the present study is its small sample size. CT examination was not performed for every patient diagnosed with acute pancreatitis and some cases were examined with only nonenhanced CT and were excluded from this study.

Conclusion

The most common CT findings of acute pancreatitis at BMA General Hospital were extrapancreatic inflammatory change, including fat stranding and/or ANC at the anterior pararenal space, prominent on the left side, pancreatic enlargement especially focal pancreatic enlargement, pancreatic necrosis mainly combined necrosis, bilateral pleural effusion, and duodenal wall thickening. The higher incidence of pancreatic necrosis in this study was due to the new definition, according to the 2012 revision of the Atlanta classification which would step up treatment for the patients of peripancreatic necrosis. No association between Balthazar CTSI and organ failure was detected. The revised Atlanta classification severity grading was associated with all clinical outcomes, especially death.

Conflict of interest

The author has no potential conflict of interest to disclose.

References

1. Manfredi R, Brizi MG, Canade A, Vecchioli A, Marano P. Imaging of acute pancreatitis. *Rays* 2001;26:135-42.
2. Bradley EL 3rd. A clinical based classification system for acute pancreatitis. Summary of the International Symposium on Acute Pancreatitis, Atlanta, Ga, September 11-13, 1992. *Arch of Surg* 1993;128: 586-90.
3. Williford ME, Foster WL Jr, Halvorson RA, Thompson WM. Pancreatitis pseudocyst: comparative evaluation by sonography and computed tomography. *AJR Am J Roentgenol* 1983;140: 53-7.
4. Balthazar EJ, Robinson DL, Megibow AJ, Ranson JH. Acute pancreatitis: value of CT in established prognosis. *Radiology* 1990;174: 331-6.
5. Balthazar EJ, Freeny PC, vanSonnenberg E. Imaging and intervention in acute pancreatitis. *Radiology* 1994;193:297-306.
6. Mortelet KJ, Mergo PJ, Taylor HM, Weisner W, Cantisai V, Ernst MD, et al. Peripancreatic vascular abnormalities complicating acute pancreatitis: contrast-enhanced helical CT findings. *Eur J Radiol* 2004;52: 67-72.
7. Bank PA, Bollen TL, Dervenis C, Goozen HG, Johnson CD, Sarr MG, et al. Classification of acute pancreatitis-2012: revision of the Atlanta classification and definitions by international consensus. *Gut* 2013;62: 102-11.
8. Pramoolsinsap C, Kurathong S. Pancreatitis: an analysis of 106 patients admitted to Ramathibodi Hospital during 1969-1984. *J Med Assoc Thai* 1989; 72:74-81.
9. Navicharern P, Wesarachawit W, Sriussadaporn S, Pak-art R, Udomsawaengsup S, Nonthasoot B, et al. Management and outcome of severe acute pancreatitis. *J Med Assoc Thai* 2006;89 Suppl 3: S25-32.
10. Pongprasobchai S, Thamcharoen R, Manatsathit S. Changing of the etiology of acute pancreatitis after using a systemic search. *J Med Assoc Thai* 2009; 92 Suppl 2:S38-42.
11. Pongprasobchai S, Jianjaronwong V, Charatchareon-witthaya P, Komoltri C, Tanwandee T, Leelakusolvong S, et al. Erythrocyte sedimentation rate and C-reactive protein for the prediction of severity of acute pancreatitis. *Pancreas* 2010;39:1226-30.
12. Jirupabha B. Enhancement pattern and appearance of hepatocellular carcinoma through triple-phase MDCT. *Chula Med J* 2009;53:185-98.
13. Block S, Maier W, Bittner W, Buchler M, Malfertheiner P, Beger HG. Identification of pancreas necrosis in severe acute pancreatitis: imaging procedures versus clinical staging. *Gut* 1986; 27:1035-42.
14. Silverstein W, Isikoff MB, Hill MC, Barkin J. Diagnostic imaging of acute pancreatitis: prospective study using CT and sonography. *AJR Am J Roentgenol* 1981;137: 497-502.
15. Mendez Jr G, Isikoff MB, Hill MC. CT of acute pancreatitis: interim assessment. *AJR Am J Roentgenol* 1980;135:463-9.
16. Banday IA, Gatto I, Khan AM, Javeed J, Gupta G, Latieft M. Modified computed tomography severity index for evaluation of acute pancreatitis and its correlation with clinical outcome: A tertiary care hospital based observational study. *J Clin Diagn Res* 2015;9:TC01-5.
17. Balthazar EJ. Acute pancreatitis; assessment of severity with clinical and CT evaluation. *Radiology* 2002;223:603-13.
18. Shyu JY, Sainani NI, Shani VA, Chick JF, Chauhan NR, Conwell DL, et al. Necrotizing pancreatitis: diagnosis, imaging and intervention. *Radiographics* 2014;34: 1218-39.