

10-1-2019

Multiple primary GISTs: Unusual presentation as jejuno-jejunal intussusception

Busaba Jiruppabha

Follow this and additional works at: <https://digital.car.chula.ac.th/clmjournal>



Part of the [Medicine and Health Sciences Commons](#)

Recommended Citation

Jiruppabha, Busaba (2019) "Multiple primary GISTs: Unusual presentation as jejuno-jejunal intussusception," *Chulalongkorn Medical Journal*: Vol. 63: Iss. 4, Article 10.
Available at: <https://digital.car.chula.ac.th/clmjournal/vol63/iss4/10>

This Case Report is brought to you for free and open access by the Chulalongkorn Journal Online (CUJO) at Chula Digital Collections. It has been accepted for inclusion in Chulalongkorn Medical Journal by an authorized editor of Chula Digital Collections. For more information, please contact ChulaDC@car.chula.ac.th.

Case report

Multiple primary GISTs: Unusual presentation as jejunum-jejunal intussusception

Busaba Jiruppabha

Bangkok Metropolitan Administration General Hospital, Bangkok, Thailand

Gastrointestinal stromal tumors (GISTs) are rare, occurring in 10 - 15 per million, and 0.2% of all gastrointestinal tumors, and is generally considered a solitary tumor. This study presented a 57 year-old female with abdominal pain and intermittent vomiting for 6 months. Acute abdomen series did not show any evidence of a small bowel obstruction. Esophagogastroduodenoscopy (EGD) suggested partial small bowel obstruction. A contrast enhanced CT scan (CECT) of the abdomen demonstrated jejunum-jejunal intussusception induced by an intraluminal tumor and another two mesenteric tumors confirmed by histopathology and immunohistochemistry as GISTs. The patient had complete resection for treatment. She recovered without complication and remained well. This study reported a rare case of multiple primary GISTs with unusual presentation as intussusception. CECT is able to detect tumors, their location, suggest diagnosis, and define complications and metastasis.

Keywords: Multiple GISTs, jejunum-jejunal, CT, intussusception.

Gastrointestinal stromal tumors (GISTs) are rare in clinical conditions; globally, the incidence is 10-15 per million ⁽¹⁾, representing 0.2% of all gastrointestinal tumors ⁽²⁾, and most commonly arise in the stomach.^(2,3) Generally, it is considered a solitary tumor and the occurrence of multiple primary neoplasms is regarded as exceptional event. ⁽⁴⁾ Intussusception and obstruction is also a very uncommon presentation of these lesions because of their tendency to grow in an extraluminal fashion. ^(5,6)

This study reports a rare case of multiple primary GISTs where one causes jejunum-jejunal intussusception as a leading point, their CT findings and a review of the literature.

Case report

A 57- year-old female presented with abdominal pain, and intermittent vomiting for 6 months. She had persistent nausea and postprandial vomiting for 2 months. She was diagnosed and treated for gastritis but the clinical outcome did not improve. No familial history of GISTs or neurofibromatosis Type1 (NF1) was identified. Physical examination showed a palpable mass of 6 cm on the left paraumbilical region.

Acute abdomen series showed no evidence of gut obstruction or definite mass. She underwent esophagogastroduodenoscopy (EGD) revealing that there was large amount of food and bile contents retained, suggestive of a partial small bowel obstruction. A CT scan of the upper abdomen (non-contrast and post-contrast enhanced scans) was performed and showed a bowel within bowel appearance on the left mid abdomen, a jejunum-jejunal intussusception containing a 4.0 × 4.0 cm² round enhancing mass with central necrosis at leading point, causing proximal small bowel obstruction.

A 5.0 × 4.6 × 4.4 cm³ mixed solid-cystic round mass with heterogeneous enhancement of the solid part was observed at the paramedian left upper abdomen. A 4.4 × 4.1 × 4.8 cm³ round-shaped, homogeneous enhancing mass was noted at the left upper abdomen, anterior-inferior-medial to the aforementioned lesion, and just medial to the intussusception. No hepatic mass, peritoneal nodules, free fluid or enlarged lymph nodes were detected. (Figure 1, 2 and 3)

She underwent an exploratory laparotomy that identified a jejunum-jejunal intussusception causing by a 4.5 cm intraluminal jejunal tumor as a leading point. Another tumor, 5 cm in diameter in the mesentery of the proximal jejunum was observed (Figure 4). Two mesenteric tumors were removed. A small bowel-including mesentery resection around the intussusception with primary anastomosis was done.

Correspondence to: Busaba Jiruppabha, Bangkok Metropolitan Administration General Hospital, Bangkok 10100, Thailand.

E-mail: busaba.12@yahoo.com

Received: November 13, 2018

Revised: December 12, 2018

Accepted: December 20, 2018

A pathologic report showed three tumors: two jejunal mesenteric masses 5.0 cm in diameter each, and a 4.5 cm intraluminal jejunal mass. All tumors were confirmed by histopathology and immuno-

histochemistry (positive CD 117) as GISTs with low mitotic figure (2 - 4/50 HPFs). She recovered well. Her follow up was without complication.

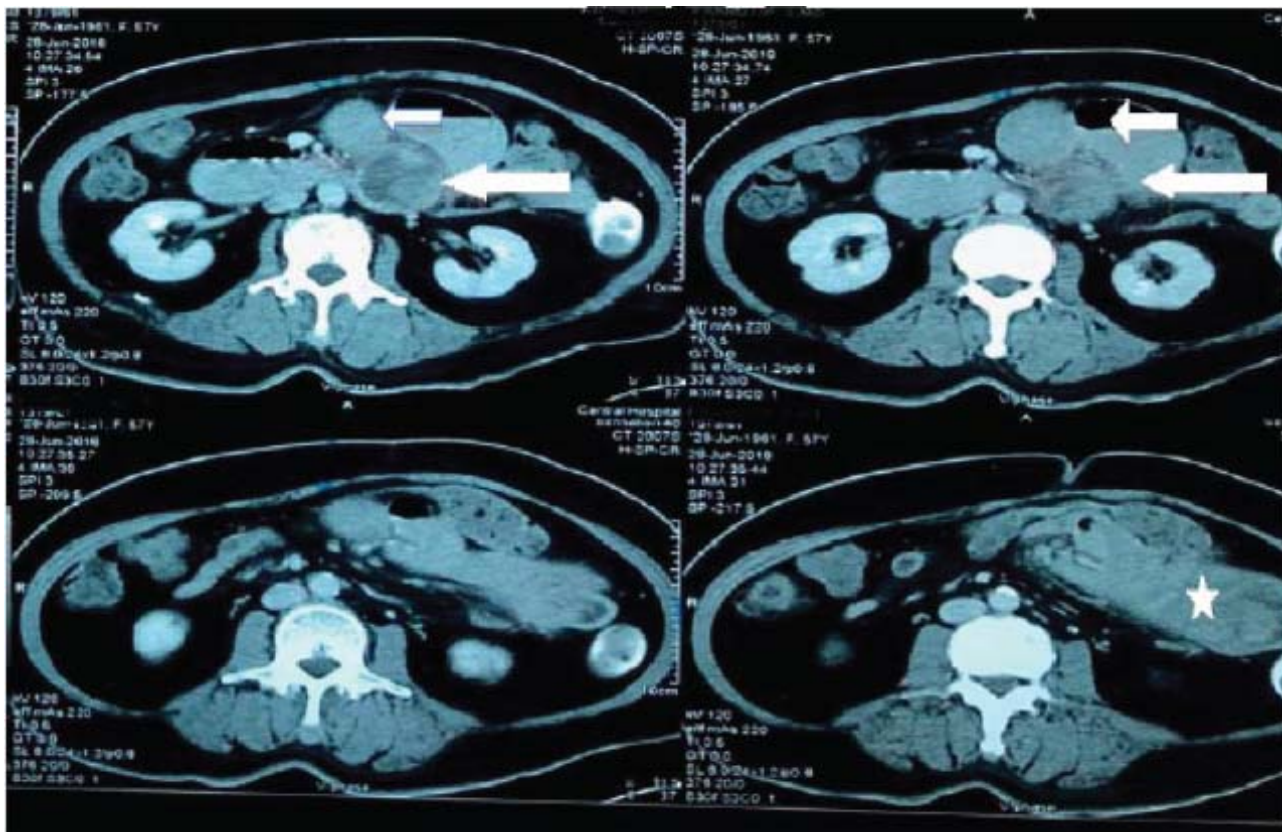


Figure 1. Axial CECT images: Two mesenteric GISTs: a 5.0 cm round solid-cystic one shows heterogeneous enhancement of the solid part and non-enhancing hypodensity area of cystic or necrotic component (long white arrows) and a 4.4 cm round homogeneous enhancing mass located anteriorly (short white arrows). A jeuno-jejunal intussusception was just inferior to mesenteric tumors. (star)

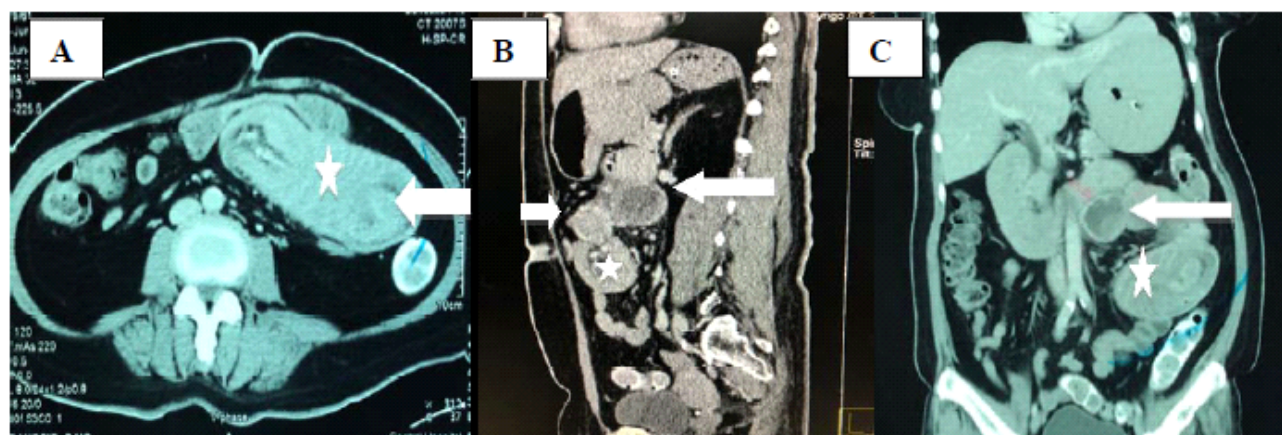


Figure 2. CECT: (A) Axial, (B) Sagittal, (C) Coronal images: A jeuno-jejunal intussusception with an intraluminal GIST as a leading point: A bowel within bowel appearance (stars) at the left sided abdomen and a 4.0 cm round enhancing mass with a central hypodensity area of necrosis or cystic degeneration as a leading point (white arrow in A) was seen. Another two mesenteric GISTs located just superior-medial to the intussusception were seen (white arrows in B and C).

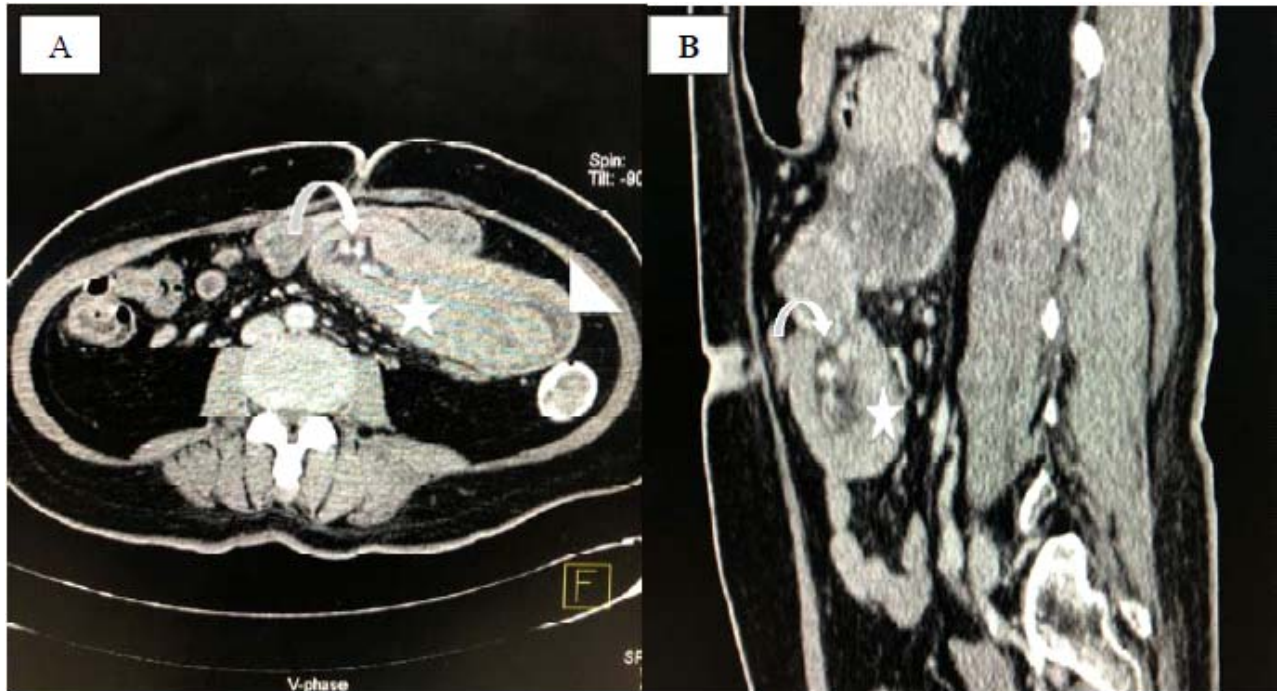

Figure 3. CECT: (A) Axial, (B) Sagittal images: A bowel within bowel appearance seen as a sausage-shaped mass in (A) (star) and atypical target-like mass in (B) (star) showed hypodensity of mesenteric fat and mesenteric vessel (curve arrows) within thick-walled intussusciens (white arrowhead in A). Differentiation between intussusceptum and intussusciens was difficult due to bowel wall edema.

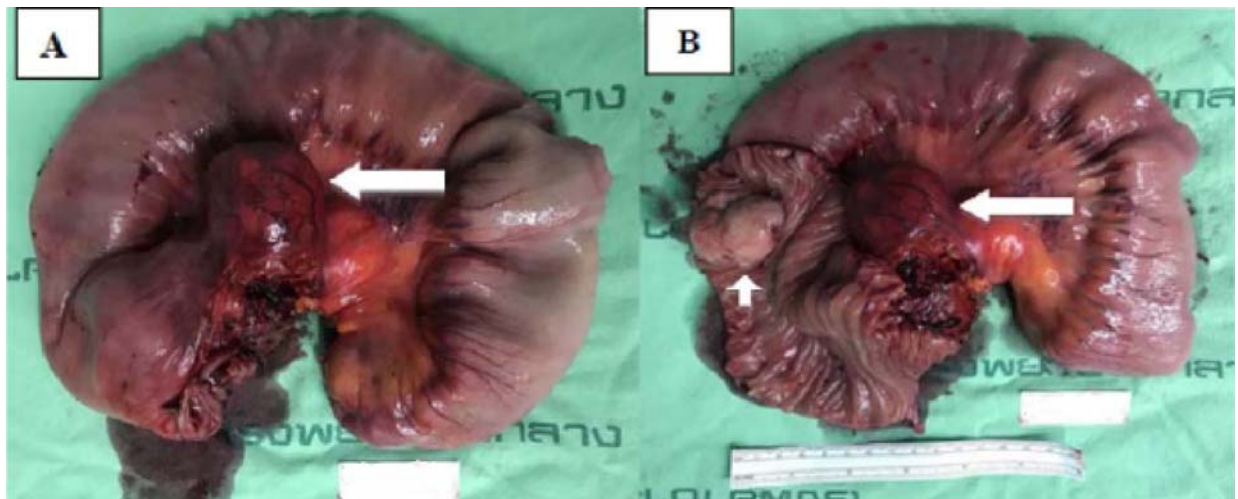


Figure 4. (A) A 5.0 cm GIST at mesentery of the proximal jejunum (long white arrows in A and B) was noted. (B) A 4.5 cm intraluminal jejunal GIST (short white arrows) was identified as a leading point of intussusception. The other mesenteric mass was not shown in these pictures.

Discussion

GISTs are mesenchymal tumors occurring anywhere along the gastrointestinal tract and are believed to originate from the interstitial cells of

Cajal. ^(2,3,7) They generally arise as solitary tumors in the stomach (50 – 60 %), small bowel (25 – 30 %), colon and rectum (5 – 10 %), esophagus (5 %), and other localizations (<1 %). ^(1,8)

They may occur primarily in the omentum, mesentery, and retroperitoneum.^(7,9) Multiple primary GISTs seem to be a less common scenario which may be found in different clinical contexts; sporadic, familial GISTs syndrome, as a component of Carney's triad, Carney-Stratakis syndrome, Von Recklinghausen disease or neurofibromatosis type I, and as metastatic disease in advanced malignant GISTs.^(8, 10)

CT findings of GISTs: the enhancement pattern can vary from homogeneous enhancement to heterogeneous enhancement, with or without ulceration. GISTs was found to be well-defined tumors with homogenous enhancement⁽¹¹⁾ and also found as large heterogeneously enhancing masses due to areas of necrosis, hemorrhage or cystic degeneration.⁽⁷⁾ Cystic changes are not seen commonly, but have been reported in rapidly growing primary GISTs.⁽¹²⁾ There is no correlation between degree of necrosis, hemorrhage, cyst formation or contrast enhancement on CT imaging and malignant potential.⁽⁷⁾ This reported case showed both enhancement patterns: homogeneous enhancing pattern of a mesenteric mass and heterogeneous enhancement with necrosis or cystic degeneration of the other two masses.

CT findings suggested that malignant GISTs are lesions with sizes larger than 5 cm, metastasis, invasion of adjacent organs^(9,13) and irregular contours.⁽¹³⁾

Differentiation between multiple primary and metastatic GISTs is important due to the different treatments of each condition. Multiple sporadic GISTs are generally characterized by the presence of two or three lesions, at the same site or in different sites⁽⁸⁾ as found in this case. Metastatic GISTs are found in 50 - 65% of cases.^(14 - 16) The liver, mesentery and omentum are the most frequent sites of metastasis.⁽¹⁶⁾ Liver metastasis is explained by hematogenous spread.⁽¹⁷⁾ Mesenteric and peritoneal metastasis are shown as multiple masses diffusely involved peritoneal surface and mesentery which is explained by the tumor extending beyond the serosa and becoming a serosal tumor seeding and peritoneal implants, and often shown accompanying liver metastasis.⁽¹⁶⁾

Differential diagnosis of tumors of GIST include adenocarcinoma, lymphoma, peritoneal carcinomatosis, carcinoid, metastasis, and other mesenchymal neoplasm, e.g. leiomyoma.⁽¹⁸⁾

This case was shown to be of three sporadic primary GISTs: one was an intraluminal jejunal tumor and two were jejunal mesenteric tumors without

hepatic lesion, peritoneal seeding, familial history of GISTs, or tumor of other organs.

GISTs usually involve the outer muscular layer, and have a propensity for exophytic growth. Therefore, the most common appearance is that of a mass arising from the intestinal wall and projecting into the abdominal cavity.^(11, 19, 20)

Intussusception and obstruction are a very uncommon presentation of these lesions because of their tendency to grow in an extraluminal fashion.^(5,6) Intussusception in adults is rather uncommon, accounting for 5% of all cases of intussusceptions, and 1% - 5% of bowel obstruction.⁽²¹⁾ In contrast to childhood where intussusception is idiopathic in 90% of cases, in adults a pathologic lesion is found in more than 90% of cases; neoplasms is considered to be the cause in 65% of the cases. A few cases of small bowel intussusceptions from stromal tumors in adults have been described in the medical literature.^(2, 3, 5, 6, 22, 23)

Most adult patients with intussusception present with chronic and nonspecific symptoms suggestive of intestinal obstruction. Abdominal pain is the most common symptom followed by nausea, vomiting, and a palpable abdominal mass.^(21, 24) Preoperative diagnosis is often difficult because of nonspecific symptoms.^(2, 3, 8) Intussusception is correctly and preoperatively diagnosed in only one-third of cases.^(2, 5)

Intussusception is the invagination of a bowel loop with its mesenteric fold (intussusceptum) into the lumen of a contiguous portion of bowel (intussusciens) as a result of peristalsis.⁽²⁴⁾

CT findings of intussusception: the presence of a bowel within bowel configuration with or without mesenteric fat and mesenteric vessels is a pathognomonic characteristic which can be seen as a target-like or sausage-shaped mass. The presence of a lead point, the configuration of the lead mass, the degree of bowel wall edema, and the amount of invaginated mesenteric fat all affect the appearance of an intussusception.⁽²⁴⁾ The intussusception of this case was shown to be a bowel within bowel appearance but differentiation between intussusceptum and intussusciens was difficult due to bowel wall edema so the typical multilayer of target sign was not identified; however, a sausage-shaped mass and atypical target-like mass containing mesenteric fat and mesenteric vessel were evident which were pathognomonic characteristics of this condition. (Figure 2 and 3)

This case presented with abdominal pain, vomiting and abdominal mass, and CT showed a bowel within bowel appearance and also indicated the cause of intussusception as a round necrotic mass at the leading point and incidental findings of another two mesenteric tumors. (Figure 1 and 2)

Taking all of these characteristics, the preoperative CT scan performed in this patient yielded excellent information which was able to detect the lesions, locate their sites, suggest diagnosis, extension of disease, complications, metastasis, and correlated well with the surgical findings.

Tumor size, tumor site and mitotic index are the main variables used in risk stratification systems. As this case's tumor size was not larger than 5 cm, the tumor was located at the small bowel and the mitotic index was less than 5 per HPFs, according to the risk stratification system developed by National Institute of Health (NIH), also called Fletcher's criteria⁽²⁵⁾, this case belonged to the low risk category.

Surgery is the primary therapeutic option with the goal being complete resection for nonmetastatic GISTs. Lymph node metastases are rare and routine removal of lymph nodes is typically not necessary.⁽²⁶⁾ This case underwent surgery, the three GISTs, the jejunal segment, and its mesentery were removed with free margin. The treatment was complete by with surgery without additional imatinib due to the low risk of these tumors.

In cases of high risk category cases who need imatinib for adjuvant therapy, CT can evaluate the response to treatment as well.⁽²⁷⁾

Conclusion

GISTs are a subset of mesenchymal tumors occurring along the GI tract and originating from interstitial cells of Cajal, and are usually considered single tumors. Multiple primary GISTs is less common. Clinical presentations of GISTs are not specific. Intussusception as presentation of GISTs is infrequent. Contrast enhanced CT scans of the abdomen are able to detect tumors, their locations, suggest diagnosis, define complications, and metastasis which are useful for designing primary and adjuvant therapy, and also evaluate response of treatment.

This study reported multiple primary GISTs with intussusception as an unusual presentation of GISTs.

Conflict of interest

The author has no potential conflict of interest to disclose.

References

1. Soreide K, Sandvik OM, Soreide JA, Gilijaca V, Jureckova A, Bulusu VR. Global epidemiology of gastrointestinal stromal tumours (GIST): A systematic review of population-based cohort studies. *Cancer Epidemiol* 2016;40:39-46.
2. Zakaria AH, Daradkeh S. Jejunojejunal intussusception induced by a gastrointestinal stromal tumor. *Case Rep Surg* 2012;2012:173680.
3. Sankey RE, Maatouk M, Mahmood A, Raja M. Case report: Jejunal gastrointestinal stromal tumour, a rare tumour, with a challenging diagnosis and a successful treatment. *J Surg Case Rep* 2015;2015.
4. Gasparotto D, Rossi S, Baerzi I, Doglioni C, Marzotto A, Hornick JL, et al. Multiple primary sporadic gastrointestinal stromal tumors in the adult: an underestimated entity. *Clin Cancer Res* 2008;14: 5715-21.
5. Rabbani K, Narjis Y, Finech B, Elidrissi A. Unusual malignant cause of adult intussusception: Stromal tumor of the small bowel. *J Emerg Trauma Shock* 2010; 3:306.
6. Martis JJ, Rajeshwara KV, Murulya KS, Raghavendra BK, Alex KM. A rare cause of jejunojejunal intussusception in an adult. *Indian J Surg* 2013;75: 18-20.
7. Levy AD, Remotti HE, Thompson WM, Sobin LH, Miettinen M. Gastrointestinal stromal tumors: radiologic features with pathologic correlation. *Radiographics* 2003; 23:283-304.
8. Diaz-Delgado M, Hernandez-Amate A, Sanchez-Leon M, Pereira-Gallardo S, Prieto-Sanchez E, Jimenez-Saenz M, et al. Multiple non-metastatic gastrointestinal stromal tumors. Differential features. *Rev Esp Enferm Dig* 2010;102:489-97.
9. Ulsan S, Koc Z, Kayaselcuk F. Gastrointestinal stromal tumors: CT findings. *Br J Radiol* 2008;81: 618-23.
10. Beltran MA, Cruces KS, Barria C, Verdugo G. Multiple gastrointestinal stromal tumors of the ileum and neurofibromatosis type 1. *J Gastrointest Surg* 2006; 10:297-301.
11. Lee CM, Chen HC, Leung TK, Chen YY. Gastrointestinal stromal tumor: Computed tomographic features. *World J Gastroenterol* 2004;10:2417-8.
12. Ding G, Yang J, Cheng S, Kai L, Nan L, Zhang S, et al. A rare case of rapid growth of exophytic gastrointestinal stromal tumor of stomach. *Dig Dis Sci* 2005;50:820-3.
13. Tateishi U, Hasegawa T, Satake M, Moriyama N. Gastrointestinal stromal tumor. Correlation of

- computed tomography findings with tumor grade and mortality. *J Comput Assist Tomogr* 2003;27:792-8.
14. Nilsson B, Bumming P, Meis-Kindblom JM, Oden A, Dortok A, Gustavsson B, et al. Gastrointestinal stromal tumors: the incidence, prevalence, clinical course and prognostication in preimatinib mesylate era—a population-based study in western Sweden. *Cancer* 2005;103:821–9.
 15. Katz SC, DeMatteo RP. Gastrointestinal stromal tumors and leiomyosarcoma. *J Surg Oncol* 2008;97:350–9.
 16. Patnaik S, Jyotsnarani Y, Rammurti S. Radiological features of metastatic gastrointestinal stromal tumors. *J Clin Imaging Sci* 2012;2:43.
 17. Hong X, Choi H, Loyer EM, Benjamin RS, Trent JC, Charnsangvej C. Gastrointestinal stromal tumor: role of CT in diagnosis and in response evaluation and surveillance after treatment with Imatinib. *Radiographics* 2006;26:481-95.
 18. Sripathi S, Rajagopal K, Srivastava RK, Ayachit A. CT features, mimics and atypical presentations of gastrointestinal stromal tumor (GIST). *Indian J Radiol Imaging* 2011;21:176-81.
 19. Hersh MR, Choi J, Garrett C, Clark R. Imaging gastrointestinal stromal tumors. *Cancer Control* 2005;12:111–5.
 20. Suster S. Gastrointestinal stromal tumors. *Semin Diagn Pathol* 1996;13:297–313.
 21. Azar T, Berger DL. Adult intussusception. *Ann Surg* 1997;226:134-8.
 22. Gupta A, Gupta S, Tandon A, Kotru M, Kumar S. Gastrointestinal stromal tumor causing ileo-ileal intussusception in an adult patient a rare presentation with review of literature. *Pan Afr Med J* 2011;8:29.
 23. Randhawa MA, Kaynat S, Niaz H, Shahzad T. Intraluminal gist, a rare cause of ileo-ileal intussusception in an elderly male. *Arch Clin Biomed Res* 2018;2:68-77.
 24. Kim YH, Blake MA, Harisinghani MG, Archer-Arroyo K, Hahn PF, Pitman MB, et al. Adult intestinal intussusception: CT appearances and identification of a causative lead point. *Radiographics* 2006;26:733-44.
 25. Demetri GD, von Mehren M, Antonescu CR, DeMatteo RP, Ganjoo KN, Maki RG, et al. NCCN Task Force report: update on the management of patients with gastrointestinal stromal tumours. *J Natl Compr Canc Netw* 2010;8 Suppl 2:S1-41.
 26. Raut CP, Dematteo RP. Evidence-guided surgical management of GIST: beyond a simple case of benign and malignant. *Ann Surg Oncol* 2008;15:1542-3.
 27. Sriariyametta S, Sriuranpong V, Arjhansiri K, Chaopathomkul B. CT appearances of responsive gastrointestinal stromal tumors (GISTs) after imatinib mesylate treatment. *Chula Med J* 2011;55:559 – 70.