

10-1-2019

Evaluation of T2 value for detection of metastatic cervical lymph node in head and neck squamous cell carcinoma compared with 18F-FDG PET/CT

Netsiri Dumrongpisutikul

Vorada Sonthithavorn

Follow this and additional works at: <https://digital.car.chula.ac.th/clmjournal>



Part of the [Medicine and Health Sciences Commons](#)

Recommended Citation

Dumrongpisutikul, Netsiri and Sonthithavorn, Vorada (2019) "Evaluation of T2 value for detection of metastatic cervical lymph node in head and neck squamous cell carcinoma compared with 18F-FDG PET/CT," *Chulalongkorn Medical Journal*: Vol. 63: Iss. 4, Article 2.

Available at: <https://digital.car.chula.ac.th/clmjournal/vol63/iss4/2>

This Article is brought to you for free and open access by the Chulalongkorn Journal Online (CUJO) at Chula Digital Collections. It has been accepted for inclusion in Chulalongkorn Medical Journal by an authorized editor of Chula Digital Collections. For more information, please contact ChulaDC@car.chula.ac.th.

Original article

Evaluation of T2 value for detection of metastatic cervical lymph node in head and neck squamous cell carcinoma compared with 18F-FDG PET/CT

Netsiri Dumrongpisutikul^{a*}, Vorada Sonthithavorn^{a,b}

^aDepartment of Radiology, Faculty of Medicine, Chulalongkorn University, Bangkok, Thailand

^bDepartment of Radiology, King Chulalongkorn Memorial Hospital, Bangkok, Thailand

Background: Difference in the staging of head and neck cancer leads to different treatments and managements of the patients to minimize mortality and improve long-term health and social consequences.

Objective: This study aimed to utilize the T2 signal value on T2WI for early detection of metastatic lymph nodes.

Methods: We retrospectively reviewed 18-fluoro-deoxyglucose positron emission tomography/computed tomography (18F-FDG PET/CT) and magnetic resonance imaging (MRI) results of patients with head and neck squamous cell carcinomas, from January 2012 to February 2018. The ratio between the T2 signal values of the lymph nodes and sternocleidomastoid muscles were calculated for each lymph node. Analytical comparisons between T2 signal value ratios of the lymph nodes with and without 18F-FDG PET uptake were performed. The differences of T2 signal value ratios in pre-treatment and post-radiation lymph nodes were analyzed.

Results: Twenty-six patients were recruited, with 54 lymph nodes in the suspected malignant group and 50 lymph nodes from the suspected benign group. There was no significant T2 signal value ratios in the suspected metastatic as compared with benign nodes. However, the minimum T2 signal value ratio of the suspected benign group was not lower than 1.5. The receiver operating characteristic (ROC) analysis of the mean T2 signal value ratio at cut-off value of 1.33 showed an area under the curve (AUC) of 0.55, a sensitivity of 57.14% and a specificity of 56.25%. History of previous radiation on the neck region showed significantly decreased T2 signal value ratios when both groups of lymph nodes were combined and in the suspected benign group. Inter-observer reliability was excellent (ICC 0.870).

Conclusions: No cut-off T2 signal value ratio exhibits high sensitivity or specificity for detection of metastatic lymph nodes.

Keywords: Cervical lymph node, head and neck cancers, PET/CT, squamous cell carcinoma, T2 signal value.

Head and neck cancers are the ninth most common malignancy worldwide. More than 90% of these cancers are squamous cell carcinomas.⁽¹⁾ Staging of head and neck cancers is based on the American Joint Committee on Cancer TNM staging Classification (AJCC) 8th edition, 2018, and depends on T: primary tumor; N: regional lymph nodes; M: distant metastasis. Difference in cancer staging leads to different treatment and management of the patients. The routine imaging investigation for the

workup includes computed tomography (CT) or magnetic resonance imaging (MRI), with 18-fluoro-deoxyglucose positron emission tomography (18F-FDG PET/CT) considered for advanced stage.⁽²⁾ For the treatment of head and neck cancer, 18F-FDG PET/CT has a role for surveillance on NI-RADS.⁽³⁾ On quantitative analysis, standardized uptake value (SUV) are more than 2.5, positive and negative predictive values were 93% and 86%.^(4,5)

Early detection of recurrent disease can minimize mortality and improve long-term health and social consequences. However, 18F-FDG PET/CT is not extensively available in most countries. MRI is a more accessible modality for the diagnosis of primary cancer, detection of local recurrence and metastatic lymph nodes. This study aimed to detect early metastatic lymph nodes before qualitative and

*Correspondence to: Netsiri Dumrongpisutikul, Department of Radiology, Faculty of Medicine, Chulalongkorn University, Bangkok 10330, Thailand.

E-mail: netsiri.d@chula.ac.th

Received: January 20, 2019

Revised: March 13, 2019

Accepted: March 18, 2019

morphological changes by utilizing the T2 signal value of tissue characteristics detected on MRI. The T2 signal value represents quantitative tissue specific characteristics from the relaxation time, the decay of transverse magnetization from 100% to 37%. A recent study reported the T2* value is useful at differentiating metastatic from benign axillary lymph nodes in patients with breast cancer.⁽⁶⁾

Materials and methods

Patients

The Institutional Review Board (IRB) has approved this study for a retrospective review, and informed consent was waived. We reviewed an electronic radiologic database from the PAC system. Inclusion criteria were: (1) patients had the 18F-FDG PET/CT in the database system of King Chulalongkorn Memorial Hospital, Bangkok, Thailand, from January 1, 2012 to February 15, 2018; (2) patients had T2 weighted MRI sequence from the MRI nasopharynx or MRI simulation of the neck. Exclusion criteria were: (1) patients had no confirmed pathology for squamous cell carcinoma, either having no official report or slide review and record in OPD/IPD card; (2) duration between PET/CT and MRI study equals to or is more than 60 days; (3) MRI was not performed at King Chulalongkorn Memorial Hospital; (4) no detectable cervical lymph node that can place ROI within the solid part; (5) 18F-FDG PET/CT had some pathology which had markedly high SUV max at the neck region such as internal jugular vein thrombosis; (6) MRI of the nasopharynx had a cross talk artifact with signal loss at the end of the slides. From a total of one hundred and fifty-seven 18F-FDG PET/CT studies in patients with head and neck cancer, 26 patients matched the criteria and were finally recruited in this study.

Patients' clinical information were collected from the hospital information system (HIS) and included demographic data, pathology, data of other carcinoma and date of complete radiation therapy.

Imaging protocol

PET/CT studies were performed on the prepared patients. The preparation before PET/CT imaging included no eating or drinking except plain water for at least 4 hours, avoiding exercise for at least 24 hours, and using only shampoo without conditioner or oil. On day of examination, 18F-FDG was injected, then patients were told to relax and remain calm for about one hour. The studies were performed by using Siemens Biograph, (Erlangen, Germany) with 3 mm thickness from vertex to toe.

MRI studies were performed on 1.5 and 3.0 Tesla scanners (GE healthcare discovery MR750w or MR simulation, General Electric Healthcare, Madison, WI; Philips healthcare Ingenia, Philips Medical Systems, Amsterdam, the Netherlands; Siemens healthcare Skyra or Aera, Siemens healthcare, Erlangen, Germany), Axial T2 weighted images were performed with the range of TR 3,000 - 7,000 ms/TE 80 - 100 ms and 3 - 5 mm thickness with 0.5 - 3 mm spacing.

Image analysis

MRI images were reviewed by 2 readers (VS is a second-year neuroradiology fellow and ND is a neuroradiologist with 8 years of experience in neuroimaging), in the suspected malignant group. The average T2 signal value ratio between the two readers represents the T2 signal value ratio of the lymph node. We placed the region of interests (ROIs) to evaluate the T2 signal values using Synapse version 4.3.2, by Fujifilm Medical systems, Tokyo, Japan at the Department of Diagnostic Radiology. The researchers meticulously placed a ROI at least 10 mm² in size within the solid part of lymph nodes in both groups as well as in the normal appearing sternocleidomastoid muscles. In the lymph nodes with sizes that equal to or were more than 1.5 cm in maximal diameter, several ROIs were placed in the solid areas in several slices, and then the mean was used of the T2 signal value to represent the T2 signal value of the lymph node from each reader. The lymph nodes were divided in two groups, namely: suspected malignant and suspected benign. The definitions of suspected malignant lymph nodes were the cervical lymph nodes that showed 18F-FDG PET uptake with a SUV max of > 2.5 or morphological change on MRI such as round shaped, loss of fatty hilum or heterogeneous attenuation. The suspected benign nodes were the cervical lymph nodes which did not meet the aforementioned criteria. Inter-observer reliability was calculated in the suspected malignant group revealing excellent intraclass correlation. Then, the suspected benign group was reviewed by one reader.

All PET/CT images were reviewed by one reader, in the Siemens workstation in separate sessions at the Department of Nuclear Medicine, using the Syngo program 2006A, Siemens healthcare, Erlangen, Germany. The method for measurement of the SUV max value was to place the ROI in the overall included slices of the targeted lymph nodes, and selected slice of the sternocleidomastoid muscles.

Statistical analysis

The parametric continuous data is expressed as mean and standard deviation (SD). Independent *t* - test was used to compare the differences between genders, history of previous radiation on the neck region, primary tumor location, side of lymph node, and primary tumor, maximal diameter of lymph node, that were less or more than 1 cm, and lymph node locations. Inter-observer reliability was calculated by intraclass correlation coefficient (ICC) analysis, using 95% limits of agreement for the suspected malignant group.

Receiver operating characteristics curve (ROC curve) were analyzed to calculate the cutoff value, sensitivity, specificity, positive likelihood ratio, negative likelihood ratio, positive predictive value, negative predictive value, and accuracy. Chi-square test was used for comparison of the aforementioned variables at the appropriate cutoff value. Fisher exact test was used to compare the history of previous radiation on the neck region in the suspected malignant group and suspected benign group; Mann-Whitney U test for comparison of continuous variables such as age at appropriate cutoff value.

The threshold for statistical significance was *P* < 0.05. All statistical analyses were performed using statistical package for the social sciences software (SPSS) version 21.0 for Windows (SPSS, Inc., Chicago, IL).

Results

Twenty-six patients were recruited, with 104 cervical lymph nodes assigned into two groups, i.e., the suspected malignant group and suspected benign group, 54 and 50 nodes, respectively. Baseline characteristics of the patients are shown in Table 1.

The mean size of lymph nodes in the maximal dimension was 1.63 cm in the suspected malignant group and 0.83 cm in the suspected benign group. The mean T2 signal value ratio of reader 1 was 3.28 and 3.29 in the suspected malignant group and the suspected benign group, respectively. While, the mean T2 signal value ratio of reader 2 was 3.25 in the suspected malignant group. The average of T2 value ratio between the two readers in the suspected malignant group was 3.27. There was no significant T2 signal value ratio of the suspected metastatic and benign nodes. The SUV max values of cervical lymph nodes were 5.71 ± 3.06 in the suspected malignant group and 1.77 ± 0.66 in the suspected benign group. Baseline characteristics in cervical lymph nodes are shown in Table 2.

The ROC curve was analyzed from the mean of the T2 signal value ratios between the 2 readers using a SUV max of more than 2.5 as a standard to diagnose metastatic nodes. The area under ROC curve was 0.55 in Figure 1. At the cutoff T2 signal value ratio of 3.3, sensitivity, specificity, positive likelihood ratio, negative likelihood ratio, positive predictive value, negative predictive value and accuracy were 57.14%, 56.25%, 1.3061, 0.7619, 60.37%, 52.94% and 56.73%, respectively.

Table 1. Demographic data of the subjects in this study.

	n = 26	%
Age (years)		
Mean ± SD	56.92 ± 14.12	
Min-Max	26 - 85	
Gender		
Male	20	76.92
Female	6	23.08
Sided primary tumor		
Left	13	50.00
Right	9	34.62
Both	4	15.38
Location primary tumor		
Nasopharynx	11	42.31
Others	15	57.69
Duration between PET/CT and MRI		
Mean ± SD	12.19 ± 14.24 days	
Min - Max	0 - 58 days	
History previous radiation at neck region		
No	16	61.54
Yes	10	38.46

Table 2. Baseline characteristics of the cervical lymph nodes categorized in suspected the malignant group and suspected benign group.

	Suspected malignant (n = 54)		Suspected benign (n = 50)		Total (n = 104)	
	n	%	n	%	n	%
Sided cervical lymph nodes						
Left	26	48.15	25	50.00	51	49.04
Right	28	51.85	25	50.00	53	50.96
Location						
I	1	1.85	26	52.00	27	25.97
II/III/IV/V	43	79.63	21	42.00	64	61.53
RP	10	18.52	3	6.00	13	12.50
Size in maximal dimension (cm)						
Mean ± SD	1.63 ± 1.01		0.83 ± 0.27		1.25 ± 0.85	
Min - Max	0.6 - 4.7		0.4 - 1.6		0.4 - 4.7	
Average T2 value ratio						
Mean ± SD	3.27 ± 1.00		3.28 ± 0.75		3.28 ± 0.88	
Min - Max	0.67 - 6.20		1.5 - 5.26		0.67 - 6.20	
SUV max cervical lymph nodes						
Mean ± SD	5.71 ± 3.06		1.77 ± 0.66		3.82 ± 2.99	
SUV max ipsilateral sternocleidomastoid						
Mean ± SD	1.12 ± 0.23		1.08 ± 0.24		1.10 ± 0.23	

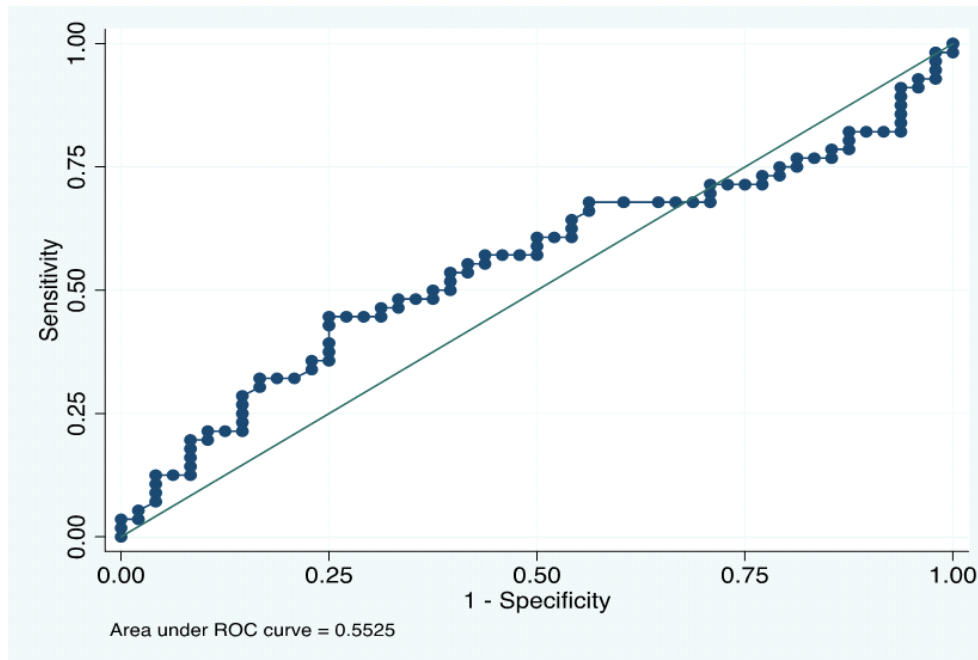


Figure 1. ROC analysis of the T2 signal value ratio of the combined group of the lymph nodes.

Comparisons of the data were performed among variables, at the cutoff T2 signal value ratio of 3.3. A significant *P* - value of 0.003 in the history of previous radiation on the neck region in the combined groups of lymph nodes was observed, as shown in Table 3.

Inter-observer reliability was analyzed via ICC statistics. The ICC was 0.870 (95% CI: 0.777 – 0.925), excellent, meaning strong inter-observer reliability, as shown in Figure 2.

Table 3. Comparison between different variables, at cut-off a T2 signal value ratio of 3.3 in combined groups of lymph nodes, suspected malignant and suspected benign groups.

Variables	Combined group lymph nodes	Suspected malignant	Suspected benign
Gender	0.016		
Age	0.395‡		
History of previous radiation at neck region	0.003	0.051†	0.022†
Primary tumor location (nasopharynx or others)	0.882		
Lymph node and primary tumor (same side/different side)	0.406		
Maximal diameter of lymph node (less than 1 cm/equal or more)	0.997		
Lymph node location (retropharyngeal or others)	0.711		
Duration between PET/CT and MRI	0.870‡		

Chi-Square test

‡Mann-Whitney U test

†Fisher's Exact Test

Significant if $P < 0.05$

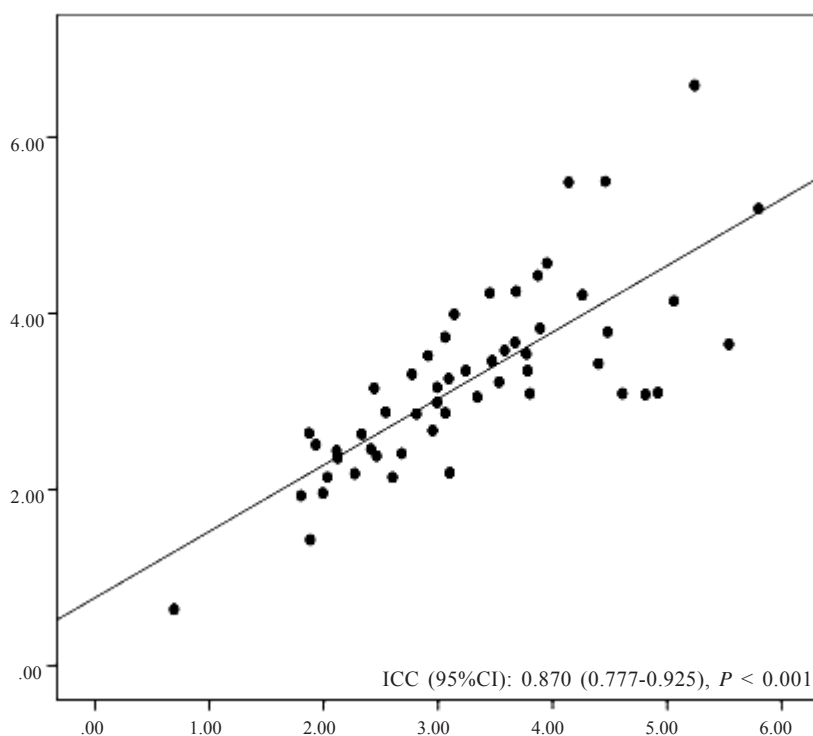


Figure 2. Inter-observer reliability in measurement of the T2 signal value ratio of cervical lymph nodes, in the suspected malignant group. (X-axis and Y-axis is T2 value ratios of reader 1 and reader 2, respectively and linear line of equality.)

Discussion

Early detection of abnormality of the cervical lymph nodes is useful for the surveillance of the disease. Histopathology of cervical lymph nodes is the gold standard, but it is invasive and cannot be used in every lymph node. Several previous studies of cervical lymph nodes metastasis in head and neck cancers are interesting in apparent diffusion

coefficients (ADC) value, and reported statistically lower ADC values in metastatic nodes compared with benign nodes⁽⁷⁻⁹⁾, and recurrent tumor compared with post-treatment change.⁽¹⁰⁾ Also, the study of breast cancer patients, mean T2* values are higher in metastatic axillary nodes compared with benign nodes.⁽⁶⁾

In our study, the mean T2 signal value ratio of the suspected malignant group and the suspected benign group is overlapping. The minimum T2 signal value ratio of the suspected malignant group (0.67) is lower than that of the suspected benign group (1.5). A T2 signal value ratio of less than 1.5 might be a clue for metastatic nodes. This finding is probably related to intermediate signal intensity on T2-weighted imaging of most primary lesions in head and neck cancer. Meanwhile, if we detect a high signal intensity on T2-weighted imaging of the solid small cervical lymph nodes, this may suggest benign.

From the ROC curve, the AUC is 0.55 and the sensitivity and specificity is just above 50% for the cutoff T2 value ratio of 3.3, implying that the T2 signal value ratio cannot be used to discriminate the lymph nodes. Inter-observer reliability between the two readers was excellent in the suspected malignant group. The suspected benign group and SUV max were measured by only reader 1.

Among several variables, the history of previous radiation at neck region showed significantly decreased T2 signal value ratio. One of the explanations is probably fibrotic change in post-radiation tissue resulting in decreased T2 value of cervical lymph nodes.⁽¹¹⁾ This may hinder imaging interpretation of recurrent lymph nodes, since the T2 signal will be decreased in both benign and metastatic groups.

This study has limitations, however. Firstly, the sample size was small and heterogeneous, because 18F-FDG PET/CT is an expensive modality and most of the head and neck cancer patients had CT imaging evaluation. This can lead to underpower of the study in clarifying the difference in T2 value ratios between the suspected malignant and benign groups. Further study including more subjects is recommended. Secondly, a SUV max cut point at 2.5 on 18F-FDG PET/CT is widely used in nuclear medicine to define malignant lesions. However, several false positives and false negatives of high SUV max are observed. Infection, inflammation, exercise, recent chemotherapy or recent radiation therapy can cause a false positive. Necrotic portions of the lymph nodes can cause a false negative. Thirdly, there might be some bias, since the readers were not blinded to 18F-FDG PET/CT images. The SUV max value and T2 value of the suspected benign lymph nodes were measured exclusively by one reader. However, the SUV max and T2 value ratios were measured in separate sessions and separate work stations, and

intraclass correlation was excellent in the suspected malignant group. Fourthly, the T2-weight images parameter were varied between each patient, however, we used the T2 value ratio to eliminate the effect from the different imaging protocols. Lastly, there is minimal variability of T2 value of the sternocleidomastoid muscle in different regions. It causes some effects to signal ratio.

Conclusions

No cutoff T2 signal value ratio exhibits high sensitivity or specificity for the detection of metastatic lymph nodes. However, we found a lower T2 signal intensity of the cervical lymph nodes in the patient with history of previous head and neck irradiation.

Conflict of interest

The authors of the article, hereby declare no conflict of interest regarding the writing of the paper.

References

1. Gupta B, Newell J, Narinder K. Global epidemiology of head and neck cancers: a continuing challenge. *Oncology* 2016;91:13-23.
2. National Comprehensive Cancer Network. NCCN clinical practice guidelines in oncology: Head and neck cancers version 1 [Internet]. 2018 [cited 2018 Feb 15]. Available from: <https://www.nccn.org>.
3. Cavazuti B, Hudgins P, Rath T, Branstetter C, Bagnon K, Corey A, et al. Neck imaging reporting and data system: an atlas of NI-RADS categories for head and neck cancer [Internet]. 2018 [cited 2018 Feb 15]. Available from: <https://www.acr.org/-/media/ACR/Files/RADS/NI-RADS/NIRADS-Atlas.pdf>.
4. Beggs AD, Hain SF, Curran KM, O'Doherty MJ. FDG-PET as a "metabolic biopsy" tool in non-lung lesions with indeterminate biopsy. *Eur J Nucl Med Mol Imaging* 2002;29:542-6.
5. Workman R, Coleman R. PET/CT essentials for clinical practice. Palo Alto, CA: Ebrary; 2007.
6. Li C, Meng S, Yang X, Wang J, Hu J. The value of T2* in differentiating metastatic from benign axillary lymph nodes in patients with breast cancer—a preliminary in vivo study. *PLoS One* 2014;9:e84038.
7. Choi YJ, Lee JH, Kim HO, Kim DY, Yoon RG, Cho SH, et al. Histogram analysis of apparent diffusion coefficients for occult tonsil cancer in patients with cervical nodal metastasis from an unknown primary site at presentation. *Radiology* 2016;278:146-55.
8. Zhong J, Lu Z, Xu L, Dong L, Qiao H, Hua R, et al.

The diagnostic value of cervical lymph node metastasis in head and neck squamous carcinoma by using diffusion-weighted magnetic resonance imaging and computed tomography perfusion. *Biomed Res Int* 2014;2014:260859.

9. Jin GQ, Yang J, Liu LD, Su DK, Wang DP, Zhao SF, et al. The diagnostic value of 1.5-T diffusion-weighted MR imaging in detecting 5 to 10 mm metastatic cervical lymph nodes of nasopharyngeal carcinoma. *Medicine (Baltimore)* 2016;95:e4286.
10. Acampora A, Manzo G, Fenza G, Busto G, Serino A, Manto A. High b-value diffusion MRI to differentiate recurrent tumors from post treatment changes in head and neck squamous cell carcinoma: a single center prospective study. *Biomed Res Int* 2016;2016:2865169.
11. Lell M, Baum U, Greess H, Nomayr A, Nkenke E, Koester M, et al. Head and neck tumors: imaging recurrent tumor and post-therapeutic changes with CT and MRI. *Eur J Radiol* 2000;33:239-47.