

1-1-2012

Esophageal necrosis after resection of descending thoracic aorta aneurysm: A case of successful treatment

K Luengtaviboon

W. Sindhvananda

Follow this and additional works at: <https://digital.car.chula.ac.th/clmjjournal>



Part of the [Medicine and Health Sciences Commons](#)

Recommended Citation

Luengtaviboon, K and Sindhvananda, W. (2012) "Esophageal necrosis after resection of descending thoracic aorta aneurysm: A case of successful treatment," *Chulalongkorn Medical Journal*: Vol. 56: Iss. 1, Article 7.

Available at: <https://digital.car.chula.ac.th/clmjjournal/vol56/iss1/7>

This Case Report is brought to you for free and open access by the Chulalongkorn Journal Online (CUJO) at Chula Digital Collections. It has been accepted for inclusion in Chulalongkorn Medical Journal by an authorized editor of Chula Digital Collections. For more information, please contact ChulaDC@car.chula.ac.th.

Esophageal necrosis after resection of descending thoracic aorta aneurysm: A case of successful treatment

Kittichai Luengtaviboon*

Wacharin Sindhvananda**

Luengtaviboon K, Sindhvananda W. Esophageal necrosis after resection of descending thoracic aorta aneurysm: A case of successful treatment. Chula Med J 2012 Jan - Feb; 56(1): 71 - 7

Esophageal necrosis is a rare complication of treatment of the descending thoracic or thoraco-abdominal aortic aneurysm. It is almost always fatal. Sepsis and bleeding secondary to dehiscence of the aortic- graft suture line are main mechanisms of death. However, these patients can be saved by aggressive medical and surgical treatment. A 40-year-old male was transferred to this hospital because of severe epigastric pain secondary to concealed rupture of a descending aortic aneurysm. Urgent aneurysmectomy and bypass graft was done using "clamp-and-go technique". He was in septic conditions approximately a week later. An abscess around the graft was confirmed by CT scan. The second operation was taken; the findings were necrosis of the lower esophagus with heavy contamination around the graft. The contaminations were removed as much as possible by saline irrigation and some suspicious aortic aneurysmal wall was resected then the graft was covered with pedical omental flap. Also, esophagectomy, gastrostomy, and feeding jejunostomy were done. Intravenous antibiotics were continued. His septic conditions seemed to be improved. Three weeks later, he became febrile due to remaining collections surrounding the graft. The third operation was taken in order to do another aggressive debridement and irrigation. Finally, he had no more the aortic infection and was discharged. Duration of all the mentioned treatments was approximately 5 months. A month later, reconstruction of the esophagus with colon was

* Department of Surgery, Faculty of Medicine, Chulalongkorn University

** Department of Anesthesiology, Faculty of Medicine, Chulalongkorn University

done in the fourth operation as the patient requested. Minimal complications occurred and were treated during this period. He was discharged home in approximately a month. Six months later at the follow-up encounter, he reported that he could eat regular diet and was full-time job. The total period of all the treatments including recoveries to have normal livings was approximately 1 year.

Keywords: *Esophageal necrosis, ruptured thoracic aortic aneurysm, surgical treatment.*

Reprint request: Luengtaviboon K. Department of Surgery, Faculty of Medicine, Chulalongkorn University, Bangkok10330, Thailand.

Received for publication. April 10, 2011.

กิตติชัย เหลืองทวีบุญ, วัชริน สินธวานนท์. การทะลุของหลอดอาหารหลังการผ่าตัดรักษาโรคหลอดเลือดโป่งพองในทรวงอกแตก: รายงานการรักษาที่ประสบความสำเร็จ. จุฬาลงกรณ์เวชสาร 2555 ม.ค. - ก.พ.; 56(1): 71 - 7

การผ่าตัดรักษาโรคหลอดเลือดโป่งพองในทรวงอกแตกมีภาวะแทรกซ้อนที่พบบ่อย แต่มีอันตรายสูงมากคือ การทะลุของหลอดอาหารและเกิดการติดเชื้ออย่างรุนแรง ทำให้ผู้ป่วยเสียชีวิตจากการติดเชื้อที่ควบคุมไม่ได้หรือมีเลือดออกมากเพราะรอยต่อระหว่างหลอดเลือดแดงใหญ่ และหลอดเลือดเทียมแยกออกเนื่องจากการติดเชื้อ ผู้ป่วยอายุ 40 ปีรายนี้มาโรงพยาบาลด้วยอาการปวดท้องและหลังรุนแรงและตรวจพบว่ามี การแตกของหลอดเลือดแดงใหญ่โป่งพองในทรวงอกซ้ายส่วนล่าง การผ่าตัดรักษาที่ค่อนข้างอันตรายโดยการตัดส่วนเส้นเลือดที่โป่งพองออกและทดแทนด้วยเส้นเลือดเทียม ด้วยเทคนิค 'clamp-and-go' หลังการผ่าตัดประมาณหนึ่งสัปดาห์ ผู้ป่วยมีภาวะติดเชื้อ และตรวจพบโพรงหนองรอบ ๆ หลอดเลือดเทียมจากการตรวจด้วยเอ็กเรย์คอมพิวเตอร์ ผู้ป่วยจึงได้รับการผ่าตัดครั้งที่สอง ซึ่งพบเศษอาหาร หนองรอบ ๆ หลอดเลือดเทียม และมีการทะลุของหลอดอาหารส่วนปลาย จึงทำการรักษาโดยการล้างสิ่งปนเปื้อนบนหลอดเลือดเทียมออกให้มากที่สุดด้วยน้ำเกลือรวมทั้งคลุมหลอดเลือดเทียมด้วยเยื่อไผ่และเยื่อไขมัน และทำการตัดหลอดอาหารออก ร่วมกับทำทางเบี่ยงทางเดินอาหาร หลังการผ่าตัดผู้ป่วยได้รับยาปฏิชีวนะทางหลอดเลือดดำ อาการติดเชื้อเริ่มดีขึ้น อย่างไรก็ตาม 3 สัปดาห์ถัดมาผู้ป่วยเริ่มมีไข้ และได้ตรวจพบโพรงหนองรอบ ๆ หลอดเลือดอีก จึงเข้ารับการผ่าตัดครั้งที่สามคือ การล้างสิ่งปนเปื้อนบนหลอดเลือดเทียมอย่างทั่วถึงอีกครั้ง ในที่สุดผู้ป่วยไม่มีอาการไข้และการติดเชื้อกลับมาอีก และได้กลับบ้าน โดยระยะเวลาในการรักษาที่กล่าวมาทั้งหมดนี้ประมาณ 5 เดือน หลังจากนั้นอีก 1 เดือน ผู้ป่วยขอให้ทำการผ่าตัดต่อทางเดินอาหารโดยใช้ลำไส้ใหญ่ ทดแทนหลอดอาหาร ซึ่งเป็นการผ่าตัดครั้งที่สี่ หลังการผ่าตัดมีภาวะแทรกซ้อนเล็กน้อยที่ต้องให้การรักษา ผู้ป่วยพักรักษาตัวครั้งนี้ประมาณ 1 เดือน ผู้ป่วยมาตรวจรักษาติดตามที่คลินิกหลังจากกลับบ้านไป 6 เดือน ครั้งนี้ผู้ป่วยให้ข้อมูลว่าสามารถรับประทานได้ปกติและได้กลับไปทำงาน ระยะเวลาการรักษาทั้งหมดรวมกับการฟื้นตัวของผู้ป่วยจนสามารถดำเนินชีวิตได้อย่างปกติเป็นเวลาประมาณ 1 ปี

คำสำคัญ: การทะลุของหลอดอาหาร, หลอดเลือดโป่งพองในช่องอกแตก, การรักษาโดยการผ่าตัด.

Esophageal necrosis is a rare complication after surgery of thoracic or thoraco-abdominal aortic aneurysms. Most reported cases were complications after surgeries for ruptured or impending rupture of aneurysms. The patients might become septic after the operation; the onset is varying from a few days to several weeks. Once the complications develop, the possibility of death is high because of the contaminations of the implanted vascular graft by esophageal contents and development of empyema thoracis. A successful treatment is, therefore, exceptional. Infection usually causes dehiscence of the aortic-graft suture line, and the presence of prosthetic material in infected environment cannot be cured unless removal of the vascular grafts. In case of the location is very close to the origin of the celiac and superior mesenteric arteries, graft removal is also risky. Closure of aortic stump may compromise these major arteries. Extra anatomical bypass is not simple in this situation. Saving the patient's life in this condition is exceptional.

A case report

The patient was a 40-year-old man. He was transferred to King Chulalongkorn Memorial Hospital from a provincial hospital. He had a sudden and severe back and epigastric pain, and was diagnosed as peptic perforation. Upper median laparotomy was performed at the local hospital. It was found that there was a hematoma in the upper retroperitoneal space, and a huge pulsatile mass was felt at suprarenal aorta. The abdomen was then closed, and the patient was transferred.

Arriving at this hospital, the patient was hemodynamically stable. Emergent CT angiogram

showed a huge fusiform aneurysm from the mid descending aorta to just above the origin of the celiac artery with surrounding hematoma, suggesting of a contained rupture of the aneurysm. The maximal diameter of the aneurysm was 9 cm. There was evidence of the surrounding hematoma. Coronary angiogram was normal.

Left thoracoabdominal incision was made in the 7th intercostal space. The diaphragm was circumferentially divided. First, partial bypass support was planned to apply; the left femoral vein was exposed. Unfortunately, a venous cannula could not pass into the right atrium because of some obstruction in the vein of the pelvis. So, the operation plan had to be changed to "clamp-and-go technique". Heparin was given intravenously at the dose of 2 mg per kilogram. The descending aorta was cross-clamped above the aneurysm; and, the aneurysm was then opened. It was a huge atherosclerotic aneurysm with leakage, but no evidence of infection was found. The aneurysmal wall was thick and heavily calcified. Transection of the relatively normal aorta just above the celiac artery was done. A 22 mm Unigraft was anastomosed end-to-end with 3-0 polypropylene. The distal anastomosis was performed first. Then, the proximal aortic neck was transected; the graft was sutured to the proximal aorta with continuous 3-0 polypropylene suture. The aortic clamp was then released; the aortic clamp time was 25 minutes. Heparin was reversed with intravenous protamine sulfate, and hemostasis was secured. A 28 Fr chest tube was placed in the left pleural cavity, and the incision was closed in layers. The postoperative course was uneventful. He had good urine output, no paraplegia, and his blood pressure was stable. He

was extubated in the following morning, and transferred to a regular ward.

Five days after the surgery, he had active bowel sounds and he passed out flatus. Oral diet was permitted. But a day later, he could not eat or drink because of severe chest and back pain; and, he became febrile. The intercostal drainage content, which was previously serosanguinous, turned to be purulent. Emergency CT scan showed abscess surrounding the aortic graft (Figure 1).

Emergency left thoracotomy was done at the previous incision. There was food particles and pus surrounding the graft. However, the suture lines were not exposed. After the contaminated materials were removed, a longitudinal defect in the lateral wall of the lower thoracic esophagus, close to the aneurysmal wall was detected. The edge of the defect was edematous, measured 2 cm long and 5 mm wide. The esophagus was then resected from the normal area above the tear to the esophagogastric junction. The upper end of the esophagus was closed with polypropylene as well as the cardiac opening. Aggressive cleansing of the left chest cavity and debridement of the aneurysmal wall were done. As the heavily calcified part of the aortic aneurysmal

wall was still left. The graft was irrigated with warm saline solution and painted with betadine solution. The diaphragm was reopened and a flap of the greater omentum was pulled upward through the diaphragm to wrap around the graft. Then, the patient was turned to supine position, and gastrostomy, feeding jejunostomy and cervical esophagostomy were subsequently done. The patient was stable during these procedures. He improved and could be weaned from the ventilator a day later. His hemodynamics was stable with good urine output. Three days after this operation, feeding via jejunostomy tube was well tolerated.

Three weeks after the second operation, he was well except that he became febrile again. Another CT scan of the chest showed a smaller collection of fluid with minimal air bubbles surrounding the graft. The feeding jejunostomy tube was found malfunctioned; then, he was re-operated for the third time. The midline laparotomy wound was reopened; the abdomen was clean with some adhesions. While mobilizing the esophageal hiatus, purulent fluid was drained from the previous aneurysmal sac behind the pericardium about 100 mL, and the vascular graft was well covered by the omental flap. The pus was totally

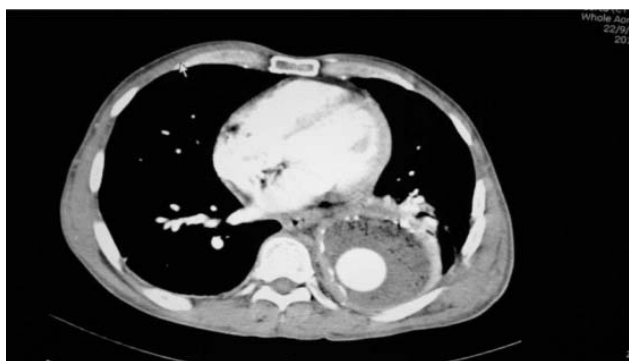


Figure 1. CT scan shows presence of air bubbles surrounding aorta graft indicating abscess formation.

suctioned out, and the cavity was irrigated with warm saline solution. Additional resection of the aneurysmal sac was done from the abdominal incision. A redivac drain was left in the perigraft space and brought out from below through the abdomen. The jejunostomy was revised as well. Finally, the abdominal incision was closed. In postoperative period, he was rather well; the amount of the redivac drain was continuing decrease and serous in color. He was fed via a jejunostomy tube and continued on antibiotics for the next two months. After removal of the redivac drain, he was observed for one week and then transferred back to the referring hospital.

Six months after the aneurysm operation (1st operation), the patient requested to close the cervical esophagostomy so that he can eat by mouth. He presented afebrile and three kilograms of weight gain. Jejunostomy tube-feeding was normal and all his wounds were well healed. Despite the CT scan showed a much smaller space around the graft than the previous one, but there was no air bubble in the fluid. His peripheral blood white blood cell count, which was normal, confirmed no septic condition.

The fourth operation-right thoracotomy was done; the upper part of thoracic esophagus was excised. There was no inflammation in the mediastinum. The abdominal incision was reopened. Left side colon was prepared, and brought into the left side of the neck for colo-esophageal anastomosis via the retrosternal space in isoperistaltic fashion. The proximal end of the colon was anastomosed to the body of stomach after removal of the gastrostomy tube. Then, the colon continuity was established by performing anastomosis between the right half of the transverse colon to the sigmoid colon. The jejunostomy was left untouched.

Postoperative course was uneventful in spite of some unfavorable conditions. At the 7th postoperative day, some water that he drank was found leaking from the cervical wound. However regarding water soluble upper gastro-intestinal contrast study, it showed patent esophago-colono-gastric anastomoses without leakage or obstruction. Oral feeding was then stopped and he was fed via jejunostomy. Another week later, oral fluid was resumed; there was no leakage this time. He was discharged after he could have solid foods for a while. All antibiotics were discontinued. In total, he stayed in this admission for a month.

Six months later, he presented at a follow-up clinic. He was looking good. He reported he could eat regular diets and be back to full-time work. There has been no recurrent aortic infection.

Discussion

The thoracic esophagus is close to the descending thoracic aorta and receives arterial blood supply from the small branches of the descending aorta. Aneurysms of the descending aorta can erode the esophagus, causing aorto-esophageal fistula with exsanguinations.⁽¹⁾ Resection of an aneurysm of the descending thoracic aorta deprives the esophagus of its blood supply.⁽²⁾ Pressure necrosis of the esophagus was also reported to be caused by adjacent descending thoracic aortic aneurysm, especially when it ruptured.⁽³⁾ Necrosis of the esophagus can be delayed after operation on the descending thoracic or thoraco-abdominal aorta.⁽⁴⁾ The causes of esophageal necrosis with mediastinitis in this patient were pressure necrosis from the aneurysm, resection of the aneurysm excluded intercostal arteries feeding the esophagus. Surgical

trauma may be another explanation. The occurrence of mediastinitis is usually delayed until oral diet is begun. Severe contamination of the vascular graft is life threatening, because the resulting anastomotic blow out is usually fatal.⁽⁵⁾ If the anastomosis is not involved, the risk of dehiscence of the aortic suture line is less.⁽⁶⁾ Excision of the graft and extra-anatomical bypass is one of the standard treatments of aortic graft infection.⁽⁷⁾ However, it is not possible in this patient, because the distal anastomosis will occlude the celiac arterial opening. Extra anatomical bypass in this patient can be performed between the ascending aorta and infra renal abdominal aorta which requires median sternotomy and midline laparotomy incisions which will increase morbidities and mortalities of the patient. The greater omentum is effective against bacterial infection is well established.⁽⁸⁾ It has been reported to treated many cases of aortic graft infections. Despite the heavy contaminations, aggressive surgical debridement, board spectrum antibiotic treatments, coverage of the graft with pedicle omental graft were important principles that saved the patient's life.

References

1. Tokuda Y, Matsumoto M, Sugita T, Nishizuma J, Matsuyama K, Yoshida K, Matsuo T, Awane M. Successful repair of an aorto esophageal fistula caused by a thoracic aortic aneurysm: report of a case. *Surg Today* 2004; 34(4): 357-9
2. Prokchis C, Charoulis N, Tselikos D, Koletris EN, Apotolakis E, Dougenis D. Primary aorto-esophageal fistula due to thoracic aortic aneurysm: successful surgical treatment. *Tex Heart Inst J* 2009; 36(6): 607-10
3. De Praetere H, Lerut P, Johan M, Daenens K, Houthoofd S, Doumeau I, Maleux G, Lerut, Navelsteen A. Esophageal necrosis after endoprosthesis for ruptured thoraco abdominal aneurysm type 1: can long segment stent grafting of the thoraco abdominal aorta induce transmural necrosis?. *Ann Vasc Surg* 2010 Nov; 24(8): 1137-12
4. Reardon MJ, Brewer RJ, Le Maire SA, Baldwin JC, Safi HJ. Surgical management of primary aorto esophageal fistula secondary to thoracic aortic neurysm. *Ann ThorcSurg* 2000; 69(3): 967-70
5. Hollander JE, Quick G. Aorto-esophageal fistula: a comprehensive review of the literature. *Am J Med* 1991 Sep; 91(3):279-87
6. Pirard L, Creemers, Van Damme H, Laurent S, Honoré P, Limet R. In situ aortic allograft insertion to repair a primary aorto-esophageal fistula due to thoracic aortic aneurysm. *J Vasc Surg* 2005 Dec; 42(6) : 1213-7
7. Oderich GS, Bawer TC, Cherry KJ Jr, Panneton JM, Sullivan TM, Noel AA, Carmo M, Cha S, Kalra M, Gloviczki P. Evolution from axillofemoral to in situ prosthetic graft reconstruction for the treatment of graft infection at a single center. *J Vasc Surg* 2006 Jun; 43(6): 1166 - 74
8. Topel I, Stehr A, Steinbauer MG, Piso P, Schiff HJ, Kaspzale PM. Surgical strategy in aorto-esophageal fistulae: endovascular stentgrafts and in situ repair of the aorta with crypreserved homografts. *Ann Surg* 2007 Nov; 246(5): 853-9