

5-1-2012

Hyperflexion trauma in the posttraumatic nonunionodontoid process fracture: A case study

C Chaichankul

W Limthongkul

W. Yingsakmongkol

Follow this and additional works at: <https://digital.car.chula.ac.th/clmjjournal>



Part of the [Medicine and Health Sciences Commons](#)

Recommended Citation

Chaichankul, C; Limthongkul, W; and Yingsakmongkol, W. (2012) "Hyperflexion trauma in the posttraumatic nonunionodontoid process fracture: A case study," *Chulalongkorn Medical Journal*: Vol. 56: Iss. 3, Article 6.

Available at: <https://digital.car.chula.ac.th/clmjjournal/vol56/iss3/6>

This Case Report is brought to you for free and open access by the Chulalongkorn Journal Online (CUJO) at Chula Digital Collections. It has been accepted for inclusion in Chulalongkorn Medical Journal by an authorized editor of Chula Digital Collections. For more information, please contact ChulaDC@car.chula.ac.th.

Hyperflexion trauma in the posttraumatic nonunion odontoid process fracture: A case study

Chaayos Chaichankul*

Worawat Limthongkul* Wicharn Yingsakmongkol*

Chaichankul C, Limthongkul W, Yingsakmongkol W. Hyperflexion trauma in the posttraumatic nonunion odontoid process fracture: A case study. Chula Med J 2012 May - Jun; 56(3): 317 - 25

Os odontoideum is a small round or oval corticated ossicle with a smooth cortical border and no body union to the body of the axis. Posttraumatic injury of the cervical spine is one of the etiologies. We reported a 28-year-old man patient with os odontoideum presented with a trivial hyperflexion cervical trauma. He developed neurogenic shock and central cord syndrome. This case supports the theory that previous trauma is the etiology of the abnormality. Surgical management alleviated his symptom. Occipitocervical fusion with C1 laminectomy was successfully achieved in this case. Odontoid nonunion is a potentially a serious situation. Patients can develop late neurological deficits if conservative treatment is undertaken. Considering prophylactic surgical stabilization in the asymptomatic patient may be relatively indicated in younger patients with active lifestyles.

Keywords: *Cervical spine, odontoid fractures, os odontoideum, atlantoaxial instability, nonunion odontoid process fracture.*

Reprint request: Yingsakmongkol W. Department of Orthopaedics, Faculty of Medicine, Chulalongkorn University, Bangkok 10330, Thailand.

Email: chaichankul@yahoo.com

Received for publication. May 10, 2011.

ไชยยศ ชัยชาญกุล, วรวรรธน ลิ้มทองกุล, วิชัญ ยิ่งศักดิ์มงคล. การบาดเจ็บแบบ hyperflexion ในภาวะที่เคยมีการหักของกระดูก odontoid ชนิด nonunion. จุฬาลงกรณ์เวชสาร 2555 พ.ค. - มิ.ย.; 56(3): 317 - 25

Os odontoideum เป็นส่วนหนึ่งของกระดูก axis ที่อยู่ส่วนบน มีลักษณะเป็นกระดูกรูปกลมหรือรูปไข่ขนาดเล็กที่มีขอบเรียบและไม่ติดกับส่วนฐาน ภาวะนี้เป็นกรณีที่พบบ่อย และมีการตีพิมพ์ในวารสารต่าง ๆ อยู่น้อย พบว่าการบาดเจ็บของกระดูกสันหลังส่วนคอเป็นหนึ่งในสาเหตุ รายงานกรณีศึกษาผู้ป่วยชายอายุ 28 ปี ที่มี *os odontoideum* ร่วมกับการบาดเจ็บแบบ hyperflexion ที่ไม่รุนแรง ผู้ป่วยรายนี้มีภาวะ neurogenic shock และ central cord syndrome

กรณีนี้สนับสนุนทฤษฎีที่กล่าวถึงการบาดเจ็บก่อนหน้านี้เป็นสาเหตุของความผิดปกติดังกล่าว การรักษาโดยการผ่าตัดช่วยบรรเทาอาการของผู้ป่วยรายนี้มีวิธีการผ่าตัดอยู่หลายวิธี เช่น C1-2 fixation (C1 – 2 transarticular screws, C1 lateral masses and C2 pedicles screws) and Occipitocervical fusion เป็นต้น ซึ่งการผ่าตัดโดยวิธี Occipitocervical fusion กับ C1 laminectomy ประสบผลสำเร็จในผู้ป่วยรายนี้ ภาวะการไม่ติดของกระดูก odontoid จัดเป็นภาวะที่รุนแรง ผู้ป่วยสามารถเกิดความบกพร่องทางระบบประสาทได้ในอนาคตหากรักษาแบบประคับประคองหรือไม่ผ่าตัด การพิจารณาผ่าตัดเพื่อป้องกันในผู้ป่วยที่ยังไม่มีอาการอาจจะมิชอบซึ่งในผู้ป่วยอายุน้อยที่ภาวะ *Os odontoideum*.

คำสำคัญ : กระดูกสันหลังส่วนคอ, การหักของกระดูกส่วน odontoid, *os odontoideum*, ภาวะไม่มั่นคงของข้อ atlantoaxial, การหักของกระดูก odontoid ชนิด nonunion.

Fractures of odontoid process can occur in all age groups.⁽¹⁾ These fractures have been reported with increasing with age, although the incidence of subaxial cervical spine fractures decreases with age.⁽²⁾ In younger patients, these fractures are usually secondary to high-energy trauma but in elderly, tend to result from low-energy trauma. Undiagnosed or maltreated odontoid fractures may develop into malunion or nonunion (os odontoideum) which lead to instability or atlantoaxial subluxation. Especially in unstable type II fractures according to the classification of Anderson and D'Alonzo⁽³⁾, maltreatment may lead to a significant nonunion rate.⁽⁴⁻⁷⁾ Os odontoideum is a rare condition. There have been few reports of os odontoideum in the literature. We report a case of a patient who had an asymptomatic posttraumatic nonunion odontoid process fracture from a motor-vehicle accident for many years, present with a trivial hyperflexion cervical trauma with developed neurogenic shock and central cord syndrome.

Case study

A 28-year-old man presented with a difficult

breathing and central cord syndrome, present while his head was impacted at the posterior aspect. At that time, his neck was in hyperflexion position. He had a history of a neck injury in a motor-vehicle accident since 8 years previously. The patient had only axial neck pain but no neurological deficit. At that time, his neck pain could be subsided with conservative treatment. On the admission physical evaluation revealed a central cord syndrome. He suffered from neurogenic shock with presenting hypotension and bradycardia. Initial radiographic examination of the cervical spine included anteroposterior, lateral and open mouth views (Fig. 1). CT imaging and three-dimensional CT scan demonstrated the separation of the odontoid process (Fig. 2 and 3). MRI showed evidence of increased T2 signal in the cord at atlanto-axial level (Fig. 4). On admission date, he needed endotracheal for relieving difficulty breathing and vasoactive drugs for neurogenic shock. He was treated by traction with cervical skeletal tong traction. Two days after the trivial injury, completed reduction was not achieved. Occipitocervical fusion with C1 laminectomy was done in this patient.

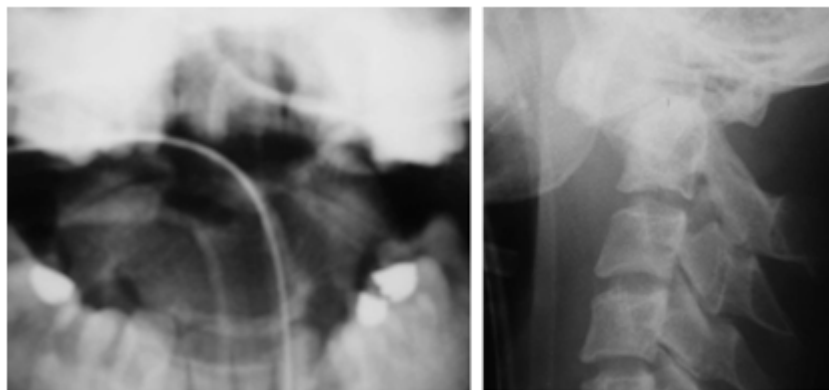


Figure 1. On the radiographs, the ossicle has smooth cortical margins and is separated from the base of odontoid process.

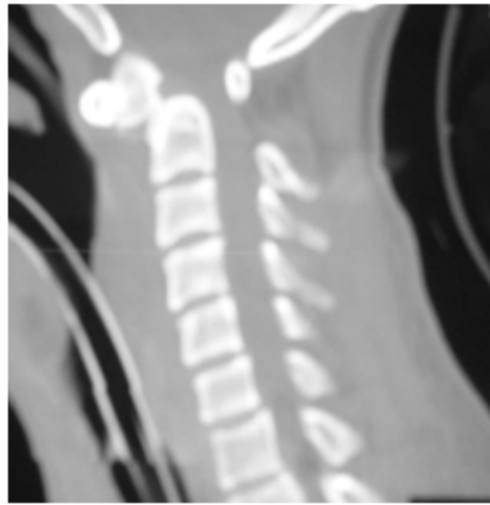

Figure 2. Saggital image CT scan showing the displaced ossicle with attaching to the anterior arch of the atlas (C1).



Figure 3. Three-dimensional CT scan of the axis, showing that the separation between the ossicle and the odontoid process.

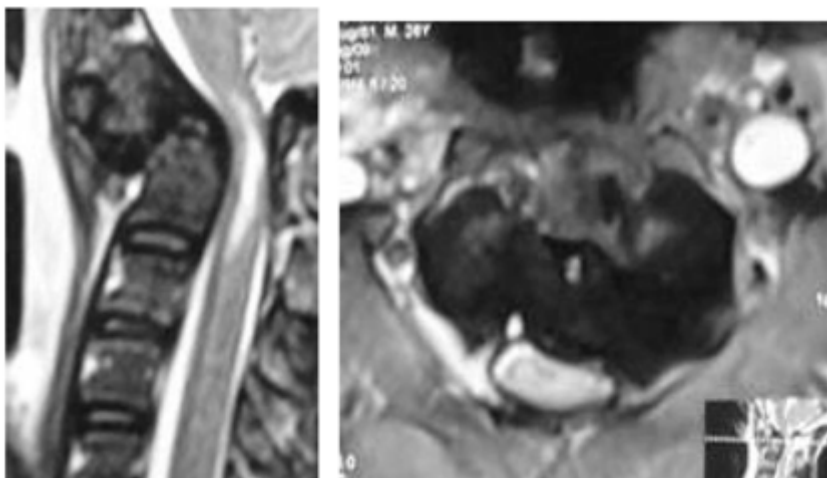


Figure 4. MRI showing high intensity signal change in the high cervical cord.

Operative procedure

The patient was placed in prone in a halo ring affixed to the table (Fig. 5). Dissection using sharp, blunt and electrocautery down the midline. Identify the midline raphe, the spinous process and the prevertebral fascia. Dissect bilaterally down the spinous processes. Preserve the ligamentum nuchae as much as possible. Expose laterally to identify lateral

masses and anteriorly to identify the inion. Lateral mass screws at C2-C4 were inserted by using fluoroscopic for controlling the direction of screws (Fig. 6). Place the plate at midline of inion and insert the screws. Contour the rods to the neutral position of the occipitocervical junction. Connect the rods to the plate and lateral mass screws. Pack the construct with autologous bone grafts to encourage fusion.

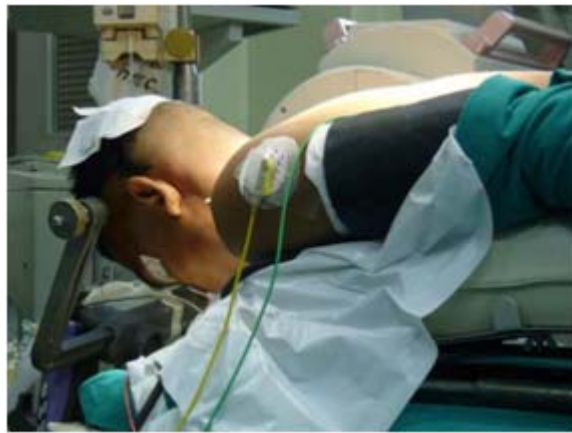

Figure 5. Place patient in prone position.

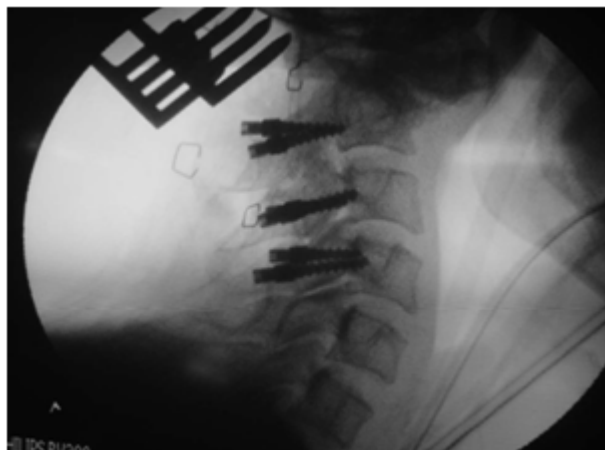

Figure 6. Fluoroscopic image for the lateral mass screws.

Postoperative course

No complication was occurred with surgery. Postoperative imaging revealed that the construct was satisfactory (Fig. 7.). On postoperative day 1, he could off the endotracheal tube and vital signs were stable. The patient could wean off vasoactive drugs. The neurologic deficit decreased after surgery

(Frankel D) (Fig. 8).The patient was discharged 5 days after surgery. The patient was placed in a hard collar for 4 weeks with radiographic follow-up until fused. At the 6-month follow-up, radiographs showed stable operative fixation and no neurologic deficit (Frankel E).

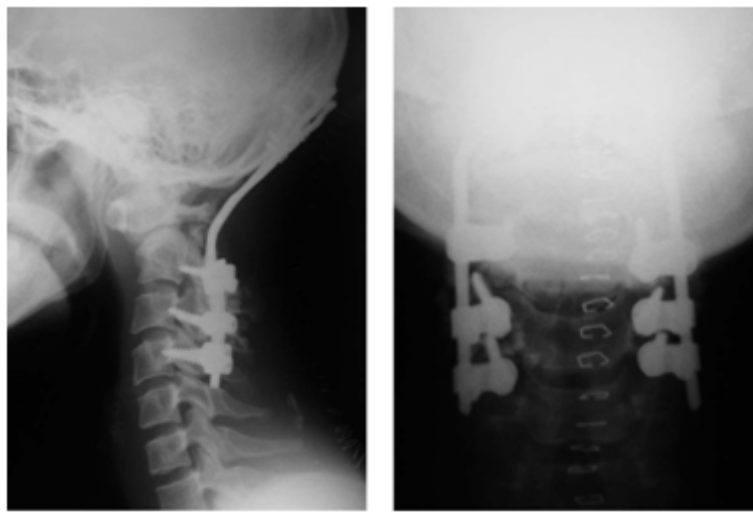


Figure 7. Occipitocervical fusion using occipital screws connected to C2, C3 and C4 lateral mass screws fixation.

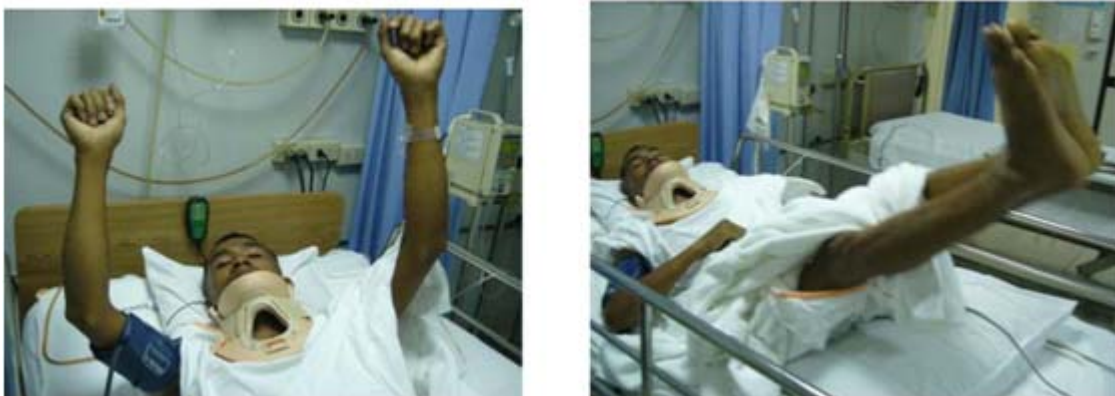

Figure 8. Motor function after the occipitocervical fusion was done in postoperative day 1.

Discussion

Os odontoideum was described by Giacomini in 1886.⁽⁸⁾ It is a small round or oval corticated ossicle with a smooth cortical border and no body union to the body of the axis. The etiology still remains in debate, with suggestion for congenital, vascular and traumatic causes. According to the study of the Stevens et al.⁽⁹⁾, the diagnosis between chronic nonunion of the odontoid process and os odontoideum which previous history of trauma could not be distinguished by the radiological criteria. The mechanism of this injury is often hyperextension resulting in posterior displacement of the odontoid.⁽¹⁰⁾
¹¹⁾ Our study, we found that the mechanism which happened in our patient was hyperflexion result.

Patients with os odontoideum can present with a wide range of clinical signs and symptoms. These patients may present with any local symptoms such as high cervical pain, stiffness of neck, weakness of neck, dizziness or torticollis.⁽¹²⁾ These patients can describe in asymptomatic with radiographic stability, asymptomatic with radiographic instability, local symptoms with radiographic stability, local symptoms with radiographic instability and patients with myelopathy or other neurologic injury.⁽¹³⁾ The treatment of nonunion odontoid process fracture still remains in controversial. The natural history of untreated injury is unknown.

The series of Fielding et al.⁽¹⁴⁾ studied in 35 patients described about the etiology of os odontoideum: congenital anomaly and acquired injury. They found that 26 patients had a previous history of trauma to the neck and 9 patients had no history of injury to the neck. Four of these had associated congenital anomalies of the cervical spine.

The four patients who had asymptomatic and neurological intact could manage without surgical treatment for 2-year follow up.

One study⁽¹⁵⁾ reported a completed displaced ossiculum terminale following a fall in a five-year-old boy. Examination revealed no neurological deficit except neck pain and torticollis. This case could manage with Halo-brace immobilization and closed observation. That patient had still the separation between the ossicle and the odontoid process. On the period of follow-up, the patient had normal neurological examination. Another study⁽¹⁶⁾ reported a 60-year-old man of a traffic accident induced a neurologic deficit resulting from nonunion odontoid process fracture. Surgical treatment of anterior screw fixation and additional posterior C1-C2 arthrodesis with K-wire and iliac crest bone graft was done. The follow-up result showed stable fixation and no neurologic deficit. In the study of Brecknell et al.⁽¹⁷⁾ concluded that the persistence neck pain, progressive neurological deficit, Lhermitte's phenomenon and a minimum canal diameter of 13 mm or less as indications for surgical stabilization. Also, in patients who have evidence of high cervical pain, surgical stabilization is relatively indicated.

We report this case to discuss the association of os odontoideum with the history of posttraumatic nonunion of odontoid process which presented in a central cord syndrome and developing neurogenic shock. In this case could achieve with surgical stabilization. Occipitocervical fusion is performed using occipital screws connected to subaxial cervical screws fixation. We recommended occipitocervical fusion in the operative management of os odontoideum if atlanto-axial subluxation is

non-reducible. Occipitocervical fusion with C1 laminectomy is occasionally required for patients who are irreducible and who have posterior cord compression behind the atlas. This condition is a contraindication for sublaminar wire passage which may cause a further damaged spinal cord.

Odontoid nonunion is a potentially a hazardous situation. Conservatively treated nonunion can lead to neurological deficits. Patients can develop neurological deficits months or years later. Considering prophylactic surgical stabilization in the asymptomatic patient may be relatively indicated in younger patients with active lifestyles because they may be experienced a minor trauma which can develop a high risk for future neurologic deterioration.

References

1. Sasso RC. C2 dens fractures: treatment options. *J Spinal Disord* 2001 Oct;14(5):455-63
2. Bracken MB, Freeman DH Jr, Hellenbrand K. Incidence of acute traumatic hospitalized spinal cord injury in the United States, 1970-1977. *Am J Epidemiol* 1981 Jun;113(6):615-22
3. Anderson LD, D'Alonzo RT. Fractures of the odontoid process of the axis. *J Bone Joint Surg Am* 1974 Dec;56(8):1663-74
4. Apuzzo ML, Heiden JS, Weiss MH, Ackerson TT, Harvey JP, Kurze T. Acute fractures of the odontoid process. An analysis of 45 cases. *J Neurosurg* 1978 Jan; 48(1): 85-91
5. Clark CR, White AA 3rd. Fractures of the dens. A multicenter study. *J Bone Joint Surg Am* 1985 Dec;67(9):1340-8
6. Fujii E, Kobayashi K, Hirabayashi K. Treatment in fractures of the odontoid process. *Spine (Phila Pa 1976)* 1988 Jun;13(6):604-9
7. Schatzker J, Rorabeck CH, Waddell JP. Fractures of the dens (odontoid process). An analysis of thirty-seven cases. *J Bone Joint Surg Br* 1971 Aug; 53(3): 392-405
8. Giacomini C. Sull' esistenza dell' "osodontoideum" nell' uomo. *Gior Accad Med Torino* 1886; 49: 24-8
9. Stevens JM, Chong WK, Barber C, Kendall BE, Crockard HA. A new appraisal of abnormalities of the odontoid process associated with atlanto-axial subluxation and neurological disability. *Brain* 1994 Feb;117 (Pt 1):133-48
10. Muller EJ, Wick M, Russe O, Muhr G. Management of odontoid fractures in the elderly. *Eur Spine J* 1999; 8 (5):360-5
11. Bednar DA, Parikh J, Hummel J. Management of type II odontoid process fractures in geriatric patients; a prospective study of sequential cohorts with attention to survivorship. *J Spinal Disord* 1995 Apr;8(2):166-9
12. Dai L, Yuan W, Ni B, Jia L. Osodontoideum: etiology, diagnosis, and management. *SurgNeurol* 2000 Feb; 53(2):106-9
13. Krishnaney AA, Kalfas IH. C2 fractures: osodontoideum. In: Alexander Vaccaro, Paul Anderson, editors. *Cervical Spine Trauma*. 1st ed. 2010; Chapter 24C: 353-357
14. Fielding JW, Hensinger RN, Hawkins RJ. Os Odontoideum. *J Bone Joint Surg Am* 1980 Apr;62(3):376-83
15. Wada E, Matsuoka T, Kawai H. Os odontoideum as a consequence of a posttraumatic displaced ossiculum terminale. A case report.

- J Bone Joint Surg Am 2009 Jul; 91(7):
1750-4
16. Boldin C, Grechenig W, Fankhauser F. Accident-
induced late complaint of odontoid nonunion.
- Spine 2004; 29(8):E169 - E171
17. Brecknell JE, Malham GM. Os odontoideum:
Report of three cases. J Clin Neurosci 2008
Mar;15(3): 295-301