

5-1-2013

Gastric volvulus in an Ehler-Danlos patient:A case report

S Prichayudh

R Pak-art

P Vejchapipat

S Sriussadaporn

P Samorn

See next page for additional authors

Follow this and additional works at: <https://digital.car.chula.ac.th/clmjjournal>



Part of the [Medicine and Health Sciences Commons](#)

Recommended Citation

Prichayudh, S; Pak-art, R; Vejchapipat, P; Sriussadaporn, S; Samorn, P; Chaivaniychaya, K; Sriussadaporn, S; and Kritayakirana, K. (2013) "Gastric volvulus in an Ehler-Danlos patient:A case report," *Chulalongkorn Medical Journal*. Vol. 57: Iss. 3, Article 8.

Available at: <https://digital.car.chula.ac.th/clmjjournal/vol57/iss3/8>

This Case Report is brought to you for free and open access by the Chulalongkorn Journal Online (CUJO) at Chula Digital Collections. It has been accepted for inclusion in Chulalongkorn Medical Journal by an authorized editor of Chula Digital Collections. For more information, please contact ChulaDC@car.chula.ac.th.

Gastric volvulus in an Ehler-Danlos patient:A case report

Authors

S Prichayudh, R Pak-art, P Vejchapipat, S Sriussadaporn, P Samorn, K Chaivanijchaya, S Sriussadaporn, and K. Kritayakirana

Gastric volvulus in an Ehler-Danlos patient: A case report

Supparerk Prichayudh* Rattaplee Pak-art*
Paisarn Vejchapipat* Suvit Sriussadaporn*
Pasurachate Samorn* Komol Chaivanijchaya*
Sukanya Sriussadaporn* Kritaya Kritayakirana*

Prichayudh S, Pak-art R, Vejchapipat P, Sriussadaporn S, Samorn P, Chaivanijchaya K, Sriussadaporn S, Kritayakirana K. Gastric volvulus in an Ehler-Danlos patient: A case report. Chula Med J 2013 May – Jun; 57(3): 359 - 65

The authors report a case of Ehler-Danlos syndrome with gastric volvulus undergoing a successful surgical treatment. The diagnosis was made with imaging studies. Preoperative resuscitation and nutritional improvement were carried out. Surgical treatment for gastric volvulus in this patient included gastrojejunostomy and anterior gastropexy. The authors also discuss diagnostic modalities and surgical treatments utilized in this patient.

Keywords: Gastric volvulus, Ehler-Danlos.

Reprint request: Prichayudh S. Department of Surgery, Faculty of Medicine, Chulalongkorn University, Bangkok 10330, Thailand.

Received for publication. April 24, 2012.

E-mail address: Supparerk.P@Chula.ac.th

ศุภฤกษ์ ปรีชายุทธ, รัฐพลี ภาคอรธร, ไพศาล เวชชพิพัฒน์, สุวิทย์ ศรีอัษฎาพร, พสุรเชษฐ์ สมร, โกมล ชัยวณิชยา, สุกัญญา ศรีอัษฎาพร, กฤตยา กฤตยาภิรม. ภาวะกระเพาะอาหารบิดในผู้ป่วย เออเลอร์ดานลอส: รายงานผู้ป่วย 1 ราย. จุฬาลงกรณ์เวชสาร 2556 พ.ศ. – ม.ย.; 57(3): 359 – 65

ได้รายงานผู้ป่วยเออเลอร์ดานลอส ที่มีภาวะกระเพาะอาหารอุดตันจากภาวะกระเพาะอาหารบิด ผู้ป่วยได้รับการวินิจฉัยก่อนผ่าตัดโดยการตรวจทางรังสีวิทยา และได้รับการผ่าตัดเพื่อแก้ไขภาวะกระเพาะอาหารบิดในเวลาต่อมา จากการตรวจติดตามผู้ป่วยที่เวลา 6 เดือนหลังผ่าตัดพบว่าผู้ป่วยไม่มีอาการผิดปกติแต่อย่างใด ผู้วิจัยได้รายงานถึงการเลือกวิธีการตรวจวินิจฉัยที่เหมาะสมและวิธีการผ่าตัดเพื่อแก้ไขภาวะกระเพาะอาหารบิดด้วย

คำสำคัญ : ภาวะกระเพาะอาหารบิด, เออเลอร์ดานลอส.

Gastric volvulus is a rare but life threatening condition. The first report was an autopsy in a 60-year-old woman described by Berti in 1866.⁽¹⁾ The presentations can range from severe acute epigastric pain in acute cases to no symptom in chronic cases. The association between gastric volvulus and Ehler-Danlos syndrome has been described that the volvulus can occur due to the laxity of tethering points of the stomach.⁽²⁾ To our knowledge, there is only one article in English reporting a case of gastric volvulus in an Ehler-Danlos patient.⁽³⁾ In this article, we describe an Ehler-Danlos patient with gastric volvulus who underwent successful surgical treatment.

Case Report

A 15-year-old female patient presented with abdominal distension and vomiting for 4 days. She

vomited approximately 30 to 60 minutes after eating, and reported no bile in the vomitus. She also had been having poor appetite, early satiety and 2 kg weight loss for 4 weeks. Past medical history was significant for Ehler-Danlos syndrome, essential type: aortic regurgitation, and scoliosis of thoracolumbar spines. On examination, the patient had stable vital signs but was dehydrated and had visible epigastric distension. There were no peritoneal signs on abdominal palpation but splashing sound was audible upon shaking the abdomen. Abdominal x-rays showed marked dilatation of the stomach with retained food particles. (Figure 1) The diagnosis of gastric outlet obstruction was made. The initial managements included intravenous fluid resuscitation and gastric decompression by a nasogastric tube. Gastric lavage was performed to empty the stomach and total parenteral nutrition was administered. Computed tomography (CT) of the

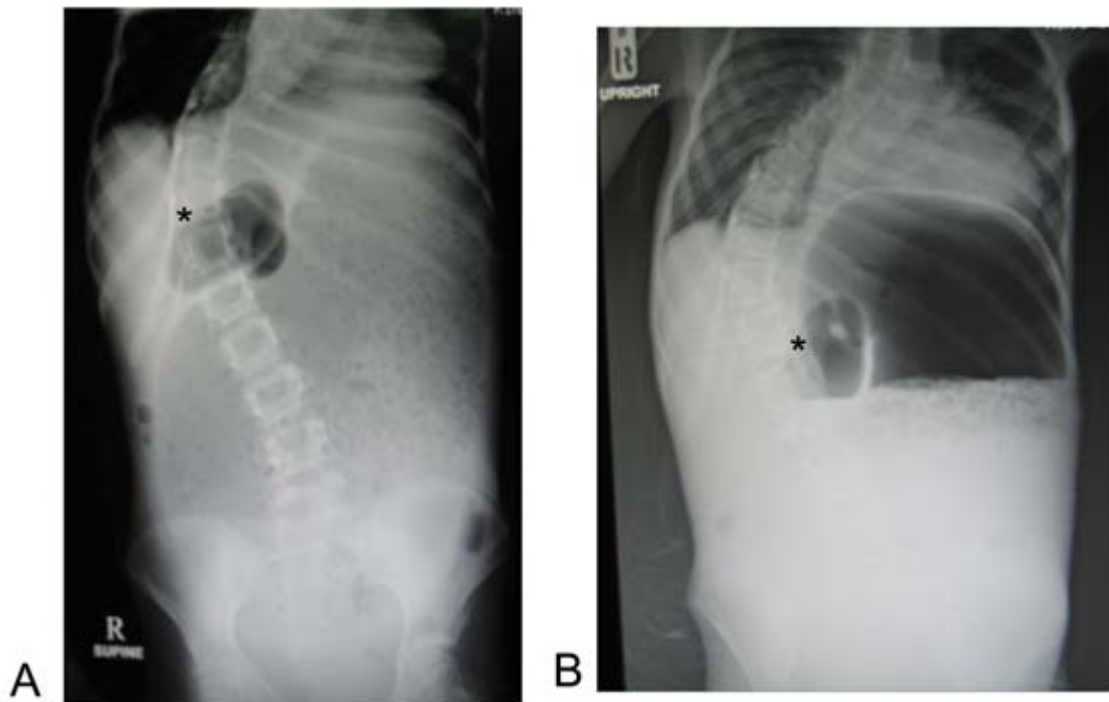


Figure 1. Abdominal x-rays demonstrate markedly distended stomach with retained food particles in the supine film (A) and air fluid level in the upright film (B). Air bubble in the duodenal bulb is also seen (asterisk).

abdomen on hospital day 9 showed gastric distension with mal-axis of the stomach, malposition of the small bowel, and malposition of the spleen in mid abdomen. (Figure 2) These findings suggested gastric volvulus with intestinal malrotation. An upper gastrointestinal (GI) study using Barium suspension via a nasogastric tube was also performed to elucidate the anatomy of the stomach. The study revealed mesentero-axial

gastric volvulus. (Figure 3) In order to provide enteral nutrition preoperatively, we inserted a nasojejunal feeding tube under gastroscopy. The patient tolerated the enteral feeding well and parenteral nutrition was eventually stopped. The patient body weight increased from 20.4 to 21.7 kg after 30 days in the hospital.

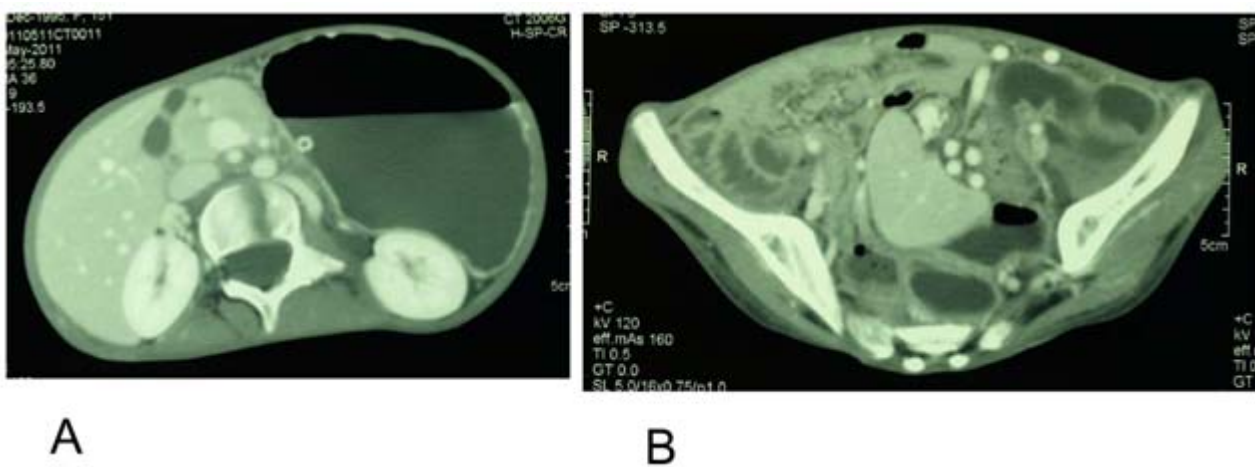


Figure 2. Computed tomography of the abdomen shows gastric dilatation (A) and malposition of the spleen (B) in the pelvis.

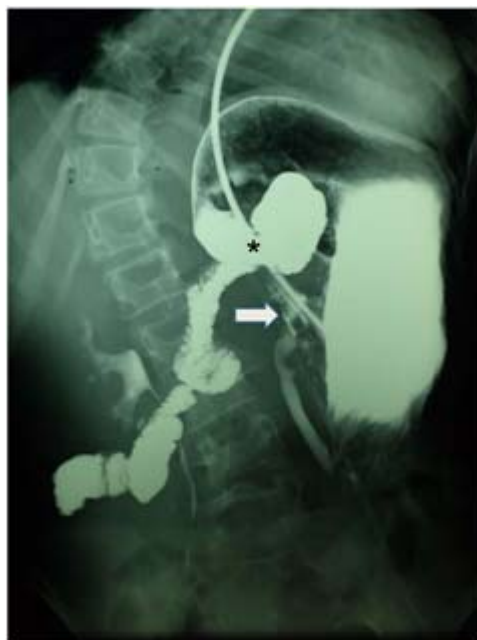

Figure 3. An upper gastrointestinal study reveals mal-axis of the stomach. The pylorus (asterisk) is situated above the gastroesophageal junction (white arrow) representing a mesentero-axial volvulus. Bilateral pyelograms are also observed since the patient had undergone contrast-computed tomography of the abdomen prior to the study.

Exploratory laparotomy was performed through an upper midline incision on hospital day 37. Operative findings included: 1) mesentero-axial gastric volvulus without diaphragmatic or hiatal hernia; 2) intestinal malrotation without Ladd's band; and, 3) a wandering spleen at mid abdomen with a long and twisted hilum. Detorsion of the stomach and the spleen was done. We then performed mesenteric root widening, appendectomy, and reposition of the cecum to the left lower abdomen (Ladd's procedure). Since the splenic hilum was very long and the completeness of splenic detorsion was questionable,

splenectomy was carried out. Subsequently, we created a gastrojejunostomy, considering there was an acute angle at the pyloro-duodenal junction. Finally, anterior gastropexy to abdominal wall was also done utilizing two 2-0 silk sutures. (Figure 4) The postoperative course was uneventful. The patient started oral diet on the 5th postoperative day and was discharged on the 10th postoperative day. She gained additional 1 kg of body weight and received post-splenectomy vaccination at the 3rd week after discharge. On 6 month follow up, she was doing well with a stable body weight.

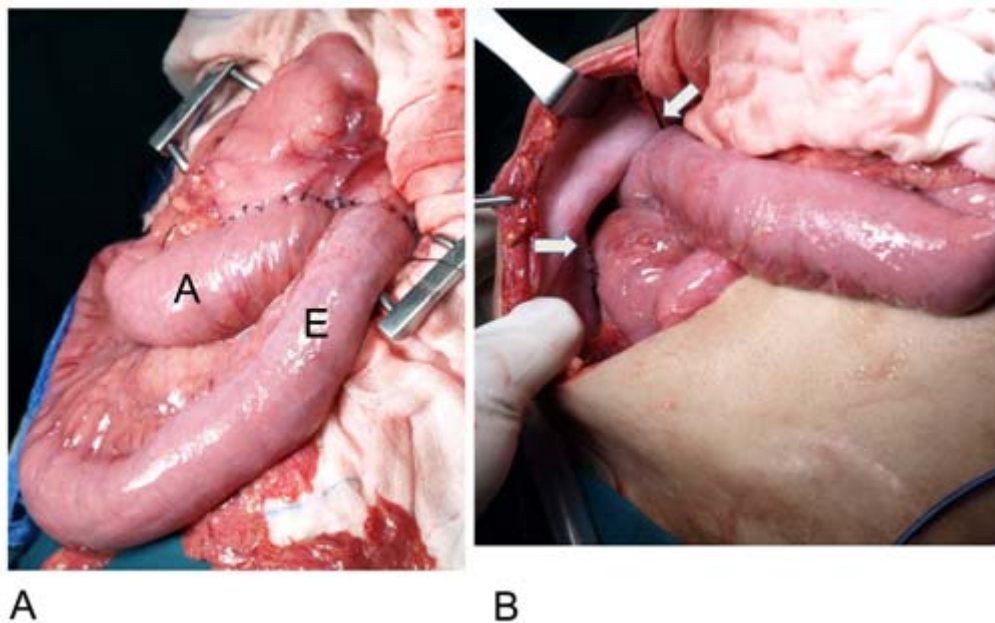


Figure 4. Operative treatment of the patient.

Figure 4A. A gastrojejunostomy was created after detorsion of the gastric volvulus (A = afferent limb, E = efferent limb).

Figure 4B. Anterior gastropexy was also performed at the level of gastrojejunal anastomosis using two 2 - 0 silk sutures (arrows).

Discussion

Gastric volvulus is defined as an abnormal degree of rotation of the stomach around its short or long axis.⁽⁴⁾ Although it is a rare condition, gastric volvulus is potentially life threatening since it can lead to gastric necrosis and mortality if the diagnosis and the treatment are delayed.⁽⁵⁾ Causes of gastric volvulus can be primary, due to laxity of tethering points of the stomach as in our patient, or secondary from diaphragmatic hernia, hiatal hernia, or a wandering spleen.^(3,6) Clinical manifestations of acute gastric volvulus as described by Borchardt in 1904 include unproductive retching, epigastric distension and inability to pass a nasogastric tube.⁽⁷⁾ However, these findings (Borchardt's triad) are not always present⁽⁵⁾, as in our patient who was able to vomit, and we were able to insert a nasogastric tube into the stomach.

Three types of gastric volvulus have been described, namely: mesentero-axial, organo-axial, and combined type depending on the rotation axis.⁽⁶⁾ After the patient is resuscitated and the stomach is decompressed, an upper gastrointestinal study should be performed to obtain the diagnosis and to elucidate the type of volvulus.^(6,8) In the mesentero-axial volvulus, the stomach is in upright position with the pylorus above the gastroesophageal junction as seen in our patient. (Figure 3) In organo-axial volvulus, the stomach is in horizontal position and the greater curvature is seen above the lesser curvature (an upside-down stomach).

The mainstay treatment of gastric volvulus is inevitably surgical treatment. The principles of treatment include reduction of the stomach, correction of underlying causes, and gastropexy.⁽⁶⁾ Several

methods of gastropexy have been described including fixing the stomach to the anterior abdominal wall (anterior gastropexy), to the esophagus (esophagocardiopexy), or to the left diaphragm (phrenofundopexy); laparoscopic gastropexy; gastrostomy; and gastrojejunostomy.^(3,6,9) Karande, *et al.* reported an Ehler-Danlos patient with acute gastric volvulus that was treated by gastropexy and gastrostomy with good result.⁽³⁾ In our case, the decision to perform gastrojejunostomy was made due to the acute angled pyloro-duodenal junction encountered during laparotomy. Gastrojejunostomy may also provide an additional fixation of the untwisted stomach to prevent recurrent volvulus.⁽⁹⁾

Conclusion

Although rarely reported, gastric volvulus should be suspected in Ehler-Danlos patients presenting with gastric outlet obstruction. Surgery is still the main treatment. Adequate preoperative resuscitation and nutritional improvement are important in order to obtain good results.

References

1. Berti A. Sigolare altorti glamento dell esofagocol dudeno segitto da rapida morte. Gazz Med Ital Prov Ver 1866 ; 9:139
2. Somers L, Szeki I, Hulbert D. Late presentation of diaphragmatic hernia and gastric volvulus. J Accid Emerg Med 2000 May; 17(3): 230
3. Karande TP, Oak SN, Karmarkar SJ, Kulkarni BK, Deshmukh SS. Gastric volvulus in childhood. J Postgrad Med 1997 Apr-Jun; 43(2): 46-7
4. Tanner NC. Chronic and recurrent volvulus of the stomach with late results of "colonic

- displacement". Am J Surg 1968 Apr; 115(4): 505-15
5. Kotobi H, Auber F, Otta E, Meyer N, Audry G, Helardot PG. Acute mesenteroaxial gastric volvulus and congenital diaphragmatic hernia. *Pediatr Surg Int* 2005 Aug; 21(8): 674-6
6. Darani A, Mendoza-Sagaon M, Reinberg O. Gastric volvulus in children. *J Pediatr Surg* 2005 May; 40(5): 855-8
7. Borchardt M. Zur pathologie und therapie des magen volvulus. *Arch Klin Chir* 1904; 74: 243-60
8. Cribbs RK, Gow KW, Wulkan ML. Gastric volvulus in infants and children. *Pediatrics* 2008 Sep; 122(3): e752-62
9. Carmalt HL, Gillett DJ. Gastrojejunostomy: A simple method of treatment of gastric volvulus. *Ann R Coll Surg Engl* 1986 Nov; 68(6): 326-7