

9-1-2014

Multidetector computed tomography angiographic imaging of the inferior mesenteric artery: Aberrant branches and branching patterns

Punnaporn Ubolviroj

Kiat Arjhansiri

Follow this and additional works at: <https://digital.car.chula.ac.th/clmjjournal>



Part of the [Medicine and Health Sciences Commons](#)

Recommended Citation

Ubolviroj, Punnaporn and Arjhansiri, Kiat (2014) "Multidetector computed tomography angiographic imaging of the inferior mesenteric artery: Aberrant branches and branching patterns," *Chulalongkorn Medical Journal*. Vol. 58: Iss. 5, Article 1.

Available at: <https://digital.car.chula.ac.th/clmjjournal/vol58/iss5/1>

This Article is brought to you for free and open access by the Chulalongkorn Journal Online (CUJO) at Chula Digital Collections. It has been accepted for inclusion in Chulalongkorn Medical Journal by an authorized editor of Chula Digital Collections. For more information, please contact ChulaDC@car.chula.ac.th.

Multidetector computed tomography angiographic imaging of the inferior mesenteric artery: Aberrant branches and branching patterns

Punnaporn Ubolviroj*
Kiat Arjhansiri*

Ubolviroj P, Arjhansiri K. Multidetector computed tomography angiographic imaging of the inferior mesenteric artery : Aberrant branches and branching patterns. Chula Med J 2014 Sep – Oct; 58(5): 471 - 83

Background : *Most of colonic polyp and colorectal carcinoma are found in inferior mesenteric artery (IMA) supplied segments. Complication such as bleeding is crucial role for endovascular embolization and chemotherapy. Knowledge of vascular anatomy is important for successful interventional procedure.*

Objective : *To determine the branching patterns and different aberrant arterial branches of IMA in Thai population by using multidetector computed tomography (MDCT) angiography.*

Setting : *Department of Radiology, King Chulalongkorn Memorial Hospital.*

Study design : *Retrospective descriptive study.*

Methods : *A total of 165 patients who underwent MDCT angiography of the whole aorta from January 2009 to December 2011 were retrospectively reviewed. The vertebral level of IMA origin, branching pattern and the presence of aberrant arterial branches were recorded. Researcher and another experienced radiologist performed image analysis in consensus.*

Results : IMA originates from the abdominal aorta at any level between superior endplate of second lumbar vertebra and inferior endplate of fourth lumbar vertebra. The body of third lumbar vertebra is the most frequent level of origin, 49 cases (29.7%). Five branching patterns are founded. The most frequent pattern is sigmoid artery (SA) branches off from superior rectal artery (SRA), 57 cases (34.5%). One of five branching patterns is newly discovered pattern which are two left colic arteries (LCAs) branch off from IMA, 20 cases (12.1%). Only two cases with aberrant branches were observed, including IMA branching from superior mesenteric artery (SMA) and LCA branches off from SMA (1.2%).

Conclusions : There were anatomical variations of IMA, including level of origin, branching patterns and aberrant branches. In the Thai population, the branching pattern and aberrant branches show some variation from the previously reported cases. Using of MDCT angiography provides good information for detection of vascular variation before interventional procedure.

Keywords : Inferior mesenteric artery (IMA), Thai, MDCT, branching patterns, aberrant branches.

Reprint request: Ubolviroj P. Department of Radiology, Faculty of Medicine, Chulalongkorn University, Bangkok 10330, Thailand. E-mail: punna.b@gmail.com

Received for publication. December 18, 2013.

ปัทมพร อุบลวิโรจน์, เกียรติ อางหาญศิริ. การศึกษาความผิดปกติและรูปแบบของแขนง
ของหลอดเลือดแดง อินพีเรียร์ มีเซนเทอริก โดยการตรวจหลอดเลือดด้วยเครื่องเอกซเรย์
คอมพิวเตอร์. จุฬาลงกรณ์เวชสาร 2557 ก.ย. - ต.ค.; 58(5): 471 - 83

เหตุผลของการทำวิจัย : ลำไส้ใหญ่ส่วนที่เลี้ยงโดยหลอดเลือด *inferior mesenteric artery* เป็นส่วนที่มี โอกาสเกิดเนื้องอกทั้งที่ไม่ใช่มะเร็ง หรือมะเร็งได้บ่อย ภาวะแทรกซ้อน เช่น ภาวะเลือดออก ถือเป็นข้อบ่งชี้สำคัญสำหรับการรักษา โดยการฉีดสารอุดหลอดเลือดผ่านทางสายสวนหลอดเลือดแดง นอกจากนี้การรักษามะเร็งยังสามารถทำได้โดยการให้ ยาเคมีบำบัดผ่านทางหลอดเลือดแดงเฉพาะเจาะจงไปที่เนื้องอก ดังนั้น ความรู้เกี่ยวกับกายวิภาคของหลอดเลือดที่ดี จะเป็นพื้นฐานสำคัญ ที่จะช่วยให้ประสบผลสำเร็จในการรักษา

วัตถุประสงค์ : เพื่อศึกษารูปแบบแขนงที่ปกติ และผิดปกติของหลอดเลือด *inferior mesenteric artery* ในคนไทย ด้วยการตรวจหลอดเลือดแดงโดยเครื่อง เอกซเรย์คอมพิวเตอร์

รูปแบบการวิจัย : การศึกษาย้อนหลังเชิงพรรณนา

สถานที่ทำการศึกษา : ภาควิชารังสีวิทยา โรงพยาบาลจุฬาลงกรณ์

ตัวอย่างและวิธีการศึกษา : ผู้ป่วยจำนวน 165 คน ที่รับการตรวจหลอดเลือดแดง โดยเครื่อง เอกซเรย์คอมพิวเตอร์ ระหว่างเดือนมกราคม ปี 2552 ถึง เดือนธันวาคม ปี 2554 ได้รับการทบทวนผลเอกซเรย์คอมพิวเตอร์ เพื่อบันทึกข้อมูล จุดกำเนิดของหลอดเลือด *inferior mesenteric artery* โดยเทียบกับ ระดับกระดูกสันหลัง, รูปแบบแขนงที่ปกติ และแขนงที่ผิดปกติ

ผลการศึกษา : จุดกำเนิดของหลอดเลือด *inferior mesenteric artery* จะเริ่มแตกออกจากหลอดเลือด *aorta* ที่ระดับขอบบนของกระดูกสันหลังส่วนเอว ข้อที่สอง ถึงขอบล่างของกระดูกสันหลังส่วนเอวข้อที่สี่ โดยที่ระดับ กระดูกสันหลังส่วนเอวข้อที่สาม เป็นตำแหน่งที่พบจุดกำเนิดบ่อยที่สุด ทั้งหมด 49 คน (29.7%) รูปแบบแขนงปกติพบทั้งหมดจำนวน 5 แบบ โดยรูปแบบที่สามจะพบบ่อยที่สุด คือหลอดเลือด *sigmoid artery* แตกออกจากหลอดเลือด *superior rectal artery* พบจำนวน 57 คน (34.5%) รูปแบบแขนงปกติแบบที่ห้า คือหลอดเลือด *left colic artery* แตกออกจากหลอดเลือด *inferior mesenteric artery* จำนวนสองเส้น

สรุป

:

พบทั้งหมด 20 คน (12.1%) เป็นรูปแบบที่ไม่เคยได้รับการกล่าวถึงในการศึกษาก่อนหน้า มีเพียงสองคนที่ให้แขนงที่ผิดไปจากปกติ (1.2%) คนแรกคือหลอดเลือด *inferior mesenteric artery* แยกออกจากหลอดเลือด *superior mesenteric artery* และคนที่สองคือหลอดเลือด *left colic artery* แยกออกจากหลอดเลือด *superior mesenteric artery* การตรวจหลอดเลือดแดงโดยเครื่องเอกซเรย์คอมพิวเตอร์ สามารถให้ข้อมูลที่มีคุณภาพในศึกษากายวิภาคของหลอดเลือด ทำให้พบความแตกต่างของจุดกำเนิด รวมทั้งรูปแบบแขนงของหลอดเลือด *inferior mesenteric artery* ในคนไทย

คำสำคัญ

:

Inferior mesenteric artery (IMA), ตรวจหลอดเลือดด้วยเครื่องเอกซเรย์คอมพิวเตอร์, คนไทย, รูปแบบแขนงปกติ, แขนงผิดปกติ.

The inferior mesenteric artery (IMA) is the smallest artery of the mesenteric vessels, originates from the left anterior wall of the abdominal aorta at about the level of third lumbar vertebra. It often supplies distal transverse colon, descending colon, then sigmoid colon and upper rectum. From the origin, it courses descending parallel to the aorta for 3 to 4 cm and gives off 3 classic branches which are left colic artery (LCA), sigmoid artery (SA) and superior rectal artery (SRA).⁽¹⁾

In a study of Zebrowski, Augustyniak and Zajac (1971) the variations of IMA origin were shown, its course and its branching patterns which were formed into 4 forms and 8 different subtypes (Figure1).⁽²⁾ Another study of Kobayashi *et al.* (2006) has classified IMA branching patterns into 3 types by using multidetector computed tomography (MDCT) angiography (Figure 2).⁽³⁾

There are some reports of the variations on the IMA, such as the absence of the IMA, common mesenteric artery, IMA branching off from superior mesenteric artery (SMA) (< 0.1%) and common arterial trunk (celiac-bimesenteric trunk).^(4, 5) The aberrant branches of IMA have also been identified such as the LCA arising from SMA (1%), absence of LCA (12%), ascending LCA to celiac trunk, middle colic branch, accessory right hepatic and accessory right renal artery.^(1, 2, 4, 6-8)

Over 75 percent of all polyps and cancer occur in the colonic segment supplies by IMA. The critical complication such as hemorrhage is crucial role for endovascular embolization. Moreover, the advancements in laparoscopy-assisted colorectal surgery and direct perfusion of chemotherapeutic agents for treatment of colorectal cancer have

reflected in the importance of precise vascular anatomical knowledge.^(3, 9-11)

The mesenteric vasculature was traditionally imaged with conventional angiography, but can now easily be imaged rapidly and safely by using MDCT scanner and 3D imaging software. The faster scanning, coupled with rapid intravenous administration of contrast material, allows excellent visualization of the normal mesenteric vasculature, both arteries and veins.^(12, 13)

Although there have been many reports on the IMA variations but almost all studies were base on conventional angiography and cadaver. The information of this arterial variation is also extremely limited in Thai population. Then, the purpose of this study is to determine the branching patterns and different aberrant arterial branches of the IMA in Thai population by using MDCT angiography.

Methods

Population

Consecutive patients who underwent MDCT angiography of the whole aorta at the Department of Radiology, King Chulalongkorn Memorial Hospital (KCMH) from January 1, 2009 to December 31, 2011 were included and retrospectively reviewed. Patients who undergone previous bowel resection, intra-abdominal organ transplantation and patients with pathological condition causing severe distortion of vascular anatomy and occlusion of arterial blood flow as well as inadequate technique were excluded.

Image acquisition

All CT examinations were performed on a 16-MDCT scanner (Somatom sensation 16, Siemens

Medical Solution, Germany) or 320-MDCT scanner (Aquilion ONE, Toshiba Medical Systems Corporation using KCMH CT whole aorta protocol (Table 1). The patients were in supine position. Craniocaudal scan was performed from the lung apex to the pubic symphysis. Image reconstruction was done with slice thickness 3 mm and increment 1 mm. Post-processing techniques were also acquired in all patients which included multiplanar reformation (MPR), maximum-intensity-projection reconstruction (MIP) and 3D volume-rendered images.

Image analysis

All MDCT angiography images of the whole aorta were reviewed using Picture Archiving and Communication System (PACS) by researcher and another experienced radiologist, concurrently. The readers were well informed of all patient information. Any different interpretations were finalized by consensus. The research proposal has been reviewed and approved by the Ethics Committee of Faculty of Medicine, Chulalongkorn University.

Data collection

The demographic data including age, sex and diagnosis from MDCT angiography were collected. The vertebral level of IMA origin, branching pattern and the presence of aberrant arterial branches were all recorded.

Data analysis

Statistical analyses were performed using a statistical software package (SPSS, version 17.0; IBM Corporation, Armonk, NY). Descriptive statistics were provided where appropriate.

Results

According to aforementioned inclusion and exclusion criteria, the final study population includes 165 patients, 107 males (64.8%) and 58 females (35.2%). Age distribution and diagnosis from MDCT angiography are demonstrated in Table 2 and Table 3.

Table 1. Protocol for CT whole aorta at the Department of Radiology, King Chulalongkorn Memorial Hospital (KCMH).

	Somatom sensation 16	Aquilion ONE
kV	120	120
mAs	140	140
Slice collimation	16 × 0.75	100 × 0.5
Slice width	1 mm	0.5 mm
Overlapping	20%	20%
Gantry rotation time	0.5 sec	0.5 sec
Pitch	1	1.030
Non-ionic contrast media (300 mgI/ml)	100 (2 ml/kg)	100 (2 ml/kg)
Flow rate	4 ml/sec	5 ml/sec
Bolus tacking		
- Threshold level	100 HU	180 HU
- Region of interest (ROI)	Descending aorta	Aorta at mid scan range

Table 2. Number and percentage of patients categorized by age range, Mean age = 64 years (range 15 - 99 years).

Age (years)	Number of patients	Percent
<40	16	9.7
41-50	16	9.7
51-60	24	14.5
61-70	49	29.7
71-80	37	22.4
>81	23	13.9
Total	165	100

Table 3. Number and percentage of patients categorized by diagnosis. (* Takayasu arteritis 3 cases; Intramural hematoma of ascending aorta to suprarenal aorta 1 case; Penetrated atherosclerotic ulcer 1 case; Aortitis at descending aorta 1 case; Coarctation of aorta 1 case).

Diagnosis	Number of patients	Percent
Dissecting aortic aneurysm type A	12	7.3
Dissecting aortic aneurysm type B	31	18.8
Ascending aortic aneurysm	9	5.5
Aortic arch aneurysm	8	4.8
Descending aortic aneurysm	14	8.5
Suprarenal aortic aneurysm	5	3.0
Infrarenal aortic aneurysm	45	27.3
Peripheral arterial disease	4	2.4
Normal/ atherosclerotic change	30	18.2
Other*	7	4.2
Total	165	100

Vertebral level of IMA origin

The distribution and percentage of the IMA origin are summarized in Table 4.

Branching patterns

Five different branching patterns are present in Table 5 and Figure 3 - 6.

Aberrant branches

There are only two cases showing aberrant patterns (1.2%). These are LCA branching off from SMA and IMA branching off from SMA without abdominal aorta origin (Figure 7). The IMA branches off from SMA gives the three classical branches as LCA, SA, and SRA.

Table 4. Vertebral level of IMA origin (* One case with absent IMA origin from aorta).

Vertebral levels	Number of patients	Percent
Superior endplate L2	3	1.8
Inferior endplate L2	5	3.0
Superior endplate L3	25	15.3
Body L3	49	29.9
Inferior endplate L3	40	24.4
Superior endplate L4	25	15.3
Body L4	12	7.3
Inferior endplate L4	5	3.0
Total	164*	100

Table 5. Branching patterns.

Patterns	Number of patients	Percent
1: Three arterial branches off from the same point	47	28.5
2: SA branches off from LCA	25	15.2
3: SA branches off from SRA	57	34.5
4: SAs branches off from both LCA and SRA	14	8.5
5: Two LCAs branch off from IMA	20	12.1
Aberrant branch	2	1.2
Total	165	100

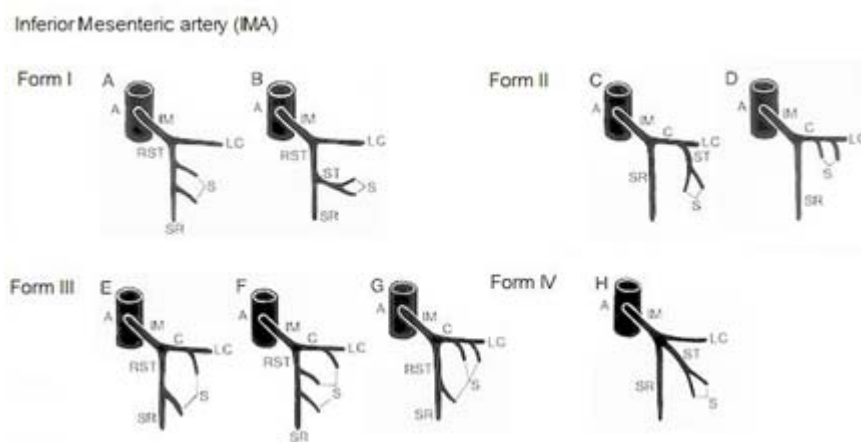


Figure 1. IMA branching patterns from the study of Zebrowski, Augustynaik and Zajac (1971). A, aorta; C, common colosigmoid trunk; IM, inferior mesenteric artery; LC, left colic artery; RST, rectosigmoid trunk; S, sigmoid arterial branches; SR, superior rectal; ST, sigmoid trunk. Image from study of Bergman RA, Afifi AK, Miyauchi RM. Illustrated Encyclopedia of Human Anatomic Variation.⁽²⁾

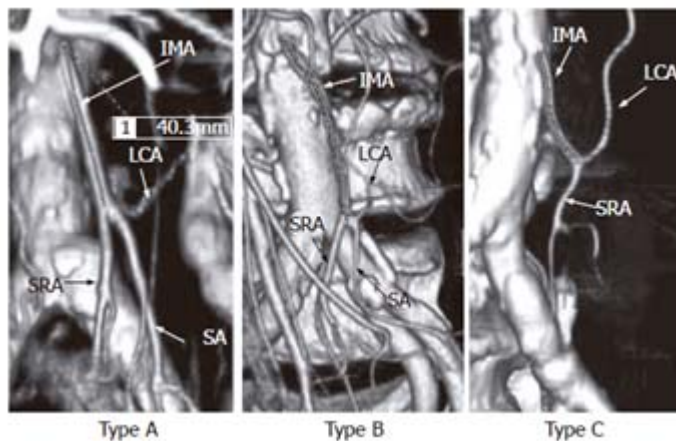


Figure 2. The branching type of IMA. Type A: The three arterial branches off from the same point; Type B: SA branches off from LCA; Type C: SA branches off from SRA. Image from study of Kobayashi et al. World J Gastroenterol 2006.⁽³⁾

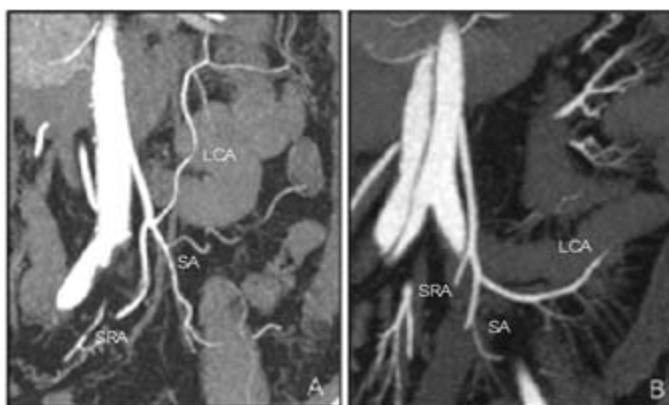


Figure 3. A, Branching pattern 1: Three arteries branch off from the same point; B, Branching pattern 2: SA branches off from LCA.

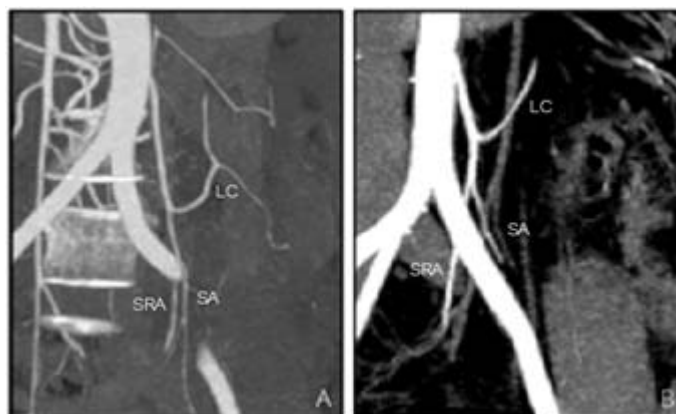


Figure 4. Branching pattern 3: SA branches off from SRA which are divided into 2 forms by LCA patterns; A, LCA gives off ascending and descending branches (21.2%); B, LCA courses to splenic flexure (13.3%).

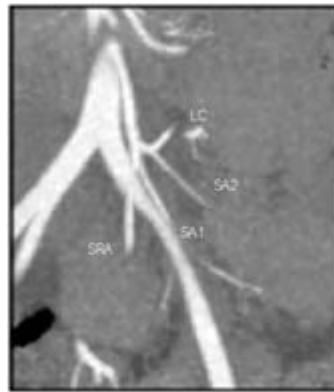

Figure 5. Branching pattern 4: SAs branches off from both LCA and SRA.

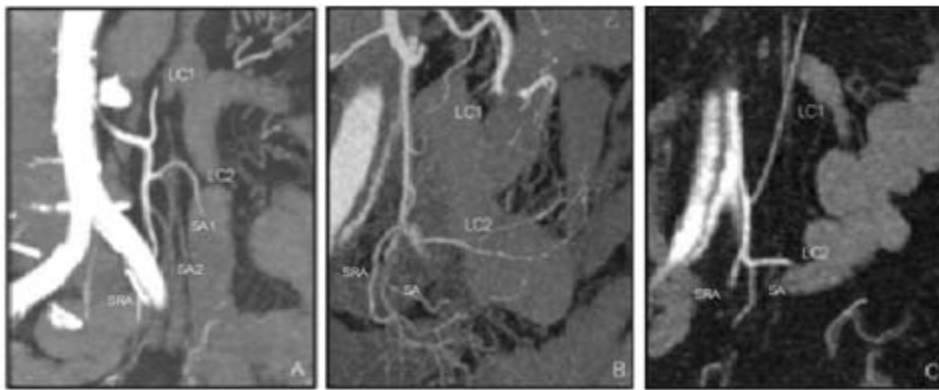


Figure 6. Branching pattern 5: Two LCAs branch off from IMA which are divided into 3 forms by SA branching patterns; A SAs branch off from both LCA and SRA (3.6%); B, SA branches off from SRA (2.4%); C, SA branches off from LCA (12.1%).

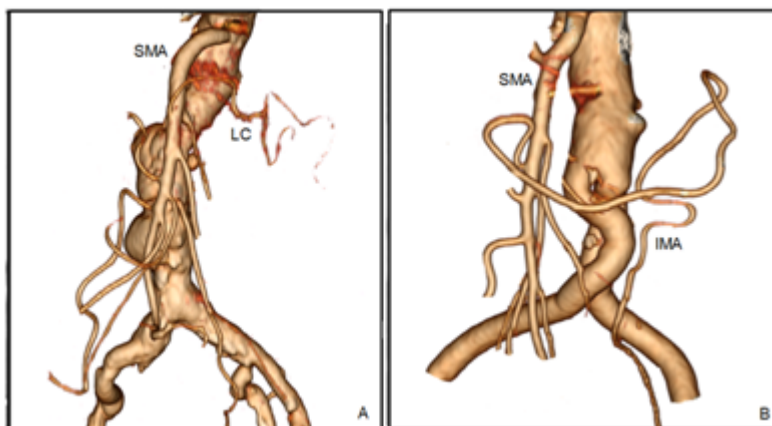


Figure 7. Two aberrant branching pattern. A, LCA branches off from SMA; B, IMA branches off from SMA without origin from abdominal aorta.

Discussion

In generally, the origin of IMA may arise anywhere from the level of the second lumbar vertebra to the middle-third of the fourth lumbar vertebra.⁽¹⁾ In our study, 87.9% of the cases, IMAs originated between inferior endplate of second lumbar vertebra and superior endplate of fourth lumbar vertebra. The most frequent level of origin is the third lumbar vertebral body (29.9%). These results are consistent with the previous angiographic study from Kahn and Abrams, U.S., 1964⁽⁹⁾ that 87% of cases, IMAs originate between the lower border of the second lumbar vertebra and the upper border of the fourth lumbar vertebra and the most frequent level of origin is the inferior border of L3 vertebral body (26.7%).

In a group of patients present with infrarenal aortic aneurysm that may alter normal anatomy of the origin level. The variability of origin levels in this group is greater than normal group. However, the most frequent origin level is the same at body of third lumbar vertebra (22.2%).

In the study using CTA technique in evaluation of IMA anatomy same as our study, Kobayashi *et al.*, 2006 from Japan⁽³⁾ has reported 3 classic branching patterns; three arterial branches off from the same point (10%), SA branches off from LCA (45%), and SA branches off from SRA (27%) (Figure 2). The remaining 16% are undetermined branching type. These 3 branching patterns are presented 78.2% in our study and the most frequent pattern is SA branches off from SRA (34.5%) which is different from the study of Kobayashi *et al.*

The other two branching patterns are demonstrated in our study. The first is SA which

branches off from both LCA and SRA (8.5%). This pattern has been reported in the study of Zebrowski, Augustyniak and Zajac, 1971 in Poland⁽²⁾ as IMA branching pattern form III which IMA divides into rectal-sigmoid and colosigmoid trunks (Figure 1).

Another pattern in our study is the two LCAs that branch off from IMA (12.1%) which is a new IMA branching pattern. In our knowledge, there has never been any report of this branching pattern before.

The IMA is a relatively regular and constant vessel. The variations of this vessel are very uncommon but they found two patterns in our study. From the study of Seung Jin Yoo *et al.*, in Korea, in 2011, they name a case of IMA arising from SMA without abdominal aorta origin as the common mesenteric artery or bimesenteric trunk. About 10 cases were presented in his reported literature from cadaveric study. Almost all cases are male and IMA branching off from SMA as the first or second branch.⁽¹⁴⁾

In our study, we found one case with no IMA origin from aorta but there is a branch from SMA that supplied IMA territory. This branch has the same characteristic of the ordinary IMA and gives the three classical branches as LCA, SA and SRA. However, in our case, there is a question that this aberrant branching pattern is the true common mesenteric artery or collateral vessel from SMA. Because of an extensive atherosclerotic change of the aorta and previous aortic surgery near IMA origin are found in this case. These are possible causes of chronic IMA occlusion. So the branch that we found from SMA, is more probable a collateral branch to supply IMA territory than true anatomic variation.

Another case of aberrant branching pattern is LCA branching from SMA. This aberrant branching pattern has been reported 1% by Lippert *et al.*, 1985.⁽⁴⁾

There are some limitations in this study. First, it was performed retrospectively. Second, we do not have other image modalities such as DSA to compare with our MDCT angiographic study. The small arterial branches may not be visualized on MDCT, so they can be misinterpreted as absent. Finally, there is too small sample size to reflect the true frequency of aberrant branches.

Conclusion

There are anatomical variations of IMA, including; the level of origin, branching patterns and aberrant branches. The MDCT angiography is a non-invasive imaging method which provides good image quality and good information of vascular anatomy. In the Thai population, branching pattern and aberrant branches show some variation from the previously reported cases. Therefore, awareness for the new form of vascular variations could assist in safe accomplishment of the interventional and surgical procedures.

References

1. Rosenblum JD, Boyle CM, Schwartz LB. The mesenteric circulation. *Anatomy and physiology. Surg Clin North Am* 1997 Apr; 77(2):289-306
2. Bergman RA, Afifi AK, Miyauchi RM. Inferior mesenteric artery. *Illustrated Encyclopedia of Human Anatomic Variation* [online] 1995-2013 [cited 2012 Sep 15]. Available from: URL:<http://www.anatomyatlases.org/AnatomicVariants/Cardiovascular/Text/Arteries/InferiorMesenteric.shtml>
3. Kobayashi M, Morishita S, Okabayashi T, Miyatake K, Okamoto K, Namikawa T, Ogawa Y, Araki K. Preoperative assessment of vascular anatomy of inferior mesenteric artery by volume-rendered 3D-CT for laparoscopic lymph node dissection with left colic artery preservation in lower sigmoid and rectal cancer. *World J Gastroenterol* 2006 Jan 28; 12(4):553-5
4. Lippert H, Pabst R. Arterial variations in man: classification and frequency. Munchen: JF Bergmann Verlag 1985; 52-3
5. Nonent M, Larroche P, Forlodou P, Senecail B. Celiac-bimesenteric trunk: anatomic and radiologic description-case report. *Radiology* 2001 Aug; 220(2):489-91
6. Stimec BV, Terraz S, Fasel JH. The third time is the charm-anastomosis between the celiac trunk and the left colic artery. *Clin Anat* 2011 Mar; 24(2):258-61
7. Kornblith PL, Boley SJ, Whitehouse BS. Anatomy of the splanchnic circulation. *Surg Clin North Am* 1992 Feb; 72(1):1-30
8. Loukas M, Aparicio S, Beck A, Calderon R, Kennedy M. Rare case of right accessory renal artery originating as a common trunk with the inferior mesenteric artery: a case report. *Clin Anat* 2005 Oct; 18(7):530-5
9. Kahn P, Abrams HL. Inferior mesenteric arterial patterns; an angiographic study. *Radiology* 1964 Mar; 82:429-42
10. Erden A, Yurdakul M, Cumhuri T. Doppler waveforms of the normal and collateralized

- inferior mesenteric artery. Am J Roentgenol 1998 Sep; 171(3):619-27
11. Chuang VP, Wallace S, Zornoza J, Davis LJ. Transcatheter arterial occlusion in the management of rectosigmoidal bleeding. Radiology 1979 Dec; 133(3 Pt1):605-9
12. Horton KM, Fishman EK. CT angiography of the mesenteric circulation. Radiol Clin North Am 2010 Mar; 48(2):331-45 ,viii
13. Horton KM, Fishman EK. Volume-rendered 3D CT of the mesenteric vasculature: normal anatomy, anatomic variants, and pathologic conditions. Radiographics 2002 Jan-Feb; 22(1):161-72
14. Yoo SJ, Ku MJ, Cho SS, Yoon SP. A case of the inferior mesenteric artery arising from the superior mesenteric artery in a Korean woman. J Korean Med Sci 2011 Oct; 26(10): 1382-5
13. Horton KM, Fishman EK. Volume-rendered 3D CT