

1-1-2016

Modified bilateral sagittal split osteotomy for correction of severe anterior open bite: Technical note and case report

Prasarn Tangarturonrasme

Laddawun Sununliganon

Follow this and additional works at: <https://digital.car.chula.ac.th/clmjournal>



Part of the [Medicine and Health Sciences Commons](#)

Recommended Citation

Tangarturonrasme, Prasarn and Sununliganon, Laddawun (2016) "Modified bilateral sagittal split osteotomy for correction of severe anterior open bite: Technical note and case report," *Chulalongkorn Medical Journal*. Vol. 60: Iss. 1, Article 4.

DOI: <https://doi.org/10.58837/CHULA.CMJ.60.1.4>

Available at: <https://digital.car.chula.ac.th/clmjournal/vol60/iss1/4>

This Clinical Report is brought to you for free and open access by the Chulalongkorn Journal Online (CUJO) at Chula Digital Collections. It has been accepted for inclusion in Chulalongkorn Medical Journal by an authorized editor of Chula Digital Collections. For more information, please contact ChulaDC@car.chula.ac.th.

Modified bilateral sagittal split osteotomy for correction of severe anterior open bite: Technical note and case report

PrasarnTangarturonrasme*

Laddawun Sununliganon*

Tangarturonrasme P, Sununliganon L. Modified bilateral sagittal split osteotomy for correction of severe anterior open bite: Technical note and case report. Chula Med J 2016 Jan – Feb;60(1): 45 - 54

Bilateral sagittal split osteotomy (BSSO) is a common procedure used for the correction of mandibular anomalies. This procedure has been through various modifications that aims to increase skeletal stability and reduce possible complications. So far, the limitation of BSSO technique remains a concern in certain circumstances, such as skeletal relapse after closing of anterior open bite, especially in severe cases. Also, there is a risk of facial paralysis following a large amount of mandibular setback in a severe mandibular prognathism. Therefore, concomitant surgery such as segmented osteotomy and/or maxillary osteotomy may be used for correction of the deformity in order to avoid those specific complications. This article proposes a new alteration of BSSO technique (Prasan's modification) that provides an ease of mandibular counterclockwise rotation. This method also allows the mandible to be set backward to a large extent. The modification of posterior osteotomy makes this technique simpler than the existing BSSO methods. For example, a satisfactory result after using this technique was demonstrated in this case report of a patient with severe anterior open bite in combination with sever mandibular prognathism. Likewise, this method has also enabled the advancement of the mandible. Hence, it can be applied as another alternative procedure for correction of mandibular anomalies.

Keywords: *Modified BSSO, mandibular setback, severe anterior open bite, Ramus osteotomy.*

Reprint request: Sununliganon L. Discipline of Oral and Maxillofacial Surgery, Faculty of Dentistry, Thammasat University, Rangsit Campus. 99 Moo 18 Paholyothin Road, KlongLuang, PathumThani, 12120, Thailand.

Email: suladdawan@hotmail.com

Received for publication. November 26, 2015.

ประธาน ตั้งจาตุรนต์รัศมี, ลัดดาวัลย์ สุนันท์ลีกันนัท. การดัดแปลงเทคนิคการผ่าตัดโดยใช้เทคนิค Bilateral sagittal split osteotomy สำหรับการแก้ไขความผิดปกติกรณที่มีการสบเปิดบริเวณฟันหน้าอย่างรุนแรง: บันทึกทางเทคนิคและรายงานผู้ป่วย. จุฬาลงกรณ์เวชสาร 2559 ม.ค. - ก.พ.; 60(1): 45 - 54

การผ่าตัดด้วยเทคนิค Bilateral sagittal split osteotomy (BSSO) เป็นวิธีที่ใช้อย่างแพร่หลายในการแก้ไขความผิดปกติของขากรรไกรล่างในลักษณะต่าง ๆ ซึ่งในระยะเวลาที่ผ่านมาวิธีการผ่าตัดด้วยเทคนิคนี้ได้มีการดัดแปลงรอยตัดไปในหลายลักษณะ โดยมีวัตถุประสงค์เพื่อให้กระดูกขากรรไกรอยู่ในสภาพที่คงที่ตามแผนการรักษาหลังผ่าตัดเพิ่มมากขึ้น รวมถึงเพื่อลดโอกาสในการเกิดข้อแทรกซ้อนที่อาจเกิดขึ้นได้หลังผ่าตัด แต่อย่างไรก็ตามการใช้เทคนิค BSSO ที่มีอยู่ในปัจจุบันยังมีข้อจำกัดเมื่อมีการนำไปใช้ในแก้ไขความผิดปกติของขากรรไกรล่างบางชนิด เช่น การแก้ไขความผิดปกติที่มีการสบเปิดบริเวณฟันหน้าที่มีอย่างรุนแรง ซึ่งจะมีโอกาสสูงที่จะเกิดการสบเปิดบริเวณฟันหน้ากลับมาได้อีกภายหลังการผ่าตัด นอกจากนี้การแก้ไขความผิดปกติของขากรรไกรล่างที่มีลักษณะยื่นยาวมากจะมีความเสี่ยงที่จะเกิดข้อแทรกซ้อนจากการเป็นอัมพาตของการเกิดกล้ามเนื้อบางส่วนบนใบหน้าหลังผ่าตัดได้ ซึ่งทำให้มีความจำเป็นที่จะต้องวางแผนการรักษาโดยใช้การผ่าตัดด้วยวิธีอื่นเพิ่มเติมด้วย เช่น การผ่าตัดกระดูกโดยการแบ่งกระดูกเป็นชิ้นย่อย ๆ หรือการผ่าตัดบริเวณขากรรไกรบนร่วมด้วย บทความนี้นำเสนอการดัดแปลงเทคนิค BSSO (เทคนิคที่ดัดแปลงโดย ประธาน) ซึ่งจะทำให้การหมุนขากรรไกรล่างในแนวทวนเข็มนาฬิกาเป็นไปได้ง่ายขึ้น รวมถึงช่วยให้การเคลื่อนขากรรไกรล่างจากตำแหน่งที่ยื่นมากไปด้านหลังได้ในระยะทางที่มากขึ้นโดยลดโอกาสการเกิดข้อแทรกซ้อนดังกล่าวได้ การดัดแปลงเทคนิคนี้มีการเปลี่ยนลักษณะของรอยตัดของเทคนิค BSSO บริเวณด้านหลังทำให้การผ่าตัดสามารถทำได้ง่ายขึ้นโดยให้ผลของการผ่าตัดที่ได้เป็นที่น่าพึงพอใจดังที่ได้แสดงในรายงานผู้ป่วยนี้ที่ได้รับการแก้ไขความผิดปกติจากการสบเปิดบริเวณฟันหน้าและมีขากรรไกรล่างยื่นยาวที่มีความรุนแรงนอกจากนี้เทคนิคที่ได้รับการดัดแปลงวิธีนี้ยังสามารถนำไปใช้เพื่อแก้ไขความผิดปกติที่เพื่อยื่นขากรรไกรล่างไปด้านหน้าได้ด้วย ดังนั้นเทคนิคนี้ถือได้เป็นอีกทางเลือกหนึ่งที่ใช้สำหรับการผ่าตัดแก้ไขความผิดปกติของขากรรไกรล่างในลักษณะต่าง ๆ ซึ่งสามารถใช้ทดแทนนอกเหนือจากเทคนิค BSSO ที่มีอยู่ในปัจจุบันได้

คำสำคัญ: Modified BSSO, mandibular setback, severe anterior open bite, ramus osteotomy.

Bilateral sagittal osteotomy (BSSO) is the most popular surgical procedure using for correction of almost all mandibular anomalies. This procedure was first introduced by Obwegeser and Trauner in 1957. Thereafter, it has been through various modifications such as those proposed by Dalpont, Hunsuck and Epker, etc. ⁽¹⁾ However, possible complications related to this technique include bleeding, unexpected fractures, malposition of the bony segments, temporomandibular joint problems and especially a skeletal relapse and facial nerve palsy remain a concern. ⁽²⁾

BSSO technique has been well accepted for correction of anterior open bite. This deformity is well recognized for the difficulty in management that tends to relapse. ⁽³⁾ In particular, the treatment of severe anterior open bite in combination with severe mandibular prognathism is still considered a great challenge. The muscle interference after counter clockwise rotation of the mandible may affect the skeletal relapse and setback of the mandible in a large amount may contribute to facial paralysis. Hence, additional surgery such as segmented osteotomy and maxillary surgery may be chosen in combination with the BSSO technique for correction of the deformities depending on the indication. ⁽⁵⁾ Consequently, the more complicated the surgery, the greater the chance of possible complications can occur.

This article proposes a new BSSO modification that is simple. This method facilitates the closure of anterior open bite as well as a set back of the mandible to a large magnitude with the advantage of reducing the chance of complications.

Technical note: Surgical procedure of the new modified BSSO (Prasan's modification)

Intraorally, mucosal incision is commenced on the buccal side of ascending ramus to the premolar region. Muscles of the posterior and inferior borders of the mandible are slightly stripped from the bone. Then osteotomy is commenced through the bony cortex, starting from the retromolar area extending to the buccal side along the external oblique ridge to the first or second molar region. Anterior vertical osteotomy is then made through the bony cortex until reach the lower border of mandible similar to the existing BSSO methods. Suggestively, the posterior osteotomy is modified using vertical or slightly oblique osteotomy on the retromolar region. Only the bony cortex on the lingual side is cut at approximately 1 cm in length. The expected osteotomy line is illustrated in Fig. 1. Thereafter, a sagittal split of the body of the mandible is performed as usual technique and the inferior alveolar bundle can be inspected (Fig. 2). The final position of the mandible is set as planned by using the occlusal wafer. Overlapping bone on the proximal segment is trimmed and internal fixation is carried out with titanium plates and screws.

Case presentation

A female, 22 years of age complained of unable to bite and protruded lower jaw. She was diagnosed with thyroid disease since a teenager and became an euthyroid condition after continuous treatment. Physical examination revealed mild exophthalmos, mild paranasal deficiency, increase lower facial height, normal lip length, negative incisor show and high mandibular plane angle with severe mandibular prognathism. Pretreatment and

presurgical pictures are illustrated in Fig. 3 (a1-a3), (b1-b5) and Fig 4 (a1-a5), (b1-b5). Intra-orally, the open bite was observed from the second molars on one side to another side. Anteriorly, the open bite was measured at 12 mm and the over jet was -9 mm. The temporomandibular joints and jaw movement

were normal. Radiographic examination revealed mild elongation of both the condylar necks, elongation of the mandibular body, severe anterior open bite and reverse curve of Spee, Fig. 5 (a1, a2, b2) and Fig. 6 (a1, a2, b1). Cephalometric analysis is demonstrated in Table 1.

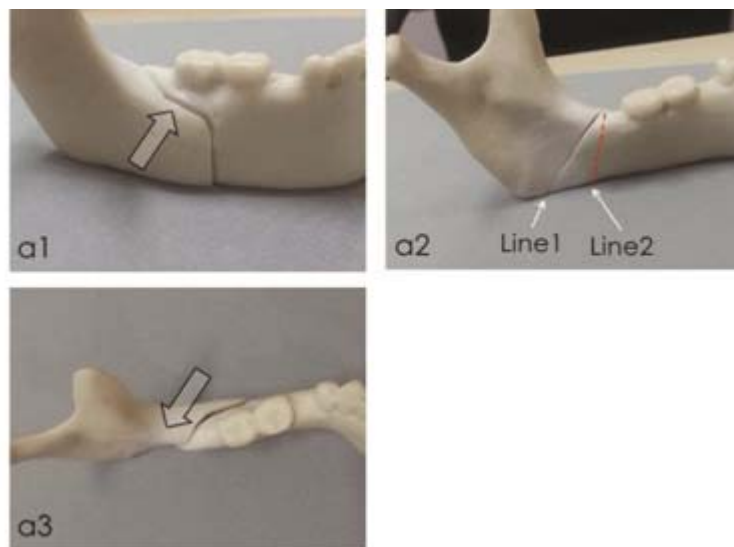


Figure 1. Illustration of the new BSSO modification (T. Prasan's method). a1: Buccal osteotomy. a2: Posterior osteotomy at the retromolar area on lingual side. The fracture line is expected to be located between line 1 and 2). a3: Top view of the osteotomy line.

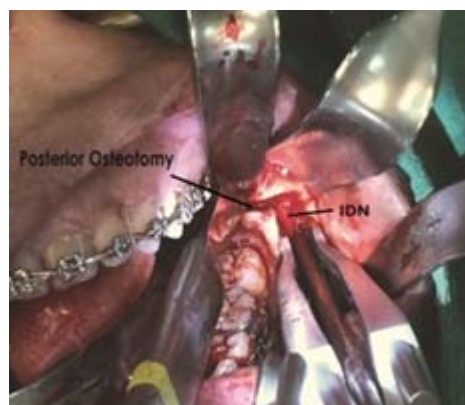

Figure 2. Clinical illustration of the posterior osteotomy in Prasan's modification method. The inferior dental nerve (IDN) is identified.

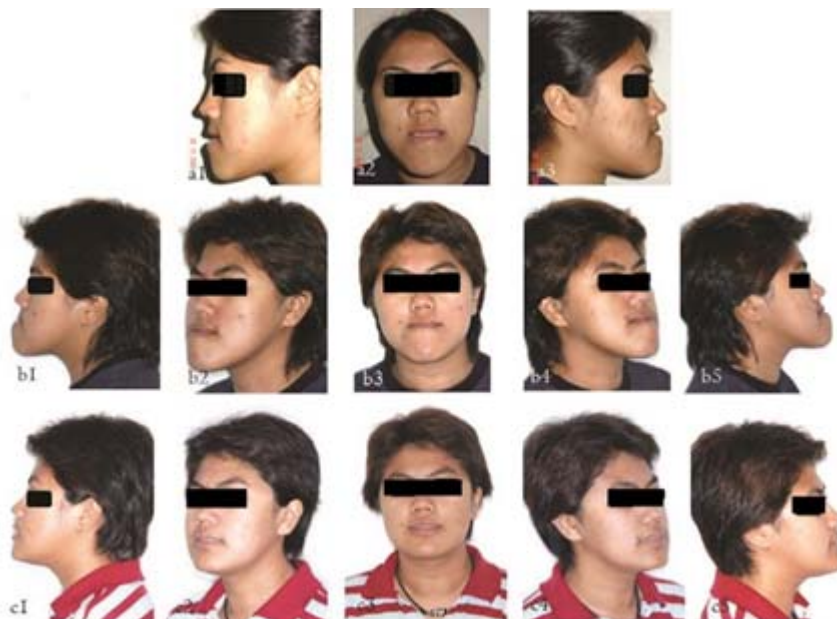

Figure 3. Clinical presentations of patient at pre-treatment (a1-3), presurgery (b1-b5) and post-surgery at 9 months (c1-5).

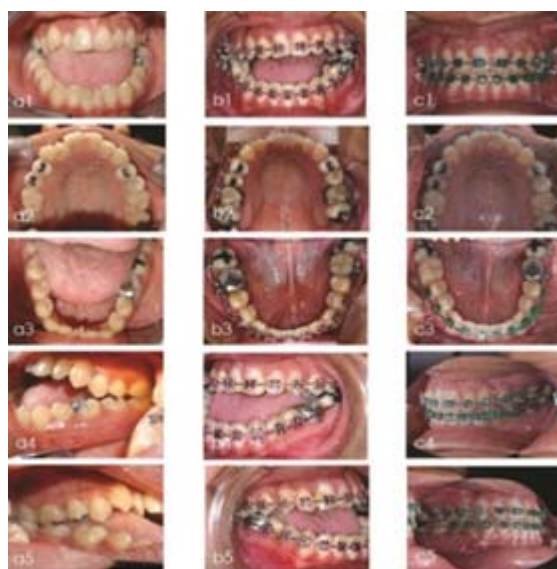

Figure 4. Intra-oral presentations of patient at pre-treatment (a1-a5), pre-surgery (b1-b5), and post-surgery at 9 months (c1-c5).

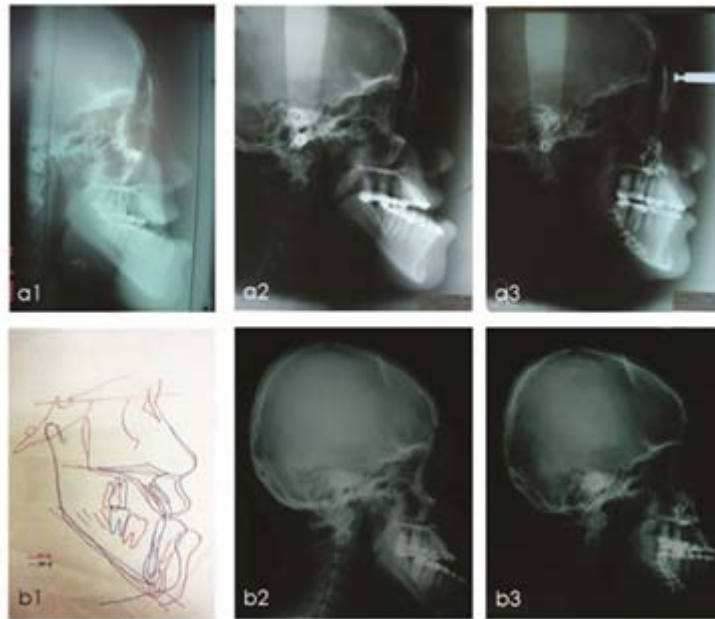


Figure 5. Lateral cephalographs of patients at pre-treatment (a1), pre-surgery (a2), and post-surgery at 9 months (a3). b1: Superimposition of cepharometric tracings at pre (red color) and post-surgery (blue color). Lateral skull radiographs at pre-surgery (b2) and post-surgery at 1 year and 3 months (b3).

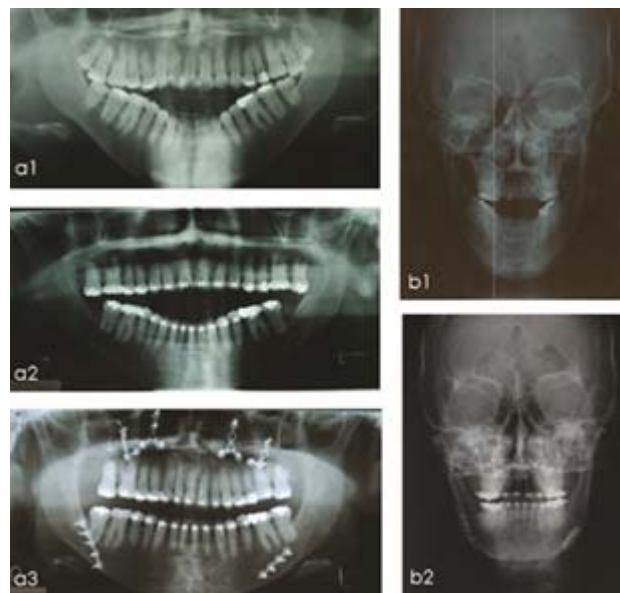


Figure 6. Orthopantomograms at pre-treatment (a1), pre-surgery (a2), and post-surgery at 9 months (a3). Postero-anterior radiographs at pre-treatment (b1) and post-surgery at 9 months (b2).

Table 1. Cephalometric analysis.⁽⁶⁾

	Measurement	Female norm ⁶	Pre-op	Post-op 9 months
Cranial base	FH-SN (dg)	67.9	11.5	65
	SN (mm)		65	
Maxilla	SNA	85.2	87	89
	NA-FH		93	
Mandible	SNB	81.3	92	89
	MP-FH		35	29
	Go. Angle (dg)		147	136
	Pog-NB (mm.)		-2	-1
	Y-axis (FH-SGn)		57	55
Direction of growth	UAFH: LAFH (%)	81	69.77	77.63
Vertical analysis	ANB (dg)	3.9	-5	0
Jaw relation	Co-A (mm)	90.1	87	90
	Co-Gn (mm)	116.9	148	140
	MP-PP (dg)		38	29
	WIT (mm.)		-24	-9
	1-NA (dg)		32	27
Upper tooth	1-NPog (mm.)		4.5	8
	1-PP (dg)		128	127
	ADH		30	36
	PDH		24	24
	1-NB (dg)		32	23
Lower tooth	1-MP (dg)		79	74
	1 to 1 (dg)		115	130
	ANB (dg)	3.9	-5	0
Teeth relation	OVJ (mm.)	1.6	-12	4
	OVJ (mm.)	2.6	-9	2
	NLA (dg)		100	102
Soft tissue	FCA (dg)		0	8
	UFH (mm.)		54	50
	LFH (mm.)		90	81
	ULL (mm.)		22.5	22
	TL (mm.)		54	50
	LCT (dg.)		108	112
	L-lip t o E line (mm.)	1.8	6.5	0

In brief, the maxilla appeared mild hypoplasia and the mandible appeared hyperplasia with marked clockwise rotation causing a dramatic increase in lower face height. Long face syndrome with the severe anterior open bite of the skeletal Class III deformity was diagnosed. The surgical treatment included two-jaw surgery. The original surgical plan was 4 pieces Le Fort I osteotomy with extraction of 14, 24 on the maxilla and double setback of mandible by step osteotomy with extraction of 34, 44 in combination with BSSO. However, we changed our plan to be one piece Le Fort I osteotomy and Prasan's modified BSSO technique. In this particular case, Le Fort I osteotomy was utilized for forward and downward movement with decanting of the maxilla. As a result, the paranasal area was improved and the upper incisor show was increased. The tip the upper incisors was moved forward at approximately 4 mm. On the mandible, the modified BSSO by Prasan was applied with a setback at 14 mm measuring from the tip of the lower central incisor as well as counterclockwise rotation to close the open bite with the net vertical changes at 16 mm. No intermaxillary fixation was applied and elastic training was commenced to refine the occlusion on day 5 post-operation. Postoperatively, the clinical and radiographic presentations were demonstrated in Fig. 3 (c1-c5), 4 (c1-c5), 5 (a3, b3) and 6 (a3, b2). The comparison of pre and post-cephalometric tracings are illustrated in fig. 5b1. The patient's recovery was uneventful and a temporary paresthesia on the chin was noted during the first 3 months after operation.

Discussion

The advantages of this modified BSSO technique, especially for correction of the severe anterior open bite with mandibular prognathism deformity caused by the abnormal mandible were discussed. Using the existing BSSO techniques, the center of rotation of mandible for the closing of the open bite is located in the area between the ligula and the posterior border of the mandible depending on the location of its posterior split. The location of the center of rotation and the posterior border after sagittal split of ramus correlates with muscle interference which may play a part in a relapse of the open bite. Also, the distance for the mandibular setback of all methods is limited by the distance between the posterior split of the ramus and the course of the facial nerve.^(7,8) Therefore, additional osteotomy or a more complicate surgery of Obwegeser II method may be used for the correction of this severe deformity to avoid the above mentioned complications.

The Obwegeser II method was introduced by Obwegeser in 1964 with the main purpose to close the severe anterior open bite. In detail, part of the bone on the proximal segment after sagittal split of the ramus is temporary removed to gain the access for IDN dissection and removal part of the bone on distal segment. Therefore the mandible is freely rotated and aligned before fixation.^(7,9) Though an adequate skeletal stability was confirmed by Kwon et al., the risk of IDN injury with the use of this method seems to be increasing.⁽¹⁰⁾

In comparison to Prasan's method, this modification makes the technique simpler than the existing techniques. It increases the magnitude of mandibular counter clock wise rotation and setback.

The center of rotation of the mandible is shifted to the retromolar area which allows the distal segment to be easily rotated with minimal muscle interference. Also, it increases the distance for mandibular setback because the posterior osteotomy is moved to the more anterior region than in the other methods. Dramatic changes without any complication can be achieved as illustrated in this case report. No force was applied for bony fixation and the occlusion was very stable throughout the healing period. In our experiences, this method also provided a satisfactory esthetic result and adequate skeletal stability in correction of the mandibular retrognathia and asymmetry.

Conclusions

The presence modification technique is one of the solutions for surgical treatment of mandibular anomalies, including severe anterior open bite and the severe mandibular prognathism. It provides the advantages over the existing methods in term of simplification and increase the potency for correction of this severe deformity. However, the evaluation of a long term result in a large group of the patient is necessary to endorse the efficacy of this technique which has been now monitoring in our unit.

Acknowledgements

We would like to offer our thanks the medical staffs and nurses of Thammasat Chalermprakiet Hospital, Thammasat University, Thailand.

References

1. Böckmann R, Meyns J, Dik E, Kessler P. The modifications of the sagittal ramus split osteotomy: a literature review. *Plast Reconstr*

- Surg Glob Open* 2015 Jan 8; 2(12):e271
2. Monson LA. Bilateral sagittal split osteotomy. *Semin Plast Surg* 2013 Aug; 27(3): 145 - 8
3. Jędrzejewski M, Smektała T, Sporniak-Tutak K, Olszewski R. Preoperative, intraoperative, and postoperative complications in orthognathic surgery: a systematic review. *Clin Oral Investig* 2015 Jun;19(5):969-77
4. Fontes AM, Joondeph DR, Bloomquist DS, Greenlee GM, Wallen TR, Huang GJ. Long-term stability of anterior open-bite closure with bilateral sagittal split osteotomy. *Am J Orthod Dentofacial Orthop* 2012 Dec;142(6): 792 - 800
5. Kor HS, Yang HJ, Hwang SJ. Relapse of skeletal class III with anterior open bite after bimaxillary orthognathic surgery depending on maxillary posterior impaction and mandibular counter clock wise rotation. *J Cranio maxillofac Surg* 2014 Jul; 42(5): e230-8
6. สุรัชย์ เดชคุณากร, จิราภรณ์ ชัยวัฒน์, พรวิชนี แสงวงกิจ, นิวัติ อนุวงศ์นุเคราะห์, นฤมล ทวีเศรษฐ์. ค่าปกติของผู้ใหญ่ไทยในการวิเคราะห์แบบต่าง ๆ จากภาพถ่ายรังสีกะโหลกศีรษะด้านข้าง ว. ทันต 2537; 44: 202 ใน: Satravaha S, Taweedsed N. Nonsurgical orthodontic treatment of anterior open-bite in adult: A case report. *O J Thai Assoc Orthod* 2002;1(1): 25 - 31
7. Obwegeser HL, Luder HU. The sagittal splitting of the mandible procedure. In: Obwegeser HL, ed. *Mandibular Growth Anomalies*. Berlin, German, Springer science & Business Media, 2000: 359-84
8. Lin LH, Huang GW, Chen CS. Etiology and

- treatment modalities of anterior open bite malocclusion. J Exp Clin Med 2013 Feb;5(1): 1-4
9. Proffit WR, Fields HW, Sarver DM. Contemporary Orthodontics. St Louis, Missouri, Mosby Elsevier, 2006
10. Kwon T, Na K, Lee S. Obwegeser II osteotomy (transoral angle osteotomy) for open bite with skeletal class III deformity. J Craniomaxillofac Surg 2014 Oct; 42(7): 1382-8