

1-1-2002

Child abuse presenting as chylothorax and chylous ascites : a case report

D. Visinonta

A. Mahayosnond

Follow this and additional works at: <https://digital.car.chula.ac.th/clmjournal>



Part of the [Medicine and Health Sciences Commons](#)

Recommended Citation

Visinonta, D. and Mahayosnond, A. (2002) "Child abuse presenting as chylothorax and chylous ascites : a case report," *Chulalongkorn Medical Journal*: Vol. 46: Iss. 1, Article 7.

DOI: 10.58837/CHULA.CMJ.46.1.6

Available at: <https://digital.car.chula.ac.th/clmjournal/vol46/iss1/7>

This Case Report is brought to you for free and open access by the Chulalongkorn Journal Online (CUJO) at Chula Digital Collections. It has been accepted for inclusion in Chulalongkorn Medical Journal by an authorized editor of Chula Digital Collections. For more information, please contact ChulaDC@car.chula.ac.th.

Child abuse presenting as chylothorax and chylous ascites : a case report

Duangdao Vasinonta*

Atchara Mahayosnond*

**Vasinonta D, Mahayosnond A. Child abuse presenting as chylothorax and chylous ascites:
a case report. Chula Med J 2002 Jan; 46(1): 57 - 64**

Child abuse is a social problem which must receive accurate diagnosis, treatment and psychological support. There is no problem in cases that have clear history and physical examination. However, clinicians must beware of discrepancies between clinical evidence of injury and unexplained accounts of the event. Signs of malnutrition, bruises or burns should prompt further medical evaluation for physical abuse. The least frequent causes of chylothorax and chylous ascites are trauma, so child abuse would rarely be considered as a cause: The radiologic detection of skeletal trauma still plays a prominent role in diagnosing child abuse cases with no classic historical or physical features. Uncommon fractures such as of the lateral end of the clavicle, ribs, scapula, sternum and spine are felt to be highly suspicious and might even be considered as a valuable sign of child abuse.

Key words : *Child abuse, Chylous ascites, Chylothorax.*

Reprint request : Vasinonta D. Department of Radiology, Faculty of Medicine,
Chulalongkorn University, Bangkok 10330, Thailand.

Received for publication. September 12, 2001.

* Department of Radiology, Faculty of Medicine, Chulalongkorn University

ดวงดาว วะสินนท์, อัจฉรา มหายศนันท์. ภาวะเด็กถูกทำร้ายที่มาแสดงด้วยอาการของ chylothorax และ chylous ascites. จุฬาลงกรณ์เวชสาร 2545 ม.ค; 46(1): 57 - 64

ภาวะเด็กที่ถูกทำร้ายเป็นปัญหาที่พบได้บ่อยในสังคมปัจจุบัน ซึ่งจำเป็นต้องได้รับการวินิจฉัยรักษาและฟื้นฟูจิตใจอย่างเหมาะสม การได้รับประวัติและการตรวจร่างกายที่ชัดเจนมักไม่มีปัญหาในการวินิจฉัยผู้ป่วย แต่เมื่อพบว่าอาการและอาการแสดงของเด็กเข้าไม่ได้กับเหตุการณ์และประวัติที่ได้รับ แพทย์ผู้รักษาคำนึงถึงภาวะนี้ไว้ด้วย และบางครั้งอาการแสดงของเด็กที่มาโรงพยาบาลไม่ได้ทำให้เราคิดถึงเรื่องของเด็กที่ถูกทำร้าย อย่างเช่น Chylous ascites และ Chylothorax ดังนั้นภาพทางรังสี จึงมีบทบาทในการวินิจฉัยภาวะเด็กที่ถูกทำร้าย ซึ่งไม่มีประวัติและการตรวจร่างกายที่เข้าได้ การมองหากระดูกหักในจุดที่เจอได้ไม่บ่อย เช่น ปลายนอกของกระดูกไหปลาร้า posterior และ lateral region ของกระดูกซี่โครง กระดูกสะบัก กระดูกหน้าอกและกระดูกสันหลังต้องดูอย่างละเอียด เพราะมักจะสัมพันธ์กับภาวะเด็กถูกทำร้าย

Child abuse may present with a broad array of sign and symptoms. A child with chylothorax and chylous ascites with no other plausible explanation for these conditions should be suspected as suffering physical abuse. Chylous ascites and chylothorax may coexist in an abused child as extremely rare sequelae of blunt trauma.⁽¹⁻⁹⁾ Skeletal imaging is essential to identify associated osseous injuries in cases with no classic historical or physical features. Although chylothorax and chylous ascites are benign conditions, the clinical course is often malignant in infancy.^(3,4) The purpose in reporting this case is to alert health professionals to an unusual manifestation of child abuse.

Case report

A year and a half old girl was brought to our hospital by her mother with problems of abdominal distension, fever and dyspnea. She was in good health until 2 months before this admission. Two months previously she had had respiratory tract symptoms of fever, cough, dyspnea and wheezing and was treated twice at another hospital. A few days prior to this admission, abdominal distension developed and she was referred to our hospital for investigation.

On examination, the child appeared thin. She was afebrile with normal vital signs. Her weight of 7.2 kgs, height of 73 cms and head circumference of 44 cms placed her in less than the third percentile of her age, representing delayed physical development. A slightly globular shape of the abdomen, with positive shifting dullness was detected. There was also a swelling of the left lower back with a cystic consistency and a diameter about 8 cms. No BCG scar was seen.

The initial hematocrit was 32.4 % and the urinalysis was normal. A diagnostic peritoneal tap returned a milky fluid. Chemical analysis of the fluid revealed total protein of 4.7 g/dl, amylase 86 IU/dl, glucose 119mg/dl, triglyceride 1,284 mg/dl, SPGR = 1.035, RBC = 1,855, WBC = 19,290 (all mononuclear) and lipase = 23. No organism was seen on gram stain and subsequently none grew in culture.

A chest radiograph shown right upper lobe opacity and right pleural effusion. Thoracocentesis found a milky pleural effusion with triglyceride 1,351 and cholesterol 118. Chylothorax and chylous ascites were diagnosed at that time. Initially the patient was supportively treated and was fed a fat free diet. On the 4th day of admission, a central line was placed. Total parenteral nutrition was administered and nothing was given orally.

Serial chest radiographs shown an increasing right pleural effusion. The right upper lobe opacity was still seen. An additional finding on CXR apart from the pleural effusion were healing fractures of right 5th and bilateral 6th rib heads. Healing fractures of the right 4th, 6th rib necks and the lateral aspect of left 6th rib were also noted on reviewing studies. (Fig 1.)

Two weeks after treatment, there was no progression of chyle leakage. Abdominal circumference decreased from 45 cms to 42 cms. A chest tube was inserted in the right thorax. Then a fat free diet was started with partial parenteral nutrition for 1 week, followed by special formula milk and a fat free diet. The abdominal circumference decreased from 42 cms to 40 cms. Two weeks later a regular diet was started. No progression of chyle leakage was seen and no increase in abdominal circumference was detected. The patient was diagnosed as probable child

abuse. She did well following treatment and was later discharged.

Two weeks after discharge, she had recurrence of her respiratory symptoms and was brought to our hospital for a 2nd admission. Chest radiograph showed a massive right pleural effusion. There were also new fractures: an incomplete fracture at lateral arc of right 1st rib and a fracture at the left proximal humeral metaphysis. (Fig. 2) A chest tube was inserted with supportive treatment and dietary modification. The patient was in good condition after treatment. Follow-up CXR showed marked decrease of the right pleural effusion but also a decreased

height of the T6 vertebral body that was not well visualized on the date of admission. The left proximal left humeral metaphysis was well seen. (Fig.3) A compression fracture of T6 vertebral body was confirmed on CT scan and the patient was later discharged. (Fig. 4)

On follow up the child was in good health. Chest radiograph shown RUL atelectasis, no pleural effusion, no new fracture, callus formation at the old fracture sites and calcified prevertebral hematoma as seen on CT before discharge. (Fig. 5) Liason with a social worker of the Child Welfare Protection Division for protecting reabused was established.

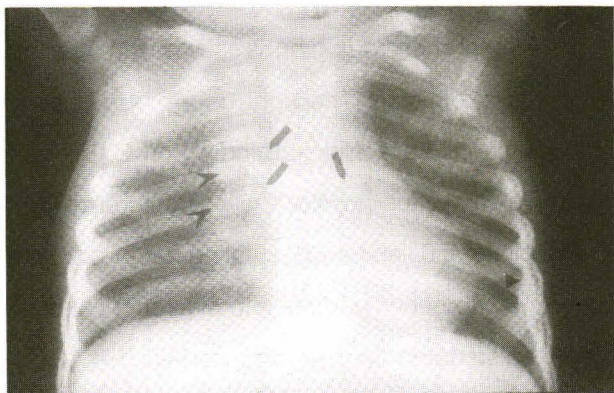


Figure 1. Right upper lung opacity with right pleural effusion is detected, RUL atelectasis with right pleural effusion. Irregularity, sclerosis and callus formation involving the head of right 5th, 6th and left 6th ribs are observed representing healing rib head fracture (arrows). Widening of right 5th and 6th rib necks are seen representing healing rib neck fracture (open arrows). Callus formation with no demonstrable fracture line at lateral left 6th rib representing healing lateral arc fracture (arrow head).

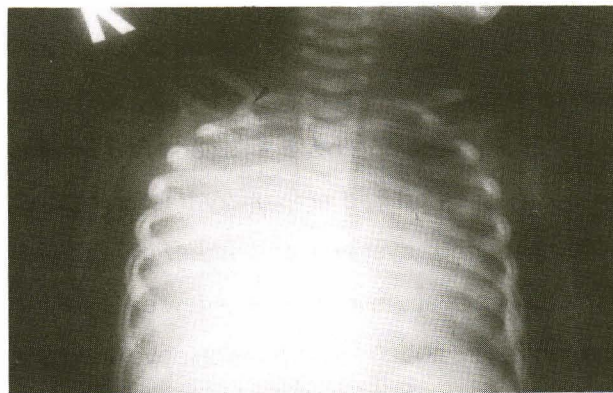


Figure 2. Total opacity of right hemithorax with mediastinum shifted to the left is noted, massive right pleural effusion. Linear incomplete fracture through the inner margin at lateral arc of right 1st rib is noted consistent with an inward bending of the anterior rib during thoracic compression (arrow).

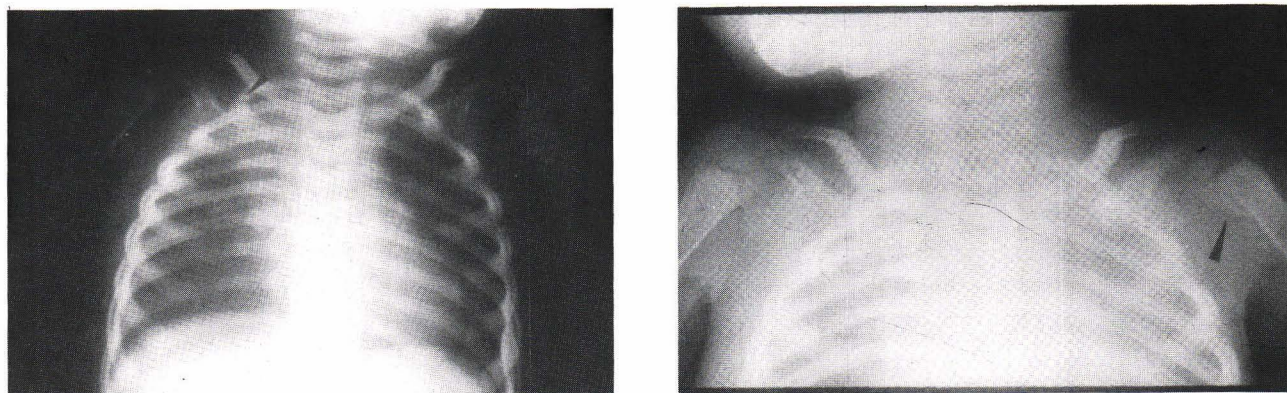


Figure 3. A, RUL opacity with right pleural effusion is noted, marked decreased as compared to Fig 2. Decreased height of T6 vertebra is presented, compression fracture of T6 vertebra is suggested. Fracture lateral arc of right 1st rib is still seen (arrow). B, Left proximal humeral metaphysis fracture is detected (arrow) .

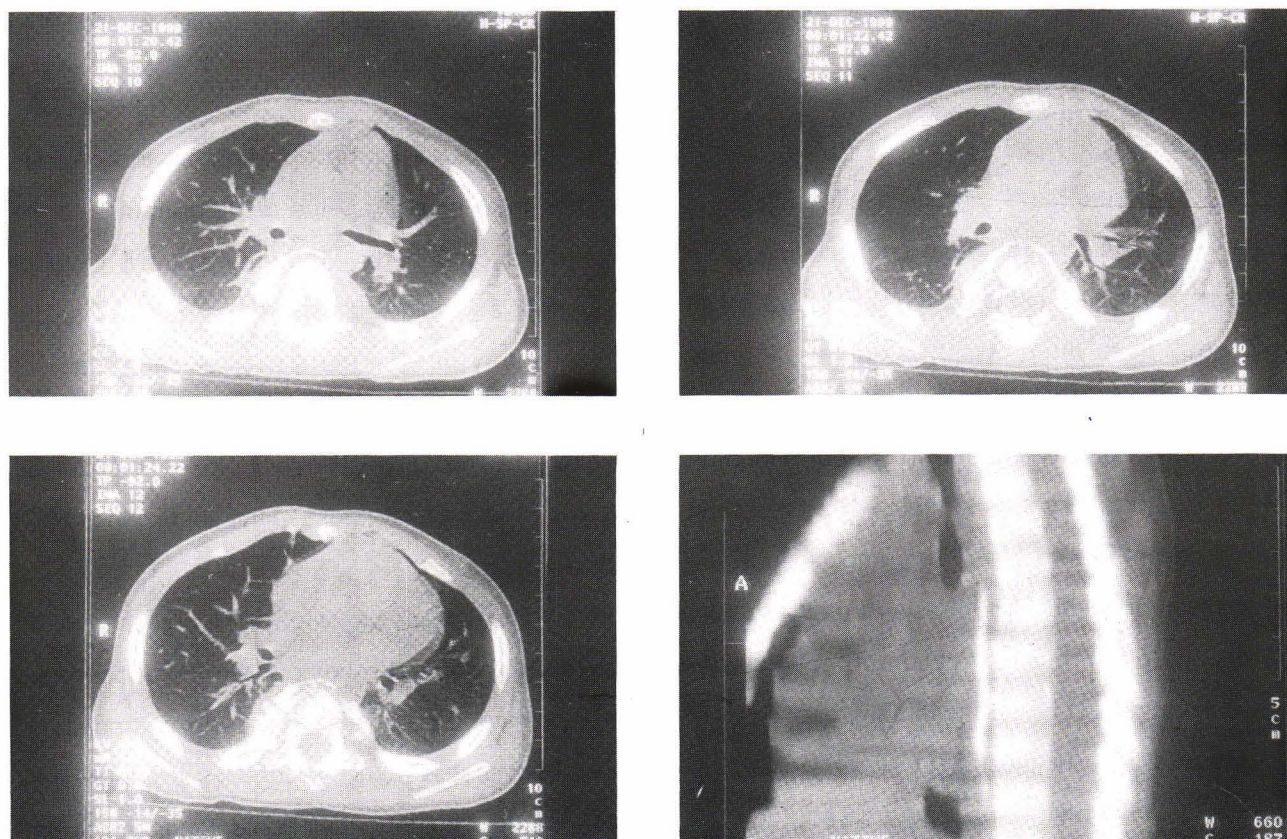


Figure 4. CT chest axial and sagittal reconstruction (bone window). A, Callus formation at right 5th rib head is noted. Linear curve-like calcification in prevertebral soft tissue is detected, more prominent on the right. B, Callus formation at bilateral 6th rib heads are seen. Linear semicircular calcification in prevertebral soft tissue is noted. C, Callus formation at bilateral 6th rib heads and right 6th rib neck are presented. Fracture T6 vertebral body and spinous process are shown. D, Long linear bone density lesion anterior to mid thoracic spines consistent with calcified prevertebral hematoma.

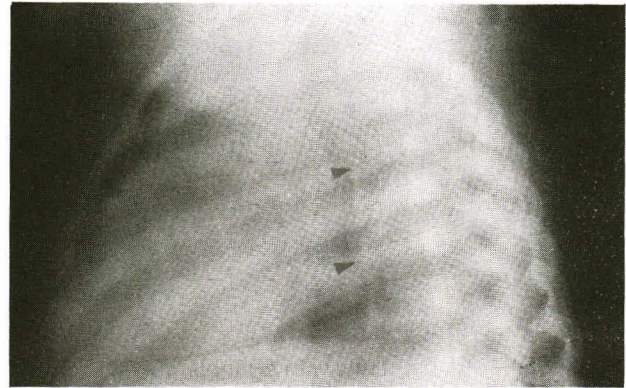
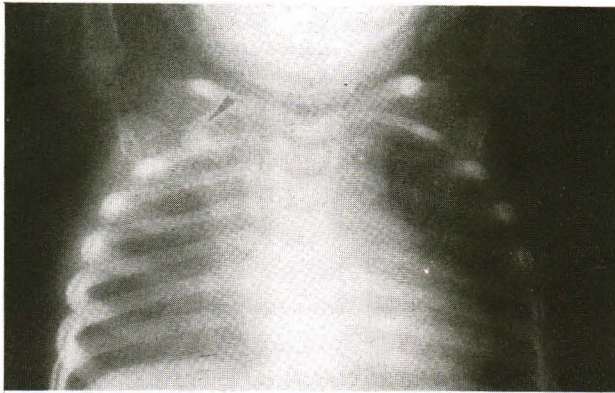


Figure 5. A, RUL opacity with no demonstrable right pleural effusion is evident. Faint callus formation with fracture line at lateral arc of right 1st rib is observed (arrow). Decreased callus at lateral arc of left 6th rib is noted. B, Long linear calcification anterior to T5 -T8 is observed, calcified prevertebral hematoma (arrows).

Discussion

Chylothorax and chylous ascites are not a primary process, but rather a manifestation of an underlying disorder. These predisposing disorders can be divided into three basic categories, trauma, obstruction and lymphatic abnormalities. The most common cause of chylothorax and chylous ascites in childhood is congenital abnormality⁽⁶⁾ and the least frequent cause is trauma.^(3,4,6-8) The various congenital defects include stenosis or atresia of the lymphatic vessels and a band or malrotation of the intestine, constricting the root of the mesentery, or a chylous cyst. Obstruction to the mesenteric lymphatic vessels by enlarged lymph nodes due to neoplasm or tuberculosis or mesenteric adenitis can result in chylous ascites or chylothorax. Surgical trauma or blunt injury to the lymphatic vessels can result in extravasation of chyle into the adjacent body cavity to produce chylothorax, chylous ascites or chylopericardium.

In our case, the chylothorax and chylous ascites were most likely the result of trauma to the thoracic duct at the level of the fractured posterior upper ribs and calcified prevertebral hematoma. The given history of falling in a shallow canal was not consistent with the back swelling, chylothorax, chylous ascites, delayed physical development and multiple stages of healing fractures, so the suspicion of child abuse was raised.

The diagnosis of chylothorax or chylous ascites is confirmed by diagnostic thoracentesis or abdominal paracentesis revealing characteristic milky fluid that is alkaline, contains predominantly lymphocytes, is higher in fat content than the serum, lower in protein than serum and clears with the addition of ether with stained with Sudan Red. After diagnosis of chylothorax and chylous ascites were confirmed and other causes eliminated, the cause was presumed to be traumatic, probably a result of beating.^(2,3,6,8)

The therapy of chylothorax and chylous

ascites is focused on three areas: 1) to improve or maintain the nutritional status of the patient. 2) to decrease the rate of the formation of chyle and 3) to correct the underlying disorder that resulted in the formation of the chylothorax and chylous ascites.⁽⁶⁾ Management has ranged from treating the underlying disorder and dietary modification to simple drainage procedures or more invasive surgical procedures.

Clinicians must be aware of discrepancies between clinical evidence of injury and absent or inappropriately explained accounts of the event. Delay in seeking medical treatment or lack of concern by the parent should raise the suspicion of child abuse. Signs of malnutrition, bruises or burns should prompt further medical evaluation for physical abuse.

Radiologists must realize that skeletal imaging is essential to identify associated osseous injuries in child abuse cases with no classic historical or physical features. In contrast to long bone shaft fractures which are often suspected clinically, rib cage fractures are usually occult. Uncommon fractures such as of the lateral end of the clavicle, ribs (usually multiple and commonly seen in posterior or lateral region), scapular, sternum and spine are felt to be highly suspicious and might even be considered as a valuable sign of child abuse.^(1,9) The strong association of rib cage fractures with abuse relate to unique anatomic factors and the typical forces applied to the thorax during violent assaults on infants and young children.


The roentgenologic detection of skeletal trauma still plays a prominent role in diagnosing cases which might otherwise pass unrecognized for considerable periods of time.

References

1. Kleinman PK: Diagnostic Imaging of Child Abuse 2nd ed., 1998.
2. Green HG. Child abuse presenting as chylothorax. *Pediatrics* 1980 Oct; 66(4): 620 - 1
3. Guleserian KJ, Glichrist BF, Luks FL, Wessethoeft CW, Deluca FG. Child abuse as a cause of traumatic chylothorax. *J Pediatr Surg* 1996 Dec; 31(12): 1696 - 7
4. Vollman RW. Post-traumatic chylous ascites in infancy. *N Engl J Med* 1966 Oct 20; 275(16): 875 - 7
5. Cochran WJ. Chylous ascites in infants and children: A case report and literature review. *J Pediatr Gas Nutr* 1984; 4(4): 668 - 73
6. Boysen BE. Chylous ascites: Manifestation of the battered child syndrome. *Am J Dis Child* 1975 Nov; 129(11): 1138 - 9
7. Stormo AC, Anatasi GW, Wertheimer HM, Rodgers AE. Traumatic chylous ascites. *Arch Surg* 1966 Jan; 92(1): 115 - 7
8. Benhaim P, Strear C, Knudson M, Neal C, Coulter K, Villarreal S. Posttraumatic chylous ascites in a child: recognition and management of an unusual condition. *J Trauma* 1995 Dec; 39(6): 1175 - 7
9. Kogut MS, Swischuk LE, Fagan CJ. Patterns of injury and significance of uncommon fractures in the battered child syndrome. *Am J Roentgenol* 1974 May; 121(1): 143 - 9
10. Silverman FN. Unrecognized trauma in infants, the battered child syndrome, and the syndrome of Ambroise Tardieu. *Radiology* 1972 Aug; 104(2): 337 - 53

11. Nimkin K, Teeger S, Wallach MT, DuVally JC, Spevak MR, Kleinman PK. Adrenal hemorrhage in abused children: Imaging and post mortem findings. Am J Roentgenol 1994 Mar; 162(3): 661 - 3
12. Wenger DR, Rokicki RR. Spinal deformity secondary to scar formation in Battered child. J Bone & Joint Surg 1978 Sep;60A(6): 847 - 9

Forensic Case Studies



เสวต กรรณล้วน พ.บ.,
วท.บ., Diplomat, American
Board of Anatomic Patho-
logy Diplomat, American
Board of Forensic Patho-
logy, USA.

กรณีศึกษาทางนิติเวชศาสตร์

ชายผิวดำ อายุ 35 ปี ผู้ประสบเหตุ พบผู้ป่วยนอนไม่รู้สึกตัวอยู่ข้างทางเดิน.
สิ่งตรวจพบจากการชันสูตรพลิกศพ

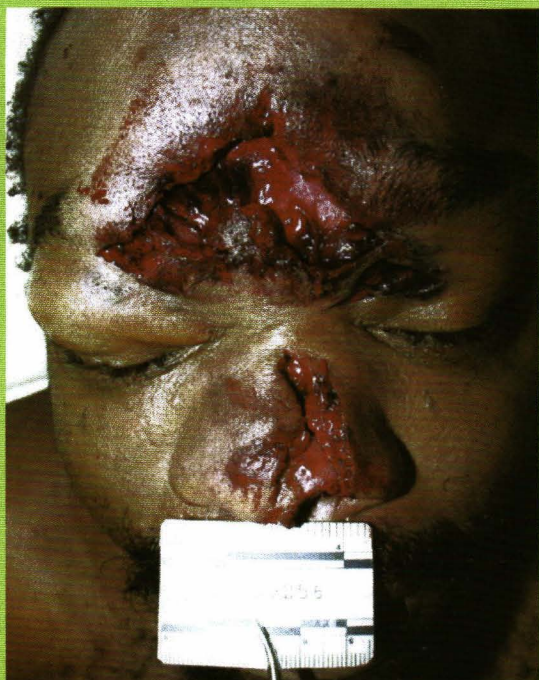1. บาดแผลผิวหนังฉีกขาดแตกเป็นหลายแฉกที่บริเวณหน้าผาก และ
ศีรษะด้านหลัง (ภาพที่ 1 และ 2) หนังศีรษะทั่วไปฟกช้ำ.
2. ผิวหนังบริเวณจมูกฉีกขาด.
3. บาดแผลผิวหนังฉีกขาดหลายบาดแผลที่บริเวณริมฝีปากบนและล่าง
และที่ frenulum ของริมฝีปากบน.
4. พบเลือดในหลอดลม และปอด (aspirated blood in trachea,
bronchi and lungs).
5. บริเวณหลังมือซ้ายบวมช้ำและมีบาดแผลผิวหนังฉีกขาดที่ด้านหลัง
ของนิ้วหัวแม่มือข้างซ้าย (ภาพที่ 3) และ
6. บาดแผลผิวหนังครูดลอกชนิด brush burn ที่ด้านหลังของสะโพกซ้าย
(ภาพที่ 4).

จงตอบคำถามต่อไปนี้

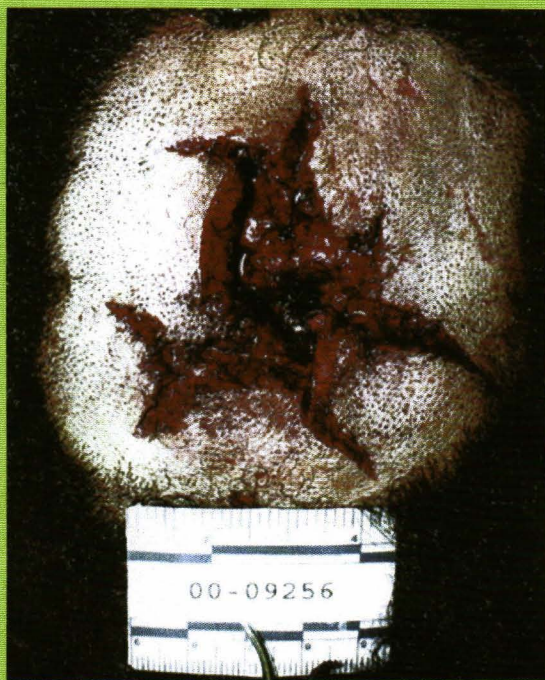1. ผู้ตายน่าจะถูกทำร้ายด้วยอาวุธใด.
2. เหตุตายคืออะไร.
3. พฤติการณ์แห่งการตายเป็นอย่างใด.
4. บาดแผลที่หลังมือซ้ายมีความสำคัญอย่างไรในทางนิติเวชศาสตร์.
5. การพบเลือดในหลอดลมและปอด อธิบายได้อย่างไร.

* 1. เฉลยในฉบับหน้า

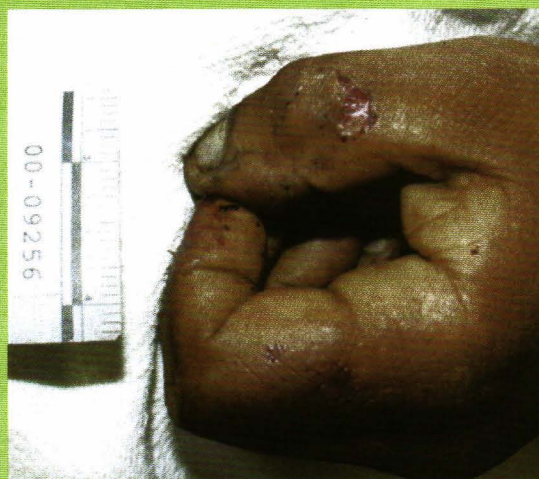2. มีแบบฟอร์มให้ตอบคำถามส่งกลับจุฬาลงกรณ์มหาวิทยาลัย
3. สื่อการศึกษาต่อเนื่องตามเกณฑ์มาตรฐานของศูนย์การศึกษาต่อเนื่องของแพทย์แพทยสภา
จำนวน 1 เครดิต



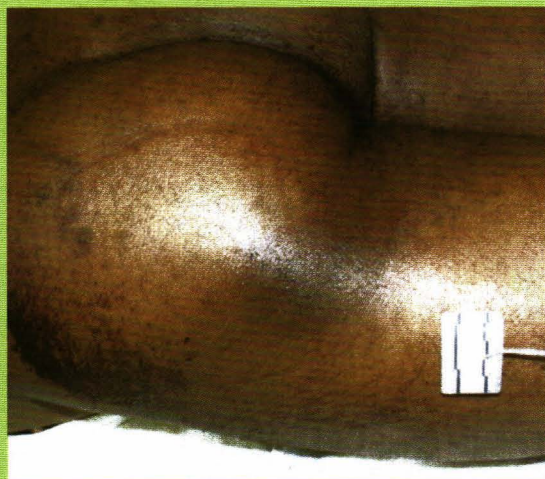
ภาพที่ 1. แผลฉีกขาดบริเวณกลางหน้าผาก.



ภาพที่ 2. แผลฉีกขาดรูปดาวแตกบริเวณด้านหลังศีรษะ.



ภาพที่ 3. แผลฉีกขาดบริเวณนิ้วหัวแม่มือซ้าย.



ภาพที่ 4. บริเวณด้านหลังสะโพกซ้าย ปากถูกจำแลงบนรอยถลอก.