

5-1-2002

Histopathological aspects of *Helicobacter pylori* infection

M. Tawevisit

T. Assanasen

Follow this and additional works at: <https://digital.car.chula.ac.th/clmjjournal>



Part of the [Medicine and Health Sciences Commons](#)

Recommended Citation

Tawevisit, M. and Assanasen, T. (2002) "Histopathological aspects of *Helicobacter pylori* infection," *Chulalongkorn Medical Journal*: Vol. 46: Iss. 5, Article 9.

Available at: <https://digital.car.chula.ac.th/clmjjournal/vol46/iss5/9>

This Review Article is brought to you for free and open access by the Chulalongkorn Journal Online (CUJO) at Chula Digital Collections. It has been accepted for inclusion in Chulalongkorn Medical Journal by an authorized editor of Chula Digital Collections. For more information, please contact ChulaDC@car.chula.ac.th.

Histopathological aspects of *Helicobacter pylori* infection

Mana Tawevisit*

Thamathron Assanasen*

Tawevisit M, Assanasen T. Histopathological aspects of *Helicobacter pylori* infection. Chula Med J 2002 May; 46(5): 427 - 36

Helicobacter pylori is an important organism of gastric infection acquired by oral route. The microbes are located along the mucous layer and often penetrate into between the surface of epithelial cells. The organism causes a number of gastric illness, namely: acute and chronic gastritis, peptic ulcer, lymphoma of mucosal associated lymphoid tissue, and gastric adenocarcinoma. Demonstrating the organism by histomorphology is essential as same as the other methods, because majority of the diseases improve when they are treated with antibiotics. We intend to demonstrate varieties of histopathological changes in gastric mucosa that was infected by *Helicobacter pylori*.

Key words : *Helicobacter pylori*, Gastritis, Peptic ulcers, MALT-lymphoma, Gastric adenocarcinoma.

Reprint request : Tawevisit M, Department of Pathology, Faculty of Medicine, Chulalongkorn University, Bangkok 10330, Thailand.

Received for publication. February 12, 2002.

Objectives :

1. To present a number of histopathologic findings that are the results of *H.pylori*.
2. To remind pathologists about the necessary in identifying *H. pylori*.

มานะ ทวีวิศิษฐ์, ธรรมธร อาศนะเสน. จุลพยาธิวิทยาของการติดเชื้อ *Helicobacter pylori*.
จุฬาลงกรณ์เวชสาร 2545 พ.ศ; 46(5): 427 - 36

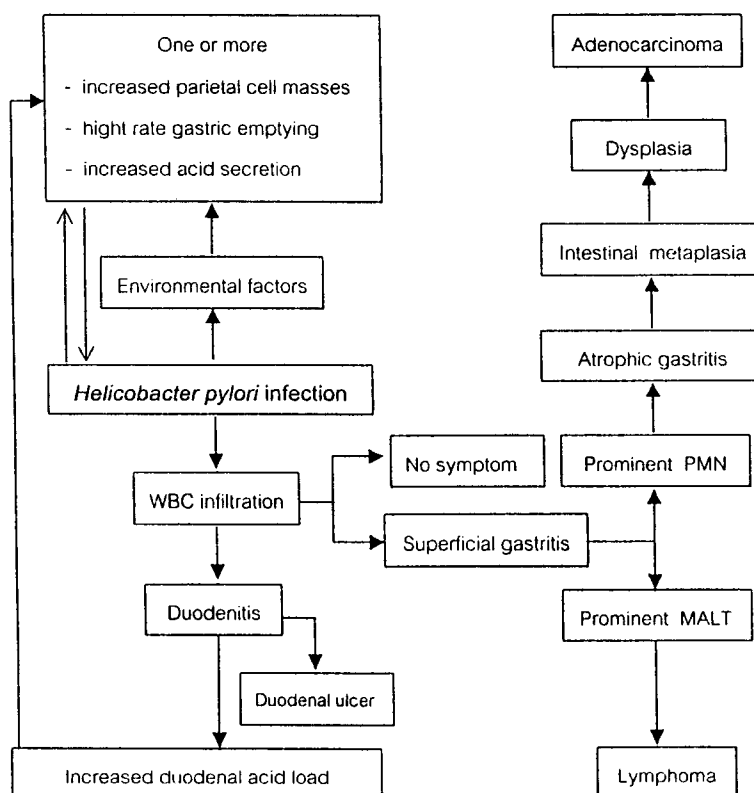
เชื้อแบคทีเรีย *Helicobacter pylori* นับว่ามีความสำคัญต่อการเกิดโรคในกระเพาะอาหาร เชื้อโรคชนิดนี้มีวงจรชีวิตผ่านไปตามระบบทางเดินอาหาร วิธีการก่อโรคเริ่มจากเชื้อในชั้นเยื่อเมือกแทรกผ่านไปยังช่องว่างระหว่างเซลล์เยื่อบุกระเพาะอาหารแล้ว ทำให้เกิดพยาธิสภาพต่าง ๆ ตามมา อันได้แก่ กระเพาะอาหารอักเสบทั้งแบบเฉียบพลันและเรื้อรัง แผลในกระเพาะอาหาร มะเร็งกระเพาะอาหาร และมะเร็งของระบบน้ำเหลืองภายนอกต่อมน้ำเหลือง ปัจจุบันมีหลักฐานยืนยันแน่ชัดและมากมายว่า การรักษาด้วยยาฆ่าเชื้อโรคสามารถรักษาและควบคุมโรคต่าง ๆ ที่ถือถือกำเนิดจากเชื้อแบคทีเรียชนิดนี้ได้เป็นส่วนใหญ่ ด้วยเหตุนี้เอง การแสดงให้เห็นว่าพยาธิสภาพที่หลากหลายดังกล่าวเกิดร่วมกับ การติดเชื้อชนิดนี้ ย่อมมีผลต่อการเปลี่ยนแปลงการรักษาเช่นกัน บทความนี้มีวัตถุประสงค์ที่จะแสดง จุลพยาธิสภาพต่าง ๆ ที่เกิดขึ้นในเยื่อบุกระเพาะอาหารซึ่งติดเชื้อแบคทีเรียนี้

คำสำคัญ : *Helicobacter pylori*, กระเพาะอาหารอักเสบ, แผลในกระเพาะอาหาร, มะเร็งของระบบ
น้ำเหลืองภายนอกต่อมน้ำเหลือง, มะเร็งกระเพาะอาหาร

Helicobacter pylori (*H. pylori*) infection is one of the World's most common chronic infectious disease in humans.⁽¹⁾ The bacteria is a nonsporing, flagellated curvilinear gram-negative bacilli, measured approximately 3.5 x 0.5 microns.^(2,3) They can be found singly or in clusters along the gastric mucosal surface and foveolar epithelium and may appear to be entrapped within mucous strands, freely floating in the foveolar spaces, or adherent to the columnar cells.⁽⁴⁾

In most cases, *H. pylori* can be identified using a standard haematoxylin and eosin method.^(3,5) However, the sensitivity is low when there are small amount of the organisms. Giemsa technique is inexpensive, but the major disadvantage is the lack of contrast between the organism and surrounding tissue. The *H. pylori* silver stain (HpSS) method gives

a good result because the organisms are coated with the silver and appear larger, making their recognition easier. Nevertheless, immunohistochemistry is the gold standard for histological diagnosis with high sensitivity and specificity. The technical time is about one hour but the method is fairly expensive.⁽⁵⁾ However, the others methods include serology, culture, rapid urease test, and C-urea breath test. With the use of immunocytochemical and polymerase chain reaction (PCR) techniques, *H. pylori* has been found to be associated with 90 % of chronic gastritis, 70 % of gastric ulcer, 95 % of duodenal ulcer, and 50 % of gastric carcinoma.⁽⁶⁾ The objective of this communication is to review the various gastric pathology, associated with *H. pylori* infection.



A diagram displaying pathogenesis of *Helicobacter pylori* infection

Acute gastritis

Normally, the infection is acquired through oral route; after ingested, the bacteria penetrate through the viscid mucous layer of stomach and later multiply in close proximity to the apical membrane of the surface lining epithelial cells. A proportion of the organisms become redundant to the plasma membrane, whereas others penetrate into potential gap between the epithelial cells.^(4,7)

Endoscopy demonstrates either erythrematous and white patches. The erythrematous patch is characterized by histologically preserved mucosal architecture. There is extensive neutrophilic infiltration within the edematous and congested lamina propria and surface epithelium.

The white patch consists of aggregates of necrotic debris, fibrin, and neutrophils attached to eroded gastric epithelium. The *H. pylori* organism is absent in the lesions and immediately adjacent gastric mucosa. In some cases; the findings resemble to erupting lesions as pseudomembranous colitis.⁽⁸⁾ The epithelial responses to infection consist of marked degenerative changes, mucin depletion, cellular exfoliation, and syncytial regenerative changes.^(7,8) Therefore there are qualitative alterations in carbohydrate composition of mucus and hydrophobicity resulting in compromise the barrier function.⁽⁸⁾

The mediators for the epithelial and inflammatory cell responses are from bacteria and host sources involving in both apoptosis and cellular proliferation.^(1,7) Secretion of the vacuolating cytotoxin may be an important cause of damage to the surface epithelium and other mechanisms such as production of ammonia and ammonia products like monochloramine, endotoxin release, and disturbances of

the protective mucous layer may share their parts. With regard to the latter, there is also formation of platelet-leukocyte aggregates within the postcapillary venules, 150-kd neutrophil-activating protein accompanied by mast cell degranulation.⁽⁸⁾ Direct exposure of the epithelium results in the synthesis and release of several chemokines, including IL-8 and growth related oncogene alpha.^(8,9)

The acute phase is relatively short lived. A minority of patients may experience spontaneous recovery with the resolution of the polymorph, and their clinical appearances quickly return to normal. However, in most cases, the initial non-specific immune response fails to eliminate the infection, and over the next 3 or 4 weeks there is a gradual accumulation of chronic inflammatory cells recognized as in a specific immune response. The diagnosis of acute neutrophilic gastritis gives way to that of an active chronic gastritis.^(4,8,10)

Chronic gastritis

Chronic *H. pylori* infection includes has a wide spectrum of histopathologic changes. The changes usually occur in antrum and corpus. The architecture of the mucosa is well preserved, with minor disarranged pits, caused by lymphoplasmacytic infiltration that occupies lamina propria.⁽³⁾ The antral mucous glands are separated by expanded lamina propria. Small aggregates of neutrophils, usually without fibrin, can often be seen on the surface epithelium and within the pits, called 'pit abscesses'. Intraepithelial neutrophils may be so rare that they are difficult to find, even when many organisms are present. Distinct destruction of heavily infiltrated and dilated pits may be seen, giving atrophy. Eosinophils may be prominent in some cases.^(4,7,8)

The lymphoid aggregation with germinal center (LAGC) may still be the most conspicuous response to *H. pylori* in the gastric antrum. LAGCs are being increasingly recognized as typical, but not pathognomonic, of *H. pylori* infection.⁽⁶⁾ Usually but not always, the overall inflammation is less intense in the corpus than in the antrum. In addition to the gastric corpus, *H. pylori*-infected stomachs may entirely have no inflammatory responses. However, frequently LAGCs are found in the corporal mucosa, where there is no evidence of infection. Scattered eosinophils are also seen between the glandular spaces, but bacteria are always absent from the location.^{(4),(7)} The cellular alterations are composed of flattening of the surface, hyperplastic-looking cellular tufts, and subtle changes resulting of direct consequence of the presence of adhering organisms. Furthermore, lymphocytes infiltrate into the epithelium and may damage their structures, in a manner considered typical of MALT-lymphoma. In these cases, a careful search for *H. pylori* bacteria is necessary. Therefore, a close follow-up of suspected cases with extensive biopsy sampling after attempting the eradicate the organisms is mandatory.⁽⁸⁾

Epithelial metaplasia is the another interesting feature of chronic gastritis for both the pyloric and the intestinal types. In pyloric metaplasia, the fundic-type glands are gradually replaced by mucous-secreting glands.^(2,6) In intestinal metaplasia, however, the glands are progressively replaced by epithelium, having the features of intestinal epithelium of either small or large bowel including goblet cells, absorptive cells, Paneth's cells, ciliated cells, and a variety of endocrine cells. The latter is also divided into three types namely: complete (type I), and incomplete (type II and III),

metaplasia.^(4,6,7) Several investigators describe differences patterns of intestinal metaplasia. Some authors apply histochemical method to study the digestive enzymes in the specimens. The complete metaplasia type, it presents the complete set of small intestinal digestive enzymes. Nevertheless, digestive enzymes within the metaplastic glands of the latter pattern are completely absent or very scarce, like that of a normal large intestine.^(4,7,8) Base on mucin morphology and histochemistry using the staining techniques of alcian blue/periodic acid-Schiff and high-iron diamine/alcine blue, the patterns are divided into type I to III.^(4,6) Type I: Straight crypts are lined by mature columnar (absorptive enterocytes) and goblet cells which secrete sialomucin. Columnar cells do not secrete mucin, and have a well-formed brush border. Paneth's cells are often present. Type II: The crypts are elongated and tortuous. Crypts are lined by columnar cells in various stages of differentiation, secreting neutral mucins or small amounts of sialomucin. The goblet cells secrete sialomucin and occasionally sulfomucin. Paneth cells are rarely observed. Type III: Distortion of crypt architecture is more documented, and loss of differentiation (cellular atypia) are more marked than in type II. Columnar cells secrete predominantly sulfomucins and goblet cells contain sialomucins Paneth cells are usually absent. Many studies in Japan, Europe, and Slovenia showed that early gastric carcinomas are frequently seen in the vicinity of foci of incomplete or colonic metaplasia.⁽¹¹⁾ When mucin studies are applied, type III (sulfomucin positive) metaplasia has a risk for development of carcinoma four times greater than type I (sulfomucin negative) metaplasia.^(4,6,7) In addition to the three well defined variants of intestinal metaplasia,

their intermediate forms are also identified as I/II, II/III, and, rarely, I/III.⁽⁴⁾

The inflammatory cells may eventually become exclusively mononuclear and may slowly vanish over a number of years, at the same time the gastric glands decrease in number. The surface and the foveolar epithelium undergo intestinal metaplasia together with increased mitoses.⁽⁴⁾ The glandular atrophy is categorized as mild, moderate, or severe, by a rough estimation, the thickness of the glandular portion is related to the thickness of the whole mucosa.⁽⁶⁾ The sequence of the changes illustrate a hypothetical pathway from *H.pylori*-associated chronic active gastritis to atrophic gastritis, to gastric metaplasia, and to atrophy.^(8,12)

A successful eradication of *H. pylori* leads to an improvement of gastritis and rapid disappearance of neutrophils from the gastric mucosa, which can be seen as early as 2 or 3 days after the beginning of the triple therapy.^(4,13)

Peptic ulcers

At least 98 % of peptic ulcers locate in the duodenal bulb or in the stomach, in a ratio of about 4:1. In patients with duodenal ulcer will be due to *H. pylori* infection in 95% of cases.⁽²⁾ Therefore, the ulcers heal quickly and completely after the eradication of *H. pylori*, and it markedly decreases the incidence of relapse accompanied with significantly relieve dyspeptic symptom.^(13,14,16) Generally, duodenal ulcers are a few centimeters in sizes. The anterior wall of the duodenum is more often affected than the posterior wall. Gastric ulcers, the second most common site, predominantly locate along the lesser curvature, in or around the border zone between the corpus and the

greater curvature.⁽¹⁷⁾ About eight weeks after the eradication of *H.pylori*, endoscopy often confirms the healing of a gastric ulcer. Although the majority of individuals have a single ulcer, in 10 – 20 % of patients with gastric ulceration there may be a coexistent duodenal ulcer. Its size does not differentiate a benign from a malignant ulcer.^(2,18)

The classic peptic ulcer is a round-to-oval, sharply punched-out defect with relatively straight walls. Its mucosal margin may slightly overhang the base, particularly on the upstream portion of its circumference. Heaping-up of the margins is rare in a benign ulcer, but it is a characteristic of a malignant lesion.^(2,15) The depth of the ulcers varies from superficial lesions involving only the mucosa and muscularis mucosae, to deeply excavated lesions down to muscularis propria.^(18,19)

The base of a peptic ulcer is usually smooth and clean. At times, thrombosed or even patent blood vessels (the source of life-threatening hemorrhage) are evident at the base of the ulcer.⁽¹¹⁾ Scarring may involve the entire thickness of the stomach; puckering up the surrounding mucosa and creating mucosal folds, which radiates from the crater in a spoke-like fashion. The gastric mucosa surrounding a gastric ulcer may be edema and red, owing to an almost invariable gastritis.^(11,17)

The histological appearance varies from active necrosis, to chronic inflammation, scarring, and healing.⁽¹⁹⁾ The four zones are demonstrable: (1) The base and margins have a superficial thin layer of necrotic debris, which is not visible to naked eyes; (2) beneath the layer is a zone of nonspecific acute inflammation; (3) the deeper layer, especially under the base of the ulcer, is active granulation tissue

infiltrated with mononuclear leukocytes; and (4) the granulation tissue rests on a more solid fibrous or collagenous scar. Vessel walls within the scarred area are typically thickened occasionally thrombosed.^(11,18,19) Evidence of *H. pylori* infection is therefore almost always demonstrable. The feature is helpful to distinguish peptic ulcers from acute erosive gastritis; the adjacent mucosa is normal in the latter condition.^(2,15)

Lymphoma of mucosal associated lymphoid tissue

Although comprising less than 5 % of all gastric cancers, gastric lymphomas are the most frequent, with the overall rates of disease about two per 100,000 per year in people between 60 - 79 years of age.⁽²⁰⁻²²⁾ Normally stomach has no lymphoid tissue. The presence of lymphoid follicles in gastric mucosa is virtually pathognomonic of *H. pylori* infection; the growth and development of lymphoid tissue associated with gastric mucosa (MALT)-lymphoma is subject to immunological stimuli related to the organism.^(4,23)

Four independent evidences link prior *H. pylori* infection with MALT-lymphoma. These include: (1) the bacteria are found in over 90 % of gastric MALT-lymphoma; (2) a high incidence of gastric MALT-lymphoma in North-East Italy, found associated with a high seroprevalence of *H. pylori*; (3) case-control data shows a positive linkage between an early *H. pylori* infection with the development of primary gastric lymphoma; and (4) studies show that treatment of the *H. pylori* infection leads to resolution of low-grade MALT-lymphoma, with approximately 70 % of the cases in stage IE of gastric MALT-lymphoma regressed after successful treatments.^(20,22,24)

Generally, gastric lymphoma are classified into low-grade and high-grade varieties.⁽²⁵⁾ The low-

grade MALT lymphoma are designated as marginal-zone B-cell lymphoma of extranodal type in the Revised European-American lymphoma (REAL) and recently published World Health Organization (WHO) classifications.^(26,27) Endoscopic findings show exophytic or infiltrative growth.^(20,22) Typical histological appearances are glandular destruction by a dense sheet of small-to-medium sized lymphoid follicles, named lympho-epithelial lesions with scattered lymphoid follicles. Dutcher bodies are often pronounced within neoplastic cells.^(4,25) Conversely glandular structure in *H. pylori* gastritis are occasionally pushed apart by follicles but rarely widely destroyed. The lympho-epithelial lesions are distinguishable from lymphocytic gastritis by the regular appearance of the lympho-epithelial lesions in the latter, and the site of the lymphoepithelial lesions (in the lymphocytic gastritis occupy the surface and foveolar epithelium as oppose to the glandular layer). In addition to the neoplastic cells, called 'centrocyte-like (CCL) cells', are B-cells whereas lymphocytic gastritis are T-cells.^(11,18) Furthermore monocytoid B-cells and plasma cells are present in MALT-lymphoma. The neoplastic follicles in MALT has to be distinguished from a true follicular, centrocytic/centroblastic lymphoma. The immunostaining for follicle centre cells display positive reaction with the antibody CD 75 in paraffin sections and CD 10 in frozen material, and a negative result with the antibody CDw32.^(4,28)

In high-grade lymphomas; most they are assumed to have arisen from an initial low-grade features, which can be found in only one-third of cases. It is interesting that 88% of lymphomas in the seroepidemiological studies, which linked them with a previous *H. pylori* infection, were of the high-grade

type. In the REAL and WHO classifications, they are designated as diffuse large B-cell lymphoma.⁽²⁵⁾ They grossly exhibit ulcerated masses or infiltrative lesion giving giant folds and rigidity.^(4,21) Typical features in high-grade lymphomas are B-cells infiltration of lamina propria with preservation of gastric gland. Pure high-grade type can present diagnostic confusion with undifferentiated carcinoma in routinely sections.⁽⁴⁾

Gastric adenocarcinoma

Worldwide rates of gastric cancer increase with age, and it rises sharply after the age of 65 to over 250 per 100,000, male are more frequent affected than female. It has been hypothesized that an early age of contracting *H. pylori* may be a plausible etiological factor associated with the occurrence of gastric carcinoma.^(4,30) Additionally, chronic gastritis is the most frequent pathological condition that predisposes gastric carcinoma.⁽³⁰⁾

Intragastric synthesis of carcinogens is postulated as a factor in gastric carcinogenesis as well as bacterial toxin. An alternative mechanism is the formation and release of nitric oxide and other free oxygen radicals by inflammatory cells attracted to the gastric mucosa by *H. pylori* infection. The free radicals are capable of inducing damage to deoxyribonucleic acid (DNA) molecules by deamination, alkylation, oxidation, and induction of strand breaks.⁽³¹⁾

The commonest location of the gastric carcinomas is the lesser curvature of the antropyloric region. The three macroscopic growth patterns enclose of exophytic, flat or depressed (linitis plastica), and excavated lesions.⁽²⁾

Gastric carcinoma can be generally divided

into two histological subtypes: (1) those exhibiting an intestinal morphology with the formation of bulky tumors composed of glandular structures and (2) those that are diffused in the infiltrative growth of poorly differentiated discohesive malignant cells.⁽²⁹⁾ The intestinal type shows tall columnar cells, often with a prominent brush border and scattered mucin-secreting goblet cells. However, abundant intracellular mucin is not a feature of this type. Generally, the adjacent chronic gastritis with widespread intestinal metaplasia. The diffused type, by contrast, mainly consists of scattered individual cells or clusters of cells. Glandular differentiation is uncommon, although it may occur in the more superficial part of the tumor. The neoplastic cells reveal signet-ring morphology recognized as small uniform and poorly cohesive pattern.^(6,32)

Conclusion

There are many evidences suggesting that *H. pylori* plays an important role in various gastric diseases, especially cancer. Moreover, killing the organism by some antibiotic regimens can also dramatically resolve the problems, even in low-grade MALT-lymphoma. Histological demonstration of *H. pylori*, hence, is important as well as the other methods including serology, culture, rapid urease test, and C-urea breath test. Pathologists, therefore, must be reminded how important to detect *H. pylori* is when ones diagnose diseases of the stomach. There are several methods to detect the organisms. Although haematoxylin and eosin stain is valuable, but Giemsa technique gives the pathologists easier.

References

1. Jones RG, Trowbridge DB, Go MF. Helicobacter

- pylori infection in peptic ulcer disease and gastric malignancy. *Front Biosci* 2001 Dec 1; 6: E213 - 26
2. Crawford JM. The Gastrointestinal tract. In : Ramzi SC, Vinay K, Stanley LR. Robbins Pathologic Basis of Disease. 6th ed. Philadelphia: W.B. Saunders 1999: 789 - 802
 3. Rotimi O, Cairns A, Gray S, Moayyedi P, Dixon MF. Histological identification of *Helicobacter pylori*: comparison of staining methods. *J Clin Pathol* 2000 Oct; 53(10): 756 - 9
 4. Day DW, Dixon MF. Biopsy Pathology of the Oesophagus, Stomach and Duodenum. 2nd ed. London: Chapman & Hall Medical, 1995: 95 - 240
 5. Lacy BE, Rosemore J. *Helicobacter pylori*: ulcer and more: the benigning fo and era. *J Nutr* 2001 Oct; 131(10): 2789s - 2793s
 6. Rosai J. Ackerman's Surgical Pathology. 8th ed. St. Louis: Mosby, 1996: 617 - 20
 7. Dixon MF. Acute *Helicobacter pylori* Gastritis. In: Graham DY, Genta RM, Dixon MF. Gastritis. 5th ed. Philadelphia: Lippincott Williams & Wilkins 1999: 170 - 3
 8. Goodgame RW, Genta RM, Go MF, Graham DY. Infectious Gastritis In: Surawicz C, Owen RL, eds. Gastrointestinal and Hepatic Infections. Philadelphia : Saunders, 1995: 47 - 67
 9. Liu Z, Ji B, Chen B. Effect of antral gastritis and cytokines on *Helicobacter pylori* associated duodenal ulcer. *Zhonghua Yi Xue Za Zhi* 1999 Sep; 79(9): 686 - 8
 10. Naumann M. Host cell signaling in *Helicobacter pylori* infection. *Int J Med Microbiol* 2001 Sep; 291(4): 299 - 305
 11. Morson BC, Dawson IMP, Day DW, Tass JR, Price AB, Williams GJ. Morson & Dowson's Gastrointestinal Pathology. 3rd ed. London: Blackwell scientific publications, 1990: 94 - 133
 12. Chi J, Lu M, Fu B, Nakajima S, Hattori T. Induction of gastritis and gastric ulcer in Mongolian gerbils infected with *Helicobacter pylori*. *Chin Med J (Engl)* 1999 Nov; 112(11): 998 - 1000
 13. Hunt RH, Sumanac K, Huang JQ. Review article: should we kill or should we save *Helicobacter pylori*? *Aliment Pharmacol Ther* 2001 Jun; 15(Suppl.1), 51 - 9
 14. Harris A, Misiewicz JJ. ABC of the upper gastrointestinal tract. Management of *Helicobacter pylori* infection. *BMJ* 2001 Nov 3; 323 (7320): 1047 - 50
 15. Lechago J, Genta RM. Stomach and Duodenum In: Danyanov I, Linder T, eds. Anderson's Pathology. 10th ed. It Louis Missouri: Mosby - Year book, Inc. 1996: 1680 - 1
 16. Wouden EJ, Thijs JC, Zwet AA, Kleibeuker JH. Six-year follow - up after successful triple therapy for *Helicobacter pylori* infection in patients with peptic ulcer disease. *Eur J Gastroenterol Hepatol* 2001 Oct; 13(10): 1235 - 9
 17. Greenberger NJ. Complication of stomach and duodenum. In: Greenberger NJ. Gastrointestinal disorders A Pathophysiologic approach. 4th ed. Chicago: Year book medical Publisher, 1989: 50 - 120
 18. Owen DA, T.K. Kelly TK. Atlas of Gastrointestinal Pathology. Philadelphia : Saunders 1994: 40 - 1
 19. Mitros FA. Atlas of Gastrointestinal Pathology. 1st ed. Philadelphia: Lippincott, 1988: 3.1-4.10

20. Feldman RA. Review article: would eradication of *Helicobacter pylori* infection reduce the risk of gastric cancer? *Aliment Pharmacol Ther* 2001 Jun; 15 (Suppl), 2 - 5
21. An SK, Han JK, Kim YH, Kim AY, Choi BI, Kim YA, Kim CW, Gastric Mucosa - associated lymphoid tissue lymphoma: spectrum of findings at double-contrast gastrointestinal examination with pathological correlation. *Radiographics* 2001 Nov-Dec; 21(6);1491 - 502
22. Alpen B, Thiede C, Wundisch T, Bayerdorffer E, Stolte M, Neubauer A. Molecular diagnostics in low-grade gastric marginal zone B-cell lymphoma of mucosa-associated lymphoid tissue type after *Helicobacter pylori* eradication therapy. *Clin Lymphoma* 2001 Sep; 2(2): 103 - 8
23. Barth TF, Bentz M, Dohner H, Moller P. Molecular aspects of B-cell lymphomas of the gastrointestinal tract. *Clin Lymphoma* 2001 Jun; 2(1): 57 - 64
24. Ferris Tortajada J, Garcia Castell J, Berbel Tornero O, Clar Gimeno S. Risk factor for non-Hodgkin's lymphomas. *An Esp Pediatr* 2001 Sep; 55(3): 230 - 8
25. Vega F, Medeiros LT. Marginal-Zone B-cell lymphoma of extra-nodal mucosa-associated lymphoid tissue type. molecular genetics provides new insights into pathogenesis. *Adv Anat Pathol* 2001 Nov; 8(6): 313 - 26
26. Harris NL, Jaffe ES, Stein H, Banks PM, Chan JK, Cleary ML, Delsol G, De Wolf-Peeters C, Falini B, Gatter KC. A revised European-American classification of lymphoid neoplasms : a proposal from the international Lymphoma Study Group. *Blood* 1994 Sep 1; 84(5): 1361 - 92
27. Isaacson PC, Berger F, Muller-Hermelink HK, et al. Extranodal marginal zone B-cell lymphoma of mucosa-associated lymphoid tissue(MALT lymphoma). In: Jaffe ES, Harris NL, Stein H, Vardiman JW eds. *Tumors of Haematopoietic and Lymphoid Tissues*. World Health Organization Classification of Tumors. Lyon, France: IARC Press; 2001: 1153 - 64
28. Leukocyte Typing Antibodies and the CD Nomenclature. In: *An Atlas and Textbook of Malignant Lymphomas Cytology, Histopathology & Immunocytochemistry*. Heerde PV, Meijer CJLM, Noorduyt LA, Van Der Valk P. London : Harvey Miller Publishers Manson Publishing 1996: 270 - 83
29. Emory TS, Carpenter HA, Gostout CJ, Sobin LH. *Atlas of Gastrointestinal Endoscopy & Endoscopic biopsies*. Washington, 2000: 153 - 69
30. Dominguez S, Adenis A. Cancer of the stomach. Gastric carcinoma. *Bull cancer* 2001 Nov; 88 (11): 1105 - 18
31. Correa P, Filipe ML, Torrado J. Gastritis and Gastric Neoplasia. In: *Gastritis*. Graham DY, Genta RM, Dixon MF, eds. Philadelphia: Lippincott Williams & Wilkins, 1999: 214
32. Fletcher CDM. *Diagnostic Histopathology of Tumors*. New York: Churchill Livingstone 1995: 211 - 4

กิจกรรมการศึกษาต่อเนื่องสำหรับแพทย์

ท่านสามารถได้รับการรับรองอย่างเป็นทางการสำหรับกิจกรรมการศึกษาต่อเนื่องสำหรับแพทย์ กลุ่มที่ 3 ประเภทที่ 23 (ศึกษาด้วยตนเอง) โดยศูนย์การศึกษาต่อเนื่องของแพทย์ จุฬาลงกรณ์มหาวิทยาลัย ตามเกณฑ์ของศูนย์การศึกษาต่อเนื่องของแพทย์แห่งแพทยสภา (ศนพ.) จากการอ่านบทความเรื่อง "จุลพยาธิวิทยาของการติดเชื้อ *Helicobacter pylori*" โดยตอบคำถามข้างล่างนี้ พร้อมกับส่งคำตอบที่ท่าน คิดว่าถูกต้องโดยใช้แบบฟอร์มคำตอบท้ายคำถาม แล้วใส่ซองพร้อมซองเปล่า (ไม่ต้องติดแสตมป์) จ่าหน้า ของถึงตัวท่าน ส่งถึง

ศ. นพ. สุทธิพร จิตต์มิตรภาพ

บรรณาธิการจุฬาลงกรณ์เวชสาร

และประธานคณะกรรมการการศึกษาต่อเนื่อง

คณะแพทยศาสตร์ จุฬาลงกรณ์มหาวิทยาลัย

หน่วยจุฬาลงกรณ์เวชสาร

ตึกอบรบวิชาการ ชั้นล่าง

เขตปทุมวัน กทม. 10330

จุฬาลงกรณ์เวชสารขอสงวนสิทธิ์ที่จะส่งเฉลยคำตอบพร้อมหนังสือรับรองกิจกรรมการศึกษา ต่อเนื่องอย่างเป็นทางการ ดังกล่าวแล้วข้างต้นสำหรับท่านที่เป็นสมาชิกจุฬาลงกรณ์เวชสารเท่านั้น สำหรับ ท่านที่ยังไม่เป็นสมาชิกแต่ถ้าท่านสมัครเข้าเป็นสมาชิกจุฬาลงกรณ์เวชสารสำหรับวารสารปี 2545 (เพียง 200 บาทต่อปี) ทางจุฬาลงกรณ์เวชสารยินดีดำเนินการส่งเฉลยคำตอบจากการอ่านบทความให้ตั้งแต่ฉบับ เดือนมกราคม 2545 จนถึงฉบับเดือนธันวาคม 2545 โดยสามารถส่งคำตอบได้ไม่เกินเดือนมีนาคม 2546 และจะส่งหนังสือรับรองชนิดสรุปเป็นรายปีว่าท่านสมาชิกได้เข้าร่วมกิจกรรมการศึกษาต่อเนื่องที่จัดโดย จุฬาลงกรณ์เวชสาร จำนวนกี่เครดิตในปีที่ผ่านมา โดยจะส่งให้ในเดือนเมษายน 2546

คำถาม - คำตอบ

1. Which one of the following is not the pathology resulting from *H.pylori* ?

- A. Acute and chronic gastritis
- B. Gastric and duodenal ulcers
- C. Gastric polyps
- D. Gastric adenocarcinoma
- E. MALT-lymphoma

คำตอบ สำหรับบทความเรื่อง "จุลพยาธิวิทยาของการติดเชื้อ *Helicobacter pylori*"

จุฬาลงกรณ์เวชสาร ปีที่ 46 ฉบับที่ 5 เดือนพฤษภาคม พ.ศ. 2545

รหัสสื่อการศึกษาต่อเนื่อง 3-15-201-2000/0205-(1011)

ชื่อ - นามสกุลผู้ขอ CME credit เลขที่ใบประกอบวิชาชีพเวชกรรม.....

ที่อยู่.....

1. (A) (B) (C) (D) (E)

4. (A) (B) (C) (D) (E)

2. (A) (B) (C) (D) (E)

5. (A) (B) (C) (D) (E)

3. (A) (B) (C) (D) (E)

2. What is the gold standard by histopathological examination to identify *H. pylori*?
- A. Immunohistochemistry
 - B. *H. pylori* silver stain (HpSS)
 - C. Giemsa technique
 - D. Gram stain
 - E. Haematoxylin and eosin method
3. Which of the following is false, about the type III epithelial metaplasia in chronic gastritis ?
- A. It has highest risk for subsequent gastric adenocarcinoma
 - B. Positive sulfomucin when using the special technique
 - C. Atypia is more pronounced
 - D. Straight crypts, lined by columnar and goblet cells
 - E. Paneth's cell are rarely seen
4. Which of the following statements is true ?
- A. The classic peptic ulcer is a round-to-oval, sharply punch-out defect.
 - B. The size does not differentiate a benign from a malignant gastric cancer
 - C. The common location of CA stomach is the antropyloric region
 - D. There are three major gross findings of gastric carcinoma composed of exophytic, linitis plastica, and excavated lesions
 - E. All of above
5. According to MALT-lymphoma, what is false ?
- A. Low-grade MALT-lymphoma is the marginal zone B-cell lymphoma in REAL and WHO classifications
 - B. The neoplastic cells are mainly T-cells
 - C. The gross appearances are non specific to diagnosis
 - D. Undifferentiated carcinoma usually can present diagnostic confusion with lymphomas in routinely section
 - E. Non of the above

**ท่านที่ประสงค์จะได้รับเครดิตการศึกษาต่อเนื่อง (CME credit)
กรุณาส่งคำตอบพร้อมรายละเอียดของท่านตามแบบฟอร์มด้านหน้า**

ศาสตราจารย์นายแพทย์สุทธิพร จิตต์มิตรภาพ
ประธานคณะกรรมการการศึกษาต่อเนื่อง
คณะแพทยศาสตร์ จุฬาลงกรณ์มหาวิทยาลัย
หน่วยจุฬาลงกรณ์เวชสาร ตึกอบรมวิชาการ ชั้นล่าง
คณะแพทยศาสตร์ จุฬาลงกรณ์มหาวิทยาลัย
เขตปทุมวัน กทม. 10330