

5-1-2002

## Intracranial germinoma with multiple lesions in unusual sites: A case report

N. Chirakalwasan

S. Phudhichareonrat

Follow this and additional works at: <https://digital.car.chula.ac.th/clmjournal>



Part of the [Medicine and Health Sciences Commons](#)

---

### Recommended Citation

Chirakalwasan, N. and Phudhichareonrat, S. (2002) "Intracranial germinoma with multiple lesions in unusual sites: A case report," *Chulalongkorn Medical Journal*: Vol. 46: Iss. 5, Article 8.

DOI: 10.58837/CHULA.CMJ.46.5.8

Available at: <https://digital.car.chula.ac.th/clmjournal/vol46/iss5/8>

This Case Report is brought to you for free and open access by the Chulalongkorn Journal Online (CUJO) at Chula Digital Collections. It has been accepted for inclusion in Chulalongkorn Medical Journal by an authorized editor of Chula Digital Collections. For more information, please contact [ChulaDC@car.chula.ac.th](mailto:ChulaDC@car.chula.ac.th).

## Intracranial germinoma with multiple lesions in unusual sites: A case report

Narida Chirakalwasan\*

Suchart Phudhichareonrat\*\*

**Chirakalwasan N, Phudhichareonrat S. Intracranial germinoma with multiple lesions in unusual sites: A case report. Chula Med J 2002 May; 46(5): 419 - 25**

*Germinoma is the commonest subtype of primary intracranial germ cell tumors. The pineal and suprasellar regions are by far the most favorable sites, followed by the basal ganglion and thalamus; other locations have been sparsely reported. Intracranial germinomas can simultaneously be found at multiple sites, but in such cases, there is generally still an involvement of the suprasellar or pineal area. We report, herein, an unusual case of intracranial germinoma presented with multiple lesions involving the centrum semiovale, corpus callosum, periventricular areas, midbrain, internal capsule and brain stem, with no tumor observed in the suprasellar or pineal region. The patient is a 20- year-old Thai male, who presented with progressive left hemiparesis.*

**Key words :** Intracranial germinoma, Multiple lesions.

Reprint request: Chirakalwasan N, Department of Pathology, Faculty of Medicine,  
Chulalongkorn University, Bangkok 10330, Thailand.

Received for publication. March 10, 2002.

\* Department of Pathology, Faculty of Medicine, Chulalongkorn University

\*\* Department of Pathology, Prasat Neurological Institute

นฤดา จีรกาลวสาน, สุชาติ พุทธิเจริญรัตน์. Germinoma ในสมองที่มีรอยโรคหลายแห่งในตำแหน่งที่พบไม่บ่อย: รายงานผู้ป่วย 1 ราย. จุฬาลงกรณ์เวชสาร 2545 พ.ศ; 46(5): 419 - 25

*Germinoma* เป็นเนื้องอกชนิดที่พบได้บ่อยที่สุดในกลุ่มเนื้องอกปฐมภูมิของสมองที่มีกำเนิดมาจาก *germ cell* ตำแหน่งที่พบได้บ่อยคือบริเวณ *pineal* และ *suprasellar* รองลงมาคือ *basal ganglion* และ *thalamus* เนื้องอกในตำแหน่งอื่น ๆ มีการรายงานอยู่ประปราย *Germinoma* ที่เกิดหลายตำแหน่งในสมองสามารถพบได้แต่ มักจะมีรอยโรคที่ *suprasellar* หรือ *pineal* ร่วมด้วยเช่นกัน

ได้รายงานผู้ป่วยชายไทยอายุ 20 ปี มาพบแพทย์ด้วยเรื่องแขนขาซ้ายอ่อนแรง ซึ่งได้รับการวินิจฉัยทางพยาธิวิทยาเป็น *germinoma* ของสมอง พบรอยโรคหลายตำแหน่งทั้งที่ *centrum semiovale*, *corpus callosum*, *periventricular areas*, *midbrain*, *internal capsule* และ *brain stem* โดยไม่มีรอยโรคบริเวณ *suprasellar* และ *pineal*

**คำสำคัญ :** *Intracranial germinoma, Multiple lesions.*

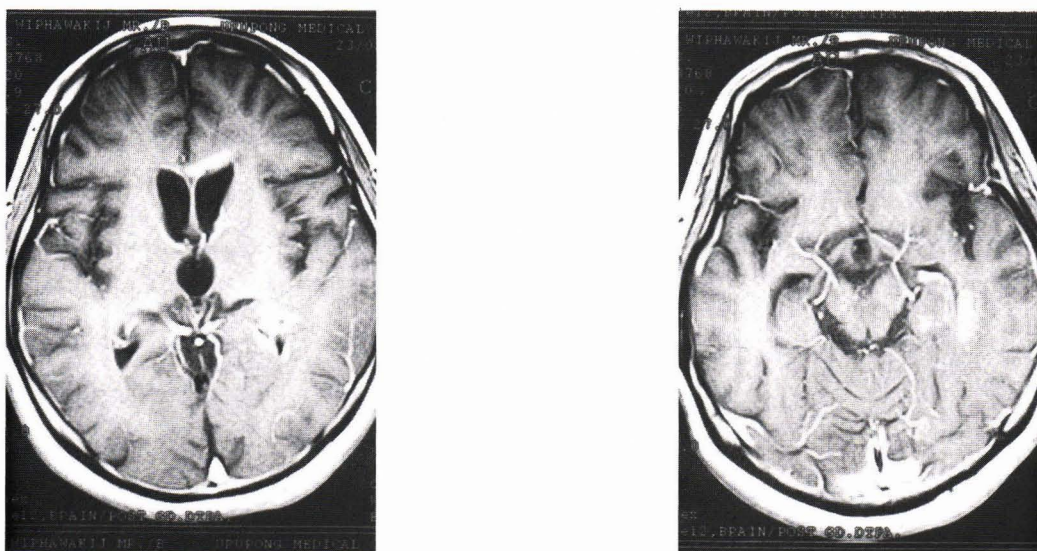
Germinoma is the most frequent subtype of primary intracranial germ cell tumors, accounted for 36 to 65 %, <sup>(1-4)</sup> and constitutes 0.1 to 3.4% of all intracranial tumors. <sup>(5)</sup> Its incidence is largely limited to the first three decades of life, with a male to female ratio of 1.88:1. <sup>(1)</sup> Midline structures are the preferred locations where the pineal and suprasellar regions are the two leading sites, <sup>(6-8)</sup> followed by the basal ganglion and thalamus. <sup>(9)</sup> The purpose of this article is to report an unusual case of multicentric intracranial germinoma that involved the centrum semiovale, corpus callosum, periventricular areas, midbrain, internal capsule and brain stem.

### Case report

A 20 – year - old Thai male presented to King Chulalongkorn Memorial Hospital with a 9-month history of progressive left-sided hemiparesis, behavioral changes, impaired memory and bowel-bladder incontinence. Increased appetite with 10 Kg-gained weight was also noted. Two weeks before admission, he developed left facial palsy.

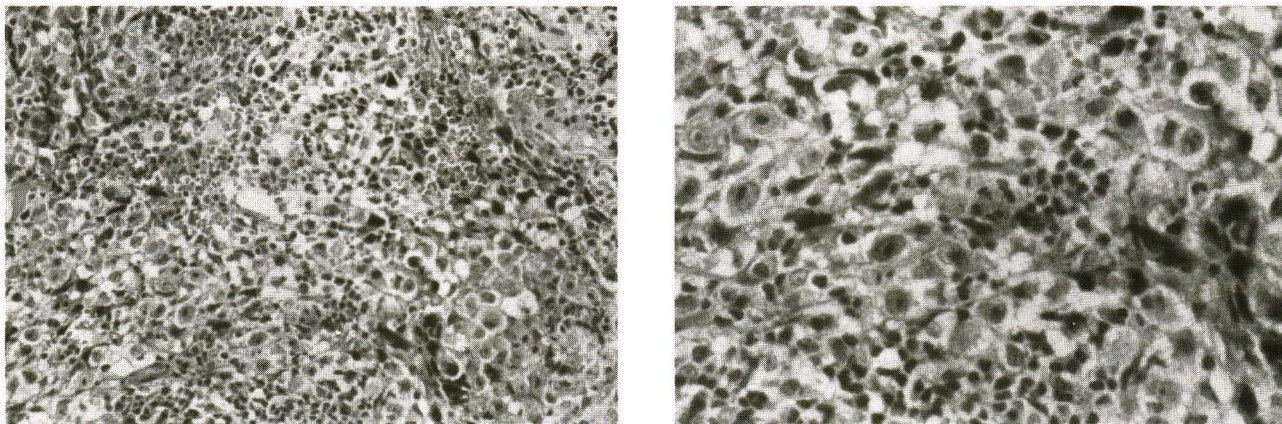
Neurological examination revealed an alert patient with slow speech and inappropriate mood, euphoria. Left facial palsy, upper motor neuron type was detected. Left- sided muscle power was graded 3/5. Increased muscle tone with cogwheel rigidity was also observed at the same side. There was left-sided plantarflexed Babinski response. Glabellar sign was positive. Others physical examinations were normal.

The patient had multiple magnetic resonance imaging (MRI) done which showed multiple lesions at bilateral centrum semiovale, posterior limb of internal capsule, midbrain especially right cerebral peduncle and pons. Demyelinating disease was the most suspected. The latest MRI and computed tomography (CT) demonstrated multiple enhanced lesions at corpus callosum and periventricular areas at both frontal horns, left occipital and left temporal horn of lateral ventricle without mass effect or shifting of midline structures (Figure1). Cerebrospinal fluid (CSF) for cytology study showed small amount of lymphocytes without malignant cell. Computed tomographic-guided stereotaxis was done to obtain periventricular tissue.



**Figure 1.** MRI of the brain (A) shows multiple enhancing lesions at corpus callosum, bilateral frontal horns and left occipital horn of lateral ventricles without pineal involvement. (B) Lesions at left temporal horn of lateral ventricle are noted. Suprasellar region is unremarkable.





**Figure 2.** Histopathology of intracranial germinoma shows (A) lobular arrangement of tumor cells separated by fibrous tissue which is infiltrated by lymphocytes (H&E, x 10). (B) They are large round cells with clear cytoplasm, prominent nuclei and distinct nucleoli (H&E, x 40).

Two pieces of dark brown tissue, 0.7x0.5x0.3 and 1x0.6x0.2 cm. were sent for histological examination. Hematoxylin and eosin stain revealed sheets of large tumor cells, separated by fibrous stroma which was infiltrated by lymphocytes. The tumor cells possessed large round nuclei with prominent nucleoli (Figure 2). The tumor cells focally reacted with placental alkaline phosphatase (PLAP) antiserum, while CD45,  $\alpha$ -fetoprotein and  $\beta$ -human chorionic gonadotropin were negative.

Germinoma was the diagnosis. No evidence of metastasis was detected. Whole brain radiation and chemotherapy were prescribed treatments for the patient. Follow-ups MRI of the brain showed progressive clearing of the lesions.

## Discussion

Beside the pineal and suprasellar regions where intracranial germinomas may occur up to 70 %, <sup>(2,10)</sup> the basal ganglion and thalamus, together are the third most common sites with an estimated

incidence of 4 to 10 %. <sup>(9)</sup> The third ventricle is another area where germinomas have been found not uncommonly. <sup>(1,2,5-6,11)</sup> Other rare locations of intracranial germinomas, including the cerebral hemisphere (frontal and occipital lobes), <sup>(6,12)</sup> corpus callosum, <sup>(13)</sup> lateral and fourth ventricles, <sup>(1-2,5-6)</sup> sellar turcica, <sup>(14)</sup> cerebellopontine angle, <sup>(15-16)</sup> medulla oblongata, <sup>(17-18)</sup> and cerebellum <sup>(2,5-6,8)</sup> have also been reported. Not frequently, intracranial germinomas appear at more than one locus. <sup>(1-2,6-7,10)</sup> Sugiyama *et al.* noted that up to 10 % of the cases of intracranial germinomas reported in Japanese literature exhibited synchronous lesions in the pineal body and suprasellar regions, <sup>(10)</sup> compared to 3 % and 16 % reported by Ho *et al.* <sup>(19)</sup> and Baranzelli *et al.*, <sup>(20)</sup> respectively. Multicentric lesions involving the suprasellar and basal ganglia were also documented by Sugiyama *et al.* <sup>(10)</sup> On a review of 58 germinomas by Matsutani *et al.*, 8 were found at multiple sites, 2 located mainly in the pineal region and 6 in the neurohypophysis. <sup>(2)</sup> Double suprasellar and cerebellar localizations, possibly

multifocal were described by Steimle *et al.*<sup>(6)</sup> Obviously, all of these reported multiple germinomas demonstrated either the suprasellar or pineal involvement. Although a few cases of multiple germinomas without suprasellar or pineal lesion have been mentioned,<sup>(8,13,21,22)</sup> none of them have scattered lesions occupying areas of the brain as many as found in this case. (Table 1) Our case is therefore unusual, both because of its site and multiple foci.

Microscopically, germinoma comprises two clearly distinguishable cell population,<sup>(6)</sup> the large polygonal or spheroidal tumor cells, and mononuclear inflammatory cells. The former possesses well-defined cell boundaries with large central spherical vesicular nuclei and prominent central nucleoli, while the latter consist mainly of lymphocytes with variable plasma-cell components.<sup>(6-7,23)</sup> Both cellular components were unequivocally present in our case; the positive result of placental alkaline phosphatase (PLAP) study supports the diagnosis.<sup>(19,24-25)</sup> Additionally, immunohistochemistry using leukocyte common antigen (CD45),  $\alpha$ -fetoprotein and  $\beta$ -human chorionic gonadotropin<sup>(7-19,26)</sup> antibodies were also done in the

case to exclude lymphoma and other subtypes of germ cell tumor.

Regarding to the multiple lesions of germinoma in the case, questions may be raised as to whether they represent: 1) metastatic tumors from a primary site outside the nervous system, and 2) dissemination of primary intracranial tumor along the cerebrospinal fluid pathway.<sup>(27)</sup> Lacking evidence of tumor elsewhere in the body, supported by the fact that it is very rare for extracranial germinoma to metastasize to the brain without widespread involvement of other Organs,<sup>(23)</sup> argues against the first possibility. Negative malignant cells in the CSF, together with discrete lesions in this patient, suggest multicentric in origin of the tumor, rather than intracranial metastases. An aberration in primordial germ cell migration is a current accepted theory of the histogenesis.<sup>(3,5,14)</sup>

In general, surgery is not considered a primary mode of treatment for intracranial germinomas, due to their usual deep-seated midline locations. Computed tomographic-guided stereotaxis is now an accepted method for obtaining tissue for diagnosis.<sup>(5)</sup> Radiation

**Table 1.** Comparison between age, sex and location of multiple germinomas without suprasellar or pineal lesion.

Author	Age	Sex	Location
Evanson et al	43	Male	Both cerebellar hemispheres
So SC and HO J	?	?	Corpus callosum and thalamus
Nagata et al	12	Female	Frontal lobe, caudate nucleus, lentiform nucleus, internal capsule and midbrain
Masuzawa et al	11	Male	Thalamus and basal ganglion
Masuzawa et al	39	Male	Ventricular system and posterior fossa
Our series	20	Male	Centrum semiovale, corpus callosum, periventricular areas, midbrain, internal capsule and brain stem

with or without chemotherapy has played an important role in the treatment and provides longer survival time, compared to other subtypes of germ cell tumors.<sup>(1,3)</sup> Disappearance of the lesions in our subject after radiation and chemotherapy indicate a good response to the treatments. Unfortunately, we are unable to compare our case and other cases mentioned in table 1. in the way of treatment and survival time due to unavailable datas.

### Acknowledgments

Dr. Kammant Phanthumchinda, M.D. and Dr. Worapong Teameukit, M.D. the attending neurologists, authorized the author to report the case.

### References

1. Jennings MT, Gelman R, Hochberg F. Intracranial germ-cell tumors: natural history and pathogenesis. *J Neurosurg* 1985 Aug; 63(2): 155 - 67
2. Matsutani M, Sano K, Takakura K, Fujimaki T, Nakamura O, Funata N, Seto T. Primary intracranial germ cell tumors: a clinical analysis of 153 histologically verified cases. *J Neurosurg* 1997 Mar; 86(3): 446 - 55
3. Balmaceda C, Modak S, and Finlay J. Central nervous system germ cell tumors. *Seminars in Oncology* 1998 Apr; 25(2): 243 - 50
4. Bjornsson J, Scheithauer BW, Okazaki H, Leech RW. Intracranial germ cell tumors: pathological and immunohistochemical aspects of 70 cases. *J Neuropathol Exp Neurol* 1985 Jan; 44(1): 32 - 46
5. Horowitz MB, Hall WA. Central nervous system germinoma: a review. *Arch Neurol* 1991 Jun; 48(6): 652 - 7
6. McLendon RE, Tien RD. Tumors and tumor-like lesions of maldevelopmental origin. In: Bigner DD, McLendon RE and Bruner JM. *Russell & Rubinstein's pathology of tumors of the nervous system*. Sixth edition. London: Edward Arnold, 1998: 304 - 12
7. Burger PC and Scheithauer BW. Germ cell tumors. In : Rosai J. *Tumors of the central nervous system: atlas of tumor pathology*. 3<sup>rd</sup> series fascicles 10. Washington, D.C. Armed forces institutue of pathology, 1993: 251 - 7
8. Evanson EJ, Lewis PD, Colquhoun IR. Primary germinoma of the posterior cranial fossa: a case report. *Neuroradiology* 1997 Oct; 39(10): 716 - 8
9. Ono N, Inoue HK, Naganuma H, Kunimine H, Zama A, Tamura M. Diagnosis of germinal neoplasm in the thalamus and basal ganglia. *Surg Neurol* 1986 Jul; 26(1): 24 - 8
10. Sugiyama K, Uozumi T, Kiya K, Mukada K, Arita K, Kurisu K, Hotta T, Ogasawara H, Sumida M. Intracranial germ-cell tumor with synchronous lesions in the pineal and suprasellar regions: report of six cases and review of the literature. *Surg Neurol* 1992 Aug; 38(2): 114 - 20
11. Koide O, Watanabe Y, Sato K. A pathological survey of intracranial germinoma and pinealoma in Japan. *Cancer* 1980 Apr; 45(8): 2119 - 30
12. Tanaka R, Ueki K. Germinomas in the cerebral hemisphere. *Surg Neurol* 1979 Sep; 12(3): 239 - 41
13. So SC, HO J. Multiple primary germinomas (ectopic pinealoma) of the brain. *Neuro-*

- chirurgia (Stuttg) 1980 Jul; 23(4): 147 - 50
14. Frank G, Galassi E, Fabrizio AP, Frank F, Manetto V. Primary intrasellar germinoma: case report. Neurosurgery 1992 May; 30(5): 786 - 8
15. Kurtsoy A, Pasaoglu A, Koc RK, Oktem IS, Kontas O. Cerebellopontine angle germinoma: a case report. Neurosurg Rev 1996; 19(2): 127 - 30
16. Nagendran K, Rice-Edwards M, Kendall B, Barnard RO, Guiloff RJ. Germinoma in the cerebellopontine angle. J Neurol Neurosurg Psychiatry 1985 Sep; 48(9): 955 - 6
17. Nakajima H, Iwai Y, Yamanaka K, Yasui T, Kishi H. Primary intracranial germinoma in medulla oblongata. Surg Neurol 2000 May; 53(5): 448 - 51
18. Sugiyama K, Uozumi T, Goishi J, Sogabe T, Arita K, Maeda H, Ikawa F. Germinoma of the medulla oblongata: case report. Neurol Med Chir(Tokyo) 1994 May; 34(5): 291 - 4
19. HO DM, Liu HC. Primary intracranial germ cell tumor: pathologic study of 51 patients. Cancer 1992 Sep; 70(6): 1557 - 84
20. Baranzelli MC, Patte C, Bouffet E, Couanet D, Habrand JL, Portas M, Lejars O, Lutz P, Gall EL, Kalifa C. Nonmetastatic intracranial germinoma; the experience of the French society of pediatric oncology. Cancer 1997 Nov; 80(9): 1792 - 7
21. Nagata K, Nikaido Y, Yuasa T, Jujimoto K, Kim YJ, Inoue M. Germinoma causing wallerian Degeneration. J Neurosurg 1998 Jan; 88(1): 126 - 8
22. Masuzawa T, Shimabukuro H, Nakahara N, Iwasa H, Sato F. Germ cell tumors (germinoma and yolk sac tumor) in unusual sites in the brain. Clin Neuropathol 1986 Sep - Oct; 5(5): 190 - 202
23. Nishiyama RH, Batsakis JG, Weaver DK, Simrall JH. Germinal neoplasms of the central nervous system. Arch Surg 1966 Aug; 93(2): 342 - 7
24. Shinoda J, Yamada H, Sakai N, Ando T, Hirata T, Miwa Y. Placental alkaline phosphatase as a tumor marker for primary intracranial germinoma. J Neurosurg 1988 May; 68(5): 710 - 20
25. Shinoda J, Miwa Y, Sakai N, Yamada H, Shima H, Kato K, Takahashi M, Shimokawa K. Immunohistochemical study of placental alkaline phosphatase in primary intracranial germ-cell tumors. J Neurosurg 1985 Nov; 63(5): 733 - 9
26. Burger PC and Scheithauer BW. Primary tumors of hematopoietic tissue. In : Rosai J. Tumors of the central nervous system: atlas of tumor pathology. 3<sup>rd</sup> series fascicles 10. Washington, D.C. Armed forces institute of pathology, 1993: 321 - 8
27. Gay JC, Janco RL, Lukens JN. Systemic metastases in primary intracranial germinoma: case report and literature review. Cancer 1985 Jun; 55(11): 2688 - 90