

5-1-2002

## Vasovasostomy : 10 years of experience atKing Chulalongkorn Memorial Hospital

A. Kongkanand

S. Permpongkosol

Follow this and additional works at: <https://digital.car.chula.ac.th/clmjjournal>



Part of the [Medicine and Health Sciences Commons](#)

---

### Recommended Citation

Kongkanand, A. and Permpongkosol, S. (2002) "Vasovasostomy : 10 years of experience atKing Chulalongkorn Memorial Hospital," *Chulalongkorn Medical Journal*: Vol. 46: Iss. 5, Article 6.  
Available at: <https://digital.car.chula.ac.th/clmjjournal/vol46/iss5/6>

This Article is brought to you for free and open access by the Chulalongkorn Journal Online (CUJO) at Chula Digital Collections. It has been accepted for inclusion in Chulalongkorn Medical Journal by an authorized editor of Chula Digital Collections. For more information, please contact [ChulaDC@car.chula.ac.th](mailto:ChulaDC@car.chula.ac.th).

## Vasovasostomy : 10 years of experience at King Chulalongkorn Memorial Hospital

Apichat Kongkanand\*

Sompol Permpongkosol\*\*

**Kongkanand A, Permpongkosol S. Vasovasostomy : 10 years of experience at King Chulalongkorn Memorial Hospital. Chula Med J 2002 May; 46(5): 401 - 7**

**Objection** : *To study the results of reconnection of vas deferens with one layer microsurgical technique in Thai men and pregnancy rate of their spouses.*

**Setting** : *King Chulalongkorn Memorial Hospital, Department of Surgery, Urology*

**Subjects** : *The patients who underwent vasovasostomy to reverse the sterile procedures during the past 10 years. (January 1986 - December 1997) using one layer microsurgical technique.*

**Result** : *Thirty - seven of eighty - four Thai male patients, aged from 31 to 53 years old operated during such period were available for study by phone interview and postcard return. We received good result of 87 % patency rate and 54 % pregnancy rate, which is excellence and comparable with other technique.*

**Conclusion** : *One layer microsurgical technique provides excellence results and requires short time to learn.*

**Key word** : *Vasovasostomy.*

Reprint request : Kongkanand A, Department of Surgery, Faculty of Medicine, Chulalongkorn University, Bangkok 10330, Thailand.

Received for publication. February 12, 2002.

\* Department of Surgery, Faculty of Medicine, Chulalongkorn University

\*\* Department of Urology, Osaka University Medical School, Osaka, JAPAN

อภิชาติ กงกะนันท์, สมพล เพิ่มพงษ์โกศล. เทคนิคการต่อหมันชายโดยกล้องไมโครสโคป ประสพการณ์ 10 ปี ในโรงพยาบาลจุฬาลงกรณ์. จุฬาลงกรณ์เวชสาร 2545 พ.ศ; 46(5): 401-7

- จุดประสงค์** : เพื่อศึกษาการต่อหมัน โดยการใช้กล้องไมโครสโคป โดยเทคนิคแบบง่าย และผลลัพธ์
- สถานที่** : ภาควิชาศัลยศาสตร์ โรงพยาบาลจุฬาลงกรณ์
- ตัวอย่างที่ทำการศึกษา** : ผู้ป่วย 84 ราย อายุระหว่าง 31 - 53 ปี, ในระหว่าง 10 ปี ที่ติดตามมาได้ 37 ราย (42 %) โดยการให้โทรศัพท์สอบถามและรายงานผลโดยบัตร ไปรษณีย์
- ผลลัพธ์** : ได้รับผลลัพธ์ 87 % ต่อหมันดีดี และได้ผล 54 % จำนวนผู้ป่วยที่ภรรยา มีครรภ์ได้ผลดีมากพอ ๆ กับหลายแห่งและเทคนิค 2 ชั้น
- สรุป** : การต่อหมันโดยการให้เทคนิคชั้นเดียวแบบง่าย โดยกล้องไมโครสโคป นับว่าได้ผลดี และใช้เวลาในการศึกษาน้อย
- คำสำคัญ** : Vasovasostomy.

Vasectomy remains the safest method of birth control and there is much to commend upon its setting of a stable family relationship.<sup>(1)</sup> The number of American men who undergone vasectomy have remained stable about 500,000 per year whereas they have the divorce rate of 50 %. A number of surveys suggested that 2 % to 6 % of vasectomized men ultimately sought for reversal.<sup>(2)</sup> In Korea, approximately 1,000,000 vasectomies were performed during 1962 to 1984. It was estimated that 1 reversal operation was performed for every 500 vasectomies.<sup>(3)</sup> Thailand's Ministry of Public Health reported that roughly 1,513,393 vasectomies were performed from 1974 to 1996,<sup>(4)</sup> the report said nothing about vasovasostomy. Naturally, the more vasectomies performed means the more vasovasostomies are needed.

Reversal of vasectomy is so far a relatively difficult procedure. Most surgeons still perform a macroscopic vasovasostomy. However, there is a little guidance in the current literature on the results that could be expected from such procedures. Patients who are considering to have a macroscopic reversal of vasectomy should be warned of a slim chance of success, less than 20 %.<sup>(5)</sup> Therefore, a microsurgical approach to vasovasostomy is worthwhile to obtain patency and fertility rates which are superior to those of other techniques.<sup>(6)</sup> Today, many variant methods of vasovasostomy are reported. We present a new technique of vasectomy reversal that is quicker and easier to perform. The technique requires no additional surgical skills, as well as it may benefit the improvement of the technique among less experienced microsurgeons.

## Material and Method

We retrospectively analyzed the results of 84 patients who were treated with a new technique of microsurgical vasovasostomy from January 1986 to December 1997 at King Chulalongkorn Memorial Hospital. A postal questionnaire was mailed to every patient who could be followed up. Semen analysis and pregnancy data were available for 37 (42 %) of them. Patients' ages ranged from 31 to 53 years, with a mean age of 40 years. Their wives ranged from 22 - 40 years, with a mean age of 31 years. The duration from vasectomy to vasovasostomy ranged from 2 to 25 years, with a mean of 8 years. Their average number of children was 2.4 (ranged 1 to 3) at vasectomy. Reversal of vasectomy was requested on the reason of remarriage in 29 patients, death of children in 3, change of attitude in 1, and desire for more children in 2 cases. Previous vasectomy reversals were involved in four cases from other hospitals.

Microsurgical anastomosis was facilitated by the use of surgical optic instruments, a modified one-layer technique, spinal anesthesia and a single surgeon (A.K.) All the patients who requested the surgical procedure were recruited into the study, regardless of their age or time since vasectomy, in order to have a non selected group. The operation time was approximately 90 minutes. A follow-up assigned with sperm counts processed under the same standard and performed at least 6 weeks, postoperatively. The results of the operation were judged as anatomical success, or patency rate. Defined as the appearance of normal viable sperm in counts of more than  $1 \times 10^6$  /ml. And functional success, or pregnancy rate (first pregnancy only.)

### Technique

The vas deferens was individually isolated by towel clips: on both sides, proximal and distal ends. The sperm granuloma or suture knots, which were tied on vasectomy procedure, were sharply removed. The length of the vas deferens on the distal part could be traced into the inguinal canal by opening the vaginal processus., Usually there was serial fluid lubricating, the scrotum or tunica albuginea; and the length of vas deferens would be followed; and it would much easily to bring together the vas deferens on both ends for reanastomosis.

There were several kinds of clamps used approximate vas deferens, we used arterial clamps to approximate both ends. The proximal end was normally wider at the opening of the vas and look for intima of the vas deferens because if we did not include the whole intima. Then the intima would be the occlusion part or just like thrombus, causing a failure to the anastomosis process.

With two 10-0 nylon cutting-edge needles of 30 cm length, we divided for 2 sutures and use it one at a time to save the suture material, making it more cost effective. The first suture went through the whole length from outside of the proximal end, passing the intima to the inner of the distal and come out as one layer suture. Then appeared as it was the running suture to the second and 3rd stitches (see picture) (Figure 1,2,3,4) Then we cut the nylon string between the first and second suture and legated the first stitch (Figure 5,6), with surgical knot tied in 3 knots. Then proceeded with second and third stitches in order, not to pull them too hard, but firm enough so that the suture would not break away. Also remember that the 10-0

nylon needed to be handled gently.

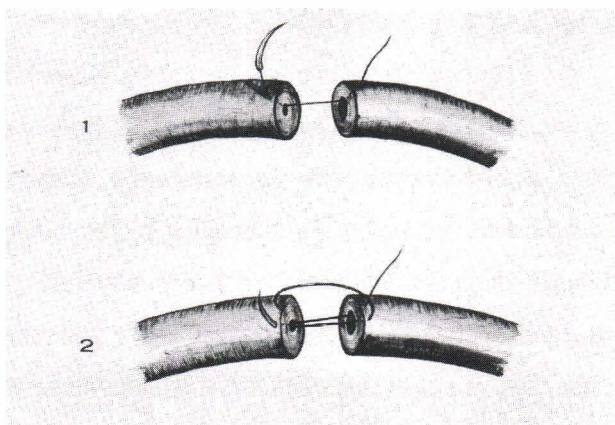
Once the suturing on 3 stitches or 4 stitches was completed, we then turned the arterial clamps to the opposite side and inspected both ends of the vas. At this stage, we should be able to see the sutures made on the opposite side or back wall, (Figure 7,8). Securing the intima into the suture everytime the needle went through it. The technique was done similarly on the other side. Additional sutures was put on seromuscular layer. Here we, tried not to go deep, as it was not necessary to include the lumen since the cutting edge of the needle may rupture the previous stitches made, by going on one layer technique. Results were as good as double layers technique, and made it much easier. An occasional or seldom microscopic surgeon could do this technique with the confidence. The technique could include all the intima and without stunt. Since microsurgery was the best choice for vas deferens anastomosis at King Chulalongkorn Memorial Hospital, our policy was not to refuse on the request for vasectomy reversal. Since many centers in the country declined to help them if they had vasectomy longer than 15 years; our results, included all the cases even those who had vasectomy for more than 20 years.

### Result

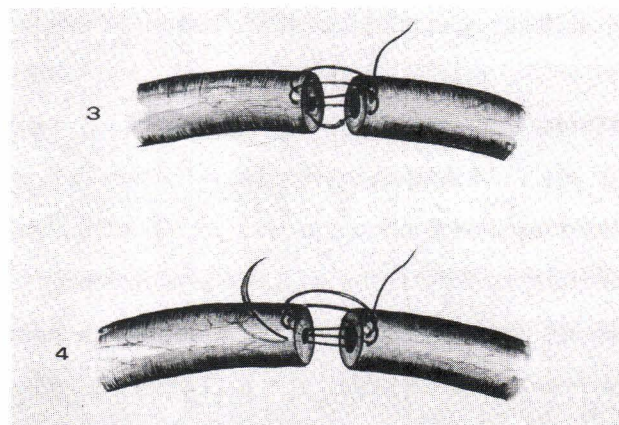
In a total of 37 cases who underwent vasovasostomy, the patency rate was 84 % (31 patients) and the pregnancy rate was 52 % (16 patients.) with obstructive intervals of less than 5 years (7 patients); sperm were presented in the ejaculation of 6 (a patency rate of 86 %), and pregnancy was established by 3, for a pregnancy

rate of 50%. However, the patency and pregnancy rate after and obstructive interval of more than 10 years (7 patients) were the same as those who took it less than 5 years. The two cases of previously repeated vasovasostomy achieved 1 case of patency,

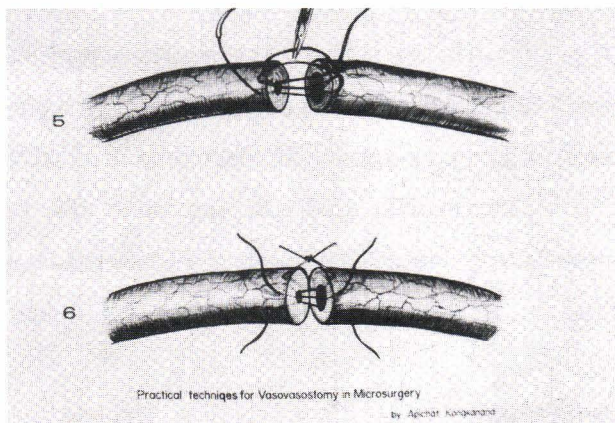
but had no pregnancy report. The partner of one patient who had an obstructive interval for 13 years became pregnant just 4 months after the surgery. Postoperative and late complications did not occur in the series.



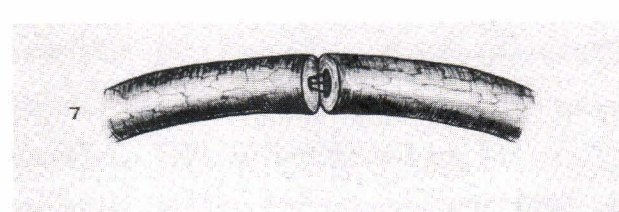
**Figure 1 - 2** Practical technique by performing such as eunning suture.




**Figure 3 - 4** Take the whole layer by including intima on both ends.



**Figure 5 - 6** Once finishing 3 or 4 stitches (if proximal end is much wider) then cut the string start tying knott one at a time.



**Figure 7.** Turn to work on the opposite side, and examine the back wall, then proceed with suture.



**Figure 8.** Start suturing the opposite side as same as the front side.

## Discussion

When sperm was found in the vassal fluid at least on one side at the time of surgery, the anastomotic technique described results in appearance of sperm in the ejaculate in 99 % of men (Matthews *et al.*, 1995). Late obstruction, after initial patency, occurred in 12 % of men, 14 months after the operation (Matthews *et al.*, 1995). Pregnancy occurred in 63 % of couples, after at least 2 years of follow-up provided that female factors were excluded and sperm was found in the vas at least on side at the time of vasovasostomy.<sup>(2,7)</sup> Microsurgical vasovasostomy provided the patients with further reasonable hope for becoming fertile, but microsurgical skills were also required. The microdot technique of precision suture placement by Marc Goldstein<sup>(8)</sup> was well documented, but would take some times for the new microsurgery attendant to learn modified one layer technique. They would do well, but it would also take more suturing and cost more for each stitch to be put on.

The main technique on the anastomosis is leak proof, accuracy and mucosa to mucosa approximation. Once the anastomosis is turned over to the opposite side, we would see to the suture on the back wall very well before tying the second side.

The success rate is at 52 pregnancy rate are comparable with what Belker had which are less than 3 years of vasectomy reversal potency was 97 % and pregnancy 76 %, 3 to 8 years 88 %, and 53 %, 9-14 years will have patency 79 % and pregnancy 44 %., More than 15 years will have 71 % patency rate and pregnancy at 30 %<sup>(9,10)</sup>

We developed the method that requires no additional surgical skills to improve the success

rate among less experienced microsurgeons. Nevertheless, the patency and pregnancy rates in our early series appeared to be somewhat parallel to that reported for other microsurgical repairs. Our procedure could be a good choice for a less experienced surgeon, and certainly better than the macroscopic techniques.

Further studies are necessary to determine the possibility of an increased success rate, because the number of patients in the series were not sufficient to draw definite conclusions. In addition, by excluding female factors in infertility, the pregnancy rate of the approach could be increased. There was one case that the patient did not have a sex partner at all after the surgery.

Furthermore, the success rates with obstructive intervals shorter than 5 years were not obviously different from those who had the operation longer than 10 years who contributed to a pregnancy 4 months after the surgery. The results suggested that a long duration from vasectomy to vasovasostomy was not a contraindication of vasectomy reversal.<sup>(11)</sup>

Like in other reports, it was found that the most common reason for requesting a vasovasostomy was the desire to have children with a new partner.

## Conclusion

We report ten years follow-up of vasectomy reversal at King Chulalongkorn Memorial Hospital and good results of success rate in vas anastomosis, using one layer technique on "day case" surgery with anesthesia, and good result comparable with other centers and propose of technique of anastomosis, which is more cost-effective and easy to do for new microsurgery attendants.

## References

1. Hendry WF. Vasectomy and vasectomy reversal. Br J Urol 1994 Apr; 73(4): 337 - 44
2. Goldstein M. Surgical management of male infertility and other scrotal disorders Campbell' Urology 7<sup>th</sup>ed.1331 - 77
3. Lee HY. A 20 – year experience with vasovasostomy. J Urol 1986 Aug,136(2): 413 - 5
4. The Thai Ministry of Health, The new report to the Thai national Family planning program in 1996
5. White AE, Sheridan WG, Crosby DL. Reversal of vasectomy and the general surgeon. Br J Clin Pract. 1994 Sep – Oct; 48 (5): 238 - 9
6. Fox M. Vasectomy reversal - microsurgery for best results. Br J Urol Apr; 73(4): 449 - 53
7. Matthews GJ, Schlegel PN, Goldstein M . Patency following microsurgical vasoepididymostomy and Vasovasostomy: temporal considerations. J Urol 1995 Dec;154(6): 2070 - 3
8. Goldstein M, Li PS, Matthews GJ. Microsurgical vasovasostomy : the microdot technique of precision suture placement. J Urol 1998 Jan; 159(1): 188 - 90
9. Sharlip ID, What is the best pregnancy rate that may be expected from vasectomy reversal?. J Urol. 1993 June; 149(6): 1469 - 71
10. Belker AM, Thomas AJ Jr, Fuchs EF, Konnak JW, Sharlip ID. Results of 1,469 microsurgical vasectomy reversals by the Vasovasostomy Study Group. J Urol 1991 Mar; 145(3): 505 -11
11. Carbone DJ Jr, Shah A, Thomas AJ Jr, Agarwal A. Partial obstruction, not antisperm antibodies, causing infertility after vasovasostomy. J Urol 1998 Mar;159(3): 827-30