

3-1-2004

Seton in the treatment of horseshoe fistula

C. Supalermongkonchai

C. Sahakitrungruang

J. Pattana-arun

A. Rojanasakul

Follow this and additional works at: <https://digital.car.chula.ac.th/clmjournal>



Part of the [Medicine and Health Sciences Commons](#)

Recommended Citation

Supalermongkonchai, C.; Sahakitrungruang, C.; Pattana-arun, J.; and Rojanasakul, A. (2004) "Seton in the treatment of horseshoe fistula," *Chulalongkorn Medical Journal*: Vol. 48: Iss. 3, Article 1.

Available at: <https://digital.car.chula.ac.th/clmjournal/vol48/iss3/1>

This Article is brought to you for free and open access by the Chulalongkorn Journal Online (CUJO) at Chula Digital Collections. It has been accepted for inclusion in Chulalongkorn Medical Journal by an authorized editor of Chula Digital Collections. For more information, please contact ChulaDC@car.chula.ac.th.

Seton in the treatment of horseshoe fistula

Chalermkit Supalermongkonchai* Chucheeep Sahakitrungruang*
 Jirawat Pattana-arun* Arun Rojanasakul*

Supalermongkonchai C, Sahakitrungruang C, Pattana-arun J, Rojanasakul A. Seton in the treatment of horseshoe fistula. Chula Med J 2004 Mar; 48(3) 137 - 43

- Objective** : *To compare the treatment of horseshoe fistula between Hanley's technique alone and Hanley's technique with Seton.*
- Setting** : *King Chulalongkorn Memorial Hospital*
- Design** : *Retrospective and descriptive study*
- Subject** : *Inpatient record of horseshoe fistula treated with Hanley's technique alone and Hanley's technique with Seton at King Chulalongkorn Memorial Hospital from 1993 to 2001.*
- Methods** : *The information on recurrences and complications were reviewed from inpatient records and outpatient records. Interviews with patients or their relatives were also conducted.*
- Results** : *There were 374 cases of fistula in ano. Twenty-five of 51 cases of horseshoe fistula were treated either with Hanley's technique alone or a combination of Hanley's technique with Seton. Twenty-six cases were treated with another technique. Accordingly, Hanley's technique was done in 13 patients. There were 4 recurrences (1 healed after re-operation; 3 lost follow-up). Healing by the first operation, without any complication, was found in 9 patients (64 %). There were 3 recurrences in twelve patients who were treated with Hanley's technique and Seton (2 were healed after re-operation; 1 lost follow-up); and 1 had partial incontinence (8 %). There was no statistical difference in recurrent rate and complication among both groups.*

Conclusion : *The result of treatment between Hanley's technique alone and Hanley's technique with Seton in horseshoe fistula was not different.*

Keywords : *Horseshoe fistula, Seton, Hanley's technique.*

Reprint request: Supalermongkonchai C. Department of Surgery, Faculty of Medicine,
Chulalongkorn University, Bangkok 10330, Thailand.

Received for publication. September 15, 2003.

เฉลิมกิตติ์ สุขเลิศมงคลชัย, ชูชีพ สหกิจรุ่งเรือง, จิรวัดน์ พัฒนะอรุณ, อรุณ โรจนสกุล.
บทบาทของ Seton ในการรักษา horseshoe fistula, การศึกษา ณ โรงพยาบาลจุฬาลงกรณ์.
จุฬาลงกรณ์เวชสาร 2547 มี.ค; 48(3) 137 - 43

- วัตถุประสงค์** : เพื่อเปรียบเทียบการรักษา horseshoe fistula ระหว่างเทคนิคแบบ Hanley แบบที่ใช้ Seton และแบบไม่ใช้ Seton
- สถานที่ทำการศึกษา** : โรงพยาบาลจุฬาลงกรณ์
- รูปแบบการศึกษา** : การศึกษาย้อนหลังแบบพรรณนา
- ตัวอย่างที่ทำการศึกษา** : ข้อมูลของผู้ป่วยที่เป็น horseshoe fistula และได้รับการรักษาแบบ Hanley ทั้งแบบที่ใช้และไม่ใช้ Seton ในโรงพยาบาลจุฬาลงกรณ์ ระหว่างปี 2536-2544
- วิธีการศึกษา** : ทบทวนวรรณกรรมที่เกี่ยวข้อง ทั้งประวัติผู้ป่วยในและประวัติผู้ป่วยนอก รวมถึงการส่งจดหมาย, การโทรศัพท์, การเยี่ยมบ้านเพื่อสัมภาษณ์ ผู้ป่วยและญาติ
- ผลการศึกษา** : มีผู้ป่วย fistula in ano ในการศึกษาจำนวน 374 ราย โดย 51 รายเป็น horseshoe fistula ซึ่งมีจำนวน 25 รายที่ได้รับการรักษาด้วยเทคนิค Hanley แบบที่ใช้และไม่ใช้ Seton ผู้ป่วย 26 รายได้รับการรักษาด้วยเทคนิคอื่น ๆ แบบไม่ใช้ Seton มีทั้งหมด 13 ราย (ชาย 11 คน หญิง 2 คน อายุเฉลี่ย 40 ปี) มีการกลับเป็นซ้ำ 4 ราย, หายในการผ่าตัดครั้งแรก 9 รายและไม่มีภาวะแทรกซ้อน แบบใช้ Seton 12 ราย (ชาย 10 คน หญิง 2 คน อายุเฉลี่ย 39 ปี) มีการกลับเป็นซ้ำ 3 ราย มีภาวะแทรกซ้อน กลับอุจจาระไม่ได้ 1 ราย จากการเปรียบเทียบผู้ป่วยทั้ง 2 กลุ่ม ทั้งด้านการกลับเป็นซ้ำและด้านภาวะแทรกซ้อนพบว่าไม่มีความแตกต่างกัน อย่างมีนัยสำคัญทางสถิติ
- สรุป** : การผ่าตัดในผู้ป่วย horseshoe fistula โดยการใช้เทคนิค Hanley แบบที่ใช้ Seton และไม่ใช้ Seton ให้ผลในการรักษาไม่แตกต่างกัน
- คำสำคัญ** : Horseshoe fistula, Seton, Hanley 's technique

Fistula in ano is an ancient and common surgical problem. We find that most common type of fistula in ano is superficial type, which can be easily treated with fistulotomy. However, the treatment of high type of fistula in ano or complicated fistula is still difficult and needs further study. One of the techniques used in the treatment of fistula in ano in the old time until now is Seton (Latin: seta means bristle). Seton in surgery refers to a foreign body that is inserted through the fistula tract in order to identify the depth of the fistula, to stimulate the fibrosis reaction, drainage, or to cut the anal sphincter with slow rate.⁽¹⁾ The study of the rate of recurrence and complication of Seton employed in the treatment of fistula in ano is not yet well established. In this study, we reviewed the results of Seton used in patients with horseshoe fistula and treated with Hanley's technique at King Chulalongkorn Memorial Hospital.

Materials and Methods

Inpatient records of cases of fistula in ano treated at the Department of Surgery between 1993 and 2001 were retrospectively reviewed. Patients who were diagnosed with horseshoe fistula in ano and treated with Hanley's technique alone (HA) or Hanley's

technique with Seton (HS) (Figure 1) were recruited into the study. Incomplete or destroyed records were not included. Patients who died before cured and patients who have horseshoe with another complex fistula were also excluded. Demographic data (sex, number, age, type, underlying disease), recurrent rate, complication and duration of healing were evaluated.

Log rank test was employed to compare the durations of healing and Fisher's exact test for recurrent rate in statistical analyses of the data.

Results

Of 374 cases of fistula in ano, 149 were intersphincteric fistula; 73 tran-sphincteric, 1 suprasphincteric; and 51 horseshoe fistula. The type of fistula in forty-six records could not be identified because of their incomplete data. Twenty-five records of 51-horseshoe fistula (13 in HA group and 12 in HS group) had complete information. The patients' ages were between 25-60 years old (21 males, 4 females). Their underlying diseases were toxic goiter, hypertension and AIDS. The number of prior-operation ranged from 1 to 4. The types of fistula were semi-horseshoe in 22 patients and bilateral horseshoe fistula in three. The demographic data of both groups

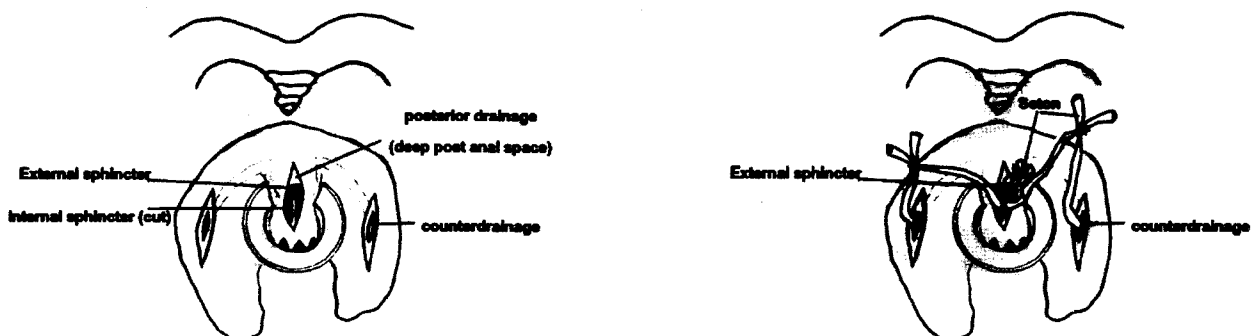


Figure 1. A. Hanley's technique alone

B. Hanley's technique with Seton

Table 1. Demographic data of horseshoe fistula patients.

Parameter	HA	HS
Technique	13	12
Sex (M: F)	11:2	10:2
Underlying disease		
Toxic goiter	1	0
Hypertension	1	0
HIV infection	1	0
No underlying	10	12
Prior- operation		
0	6	7
1	3	2
2	3	0
4	1	3
Type of horseshoe fistula		
Semi-lateral	12	10
Bilateral	1	2

Table 2. Illustration of recurrent rate and complication of horseshoe fistula patients.

Parameter	HA	HS
Recurrent rate		
0	9	10
1	4	1
2	0	1
Complication		
None	13	11
Incontinence	0	1

were similar, except their underlying diseases (Table 1). The study showed that the patients in HS group had lower recurrent rate and higher cure rate in the first operation (83 % vs. 69 %) but there was no statistical significance (p-value = 0.645) and one

patient had partial incontinence that was not found in HA group (Table 2). The median duration of treatment in HA group and HS group were 1.5 months and 3 months, but again the difference was of no statistic significance (p-value = 0.69) (Figure 2).

Discussion

There were multiple factors that influenced the results of fistula in ano such as the type of fistula and the technique of treatment. The recurrent rate of horseshoe fistula was between 18 to 28.6 %^(2,3) which corresponds to the finding in our study (24 %).

In 1965, Hanley suggested primary fistulotomy for the treatment of horseshoe anal fistula and in 1984 he recommended Seton less incontinence, but it was not supported by any statistical report.^(4,5) The recurrent rate of Seton was reported between 3.8 and 4 % in the literatures,^(3,6) but all types of fistula were included in these studies.

In 1990, Ustynoski K reported 18.1 % of recurrent rate for the result of Seton technique in horseshoe fistula but he did not show any other comparative technique.⁽⁷⁾

The treatment of horseshoe fistula with deroofting of deep postanal space that used Seton for drainage was also reported by Micheal E. He reported 96 % of the patients were healed; 21 % required reoperation; and 21% had incontinence.⁽⁸⁾

Since this is a retrospective study, it is difficult to control the confounding factors which would enable us to interpret the records correctly. However, we tried to complete the information by interviewing the patients or their relatives by phone calls, letters and home visits. This study showed that many patients were healed in 1 and 3 months

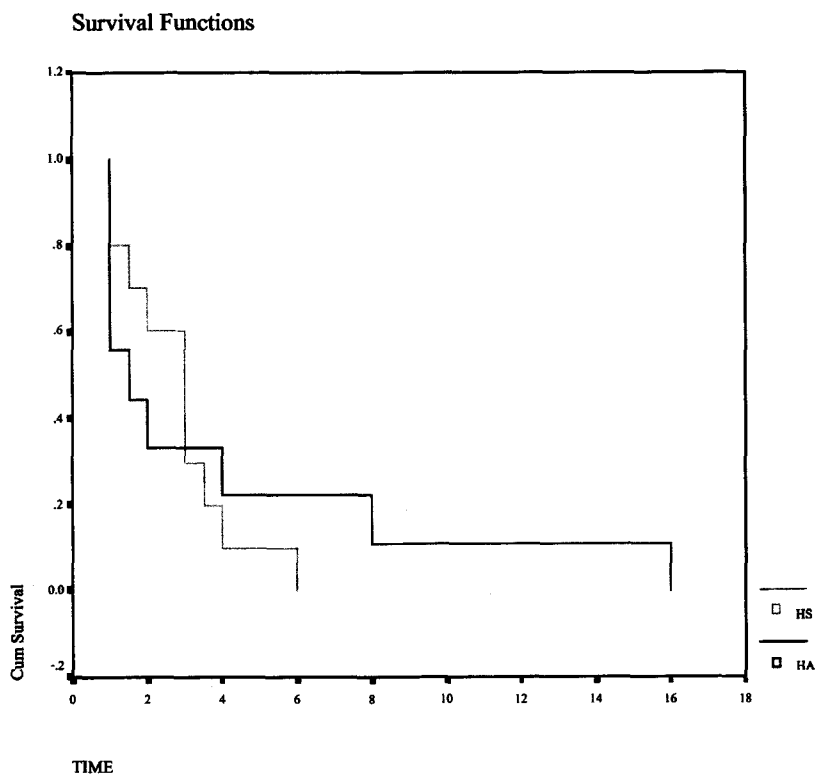


Figure 2. Illustration of the duration of healing of horseshoe fistula between Hanley's technique alone and Hanley's technique with Seton.

in HA and HS, respectively. However, the mean healing time in HA group was longer than HS group, due to the healing time of one subject in the HA group was spread far out from the others. As for the recurrence, all patients were eventually healed after they turned to alternative medicine for their treatment, except one case because of negligence for further treatment. However, the differences of the healing time and recurrent rate in this study did not reach the level of statistical significance because of the small size of the subjects. Therefore, the result might be concluded in further study. Based on the findings of this study, There were no difference between Hanley's technique alone and Hanley's with Seton technique.

References

1. McCourtney JS, Finlay IG. Setons in the surgical management of fistula in ano. *Br J Surg* 1995 Apr; 82(4): 448 - 52
2. Held D, Kubchandani IT, Sheets J, StasiK J, Rosen L, Riether R. Management of anorectal horseshoe abscess and fistula. *Dis Colon Rectum* 1986 Dec; 29(12): 793 - 7
3. Misra MC, Kapur BM. A new non-operative approach to fistula in ano. *Br J Surg* 1988 Nov; 75(11): 1093 - 4
4. Hanley PH. Conservative surgical correction of horseshoe abscess and fistula. *Dis Colon Rectum* 1965 Sep-Oct; 8(5): 364 - 8

5. Hanley PH. Reflections on anorectal abscess fistula: 1984. *Dis Colon Rectum* 1985 Jul; 28(7): 528 -33
6. McCourtney JS, Finley IG. Cutting seton without preliminary internal sphincterotomy in management of complex high fistula in ano. *Dis Colon Rectum* 1996 Jan; 39(1): 55 - 8
7. Ustynoski K, Rosen L, Stasik J, Riether R, Sheets J, Khubchandani IT. Horseshoe abscess fistula. Seton treatment. *Dis Colon Rectum* 1990 Jul; 33(7): 602 - 5
8. Pezim ME. Successful treatment of horseshoe fistula requires deroofting of deep postanal space. *Am J Surg* 1994 May; 167(5): 513 - 5