

7-1-2004

Anatomical variations of the colic arteries from the superior mesenteric artery

P. Karnjanasilp

S. Kornthong

T. Huanmanop

S. Agthong

V. Chentanez

Follow this and additional works at: <https://digital.car.chula.ac.th/clmjjournal>



Part of the [Medicine and Health Sciences Commons](#)

Recommended Citation

Karnjanasilp, P.; Kornthong, S.; Huanmanop, T.; Agthong, S.; and Chentanez, V. (2004) "Anatomical variations of the colic arteries from the superior mesenteric artery," *Chulalongkorn Medical Journal*: Vol. 48: Iss. 7, Article 3.

Available at: <https://digital.car.chula.ac.th/clmjjournal/vol48/iss7/3>

This Article is brought to you for free and open access by the Chulalongkorn Journal Online (CUJO) at Chula Digital Collections. It has been accepted for inclusion in Chulalongkorn Medical Journal by an authorized editor of Chula Digital Collections. For more information, please contact ChulaDC@car.chula.ac.th.

Anatomical variations of the colic arteries from the superior mesenteric artery

Prapon Karnjanasilp*

Suraporn Kornthong* Thanasilp Huanmanop*

Sithiporn Agthong* Vilai Chentanez*

Karnjanasilp P, Kornthong S, Huanmanop T, Agthong S, Chentanez V. Anatomical variations of the colic arteries from the superior mesenteric artery. Chula Med J 2004 Jul; 48(7): 465 - 71

- Problem/Background** : *Currently, there are no detailed data of the anatomical variations of the colic arteries in Thai population. Since colon surgery is still widely practiced in Thailand, a study to provide such data is essentially required.*
- Objective** : *To study the anatomical variations of ileocolic, right colic and middle colic arteries in Thai cadavers.*
- Setting** : *Department of Anatomy, Faculty of Medicine, Chulalongkorn University*
- Research design** : *Descriptive study*
- Material** : *100 cadavers collected at the Department of Anatomy, Faculty of Medicine, Chulalongkorn University from 2001 to 2003*
- Methods** : *The abdomen of each cadaver was dissected to expose the ileocolic, right colic and middle colic arteries. The existence and origins of these arteries were then noted and categorized into 11 patterns described in Netter's Atlas of Human Anatomy.*

*Department of Anatomy, Faculty of Medicine, Chulalongkorn University

- Results** : *The most common pattern was the common origin of the right colic and middle colic arteries which was different from the previous report. The branch from the middle colic artery to left colic flexure (Pattern 6) was observed with much higher frequency than in the previous study. Arch of Riolan was found in 6 % of the cadavers and the middle colic artery from the celiac trunk was also observed.*
- Conclusion** : *This study showed some differences between Thai and western subjects in the anatomical variations of the colic arteries from the superior mesenteric artery. These data will be useful for performing colon surgery in Thai patients.*
- Keywords** : *leocolic artery, Right colic artery, Middle colic artery, Anatomical variation.*

Reprint request : Karnjanasilp P. Department of Anatomy, Faculty of Medicine,
Chulalongkorn University, Bangkok 10330, Thailand.

Received for publication : June 29, 2004.

ประพนธ์ กาญจนศิลป์, สุรพร ก้อนทอง, ธนศิลป์ หวลมานพ, สิทธิพร แยกทอง, วิไล ชินธเนศ.
ความผันแปรทางกายวิภาคของหลอดเลือดแดง colic ที่เป็นแขนงของหลอดเลือดแดง superior
mesenteric. จุฬาลงกรณ์เวชสาร 2547 ก.ค; 48(7): 465 - 71

- เหตุผลการทำวิจัย** : ในปัจจุบันยังขาดข้อมูลเกี่ยวกับความผันแปรทางกายวิภาคของหลอดเลือดแดง colic ในคนไทย เนื่องจากการผ่าตัดลำไส้ใหญ่ยังมีความสำคัญอยู่ ดังนั้นการศึกษาในเรื่องดังกล่าวจึงมีความจำเป็น
- วัตถุประสงค์** : เพื่อศึกษาความผันแปรทางกายวิภาคของหลอดเลือดแดง ileocolic, right colic และ middle colic ในศพของคนไทย
- สถานที่ทำการศึกษา** : ภาควิชากายวิภาคศาสตร์ คณะแพทยศาสตร์ จุฬาลงกรณ์มหาวิทยาลัย
- รูปแบบการวิจัย** : การศึกษาเชิงพรรณนา
- ตัวอย่างที่ใช้ศึกษา** : ศพของคนไทย 100 ศพที่ได้รับการอุทิศให้กับภาควิชากายวิภาคศาสตร์ คณะแพทยศาสตร์ จุฬาลงกรณ์มหาวิทยาลัย ในช่วงปี 2001 ถึง 2003
- วิธีการศึกษา** : ทำการผ่าตัดเปิดช่องท้องและเลาะหาหลอดเลือดแดง ileocolic, right colic และ middle colic จากนั้นทำการบันทึกการมีอยู่และจุดกำเนิดของหลอดเลือดแดงดังกล่าวและจัดเป็นรูปแบบทั้งหมด 11 แบบตามที่ใช้ในหนังสือ Netter's Atlas of Human Anatomy
- ผลการศึกษา** : รูปแบบที่พบมากที่สุดในการศึกษานี้คือ การมีจุดกำเนิดร่วมกันของหลอดเลือดแดง right colic และ middle colic ซึ่งแตกต่างกับผลการศึกษาก่อนหน้านี้ นอกจากนี้ยังพบแขนงของหลอดเลือดแดง middle colic ไปทาง colic flexure ช้างซ้ายมากกว่าในรายงานในอดีต ส่วน Arch of Riolan พบได้ 6% และยังพบว่าในบางศพมีจุดกำเนิดของหลอดเลือดแดง middle colic จาก celiac trunk
- สรุป** : การศึกษานี้พบว่าความผันแปรทางกายวิภาคของหลอดเลือดแดง colic เหล่านี้ในศพของคนไทยมีความแตกต่างหลายประการจากชาวตะวันตก ข้อมูลเหล่านี้จะเป็นประโยชน์ต่อการผ่าตัดลำไส้ใหญ่ต่าง ๆ
- คำสำคัญ** : หลอดเลือดแดง ileocolic, หลอดเลือดแดง right colic, หลอดเลือดแดง middle colic, ความผันแปรทางกายวิภาค

Nowadays, operations of the colon are among common procedures performed by surgeons, for example, resection of the colon which is done as a curative or palliative treatment for colon cancers. The extent of colonic resection is largely determined by the blood vessels in order to remove the lymphatic drainage from the tumor-containing part of the colon. Another instance is colonic interposition which is employed to replace the removed esophagus in patients suffering from esophageal cancers. The anatomy of blood vessels must be considered in this case as well. Therefore, the knowledge in the anatomy of colonic blood supply, especially arterial system, is essential in performing these life-saving operations. The surgeons have to keep in mind not only the normal anatomy, but also the variations of colonic arteries.

Since the extensive study of colonic artery variations by Sonneland and colleagues in 1958⁽¹⁾, in which specimens from 600 bodies were examined, there have been only some small reports of aberrant colonic arteries, for example, the anomalous middle colic artery from the proximal segment of the splenic artery⁽²⁾ and the middle colic artery from abdominal aorta (middle mesenteric artery).⁽³⁾ Moreover, there were no such studies in Thai population. Due to the possibility of different anatomical variations between the Thai and westerners, the study of the anatomy of colonic arteries in Thai population should be done. Hence, this study was carried out to serve this purpose.

Materials and Methods

One-hundred Thai cadavers collected at the Department of Anatomy, Faculty of Medicine, Chulalongkorn University were used in this study. The

existence and origins of the middle colic, right colic and ileocolic arteries were noted and reported according to the patterns shown in the standard anatomy atlas, Netter's Atlas of Human Anatomy.⁽⁴⁾ This study was started in 2001 and finished in 2003.

Results

According to Netter's Atlas, there are 11 recognized patterns of the variations of the colic arteries (Table 1 and Fig.1). We found 14 cadavers (14 %) with Netter's Pattern 1 (Table 1). Common origin of the right colic and middle colic arteries (Pattern 2) was the most frequently found pattern, observed in 28 cadavers (28 %). Pattern 6 was observed with less frequency (18 %). Pattern 3,5 and 7 were found with similar incidences (8,9 and 10 cadavers, respectively). Arch of Riolan (Pattern 8) was identified in 6 cadavers. The patterns with the least frequencies were Pattern 4 and 10 (3 and 4 cadavers, respectively). Pattern 9 and 11 were not found in this study. No new variation compared to Netter's Atlas was identified in our specimens.

Discussion

The most frequently found pattern in this study was Pattern 2 (28 %) which had a common trunk for the right colic and middle colic arteries. This is in contrast to the report of Sonneland and colleagues where separate origins of right colic, middle colic and ileocolic arteries (Pattern 1) were observed with the highest incidence (23.8 %).⁽¹⁾ Moreover, the incidences of Pattern 1 and 3 were much lower in our study (14 % and 8 %, respectively) compared to those of Sonneland⁽¹⁾ (23.8 % and 22.7 %, respectively). This may be of clinical interest as the middle colic

Table 1. Variation patterns of the colic arteries in this study compared with those in Sonneland et al.⁽¹⁾

Pattern Description	Percentage of cases	
	Sonneland	This study
1 Right colic, middle colic and ileocolic arteries have their own origins	23.8	14
2 Common origin of right colic and middle colic arteries	21.5	28
3 Common origin of right colic and ileocolic arteries	22.7	8
4 Absence of middle colic artery, replaced by the branch from left colic artery	3.6	3
5 Absence of right colic artery	12.4	9
6 Branch from middle colic artery to left colic (splenic) flexure	0.4	18
7 Accessory middle colic artery to left colic (splenic) flexure	NM	10
8 Arc of Riolan between middle colic and left colic arteries	NM	6
9 Discontinuity of marginal artery between right colic and ileocolic arteries	NM	0
10 Middle colic artery originating from celiac trunk via dorsal pancreatic artery	0	4
11 Middle colic artery gives origin to dorsal pancreatic artery	NM	0
Total no. of cases	600	100

NM = Not mentioned

artery cannot be divided close to the superior mesenteric artery in the Thai more than in western patients. Regarding Pattern 6, we observed a much higher percentage relative to what was reported in the same study⁽¹⁾ (18 % and 0.4 %, respectively). In addition, we found 4 % of our cadavers with Pattern 10 which was not seen in any cadaver in Sonneland's study.⁽¹⁾ These inconsistencies may be due to the differences in the races of cadavers used.

Despite these several differences, there were some similarities in the variations of colic arteries. The frequencies of Pattern 2 in the above study and ours were not much different (21.5 % and 28 %, respectively). The absence of middle colic artery (Pattern 4) was seen in 3 % of our cadavers which was similar to what was previously reported by Sage and co-workers⁽⁵⁾ (5 %), and Sonneland and

colleagues⁽¹⁾ (3.6 %). In contrast, our figure of 3 % was slightly higher than that of Garcia-Ruiz and colleagues' report⁽⁶⁾ (6 %). Moreover, the frequency of the absence of right colic artery (Pattern 5) in this study (9 %) was comparable to that observed in Sonneland's study⁽¹⁾ (12.4 %). Our percentage of the presence of Riolan's arch (6 %) was also similar to what was reported by Renner's group⁽⁸⁾ (9.6 %). These data are clinically important since radical high ligation of the inferior mesenteric artery can be done with less effects on the viability of the descending colon if this arch is present.⁽⁹⁾

It is worth noting that we did not find the middle mesenteric artery arising from the aorta and supplying the transverse colon which is an extremely rare anomaly, only reported by two studies.^(3,7)

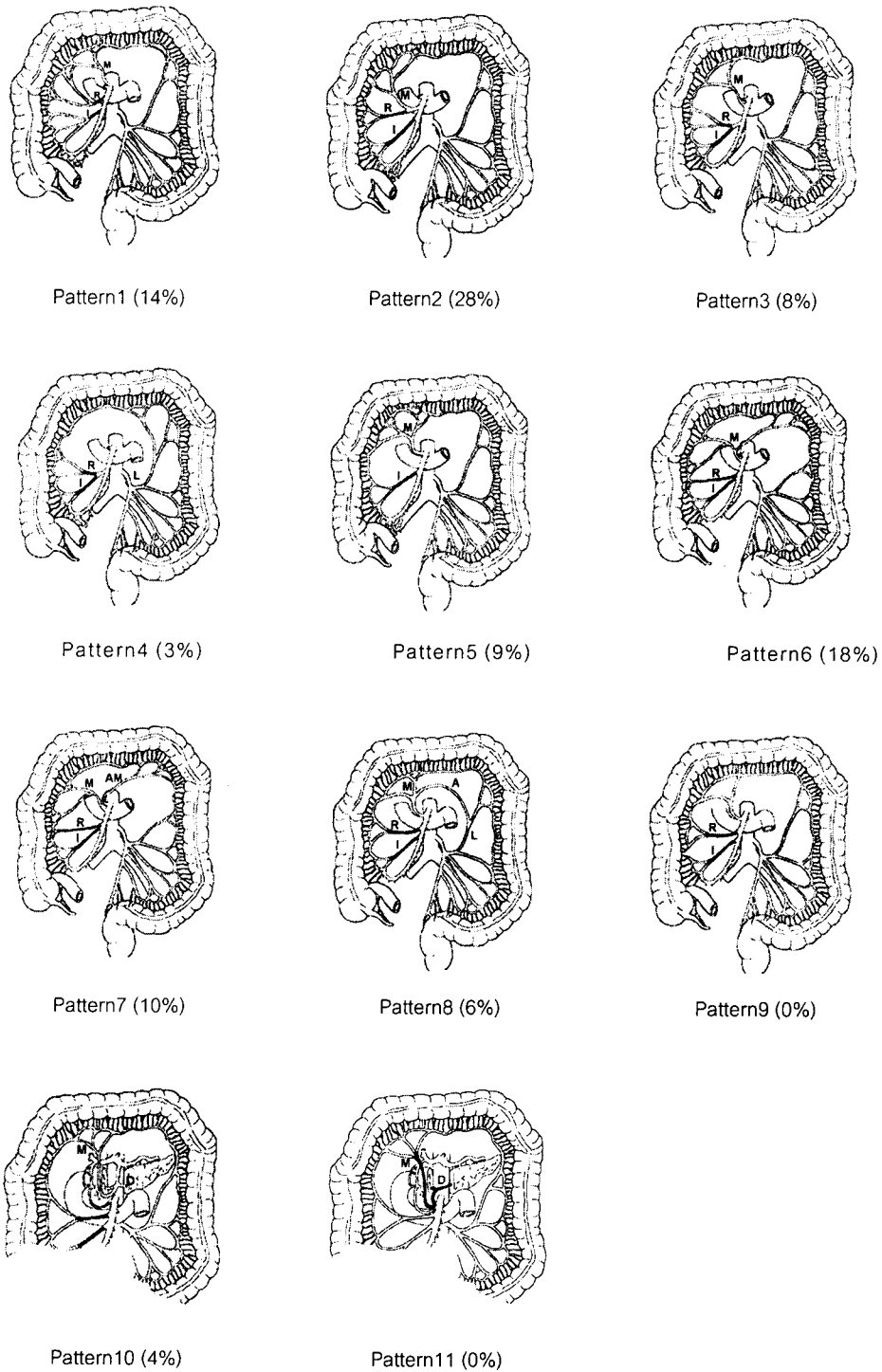


Figure 1. Eleven patterns of colic arteries I = Ileocolic artery, R = Right colic artery, M = Middle colic artery, L = Left colic artery, A = Arch of Riolan, D = Dorsal pancreatic artery, AM = Accessory middle colic artery (modified from Netter's atlas⁽⁴⁾)

In conclusion, in this study, we found that several anatomical variations of colic arteries in Thais had different incidences compared to the previous studies which based on different population. Some variations are likely of clinical interest for example, when truly radical right hemicolectomy is desired. Therefore, our data indicate that these anatomical variations of colic arteries should be concerned when colon surgery is to be performed in Thai subjects.

References

1. Sonneland J, Anson BJ, Beaton LE. Surgical anatomy of the arterial supply to the colon from the superior mesenteric artery based upon a study of 600 specimens. *Surg Gyn Obst* 1958 April;106(4): 385 - 98
2. Amonoo-Kuofi HS, el-Badawi MG, el-Naggat ME. Anomalous origins of colic arteries. *Clin Anat* 1995;8(4):288-93
3. Yoshida T, Suzuki S, Sato T. Middle mesenteric artery: an anomalous origin of a middle colic artery. *Surg Radiol Anat* 1993;15(4): 361 - 3
4. Netter FH. Abdomen. In: Colacino S, ed. *Atlas of Human Anatomy*. Hong Kong: CIBA-GEIGY, 1993: 291 - 2
5. Sage M, Calmat A, Leguerrier A, Honnart F, Cabrol C, Guerin-Surville H. Vascularization of the transverse colon. *Bull Assoc Anat (Nancy)* 1977 Sep;61(174): 397 - 406
6. Garcia-Ruiz A, Milsom JW, Ludwig KA, Marchesa P. Right colonic arterial anatomy. Implications for laparoscopic surgery. *Dis Colon Rectum* 1996 Aug; 39(8): 906 - 11
7. Koizumi J, d'Othee BJ, Otal P, Rousseau H, Joffre F, Kohda E, Hiramatsu K. Middle mesenteric artery visualized by computed tomographic angiography. *Abdom Imaging* 1999 Nov-Dec; 24(6): 556 - 8.
8. Renner K, Ausch C, Rosen HR, Perik E, Hochwarter G, Schiessel R, Firbas W. Collateral circulation of the left colon: historic considerations and actual clinical significance *Chirurg* 2003 Jun; 74(6): 575 - 8
9. Morgan CN, Griffiths JD. High ligation of the inferior mesenteric artery during operations for carcinoma of the distal colon and rectum. *Surg Gynecol Obstet* 1959 Jun;108(6): 641 - 50