

4-1-2005

Hernia uteri inguinalis with calcified fibroma of ovary in male: A case report

M. Phattharathieanon

Follow this and additional works at: <https://digital.car.chula.ac.th/clmjournal>



Part of the [Medicine and Health Sciences Commons](#)

Recommended Citation

Phattharathieanon, M. (2005) "Hernia uteri inguinalis with calcified fibroma of ovary in male: A case report," *Chulalongkorn Medical Journal*: Vol. 49: Iss. 4, Article 6.

DOI: 10.58837/CHULA.CMJ.49.4.6

Available at: <https://digital.car.chula.ac.th/clmjournal/vol49/iss4/6>

This Case Report is brought to you for free and open access by the Chulalongkorn Journal Online (CUJO) at Chula Digital Collections. It has been accepted for inclusion in Chulalongkorn Medical Journal by an authorized editor of Chula Digital Collections. For more information, please contact ChulaDC@car.chula.ac.th.

Hernia uteri inguinalis with calcified fibroma of ovary in male : A case report

Mongkhon Phattharathiwanon*

Phattharathiwanon M. Hernia uteri inguinalis with calcified fibroma of ovary in male : A case report. Chula Med J 2005 Apr; 49(4): 241 - 5

Hernia uteri inguinalis (also known as Persistent Mullerian Duct Syndrome) is extremely rare, In this case, a 51 year-old man with the complaint of painful swelling of the right scrotal sac and inguinal region was operated on under the suspicion of having right incarcerated hernia. A standard oblique inguinal incision was performed. The hernial sac contained with uterus, right uterine tube (sliding hernia type) and left ovarian tumour (intraperitoneal part). Hysterectomy with bilateral salpingo-oophorectomy and herniorrhaphy was made through the inguinal incision, To our knowledge, this is the first case reported of Hernia uteri inguinalis with calcified fibroma of ovary in male.

Keywords : *Hernia uteri inguinalis, calcified fibroma of ovary, Persistent Mullerian Duct Syndrome.*

Reprint request : Phattharathiwanon M. Department of Surgery, Sisaket Hospital,
Sisaket Province, Thailand 33000.

Received for publication. December 21, 2004.

* Department of Surgery, Sisaket Hospital, Sisaket Province, Thailand.

มงคล ภัทรทิวานนท์. Hernia uteri inguinalis ร่วมกับเนื้องอกรังไข่ชนิด calcified fibroma ในผู้ป่วยชาย : รายงานผู้ป่วยกรณีศึกษา. จุฬาลงกรณ์เวชสาร 2548 เม.ย; 49(4): 241 – 5

รายงานกรณีศึกษาผู้ป่วย 1 รายมีลักษณะทางเพศภายนอกเป็นชาย อายุ 51 ปี มาโรงพยาบาลด้วยอาการปวดบวมและมีก้อนที่ขาหนีบขวา ลักษณะเป็นได้เลื่อนชนิดอุดตัน หลังจากทำการผ่าตัดพบว่าเป็นได้เลื่อนชนิด sliding ประกอบด้วยมดลูกและรังไข่ขวาบริเวณที่ผ่าตัดและเนื้องอกรังไข่ภายในช่องท้อง ได้ให้การรักษาโดยผ่าตัดมดลูก รังไข่และเย็บซ่อมผนังหน้าท้องทางแผลบริเวณขาหนีบขวา ผลการตรวจชิ้นเนื้อของรังไข่ซ้ายเป็น calcified fibroma ซึ่งเป็นผู้ป่วยรายแรกที่ได้รับการรักษาและรายงาน

คำสำคัญ : *Hernia uteri inguinalis, เนื้องอกรังไข่ชนิด calcified fibroma, Persistent Mullerian Duct syndrome*

Case Report

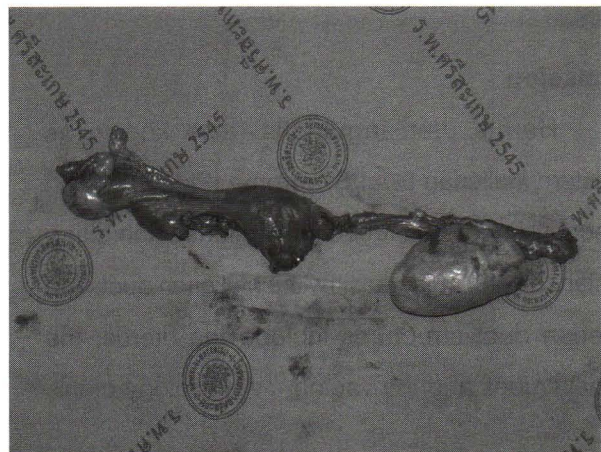
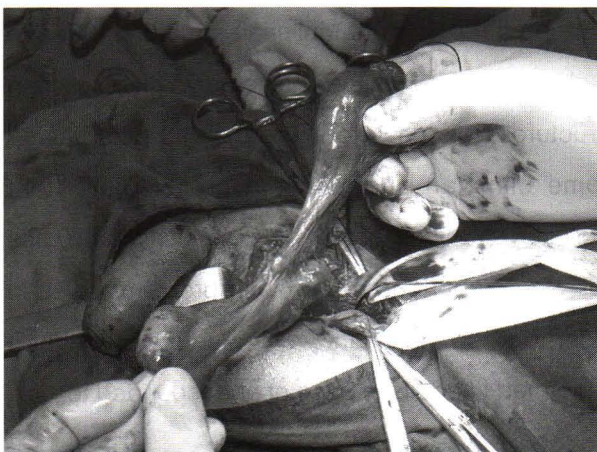
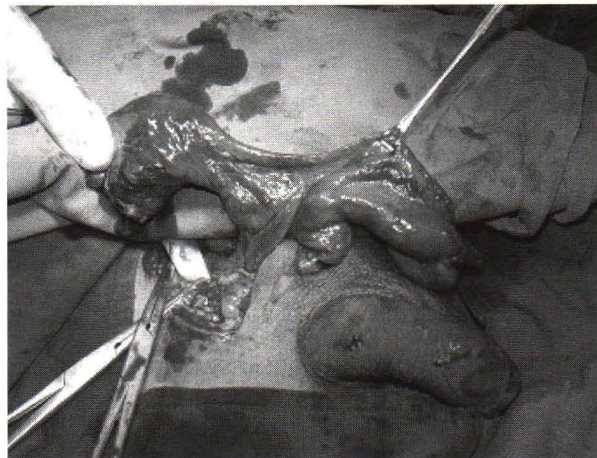
A 51 year-old man was referred to the emergency room complaining of painful swelling of the right scrotal sac and the inguinal region 2 days prior to admit. He was classified as American Society of Anesthesiologist I. Past medical history was no contributory; he had no history or evidence of trauma or infertility.

On physical examination, his vital signs were stable. The abdomen was soft and not tender. There was an obvious painful swelling of the right scrotal sac and the inguinal region and normally male secondary sex characteristics, But the right scrotum was not palpable. He was resuscitated with

intravenous fluids being taken to the operating room. Since the preoperative diagnosis was right incarcerated hernia, the patient was given prophylactic antibiotics.

After standard oblique inguinal incision was performed, the hernial sac which was found to contain an immature uterus and right uterine tube, Atrophic testis, (sliding hernia type), The uterus was measuring $3.5 \times 3 \times 2 \text{ cm}^3$. Its endometrium was 0.2 cm. Thick : myometrium 1 cm; the attached ovary $2 \times 1 \times 1 \text{ cm}^3$. Left uterine tube with $6 \times 3.5 \times 3 \text{ cm}^3$. ovarian tumor (intraperitoneal part) diameter, The uterus was excised and bilateral salpingo-oophorectomy and hemiorrhaphy were made through the inguinal incision.

Gross pathology and intraoperative part as figure



The picture shows male secondary sex characteristic and hernia uteri inguinalis with calcified mass of left ovary with testicular atrophy.

Postoperatively he made unevenful recovery and was discharged 3 days later, During his revisit to the Out-patient Department one month later, he was found healthy.

Surgical pathology report :

Microscopic finding : section of ovarain nodule composed of atrophic hyarinizes semiferous tubules with clusters of leydig's cells. Section of structure resembling fallopian tube show epididymis with dilated ducts.

Sections of separated mass composed totally of hyalinized collagenised tissue with extensive calcification. No ovarian tissue seen.

Diagnosis : Uterus with one adnexa

- weakly proliferative endometrium.
- unremarkable myometrium.
- attached adnexae composed of atrophic testis with dilated epididymis.

Separated mass

- totally calcified mass, probably calcified fibroma of ovary.

Discussion

Hernia uteri inguinalis (also known as Persistent Mullerian Duct Syndrome (PMDS)) which cause by impaired action of Mullerian Inhibiting Substance (MIS) in regreasithy the Mullerian duct. The Mullerian duct structures include the uterus, the fallopain tubes and the vagina.⁽¹⁾ An etiology of this

syndrome may be genetically inherited either by autosomal recessive genes with sex limitation or X-linked recessive mutation.⁽²⁾

Preoperative diagnosis of hernia uteri inguinalis is difficult. Various organs have been found in indirect inguinal sac, but the presence of uterus in inguinal hernia in male has only rarely been first described by Nilson 1939.⁽³⁾ He described three main types of hernia uteri inguinalis, namely:-

Type I the uterus and adnexa of both sides are present in the hernia.

Type II the uterus and adnexa on oneside are contained in the hernia and the adnexa on the other side remain in the peritoneal cavity.

Type III a unicornuate uterus, or one horn of a bicornuate uterus, with its corresponding adnexa are contained in the hernia.⁽³⁾

The possibility of this type of intersex abnormality is not normally considered until laparotomy or repair of a hernia reveals the abnormality, Nilson, however, suggested that it should be possible to diagnose hernia uteri inguinalis preoperatively by bimanual examination. However, the rare condition is not known to the surgeon and it was not kept in mind then that diagnosis might be possible. The treatment is controversial with most clinicians recommending excising the persistent Mullerian structures but due to close location with the vas deferens and Mullerian structures, it is easy to injure the vas deferens.⁽²⁻⁵⁾ Some clinician suggest leaving the persistent Mullerian structures intact because malignancy has not been reported and no such problems exist, in order to avoid malignancy orchidectomy should be performed in adults in case of undescended testis.

Conclusion

A case of Type II hernia uteri inguinalis (Nilson 1939) that occurred in a phenotypically normal 51 year-old male but, to our knowledge, this is the first case report of hernia uteri inguinalis with calcified fibroma of ovary in male.

References

1. Sunpaweravong S, Pripatnanont C. Persistent Mullerian duct syndrome in adult: a case report. J Med Assoc Thai 2000 Dec; 83(12): 1541 - 3
2. Beheshti M, Churchill BM, Hardy BE, Bailey JD, Weksberg R, Rogam GF. Familial persistent mullerian duct syndrome. J Urol 1984 May; 131(5):968-9
3. Binns JH, Cross RM. Hernia uteri inguinalis in male. Br J Surg 1967 Jun; 54(6): 571 - 5
4. Loeff DS, Imbeaud S, Reyes HM, Meller JL, Rosenthal IM. Surgical and genetic aspects of persistent mullerian duct syndrome. J Pediatr Surg 1994 Jan; 29(1): 61 - 5.
5. Fernandes ET, Hollabaugh RS, Young JA, Wilroy SR, Schriock EA. Persistent mullerian duct syndrome. Urology 1990 Dec; 36(6): 516 - 8