

4-1-2006

Granuloma formation of lymph node in pulmonary alveolarproteinosis after therapeutic lung lavage

K. Kawkitinarong

T. Parimon

C. Chantranuwat

C. Sittipunt

Follow this and additional works at: <https://digital.car.chula.ac.th/clmjjournal>



Part of the [Medicine and Health Sciences Commons](#)

Recommended Citation

Kawkitinarong, K.; Parimon, T.; Chantranuwat, C.; and Sittipunt, C. (2006) "Granuloma formation of lymph node in pulmonary alveolarproteinosis after therapeutic lung lavage," *Chulalongkorn Medical Journal*: Vol. 50: Iss. 4, Article 4.

Available at: <https://digital.car.chula.ac.th/clmjjournal/vol50/iss4/4>

This Case Report is brought to you for free and open access by the Chulalongkorn Journal Online (CUJO) at Chula Digital Collections. It has been accepted for inclusion in Chulalongkorn Medical Journal by an authorized editor of Chula Digital Collections. For more information, please contact ChulaDC@car.chula.ac.th.

Granuloma formation of lymph node in pulmonary alveolar proteinosis after therapeutic lung lavage

Kamon Kawkitinarong* Tanyaluk Parimon*

Chawit Chantranuwat** Chanchai Sittipunt*

Kawkitinarong K, Parimon T, Chantranuwat C, Sittipunt C. Granuloma formation of lymph node in pulmonary alveolar proteinosis after therapeutic lung lavage. Chula Med J 2006 Apr; 50(4): 243 - 7

We hereby describe a case of pulmonary alveolar proteinosis (PAP) with symmetrical hilar lymphadenopathy that enlarged after lung lavage. Lymph node biopsy findings revealed granulomatous inflammation with negative microbiological studies. Our report shows that, lymph node enlargement, although it is rare, may be found in PAP, especially in severe cases. The pathogenesis of lymphadenopathy in this patient could be explained by excretion of excess surfactant via lymphatic system and immune restoration after treatment. To our knowledge, this is the first ever documented pathological case that shows granuloma formation after therapeutic lavage in PAP.

Keywords : Alveolar proteinosis, Lymph node enlargement, Granuloma.

Reprint request: Kawkitinarong K. Department of Medicine, Faculty of Medicine,
Chulalongkorn University, Bangkok 10330, Thailand.

Received for publication. November 1, 2005.

* Department of Medicine, Faculty of Medicine, Chulalongkorn University

** Department of Pathology, Faculty of Medicine, Chulalongkorn University

กมล แก้วกิติณรงค์, ธัญญลักษณ์ ปริมณ, ชวิษฐ์ จันทรานูวัฒน์, ฉันทชาย สิทธิพันธ์. การเกิด granuloma ของต่อมน้ำเหลืองในโรค pulmonary alveolar proteinosis หลังจากรับการรักษาด้วยการล้างถุงลมปอด. จุฬาลงกรณ์เวชสาร 2549 เม.ย; 50(4): 243 - 7

คณะผู้นิพนธ์ได้รายงานผู้ป่วยโรคอัลวีโอลาร์ โปรตีนโนซิสในปอดรายหนึ่ง ที่มีลักษณะพิเศษคือพบมีต่อมน้ำเหลืองโตที่ขั้วปอดทั้งสองข้าง ซึ่งโตขึ้นหลังการรักษาโดยการล้างถุงลมปอด ผลการตรวจทางพยาธิวิทยาชิ้นเนื้อต่อมน้ำเหลืองพบว่าการอักเสบและตรวจพบแกรนูโลมาร่วมด้วย โดยที่การตรวจทางจุลชีววิทยาทั้งหมดให้ผลลบ รายงานนี้ชี้ให้เห็นว่าภาวะต่อมน้ำเหลืองโตนั้นอาจพบได้ในโรคอัลวีโอลาร์ โปรตีนโนซิส โดยเฉพาะอย่างยิ่งในรายที่มีอาการรุนแรง การเกิดต่อมน้ำเหลืองโตในผู้ป่วยรายนี้อาจอธิบายได้จากการกำจัด surfactant ที่มากเกินไป โดยผ่านทางทางเดินน้ำเหลือง และการที่ภูมิคุ้มกันพื้นเป็นปกติหลังการรักษาด้วยการล้างปอด นับเป็น ผู้ป่วยรายแรกที่พบพยาธิสภาพแบบแกรนูโลมาภายหลังการรักษาโดยการล้างปอดในผู้ป่วยอัลวีโอลาร์ โปรตีนโนซิส

คำสำคัญ : อัลวีโอลาร์ โปรตีนโนซิส, ต่อมน้ำเหลืองโต, แกรนูโลมา.

Pulmonary alveolar proteinosis (PAP) is a rare parenchymal lung disease characterized by intra-alveolar accumulation of surfactant-like phospholipids and proteinaceous substance. Lung inflammation and fibrosis are rare and minimal. The patients usually present with progressive dyspnea on exertion of gradual onset and hypoxemia. Lymph node involvement has been reported in only few cases without pathologic finding shown.⁽¹⁾

Case Report

In February 2002, a 22-year-old woman presented at King Chulalongkorn Memorial Hospital with exertional dyspnea for one year. She had no past medical illness and did not smoke. One year before the admission, she had dry cough and breathless during vigorous housework. Two months before the

admission her dyspnea deteriorated. On examination, the patient was tachypneic with respiration of 30, pulse rate 108/min, temperature 36.8 °C and blood pressure 120/70 mmHg. Chest auscultation revealed mild fine crepitation on both lungs. She had no cyanosis and no digital clubbing. Chest radiograph showed diffuse alveolar infiltrates. Interestingly, bilateral hilar lymph node enlargement was observed. Microbiological sputum analyses showed negative results on staining and culture. Spirometry results were as follows: FEV₁ 0.82 L (24.7 % predicted); FVC 0.82 L (21.0 % predicted); TLC could not be performed due to unfavorable status of the patient. ABG measurements (room air) were: pH 7.35; PaCO₂ 35 mmHg; PaO₂ 52 mmHg ; and oxygen saturation 89 %. High resolution CT scans of the thorax showed "crazy paving" pattern, characteristic of PAP (Figure 1A). Mediastinal lymph

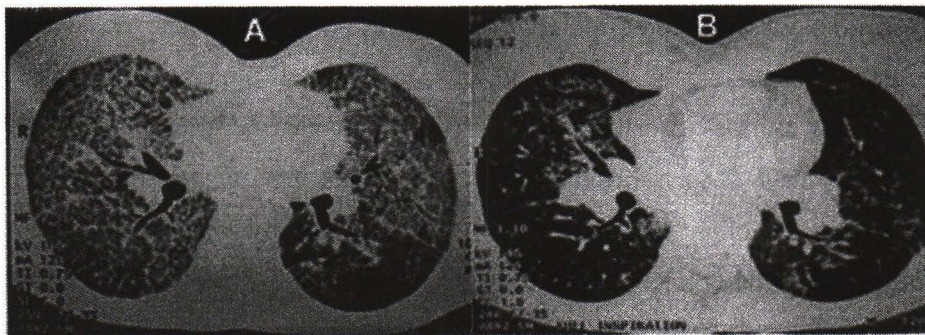


Figure 1. High-resolution CT scan of the thorax in this patient.

- A. Before whole lung lavage. Diffuse ground glass appearance superimposed with fine reticular opacity producing "crazy paving" pattern with hilar lymphadenopathy was observed.
- B. Two weeks after bilateral whole lung lavage. Marked clearing of parenchymal infiltrates but increased size of hilar lymph nodes was noted.

Declaration of interest and consent

We declare no competing interest and receive patient's consent to disclose this information for publication.

node enlargement was confirmed by CT scans. Bronchoalveolar lavage and transbronchial biopsy were performed and the pathological findings showed eosinophilic granular material with PAS-positive and diastase resistant filling in the alveoli that was consistent with alveolar proteinosis.

The patient underwent whole lung lavage twice separately without any complication. Two weeks after discharge, her dyspnea improved markedly and her exercise capacity nearly returned to normal. However, low-grade fever persisted. Chest radiographs and high resolution CT scan showed resolution of infiltrates in both lungs. However, both hilar nodes were more predominant (Figure 1B). As hematological malignancy associated with PAP was considered, the patient was preceded to mediastinoscopy and lymph nodes sampling. The pathological findings revealed caseating granulomas with negative acid fast staining (Figure 2). All microbiological cultures including mycobacterial culture were negative. PCR for *M. Tuberculosis* was negative skin testing for tuberculosis revealed negative result. Without receiving any treatment, she returned to normal spirometry two months later, and no lymph node enlargement was then detected.

Discussion

We observed mediastinal lymph node enlargement and PAP in this patient. Although it is a rare presentation, the correlation could be explained by several mechanisms. In healthy adults, most of alveolar surfactant is taken into alveolar type II cells and reutilized to maintain surfactant storage.^(2,3) Ten to fifteen percent of alveolar surfactant is phagocytosed into alveolar macrophages and degraded; although the

amount is small, it is crucial into the loss of alveolar compartment. Macrophages can either migrate to ciliary airways for mucociliary clearance or enter the lymphatic circulation.⁽⁴⁾ The movement to the ciliated region, which is usually enhanced by differences in surface tension between the lower surface tension surfactant to the higher surface tension bronchial fluid, could be lessened by abnormal accumulation of surfactants in the alveoli and terminal bronchioles in PAP.^(2,3) Therefore, macrophages tend to enter to the lymphatics in this situation. Due to its abnormally large size, overfed macrophages migrate slowly leading to stagnation of macrophages in the pulmonary lymphatic system.⁽⁵⁾ Furthermore, in overloading state of macrophage, nonphagocytosed surfactants can be transported to lymphatic vessels and leads to lymphadenopathy.⁽⁵⁾ Interestingly, lymph node enlargement in PAP seems to be found in only severe cases. All three cases in the literature (including our case) have severe diseases.⁽¹⁾

After whole lung lavage, hilar lymph nodes enlarged and pathological findings demonstrated granulomatous inflammation. How do granulomas form in this case? Macrophages and key cytokines in granuloma formation including IFN γ , TNF α and GM-CSF^(6,7) are suppressed during active PAP disease.⁽⁸⁾ Additionally, an increase in total T-lymphocyte, CD4/CD8 ratio, and T-cell activation have been observed from PAP patients.⁽⁹⁾ After a lung lavage, pulmonary immune response and macrophage function recovered.⁽¹⁰⁾ Preformed activated T-cells may have released several cytokines that recruited macrophages and they played certain roles in granuloma formation in this case.

References

1. Usui Y, Takayama S, Nakayama M, Miura H, Kimula Y. Interstitial lattice shadow and mediastinal lymphadenopathy with an elevation of carcinoembryonic antigen in severe pulmonary alveolar proteinosis. *Intern Med* 1992 Mar;31(3):422-5
2. Notter RH. Discovery of endogenous lung surfactant and overview of its metabolism and actions. In: Claude Lenfant, exec. ed, Bland RD, Coalson JJ, eds *Lung Surfactants: Basic Science and Clinical Applications, Lung Biology in Health and Disease Series Vol. 149*. New York, NY: Marcel Dekker, 2000: 119-49
3. Yeates DB, Moetensen J. Deposition and clearance. In: Murray JF, Nadel JA, Mason RJ, Boushey HA, eds. *Textbook of Respiratory Medicine*, 3rd ed. Philadelphia, PA: WB. Saunders, 2000: 349-84
4. Lauweryns JM, Baert JH. Alveolar clearance and the role of pulmonary lymphatics. *Am Rev Respir Dis* 1977 Apr;115(4):625-83
5. Bolton RE, Vincent JH, Jones AD, Addison J, Beckett ST. An overload hypothesis for pulmonary clearance of UICC amosite fibers inhaled by rats. *Br J Ind Med* 1983 Aug;40(3): 264-72
6. Kobayashi K, Kaneda K, Kasama T. Immunopathogenesis of delayed-type hypersensitivity. *Microsc Res Tech* 2001 May 15;53(4):241-5
7. Bergeron A, Bonay M, Kambouchner M, Lecossier D, Riquet M, Soler P, Hance A, Tazi A. Cytokine patterns in tuberculous and sarcoid granulomas: correlations with histopathologic features of the granulomatous response. *J Immunol* 1997 Sep 15;159(6):3034-43
8. Shibata Y, Berclaz PY, Chroneos Z, Yoshida M, Whitsett JA, Trapnell BC. GM-CSF regulates alveolar macrophage differentiation and innate immunity in the lung through PU.1. *Immunity* 2001 Oct;15(4):557-67
9. Milleron BJ, Costabel U, Teschler H, Ziesche R, Cadranel JL, Matthys H, Akoun GM. Bronchoalveolar lavage cell data in alveolar proteinosis. *Am Rev Respir Dis* 1991 Dec; 144(6):1330-2
10. Hoffman RM, Dauber JH, Rogers RM. Improvement in alveolar macrophage migration after therapeutic whole lung lavage in pulmonary alveolar proteinosis. *Am Rev Respir Dis* 1989 Apr;139(4):1030-2