

11-1-1997

## DNA proliferation indices in papillary immaturemetaplasia of the cervix

Prasert Trivijitsilp

CP Crum

Follow this and additional works at: <https://digital.car.chula.ac.th/clmjournal>



Part of the [Medicine and Health Sciences Commons](#)

---

### Recommended Citation

Trivijitsilp, Prasert and Crum, CP (1997) "DNA proliferation indices in papillary immaturemetaplasia of the cervix," *Chulalongkorn Medical Journal*: Vol. 41: Iss. 11, Article 5.

DOI: 10.58837/CHULA.CMJ.41.11.3

Available at: <https://digital.car.chula.ac.th/clmjournal/vol41/iss11/5>

This Article is brought to you for free and open access by the Chulalongkorn Journal Online (CUJO) at Chula Digital Collections. It has been accepted for inclusion in Chulalongkorn Medical Journal by an authorized editor of Chula Digital Collections. For more information, please contact [ChulaDC@car.chula.ac.th](mailto:ChulaDC@car.chula.ac.th).

## DNA proliferation indices in papillary immature metaplasia of the cervix

Prasert Trivijitsilp\*

Crum CP.\*\*

Trivijitsilp P, Crum CP. DNA proliferation indices in papillary immature metaplasia of the cervix. *Chula Med J* 1997 Nov; 41(11): 805-13

**Background** : Papillary immature metaplasia (PIM) is manifested as an immature metaplasia with filiform papillae, variable cytologic atypia and frequently extension into the endocervical canal. It must be distinguished from low and high grade squamous intra-epithelial lesions (LSIL and HSIL). DNA proliferation indices by Ki-67 immunostaining may be helpful in diagnosis of these lesions. The association of these lesions with Human papilloma virus type 6/11 has been reported.

**Method** : We compared the distribution and intensity of Ki-67 immunostaining between 10 cases each of PIM, LSIL and HSIL. Human papilloma virus (HPV) typing was performed by polymerase chain reaction and restriction fragment length polymorphism in the PIM cases.

**Result** : All ten cases of PIM displayed homogeneous staining of Ki-67 in variable numbers of nuclei in the lower epithelial strata with progressive reduction in the superficial epithelium. This was similar to the distribution in adjacent metaplasia. In contrast, HSIL displayed more intense staining in a higher proportion of cells of all epithelial layers. Staining in LSIL was similar to PIM, except for focally intense staining in upper cell layers, predominantly in koilocytes. Seven of ten cases of PIM were HPV type 6/11 positive.

\* Department of Obstetrics and Gynecology, Faculty of Medicine, Chulalongkorn University.

\*\* Department of Pathology, Brigham and Women's Hospital, Boston, Massachusetts, USA.

**Conclusion** : *The marked reduction in Ki-67 staining of superficial cell layers distinguishes PIM from many cases of LSIL which have focally intense staining in koilocytes. The low level of immunopositivity in superficial cells is in sharp contrast to HSIL and may serve to distinguish not only PIM but also other immature benign proliferations in the cervical transformation zone from HSIL. We also demonstrated the association of PIM and human papilloma virus type 6/11 which are low virulent groups.*

**Key words** : *Ki-67, papillary immature metaplasia.*

Reprint request : Trivijitsilp P, Department of Obstetrics and Gynecology, Faculty of Medicine, Chulalongkorn University, Bangkok 10330, Thailand.

Received for publication. September 15, 1997.

ประเสริฐ ตรีวิจิตรศิลป์, Christopher Paul Crum. ผลของ DNA proliferation indices ในพยาธิสภาพ Papillary immature metaplasia ของปากมดลูก. จุฬาลงกรณ์เวชสาร 2540 พ.ย; 41(11): 805-13

- วัตถุประสงค์** : เพื่อเปรียบเทียบความเข้มข้นและลักษณะการติดสีจากการย้อมตรวจหา DNA proliferation indices (Ki-67) ในพยาธิสภาพ Papillary immature metaplasia (PIM) ของปากมดลูกกับ low and high grade squamous intra-epithelial lesion (LSIL and HSIL) และตรวจหาความสัมพันธ์ระหว่าง PIM กับการติดเชื้อและชนิดของไวรัส human papilloma
- สถานที่ที่ทำการศึกษา** : หน่วยพยาธิวิทยาระบบอวัยวะสืบพันธุ์สตรี ภาควิชาพยาธิวิทยา Brigham and Womens Hospital
- วิธีการศึกษา** : เปรียบเทียบความเข้มข้นและลักษณะการติดสีภายหลังจากการย้อม Ki-67 ใน PIM, LSIL และ HSIL อย่างละ 10 ราย และตรวจหาไวรัส human papilloma (HPV) ใน PIM โดยปฏิกิริยาโพลีเมอเรส และ restriction fragment length polymorphism
- ผลการศึกษา** : ลักษณะการติดสีภายหลังย้อม Ki-67 ใน PIM พบว่ามีเฉพาะบริเวณชั้นล่างสุดของผิวเนื้อปากมดลูก และลดลงอย่างมากที่ผิวด้านบน ซึ่งแตกต่างจาก HSIL ที่ติดสีค่อนข้างเข้มเกือบตลอดผิวเนื้อ ส่วน LSIL จะติดสีคล้าย PIM แต่ด้านบนยังติดสีในเซลล์ koilocytes การตรวจหาไวรัส HPV จะพบชนิด 6/11 จำนวน 7 รายใน 10 ราย ของ PIM
- สรุป** : ลักษณะการย้อม Ki-67 ใน PIM จะมีการติดสีน้อยมากที่บริเวณผิวด้านบนซึ่งแตกต่างจาก HSIL และ LSIL จึงอาจนำเอาการย้อม Ki-67 มาช่วยวินิจฉัยแยกโรค PIM จาก HSIL และ LSIL ยังพบว่า PIM มีความสัมพันธ์กับการติดเชื้อไวรัส human papilloma โดยเฉพาะชนิด 6/11

The Bethesda system (1991) for cervical cytologic report has produced two-grading category of cervical intra-epithelial neoplasia (CIN) of cervix as low-grade squamous intra-epithelial lesion (LSIL = condyloma acuminata plus CIN I) and high-grade squamous intra-epithelial lesion (HSIL = CIN II plus CIN III). The criteria for distinction between LSIL and HSIL of cervix focuses principally on the degree of maturation and cytological atypia in the abnormal epithelium. In general, the progress decrease in maturation with correspond with an increase in cytologic atypia.<sup>(1, 2)</sup> Some lesions display a disparity between maturation and cytological atypia, demonstrating a progressive decrease in maturation without a corresponding increase in cytological atypia.<sup>(3)</sup> However, these processes may manifest as immature or metaplastic epithelium with varying degrees of cytological atypia.<sup>(4)</sup> A portion of these lesions that appears to have sufficient atypia to warrant classification as a squamous intra-epithelial lesion (versus an inflammatory or reactive process) has been previously termed atypical immature metaplasia. Crum et al. applied this term to a morphological variant of benign-appearing cervical condyloma involving immature metaplastic epithelium.<sup>(4)</sup> Ward et al. designated these lesion as papillary immature metaplasia (PIM) which must be distinguished from LSIL and HSIL.<sup>(5)</sup> The association of PIM and human papilloma virus type 6/11 has been reported.<sup>(5)</sup>

DNA proliferation indices (Ki-67) is monoclonal antibodies reacting with a human

nuclear cell proliferation-associated antigen that is expressed in all active part of the cell cycle.<sup>(6)</sup> These antibodies of immunohistochemical study may provide one additional parameter for evaluating the proliferation of PIM, LSIL and HSIL to distinguish each lesion. In this study, we focused on the subset of exophytic lesions characterized by atypical metaplasia criteria of which we designated PIM. We compared the distribution and intensity of Ki-67 immunostaining of PIM with LSIL and HSIL. Human papilloma virus analysis by polymerase chain reaction (PCR) and restriction fragment length polymorphism (RFLP) was also done in PIM lesions.

## Materials and methods

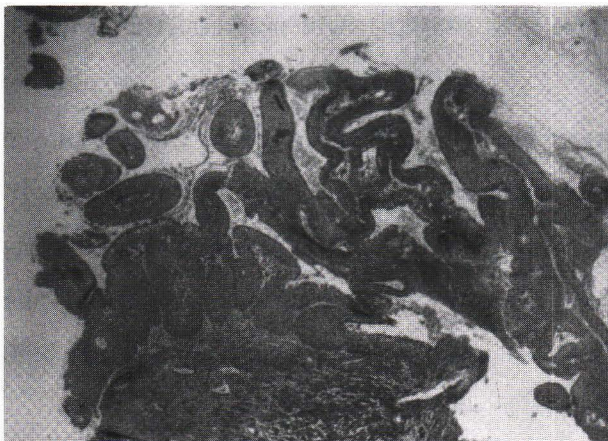The specimens were acquired from the files of the Women's and Perinatal pathology Division, Department of Pathology at the Brigham and Women's Hospital in the U.S.A. All biopsies were paraffin-embedded tissues which had been formalin-fixed for variable durations prior to processing. Hematoxylin and eosin stained tissues sections were screened for morphologic features correlating with the PIM, LSIL and HSIL categories. The diagnosis of PIM required a papillary or exophytic lesion with slender papillae, acanthotic immature metaplastic epithelium and increased cellularity but with mild nuclear atypia and a low mitotic index (figure 1.). The overlying columnar epithelium may be preserved in some areas, similar to conventional squamous metaplasia, but in PIM there was greater nuclear crowding, binucleate



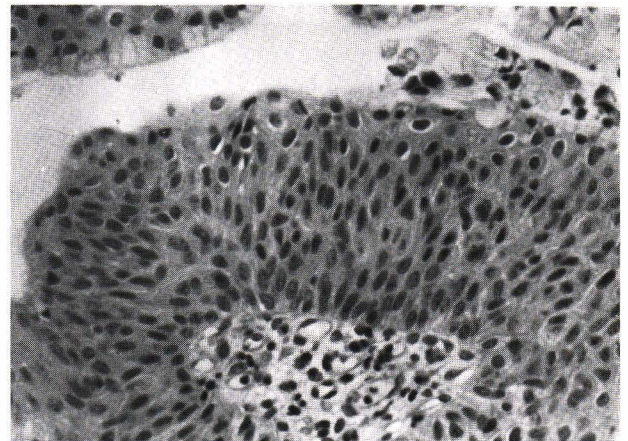
forms and anisonucleosis in the middle or upper epithelial layers (figure 2). In contrast with LSIL and HSIL, the nuclear atypia was mild, associated with uniform chromatin distribution and chromocenters, and increased in degree as a function of maturation, when present. LSIL and HSIL were

diagnosed by the usual criteria<sup>(7)</sup> (figure 3,4).

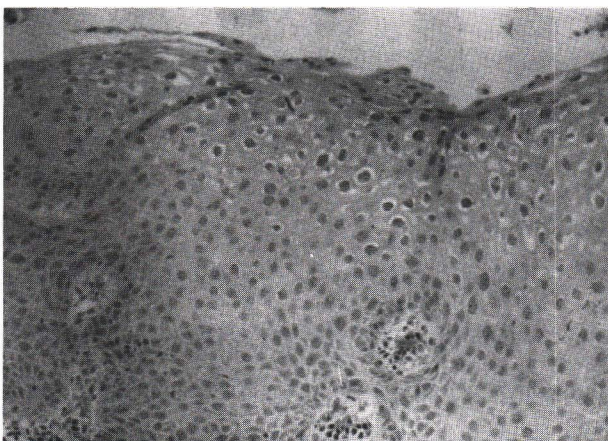
After selection of cases for each group, Ki-67 immunostaining with MIB-1 primary antibody was done in microwave-processed formalin-fixed paraffin sections as described by Cattoretti, et al,<sup>(6)</sup> and compared with the other cases.



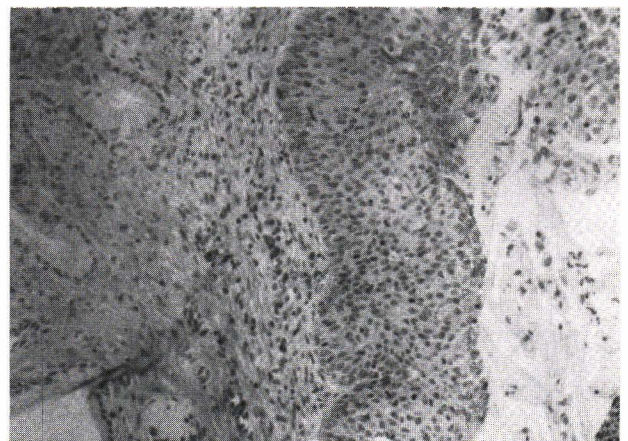
**Figure 1.** Low power micrograph of PIM shows papillary lesion with slender filiform papillae.



**Figure 2.** Higher magnification depicts proliferation of immature metaplastic cells with retention of endocervical cells (upper left corner)



**Figure 3.** H and E stain of LSIL displays typical abundant koilocytic atypia.



**Figure 4.** Low power of HSIL reveals greater heterogeneity in nuclear size, shape, spacing and chromatin pattern.

## Human Papillomavirus Analysis

For each case of PIM, four (6-micron) sections of each block were processed in a microcentrifuge tube and the DNA was extracted as previously described by Wright and Manos.<sup>(8)</sup> Using oligonucleotide primers flanking a 450-bp segment of the papillomavirus L1 open reading frame, a 2.5 micron aliquot of each sample was amplified by polymerase chain reaction as previously described by Manos et al.<sup>(9)</sup> Candidate positives were recognized as a 450-bp fragment visible by ethidium staining of 2.0% agarose gels. The presence of HPV was confirmed in each case following reamplification of the original DNA in the presence of 32 p-labeled dCTP. The radiolabeled reaction product was digested with Pst I, Rsa I and Hae III as previously described by Lungu, et al.<sup>(10)</sup> Five microliters of each digestion were loaded on an 8% polyacrylamide gel, electrophoresed overnight, vacuum dried, and exposed to x-ray film for 4 to 8 hours. Restriction digest products were sized and an HPV type was assigned based on the types for which information was available.<sup>(10)</sup>

Two address potential contamination procedures were followed: the first was designed to minimize contamination and the second was designed to maximize identification of contaminants. In the first procedure, all PCR reagents were prepared in a biologic safety hood apart from areas where template DNA was handled. All reagents were pretested by PCR to exclude potential contaminants. In the second procedure, every fifth paraffin block section consisted of paraffin alone and was assessed in the initial screening by PCR analysis.

## Result

### Ki-67 (Immunostaining)

Thirty biopsies were evaluated using the criteria outlined in "Materials and Methods" Ten cases were classified as PIM, 10 as LSIL and 10 as HSIL.

The Ki-67 stainings in PIM cases were homogeneous in variable numbers of nuclei in the lower epithelial strata with progressive reduction in the superficial epithelium, similar to adjacent metaplasia (figure 5). In contrast, HSIL displayed more intense staining in a higher proportion of cells in all layers of the epithelium (figure 6). Staining in LSIL was similar to PIM, except for focally intense staining in upper cell layers, predominantly in koilocytes (figure 7).

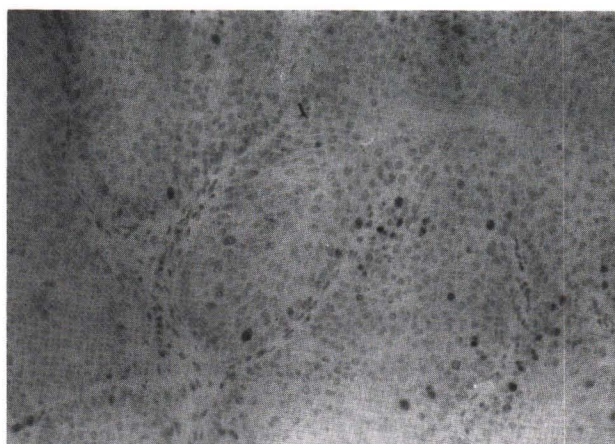
### HPV type in PCR and RFLP

The PCR product from seven of the ten cases of PIM lesions were positive by detection of a 450-bp fragment visible by ethidium staining of 2.0% agarose gel. All seven cases showed HPV type 6/11 based on the types for which RFLP information is available (figure 8).

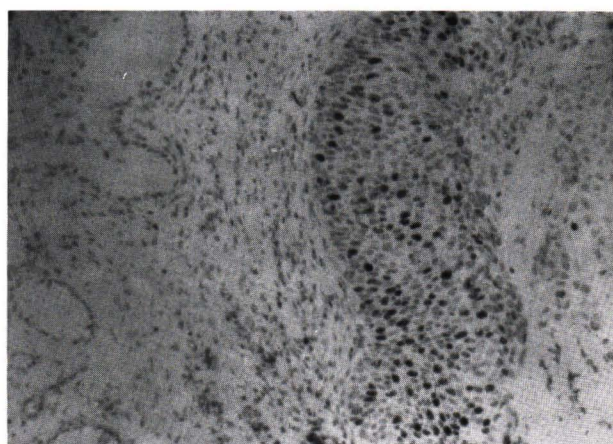
## Discussion

Atypical (papillary) immature metaplasia was morphologically distinct and characterized by slender papillae in the papillary growth pattern, variable maturation, mild nuclear atypia, uniform chromatin distribution and nuclear morphology.<sup>(4,5)</sup> These lesions displayed a tendency to extend into the endocervical canal.<sup>(4,5)</sup> It should be emphasized that some PIM lesions may be difficult to distinguish from lesions that are associated with high grade

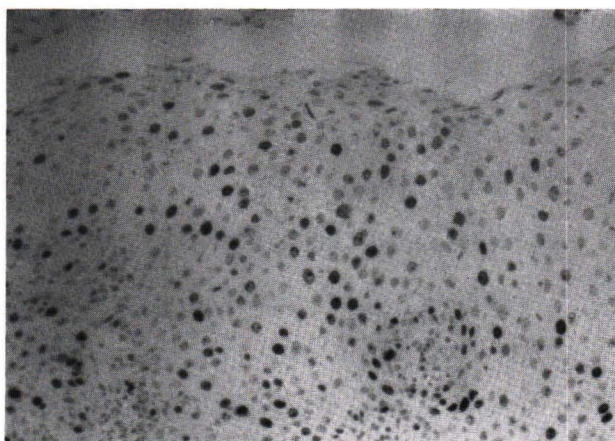




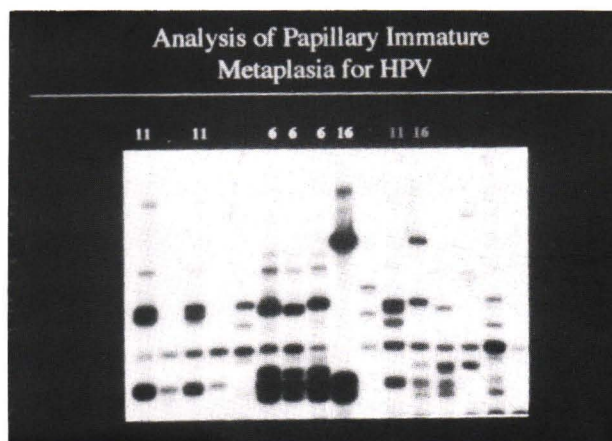
**Figure 5.** Ki-67 staining in PIM show homogeneously in variable numbers of nuclei in the lower epithelium.



**Figure 6.** Ki-67 staining in HSIL displays more intense staining in higher proportion of cells.



**Figure 7.** Ki-67 staining in LSIL show focal intense staining in upper cell layers.



**Figure 8.** Autoradiography of polyacrylamide gel displays DNA sequencing band to analysis HPV type by PCR and RFLP method.

precursors (HSIL) or invasive cancer.<sup>(4,11)</sup> Moreover, histologically these PIM lesions conceivably may be confused with reactive metaplasia and papillary squamous cell carcinoma.<sup>(11,12)</sup>

The purpose of this study was to compare the Ki-67 immunostaining patterns of PIM, LSIL and HSIL for differences of distribution and intensity of staining. PIM cases revealed homogeneous

staining in variable numbers of nuclei in the lower epithelial strata with progressive reduction in the superficial epithelium. Staining in LSIL cases was similar to PIM cases, except for focally intense staining predominantly in koilocytes at upper cell layers. In contrast, HSIL cases displayed more intense staining in a higher proportion of cells in all layers of the epithelium. These findings may be an additional parameter for distinguishing each type of



lesion. The pattern of Ki-67 immunostaining might be consistent with DNA proliferation of each lesion for which HSIL contained more proliferating cells.

Ward, et al, demonstrated the association of papillary immature metaplasia with HPV type 6/11 in 5 of 6 cases.<sup>(5)</sup> In our study, we found seven of ten PIM cases positive for HPV type 6/11 by PCR and RFLP. These findings confirmed the concept that PIM was a distinct subset of exophytic cervical condyloma and could be classified by LSIL criteria.<sup>(4,7,11)</sup> However, it is not clear whether the presence of HPV type 6/11 DNA excludes the risk of progression in this unique subset to HSIL or invasive cancer.

In conclusion, the markedly different distribution and intensity of Ki-67 immunostaining may be helpful for pathologists in differentiating PIM lesions from HSIL. In LSIL, focally intense staining in upper cell layers is in contrast to PIM although not so impressively. The association of PIM and HPV type 6/11 is demonstrable.

## References

1. Crum CP, Mitao M, Levine RU, Silverstein SJ. Cervical papillomaviruses segregate within morphologically distinct precancerous lesions. *J Virol* 1985 Jun; 54 (3): 675-81
2. Richart RM. Cervical intraepithelial neoplasm. In: Sommers SC, ed. *Pathology Annual*. New York: Appleton-Century-Croft, 1973: 301-28
3. Bonfiglio TA, Patten SF. Histopathologic spectrum of benign proliferative and intraepithelial neoplastic reactions of the uterine cervix. *J Reprod Med* 1976 May; 16(5): 253-62
4. Crum CP, Egawa K, Fu YS, Lancaster WD, Barron B, Levine RU, Fenoglio CM, Richart RM. Atypical immature metaplasia (AIM). A subset of human papilloma virus infection of the cervix. *Cancer* 1983 Jun 15; 51 (12): 2214-9
5. Ward BE, Saleh AM, Williams JV, Zitz JC, Crum CP. Papillary immature metaplasia of the cervix: a distinct subset of exophytic cervical condyloma associated with HPV-6/11 nucleic acids. *Mod Pathol* 1992 Jul; 5 (4): 391-5
6. Cattoretti G, Becker MHG, Key G, Duchrow M, Schluter C, Galle J, Gerdes J. Monoclonal antibodies against recombinant parts of the Ki-67 antigen (MIB1 and MIB3) detect proliferating cells in microwave-processed formalin-fixed paraffin sections. *J Pathol* 1992; 168: 357-363
7. Kurman RJ, Norris HJ, Wilkinson EJ. Atlas of tumor pathology, tumors of the cervix, vagina and vulva. Washington D.C.: Armed forces institute of pathology 1992, 44-55
8. Wright DK, Manos MM. Sample preparation from paraffin-embedded tissues. In: Innis MA, Gelfand DH, Sninsky JJ. *PCR protocols: A guide to methods and applications*. San Diego: Academic press 1990, 153-158
9. Manos MM, Ting Y, Wright DK, Lewis AJ,

- Broker TR, Wolinsky SM. The use of polymerase chain reaction amplification for the detection of genital human papilloma viruses. In: Furth H, Greaves H. Cancer cells vol 7. Molecular diagnostics of human cancer. New York: Cold Spring Harbor. Laboratory 1989, 209-214
10. Lungu O, Wright TC, Silverstein S. Typing of human papillomaviruses by polymerase chain reaction amplification with L1 consensus primers and RFLP analysis. Mol Cell Probes 1992; 6: 145-152
11. Crum CP, Cibas ES, Lee RK. Pathology of early cervical neoplasm. New York: Churchill Livingstone 1997; 61-66
12. Randall ME, Andersen WA, Mills SE. Papillary squamous cell carcinoma of the uterine cervix: a clinicopathologic study of nine cases. Int J Gynecol Pathol 1986; 5: 1-8