

6-1-1998

A case of Kenny-Caffey syndrome

S. Wacharasindhu

S. Likitmaskul

K. Angsusingha

C. Tuchinda

S. Keorochana

Follow this and additional works at: <https://digital.car.chula.ac.th/clmjjournal>



Part of the [Medicine and Health Sciences Commons](#)

Recommended Citation

Wacharasindhu, S.; Likitmaskul, S.; Angsusingha, K.; Tuchinda, C.; and Keorochana, S. (1998) "A case of Kenny-Caffey syndrome," *Chulalongkorn Medical Journal*: Vol. 42: Iss. 6, Article 5.

Available at: <https://digital.car.chula.ac.th/clmjjournal/vol42/iss6/5>

This Case Report is brought to you for free and open access by the Chulalongkorn Journal Online (CUJO) at Chula Digital Collections. It has been accepted for inclusion in Chulalongkorn Medical Journal by an authorized editor of Chula Digital Collections. For more information, please contact ChulaDC@car.chula.ac.th.

A case of Kenny-Caffey syndrome

Suttipong Wacharasindhu*

Supawadee Likitmaskul** Kitti Angsusingha**

Chanika Tuchinda** Sriprapai Keorochana***

Wacharasindhu S, Likitmaskul S, Angsusingha K, Tuchinda C, Keorochana S. A case of Kenny-Caffey syndrome. *Chula Med J* 1998 Jun; 42(6): 455-60

We report a case of a patient with Kenny-Caffey syndrome who presented with hypocalcaemic seizures during his neonatal period due to hypoparathyroidism. The clinical features of this syndrome consist of growth retardation, medullary stenosis of the long bones, intermittent or long-standing hypocalcaemia due to mild to complete hypoparathyroidism, eye abnormalities such as microphthalmia, hyperopia, myopia and normal intelligence. Some of the clinical manifestations may be similar to pseudohypoparathyroidism. To recognize this syndrome early, we suggest a radiological study of the long bones in neonates with hypocalcaemia and wide anterior fontanel.

Key words : *Kenny-Caffey, Hypoparathyroidism.*

Reprint request : Wacharasindhu S, Department of Paediatrics, Faculty of Medicine,
Chulalongkorn University, Bangkok 10330, Thailand.

Received for publication. April 9, 1998.

* Department of Paediatrics, Faculty of Medicine, Chulalongkorn University

** Department of Paediatrics, Siriraj Hospital, Mahidol University

***Department of Radiology, Siriraj Hospital, Mahidol University

ศุทธิพงษ์ วัชรสินธุ, สุภาวดี ลิขิตมาศกุล, กิตติ อังศุสิงห์, ชนิกา ตู้อินดา, ศรีประไพ แก้วโรจน์.
กลุ่มอาการ Kenny - Caffey : รายงานผู้ป่วย 1 ราย. จุฬาลงกรณ์เวชสาร 2541 มิ.ย; 42(6) : 455-60

รายงานผู้ป่วย *Kenny - Caffey syndrome* 1 ราย ที่มาพบด้วยอาการชักในวัยแรกคลอด เนื่องจากภาวะแคลเซียมในเลือดต่ำ อันมีสาเหตุจาก *hypoparathyroidism* อาการและอาการแสดงของโรคกลุ่มนี้ได้แก่ *growth retardation, delayed closure of anterior fontanel, medullary stenosis* ของ *long bone, hypoparathyroidism* ความผิดปกติทางตา ได้แก่ *microphthalmia, hyperopia, myopia* ระดับสติปัญญาในเด็กกลุ่มนี้มักจะปกติ ดังนั้นในเด็กแรกเกิดที่มีภาวะแคลเซียมในเลือดต่ำ ร่วมกับมีขนาดของ *anterior fontanel* กว้าง ควรจะตรวจทางรังสีของกระดูก *long bone* เพื่อให้ได้การวินิจฉัยกลุ่มอาการนี้ได้เร็วขึ้น

Kenny-Caffey syndrome is an extremely rare disorder characterized by hypocalcemia, internal cortical thickening and medullary stenosis of tubular bones, delayed closure of anterior fontanel, eye abnormalities, short stature and normal intelligence. This condition was first reported in 1966 by Kenny⁽¹⁾ and since then there have been 27 cases reported in the literature. Although most cases of Kenny-Caffey syndrome are thought to be inherited as an autosomal dominant, some cases may be autosomal recessive or sporadic.⁽²⁻⁴⁾ We report a case of this disorder presented during the neonatal period with hypocalcemic seizures due to hypoparathyroidism.

Case report

An 8-day old Thai boy was admitted to our hospital because of many episodes of jerking movement of facial muscles followed by the same in the upper and lower extremities, more on the left side, without conscious changes. Each attack lasted about 2 minutes. He was the first offspring of nonconsanguineous parents and was delivered by cesarian section due to placenta previa. His birth weight was 3200 gm. There were no remarkable events during the first week of his life. There was no history of this condition in his parents.

The initial physical examination upon admittance revealed a weight of 3300 gm and length of 51 cm. He had a prominent forehead with the anterior fontanel measuring 7 x 8 cm, the posterior fontanel measuring 3 x 3 cm. and a head circumference of 34 cm. No other abnormalities were detected from physical examination.

The results of the laboratory investigations were as follows. The complete blood count revealed,

hematocrit 48.7 % , hemoglobin 15.6 g/dl, white blood cell 18,340 mm³, PMN 38 % , L 45 % , M 10 % , E 4 % , B 3 % , platelets 433,000/mm³. Normal urine findings were found . Serum glucose 4.4 mmol/L, Na 136, K 5.7, Cl 105, HCO₃ 19 mmol/L, ionized calcium 0.9 mmol/L ,phosphorus 3.7 mmol/L, magnesium 0.6 mmol/L , albumin 42 g/L, urea nitrogen 1.4 mmol/L, and creatinine 35.3 µmol/L. The cerebrospinal fluid from a lumbar puncture was normal.

The radiological study of the long bones showed cortical thickening and medullary stenosis and absence of a diploic space was demonstrated on skull X- ray (Figure.1,2) . Because of seizures with hypocalcemia, he was initially treated intravenously with 10 % calcium gluconate. Subsequently, he was put on elemental calcium supplementation orally up to a dose of 100 mg/k/day (Calcium-Sandoz - 1 tablet contains 2.94 g of Ca lactate-gluconate, 0.3 g of Ca carbonate equivalent to 500 mg of elemental calcium) and calcitriol (Rocaltrol) 100 ng/k/day because of suspicion of hypoparathyroidism. With this treatment, the serum calcium and phosphate levels were normalized and the patient was free of seizures. Finally, the diagnosis of hypoparathyroidism was confirmed by a low serum intact parathyroid hormone level of 0.1 pmol/L (IRMA; normal range 1.4-5.7.

Discussion

The clinical constellation of 1) medullary stenosis of the long bones 2) growth retardation, 3) intermittent to long-standing hypocalcaemia due to mild to complete hypoparathyroidism , and 4) ophthalmologic abnormalities should make anyone suspicious of Kenny-Caffey syndrome.⁽⁵⁾ However,

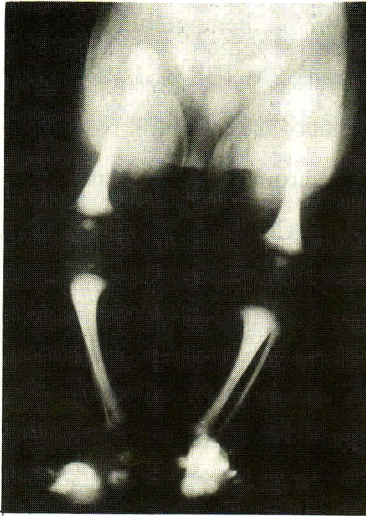


Figure 1. The radiological study of long bone demonstrates cortical thickening and medullary stenosis.

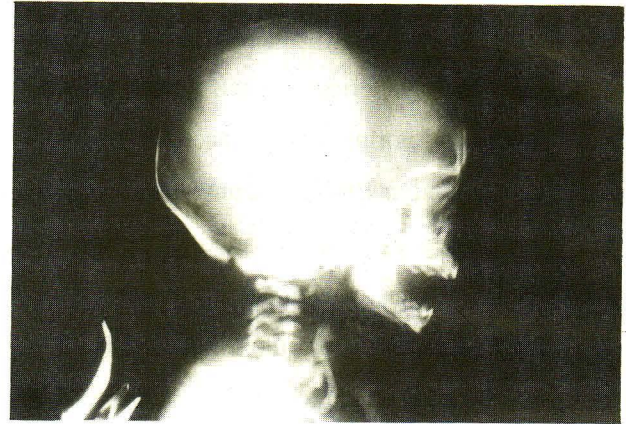

Figure 2. Skull X – ray demonstrates the absent of diploic space in this patient.

diagnosis in the neonatal period may be difficult because some clinical manifestations such as growth retardation and eye abnormalities may not be presented during this period. In addition, X-rays of the long bones are not routinely performed for hypocalcemic seizures. The condition may be misdiagnosed as pseudohypoparathyroidism because of the short stature, and hypocalcemia suggests a spectrum of pseudohypoparathyroidism. However, the shortened fourth metacarpal bone and metastatic subcutaneous calcification would not Franceschini et al⁽²⁾ reviewed the previously reported cases and showed that more than 90 % of the patients had short statures, cortical thickening with medullary stenosis of the long bones and delayed fontanelle closure, but three patients reported by Majewski et al⁽⁶⁾ showed no medullary stenosis. Eighty five percent of reported cases had hypocalcemia, but low parathyroid hormone was found in only 60 %. Boynton et al⁽⁷⁾ also reported a Kenny-

Caffey patient with no parathyroid tissue at autopsy at 19 years of age. Other abnormalities can be found in this disorder, such as microphthalmia(56%), hyperopia (61 %), myopia (21 %), and delayed dentition (67 %). Eventually, most of the patients became of short stature with normal growth hormones (GH) and thyroid hormones. Short term GH therapy proved to be ineffective in this condition.^(6,8) Up to the present, no evidence of pituitary causes of the short stature have been report. studies in women with this condition showed normal sexual maturity and normal fertility,^(1,6) however, cryptorchidism was reported in a man with Kenny syndrome.⁽⁹⁾ More than half of the cases are familial, probably transmitted as autosomal dominants but autosomal recessive and sporadic cases have also been reported⁽²⁻⁴⁾ In molecular study. Bergada et al⁽¹⁰⁾ demonstrated no parathyroid hormone gene abnormalities in this condition. Intelligence was reported to be normal in 90 % of cases in spite of many episodes

of seizure.⁽⁴⁾ Furthermore, iron deficiency anemia could be demonstrated in this condition but anemia related to medullary stenosis has never been proven. ⁽²⁾ Table 1 shows the relative incidence of major manifestations in previously published cases of Kenny-Caffey syndrome compared with those in our

patient. Because of a high percentage of delayed closures of fontanel, we suggest that X-ray of the long bones should be performed in hypocalcaemic neonates with wide anterior fontanel so as to recognize this condition early.

Table 1. Relative incidence of major manifestations of Kenny - Caffey syndrome.

Major manifestations	Previous published cases	Our patient	Incident at present (%)
Sex , M:F	12:15	M	13:15
Cortical thickening and medullary stenosis	26/27	present	27/28 (96 %)
Dwarfism	25/27	not present (need long term follow up)	25/28 (89 %)
Delayed fontanelle closure	21/23	present	22/24 (92 %)
Hypocalcemia	19/22	present	20/23 (87 %)
Eye abnormalities	17/25	not present	17/26 (65 %)
Normal intelligence	18/20	need long term follow up	18/20 (90 %)
Low serum parathyroid hormone	7/12	present	8/13 (61 %)

References

1. Kenny FM, Linarelli L. Dwarfism and cortical thickening of tubular bones . Transient hypocalcemia in a mother and son. *Am J Dis Child* 1966 Feb; 111(2) : 201-7
2. Franceschini P, Testa A, Bogetti G, Girardo E, Gual A, Lopez-Bell G, Buzio G, Ferrario E. Kenny-Caffey syndrome in two sibs born to consanguineous parents: evidence for an autosomal recessive variant. *Am J Med Genet* 1992 Jan 1; 42(1):112-6
3. Churesigaew S. Keny-Caffey syndrome. *J Med Assoc Thai* 1994 Oct; 77(10): 554-8
4. Abdel-Al YK, Auger LT, el-Gharbawy F. Kenny-Caffey syndrome : case report and literature review. *Clinical Pediatrics* 198 Apr; 28(4): 175-9
5. Larsen JL, Kivlin J, Odell WD. Unusual cause of short stature. *Am J Med* 1985 Jun; 78 (6 pt 1):1025-32

6. Majewski F, Rosendahl W, Ranke M, Nottle K. The Kenny syndrome, a rare type of growth deficiency with tubular stenosis, transient hypoparathyroidism and anomalies of refraction. *Eur J Pediatr* 1981Mar; 136 6(1):21-30
7. Boynton JR, Pheasant TR, Johnson BL, Levin DB, Streeten BW. Ocular finding in Kenny syndrome. *Arch Ophthalmol* 1979 May; 97(5): 896-900
8. Lee WK, Vargas A, Bames J, Root AW. The Kenny-Caffey syndrome: growth retardation and hypocalcemia in a young boy. *Am J Med Genet* 1983 Apr; 14(4): 773-82
9. Wilson MG, Marondi RF, Mikity VG, Shinno NW. Dwarfism and congenital medullary stenosis (Kenny syndrome). *Birth Defects* 1974; 10(12): 129-32
10. Bergada I, Schiffrin A, Abu Srair H, Kaplan P, Dornan J, Goltzman D, Hendy GN. Kenny syndrome : description of additional abnormalities and molecular studies. *Hum Genet* 1988 Sep; 80(1): 39-42