

6-1-1998

Hemodynamic changes after pulmonary balloonvalvuloplasty in tetralogy of Fallot patients

K. Thongchaiprasit

P. Lertsapcharoen

P. Chottivittayatarakorn

C. Thisyakorn

C. Pathmanand

See next page for additional authors

Follow this and additional works at: <https://digital.car.chula.ac.th/clmjjournal>



Part of the [Medicine and Health Sciences Commons](#)

Recommended Citation

Thongchaiprasit, K.; Lertsapcharoen, P.; Chottivittayatarakorn, P.; Thisyakorn, C.; Pathmanand, C.; and Sueblinvong, V. (1998) "Hemodynamic changes after pulmonary balloonvalvuloplasty in tetralogy of Fallot patients," *Chulalongkorn Medical Journal*: Vol. 42: Iss. 6, Article 3.

Available at: <https://digital.car.chula.ac.th/clmjjournal/vol42/iss6/3>

This Article is brought to you for free and open access by the Chulalongkorn Journal Online (CUJO) at Chula Digital Collections. It has been accepted for inclusion in Chulalongkorn Medical Journal by an authorized editor of Chula Digital Collections. For more information, please contact ChulaDC@car.chula.ac.th.

Hemodynamic changes after pulmonary balloonvalvuloplasty in tetralogy of Fallot patients

Authors

K. Thongchaiprasit, P. Lertsapcharoen, P. Chottivittayatarakorn, C. Thisyakorn, C. Pathmanand, and V. Sueblinvong

Hemodynamic changes after pulmonary balloon valvuloplasty in tetralogy of Fallot patients

Kriangsak Thongchaiprasit * Pornthep Lertsapcharoen**

Pairoj Chottivittayatarakorn ** Chule Thisyakorn **

Chotima Pathamanand** Viroj Sueblinvong **

Thongchaiprasit K, Lertsapchareon P, Chottivittayatarakorn P, Thisyakorn C, Pathamanand C, Sueblinvong V. Hemodynamic changes after pulmonary balloon valvuloplasty in tetralogy of Fallot patients. Chula Med J 1998 Jun; 42(6): 431-40

- Objective** : *To study the effect of pulmonary balloon valvuloplasty in tetralogy of Fallot patients.*
- Setting** : *Division of Pediatric Cardiology, Department of Pediatrics, Faculty of Medicine, Chulalongkorn University.*
- Design** : *Prospective study.*
- Subject** : *Thirteen tetralogy of Fallot patients who attended the pediatric cardiology clinic, Department of Pediatrics, Faculty of Medicine, Chulalongkorn University.*
- Patients** : *Thirteen tetralogy of Fallot patients with an age range of 44.62 ± 16.02 months were enrolled in the study. They were moderately to severely cyanotic with histories of progressive hypoxic spells.*
- Method** : *Data on hypoxic spells, hemoglobins, oxygen saturations and echocardiographic measurements of pulmonary annulus, pulmonary arteries, aorta diameters and ventricular volumes were obtained immediately after, and one and two months after the pulmonary balloon valvuloplasty.*

* Fellow in Cardiology, Department of Pediatrics, Faculty of Medicine, Chulalongkorn University

**Department of Pediatrics, Faculty of Medicine, Chulalongkorn University

- Results** : *There were significant increases in systemic oxygenations, diameters of pulmonary valve annulus, pulmonary arteries, left ventricular volume, and right ventricular volume ($p < 0.05$) after balloon valvuloplasty. These persisted during the 2 month period of follow-up. Frequencies of hypoxic spells decreased, but there were no significant differences in hemoglobin levels and aortic diameters. Even though the number of cases of our experience.*
- Conclusion** : *Even though the number of cases of our experience. Balloon pulmonary valvuloplasty showed beneficial effects in improved hemodynamics especially increases in ventricular volume and pulmonary arteries size in the tetralogy of Fallot patients. It might be a palliative treatment comparable to systemic in pulmonary shunt operations .*
- Key words** : *TOF, Balloon valvuloplasty, Palliative treatment.*

Reprint request : Lertsapchareon P, Department of Pediatrics, Faculty of Medicine,
Chulalongkorn University, Bangkok 10330, Thailand.

Received for publication. April 2, 1998.

เกรียงศักดิ์ ทองชัยประสิทธิ์, พรเทพ เลิศทรัพย์เจริญ, ไพโรจน์ โชติวิทยธารากร, จุล ทิธยากร, คุณหญิงโชติมา ปัทมพันธ์, วิโรจน์ สืบหลินวงศ์. ภาวะการเปลี่ยนแปลงภายหลังการใช้ลูกโป่งขยายลิ้นหัวใจพัลโมนิก ในผู้ป่วย tetralogy of Fallot. จุฬาลงกรณ์เวชสาร 2541 ม.ย ; 42 (6) : 431-40

- วัตถุประสงค์** : เพื่อศึกษาผลของลูกโป่งขยายลิ้นหัวใจพัลโมนิก ในผู้ป่วย tetralogy of Fallot.
- สถานที่ทำการศึกษา** : คลินิกโรคหัวใจเด็ก หน่วยกุมารเวชศาสตร์โรคหัวใจ ภาควิชากุมารเวชศาสตร์ คณะแพทยศาสตร์ จุฬาลงกรณ์มหาวิทยาลัย.
- รูปแบบการการศึกษา** : การศึกษาแบบไปข้างหน้า
- ผู้ป่วยที่ได้ทำการศึกษา** : การศึกษานี้ได้คัดเลือกผู้ป่วย จำนวน 13 ราย อายุอยู่ระหว่าง 44.62 ± 16.02 เดือน โดยผู้ป่วยที่ทำการศึกษา จะมีภาวะเขียวปานกลางถึงมาก หรือมี ภาวะ hypoxic spells เพิ่มขึ้น
- วิธีการศึกษา** : เก็บข้อมูลเกี่ยวกับภาวะ hypoxic spells ความอิ่มตัวออกซิเจนในเลือด ซีโมโกลบิน ทำการตรวจวัดค่าขนาดของ หลอดเลือดแดงพัลโมนารี, หลอดเลือดเอออร์ต้า และปริมาตร ของห้องหัวใจเวนตริเคิล ทั้งสองข้าง โดยใช้คลื่นเสียงความถี่สูงก่อนและหลังการใช้ลูกโป่งขยายลิ้นหัวใจ โดยติดตามผล ทุกเดือน ทั้งสิ้น 2 เดือน.
- ผลการศึกษา** : พบว่ามีการเพิ่มขึ้นอย่างมีนัยสำคัญทางสถิติ ($p < 0.05$) ของค่าความอิ่มตัวออกซิเจน ในเลือด, ขนาดของเส้นเลือดพัลโมนารี และปริมาตรของห้องหัวใจเวนตริเคิลทั้งสองข้าง และ คงที่ในช่วงที่ทำการศึกษา นอกจากนั้นจำนวนครั้งของการเกิด hypoxic spells ก็ลดลงอีกด้วย แต่ไม่พบความเปลี่ยนแปลงใน ความเข้มข้น ของเม็ดเลือดแดง และ ขนาดของหลอดเลือดเอออร์ต้า
- วิจารณ์และสรุปผล** : ถึงแม้ว่าจำนวนผู้ป่วยที่ใช้ศึกษาน้อย แต่พบว่าการใช้ลูกโป่งขยายลิ้นหัวใจพัลโมนิก มีประโยชน์ในการช่วยให้ภาวะการไหลเวียน โลหิต ในร่างกายดีขึ้น ช่วยเพิ่มขนาดของหลอดเลือดแดงพัลโมนารี และปริมาตร ของเวนตริเคิล ซึ่งน่าจะเป็นทางเลือกหนึ่งของ การรักษาผู้ป่วย ก่อนที่จะทำการผ่าตัดแก้ไขความผิดปกติทั้งหมดต่อไป

Pulmonary balloon valvuloplasty had been performed for cyanotic heart disease with right ventricular outflow tract obstruction for palliative treatment,⁽¹⁾ especially in patients with tetralogy of Fallot (TOF),⁽²⁻⁷⁾ but it remains a controversial procedure in TOF patients. Because of unpredictable improvements in clinical manifestations and growth of pulmonary arteries as compared to systemic in pulmonary shunt procedures. The purpose of this report is to evaluate the effects of balloon valvuloplasty on severity of cyanosis, the pulmonary artery sizes and the ventricular volumes in patients with TOF.

Materials and Methods

Patients :

Thirteen children with TOF were enrolled in this study from Aug.1997 to Jan.1998. All patients had moderate to severe cyanosis and, typical clinical manifestations of TOF. Data was by collected by echocardiogram (Acuson model 128 XP/IO). Each patient was evaluated for manifestations of hypoxic spells, hemoglobin levels, oxygen saturation, clinical hypoxic spells, hemoglobin, pulmonary artery

sizes, ventricular volumes, descending aorta sizes and complications of the procedure. All patients were followed up monthly for two months. (Table 1)

Protocol for dilatation:

After the diagnosis was confirmed by right sided heart catheterization and right ventricular angiogram. The pulmonary balloon dilatation was performed using a single balloon technique with a balloon diameter/diameter of pulmonic valve annulus ratio of 1.35 ± 0.31 ($x \pm SD$). The diameter of the pulmonic valve annulus was measured from lateral view of the right ventricular angiogram in end systolic period. The balloon dilatation technique was performed by advancing an endholecatheter across the right ventricular outflow tract to the pulmonary artery and a 0.032 inch Teflon-coated guidewire was threaded through the catheter. The introducing catheter was then exchanged for a Manfields balloon dilatation catheter. When the balloon was passed through the stenotic site, it would be inflated (with contrast media diluted 1:2 with normal saline) 2.77 ± 0.93 times (mode 3 times) until no waste was seen in the balloon. The balloon was then withdrawn. A right ventricular angiogram was repeated after the

Table 1. Follow-up protocol.

Data	Spell	Medication	O2sat.	PA	LPA	RPA	AO	LVEDV	RVEDV	Hb
Pre-balloon	+	+	+	+	+	+	+	+	+	+
Post-balloon every mo.	+	+	+	+	+	+	+	+	+	+

O2 sat.:cutaneous oxygen saturation ; PA:pulmonic valve anulus(end systole); RPA, PA: pulmonary arthey size (bifurcation in end systole) AO: des.AO at diapharm level (end systole); LVEDV:LV end diastolic volume^(8,13) and RVEDV:RV end diastolic volume^(14,15) by modified Simson rule, *Hb:hemoglobin (2mo.after balloon valvuloplasty)

procedure. After the dilatation procedure data was collected. (Figure 1.)

relation between ventricular volume and balloon size, and oxygen saturations were assessed by linear regression A

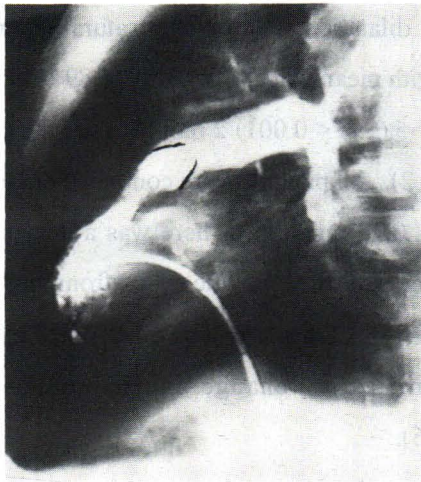


Figure 1. A

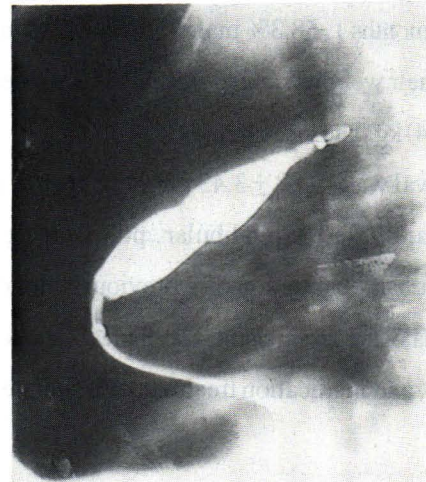


Figure 1. B

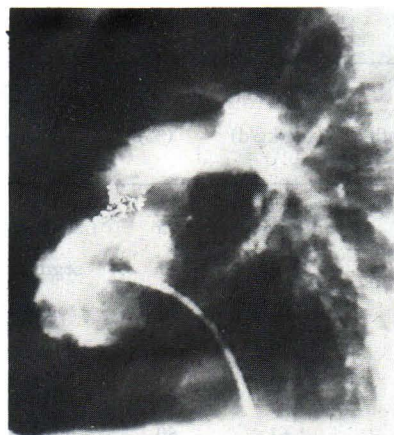


Figure 1. C

Figure 1. Pulmonary balloon valvuloplasty technique. A, Selective right ventricular angiogram in lateral view showing thickening annulus and infundibular stenosis. B, Lateral view of a partially inflated valvuloplasty. A slight “waist” can be noted in the mid portion of the balloon. C, Lateral view showing increase of pulmonary annulus, left and right pulmonary arteries after balloon dilatation, increase infundibular stenosis.

Statistical Analysis:

Data analysis was conducted with the use of the SPSSPC program for Windows version 6.0. Some variables were transformed into ratios. The changes after balloon dilatation were tested with a paired t test. The

value of $p < 0.05$ was considered significant. The result was presented as mean \pm SD with 95% CI for difference means when required.

Results

Patients :

Thirteen children , aged 44.62 ± 16.02 months (median 47months) , 58.3% male were enrolled in this protocol. Their weights ranged from 9 to 18.6 (mean 13.14 ± 3.04) kg. The mean hemoglobin (Hb) level was 19.88 ± 3.43 gm % . Three of the 13 patients mainly had infundibular pulmonic stenosis. One patient had obstruction of a previously done right modified Blalock Taussig shunt. The clinical data, severity of cyanosis , and medication treatment are summarized. (Table 2)

supportive treatment. The systemic oxygen saturations increased from a mean value of 74.85 ± 7.15 % to 85.92 ± 4.46 % (95 % CI, - 14.31 to - 7.85 , $p < 0.001$) after balloon dilatation. The oxygen saturations remained stable with mean value of 84.31 ± 5.89 % (95 % CI, - 13.21 to -5.6, $p < 0.001$) 2 months after the procedure (Figure. 2). All patients were continued on propranolol 2.05 ± 0.38 mg/kg/d. There was a decrease in the frequencies of the cyanotic spells from more than 15 times/mo. (76.9 %) to less than 5times/mo (92.3 %) with no significant change in Hb concentrations. ($p > 0.05$).

Table 2 . Clinilcal summary

Case No.	Age (mo)	Wt (Kg.)	Hb (g%)	spell (time/month)	propranolol (mg/kg/d)	O2 sat. (%)	level of RVOT infundibular	obstruction valvular	balloon/PA size ratio
1	54	12.6	22.3	<5	2.33	75	short segment	moderate	2.11
2	60	13.3	17.3	10-20	1.13	77	segment	mild	1.33
3	56	13.8	26.6	>30	2.17	77	segment	no	1.3
4	48	15	20.7	>30	2	69	short segment	no	1.25
5	47	12.5	18	5-10	2.5	69	tubular segment	severe	1.5
6	39	18.6	22	<5	1.61	69	tubular segment	severe	1.04
7	25	9.8	15.1	>30	2.04	75	tubular segment	moderate	1.02
8	36	12	18.2	10-20	2.5	77	segment	moderate	1.61
9	24	9	16.1	>30	2.5	83	segment	mild	1.49
10	68	17.7	16.2	>30	2.26	89	segment	moderate	1.0
11	25	9.3	22	>30	2.15	60	tubular segment	moderate	1.0
12	68	15.9	24.2	>30	1.89	75	tubular segment	no	1.49
13	30	11.2	14.6	10-20	1.79	78	segment	moderate	1.39

Clinical manifestrations:

After balloon dilatation, two children exhibited hypoxic spells which were corrected by

Complications of valvuloplasty:

No patient demonstrated any serious local complication or severe ventricular arrhythmia. Two

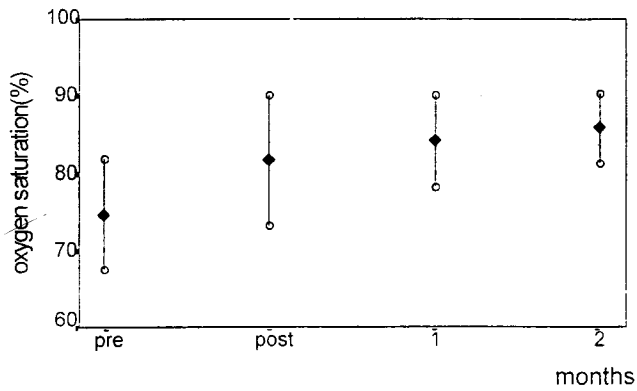


Figure 2. Immediate and short term follow-up showing (mean \pm SD) significant increase in systemic oxygen saturation after balloon valvuloplasty. ($p < 0.001$)

children (15.38%) had hypoxic spells during the first day after balloon dilatation. Minimal tricuspid valve regurgitation was detected by echocardiogram in two cases after the procedure.

Growth of pulmonary annulus valve and pulmonary arteries:

Balloon pulmonary valvuoplasty increased pulmonary annulus sizes from 1.05 ± 0.18 cm. to 1.28 ± 0.27 cm. (95% CI, -0.31 to -0.15, $p < 0.001$). The sizes of the left pulmonary artery and the right pulmonary artery increased from 0.67 ± 0.15 cm. to 0.78 ± 0.145 cm. (95% CI, -0.2 to -0.02) and from 0.64 ± 0.16 cm. to 0.75 ± 0.14 cm. (95% CI, -0.19 to -0.03) respectively ($p < 0.02$). However, these changes were not seen in the aortic diameters which remained from 0.92 ± 0.15 cm. to 0.94 ± 0.11 cm. ($p > 0.05$) and the pulmonary pressure gradient across the pulmonic valve ($p > 0.05$).

Changes in left and right ventricular volume:

After balloon pulmonary valvuloplasty the left and right ventricular volumes were increased from 10.02 ± 2.87 ml. to 12.83 ± 4.72 ml. (95% CI, -4.8 to -0.84, $p < 0.009$) and from 12.29 ± 2.41 to 14.63 ± 4.76 ml. (95% CI, -4.66 to -0.02, $p < 0.05$) respectively

(Figure 3, 4) and they are not statistically correlated with

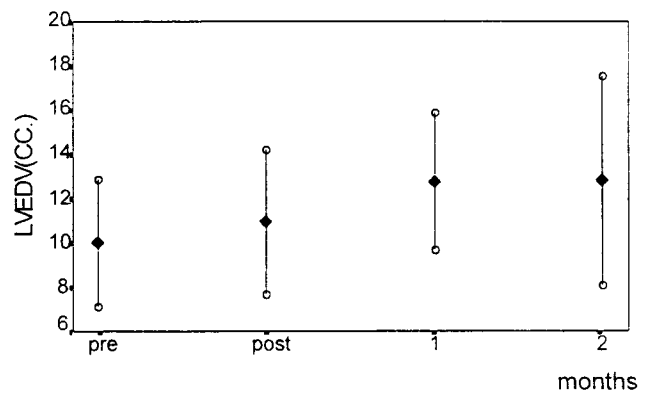


Figure 3. Immediate and short term follow-up showing (mean \pm SD) significant increase in left ventricular end diastolic volume after balloon valvuloplasty. ($p < 0.009$)

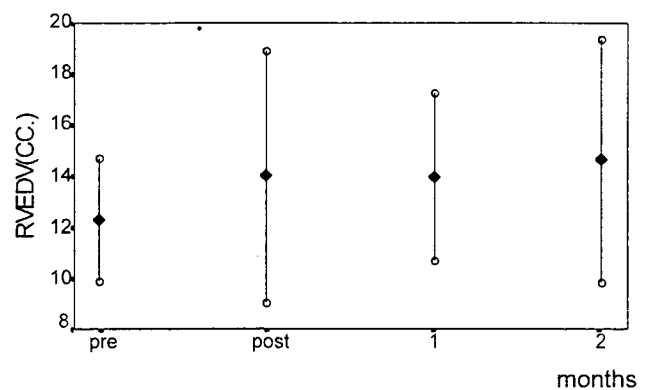


Figure 4. Immediate and short term follow-up showing (mean \pm SD) significant increase in right ventricular end diastolic volume after balloon valvuloplasty. ($p < 0.05$)

balloon size/pulmonary annulus ratios or the increase in systemic oxygen saturations.

Discussion

Pulmonary balloon valvuloplasty has been suggested in TOF as a palliative treatment⁽¹⁻⁷⁾ but it is questionable in regard to risks and benefits.^(4,9) As previously reported^(1-6,10) the procedure proved to improve systemic oxygenations,⁽¹⁻⁶⁾ pulmonic valve annulus growth^(1-6,10) and hematocrits.⁽¹⁾ This study found significant increases in systemic oxygenations, pulmonary artery growth, and improvement in cyanotic spells but not in hemoglobin as found by Boucek MM. et al.⁽¹⁾ Lock JE. et al. reported encouraging initial results with clear - cut clinical or hemodynamic deterioration in 2 months periods.^(11,12) In our report, follow-up periods of 2 months was appropriate for short term evaluation of pulmonary balloon valvuloplasty but long term effects need further evaluation as Battistessa SA. et al.⁽⁹⁾ reported no correlation of pulmonary annulus growth and balloon valvuloplasty in surgical findings. Ventricular volume has been well demonstrated to be comparable in echocardiograms and ventricular angiograms.^(8,13-15) We found that after balloon valvuloplasty, both the right and left ventricular volumes increased, thus confirming improvement of pulmonary blood flow, as in arteropulmonary shunt operations in TOF.⁽¹⁶⁾ Balloon valvuloplasty promotes pulmonary artery growth leading to improved ventricular volume thus decrease the chance for needing a transannular patch that increases risks of morbidity and mortality after surgery in long term follow-up.^(4,17-19)

Complications of balloon valvuloplasty in this

study were minimal. Many studies found severe complications such as severe cyanotic spells,⁽³⁾ venous thrombosis,⁽⁴⁾ cardiac tamponade,⁽²⁾ severe tricuspid valve trauma⁽³⁾ and sepsis.⁽²⁾ Complications depend on the patients status, technique and especially balloon size. It has been demonstrated in normal newborn lambs that trauma is minor if the balloon is 30% larger than the pulmonary annulus.⁽²⁰⁾ Some investigators suggested smaller balloon size (equal to the pulmonary annulus) to prevent increases in hypoxic spells.⁽⁵⁾ This study showed improvement of hypoxic spells and better physical activity.

Conclusions

Even though the number of cases of our experience is limited, pulmonary balloon valvuloplasty showed beneficial effects in significant improvement of oxygenation, left and right ventricular end diastolic volumes pulmonary annulus, pulmonary arteries and quality of life in tetralogy of Fallot patients that might be a palliative treatment as well as systemic to pulmonary shunts in moderate to severe cyanosis cases before total correction.

References

1. Boucek MM, Webster HE, Orsmond GS, Ruttenberg HD. Balloon pulmonary valvulotomy: palliation for cyanotic heart disease. *Am Heart J* 1988; 115: 318-22
2. Sreeram N, Saleem M, Jackson M, Peart I, McKay R, Arnold R, Walsh K. Result of balloon pulmonary valvuloplasty as a palliative procedure in tetralogy of Fallot. *J Am Coll Cardiol* 1991 Jul; 18(1): 159 - 65

3. Qureshi SA, Kirk CR, Lamb RK, Arnold R, Wilkinson JL. Balloon dilatation of the pulmonary valve in the first year of life in patients with tetralogy of Fallot: a preliminary study. *Br Heart J* 1988 Sep; 60(3):232 - 5
4. Sluysmans T, Neven B, Rubay J, Lintermans J, Ovaert C, Mucumbitsi J, Shango P. Early balloon dilatation of the pulmonary valve in the infants with tetralogy of fallot. Risks and benefits. *Circulation* 1995 Mar 1; 91(5): 1506-11
5. Hwang B, Lu JH, Lee BC, Hsieng JH, Meng CC. Palliative treatment for tetralogy of Fallot with percutaneous balloon dilatation of right ventricular outflow tract. *Jpn Heart J* 1995 Nov ;36(6) : 751 - 61
6. Matsuoka S, Ushiroguchi Y, Kubo M, Tarata K, Kitagawa T, Katch I, Kuroda Y. Balloon pulmonary valvuloplasty for infants with severe tetralogy of Fallot. *Jpn Heart J* 1993 Sep ;34(5) : 643 - 51
7. Kreutzer J, Perry SB, Janas RA, Mayer JE, Castadede AR, Lock JE. Tetralogy of Fallot with diminutive pulmonary arteries: preoperative pulmonary valve dilatation and transcatheter rehabilitation of pulmonary arteries. *JACC* 1996 Jun; 27(7) : 1741 - 7
8. Mercier JC, DiSessa TG, Jarmakani JM, Nakanishi T, Hireishi S, Isabel - Jones J, Friedman WF. Two-dimensional echocardiographic assessment of left ventricular volumes and ejection fraction in children. *Circulation* 1982 May; 65(5) : 962 - 9
9. Battistessa SA, Robles A, Jackson M, Miyamoto S, Arnold R, McKay R. Operative findings after percutaneous pulmonary balloon dilatation of the right ventricular outflow tract in tetralogy of Fallot. *Br Heart J* 1990 Nov; 64(5) : 321 - 4
10. Parsons JM, Ladusans EJ, Qureshi SA. Growth of the pulmonary artery after neonatal balloon dilatation of the right ventricular outflow tract in an infant with tetralogy of Fallot and atrioventricular septal defect. *Br Heart J* 1989 Jul; 62(1) : 65 - 8
11. Lock JE, Niemi T, Einzig S, Amplate K, Burke B, Bass JL. Transvenous angioplasty of experimental branch pulmonary artery stenosis in newborn lambs. *Circulation* 1981 Nov; 64(5) : 886 - 93
12. Lock JE, Castaneda-Zuniga WR, Fuhrman BP, Bass JL. Balloon dilatation angioplasty of hypoplastic and stenotic pulmonary arteries. *Circulation* 1983 May; 67(5): 962 - 7
13. Siverman NH, Ports TA, Snider AR, Schiller NB, Carlsson E, Heilbron DC. Determination of left ventricular volume in children: echocardiographic and angiographic comparisons. *Circulation* 1980 Sep ; 62(3) : 548-57
14. Hiraishi S, DiSessa TG, Jarmakani JM, Nakanishi T, Isabel-Jones JB, Friedman WF. Two-dimensional echocardiographic assessment of right ventricular volume in children with congenital heart disease. *Am J Cardiol* 1982 Dec ; 50(6) : 1368 - 75
15. Hirachi S, Jarmakani JM, DiSessa TG, Nakanishi T, Isabel Jones JB, Friedman WF. Simplified

- Simplified angiographic right ventricular volume methods, applicable to echocardiographic in children with congenital heart disease (abstr). *Circulation* 1981 Oct; 64 (4pt 2) Suppl:IV—18
16. Graham TP Jr, Cordell D, Atwood GF, Boucek RJ Jr, Boerthe RC, Bender HW, Nelson JH, Vaughn WK. Right ventricular volume characteristic before and after palliative and reparative operation in tetralogy of Fallot. *Circulation* 1976 Sep; 54(3): 417 - 23
17. Danton MH, Craig B, Gladstone D. Acute dissection of the right ventricular outflow tract after balloon dilatation in a patient with previously corrected tetralogy of Fallot. *Br Heart J* 1994 Aug; 72: 203 - 4
18. Katz NM, Blackstone EH, Kirklin JW, Pacifico AD, Bargernon LM. Late survival and symptoms after repair of tetralogy of Fallot. *Circulation* 1982 Feb; 65 (2): 403 - 10
19. Wessel HU, Cunningham WJ, Paul MH, Bastanier CK, Muster AJ, Idriss FS. Exercise performance in tetralogy of Fallot after intracardiac repair. *J Thorac Cardiovas Surg* 1980 Oct; 80: 582 - 93
20. Ring JC, Kulik TJ, Burke BA, Lock JE. Morphologic changes induced by dilation of the pulmonary valve annulus with overlarge balloons in normal newborn lambs. *Am J Cardiol* 1989; 55: 210 - 14