

10-1-1998

## The study of normal interorbital distances of Oriental adults : a preliminary report

N. Rojvachiranonda

T. Bunaprasert

P. maglin

T. Watanakajorn

Follow this and additional works at: <https://digital.car.chula.ac.th/clmjournal>



Part of the [Medicine and Health Sciences Commons](#)

---

### Recommended Citation

Rojvachiranonda, N.; Bunaprasert, T.; maglin, P.; and Watanakajorn, T. (1998) "The study of normal interorbital distances of Oriental adults : a preliminary report," *Chulalongkorn Medical Journal*: Vol. 42: Iss. 10, Article 4.

DOI: 10.58837/CHULA.CMJ.42.10.3

Available at: <https://digital.car.chula.ac.th/clmjournal/vol42/iss10/4>

This Article is brought to you for free and open access by the Chulalongkorn Journal Online (CUJO) at Chula Digital Collections. It has been accepted for inclusion in Chulalongkorn Medical Journal by an authorized editor of Chula Digital Collections. For more information, please contact [ChulaDC@car.chula.ac.th](mailto:ChulaDC@car.chula.ac.th).

## The study of normal interorbital distances of Oriental adults : a preliminary report

Nond Rojvachiranonda\* Tanom Bunaprasert\*\*

Prachya Maglin\*\*\* Thawatchai Watanakajorn\*\*\*\*

Rojvachiranonda N, Bunaprasert T, Maglin P, Watanakajorn T. The study of normal interorbital distances of Oriental adults : a preliminary report. Chula Med J 1998 Oct; 42(10): 945-52

- Objective** : *To establish the normative value of medial interorbital distances in normal Oriental adults.*
- Setting** : *Department of Anatomy, Faculty of Medicine, Chulalongkorn University*
- Subjects** : *212 normal Oriental skulls*
- Design** : *Descriptive study*
- Method** : *Direct measurement of the medial interorbital distance in adult Oriental skulls using a standard caliper (Thorpe caliper) by one individual.*
- Result** : *Of 188 adult skulls (> 25 yrs) included in the study, 169 were from men and 19 were from women. Mean IOD was  $23.04 \pm 2.30$  mm. (18.0 - 30.0 mm) without statistical difference between sexes.*
- Conclusions** : *This is the first study in which IOD the measurement was taken directly from skulls. The mean IOD is smaller than previously reported in Caucasians. There was no sexual difference but the number of female specimens was too small. The data can be used as a baseline by physicians who care for craniofacial patients in Thailand.*

\* Department of Surgery, Faculty of Medicine, Chulalongkorn University

\*\* Department of Anatomy, Faculty of Medicine, Chulalongkorn University

\*\*\* Unit of Plastic and Reconstructive Surgery, King Chulalongkorn Memorial Hospital

\*\*\*\*Department of Forensic Medicine, Faculty of Medicine, Chulalongkorn University

**Key words** : *Interorbital distance, Medial interorbital distance, Bony interorbital distance, IOD, Orbital dimension.*

Reprint request : Rojvachiranonda N, Department of Surgery, Faculty of Medicine,  
Chulalongkorn University, Bangkok 10330, Thailand.

Received for publication. September 2, 1998.

นนท์ โรจน์วชิรนนท์, ถนอม บรรณประเสริฐ, ปรัชญา มากลีน, ธวัชชัย วัฒนขจร. การศึกษาถึงค่าปกติของระยะห่างระหว่างผนังด้านในกระบอกตาในชาวตะวันออก : รายงานเบื้องต้น. จุฬาลงกรณ์เวชสาร 2541 ต.ค; 42(10): 945-52

- วัตถุประสงค์ : เพื่อศึกษาหาค่าเฉลี่ยระยะห่างระหว่างผนังด้านในกระบอกตาในผู้ใหญ่ชาวตะวันออก
- สถานที่ทำการศึกษา : ภาควิชากายวิภาคศาสตร์ คณะแพทยศาสตร์ จุฬาลงกรณ์มหาวิทยาลัย
- ตัวอย่าง : กะโหลกชาวตะวันออกที่มีลักษณะปกติจำนวน 212 กะโหลก
- รูปแบบการวิจัย : การศึกษาเชิงพรรณนา
- วิธีการศึกษา-วัดผล : ทำการวัดระยะห่างระหว่างผนังด้านในของกระบอกตาทั้งสองข้างโดยตรงจากกะโหลกศีรษะผู้ใหญ่ โดยใช้อุปกรณ์วัดมาตรฐานซึ่งใช้ในห้องผ่าตัด (Thorpe caliper)
- ผลการศึกษา : คัดเลือกได้กะโหลกศีรษะผู้ใหญ่ (อายุ > 25 ปี) จำนวน 188 กะโหลก เป็นชาย 169 และเป็นหญิง 19 ค่าเฉลี่ย IOD เท่ากับ  $23.04 \pm 2.30$  มิลลิเมตร (18.0-30.0 มม.) โดยไม่พบความแตกต่างเนื่องจากเพศ
- วิจารณ์และสรุป : เป็นการศึกษาแรกที่วัดค่า IOD โดยตรงจากกะโหลกศีรษะเพื่อใช้เป็นข้อมูลพื้นฐานในการรักษาผู้ป่วยที่มีความผิดปกติของกะโหลกศีรษะและใบหน้าและพบว่า ค่าเฉลี่ย IOD ต่ำกว่าที่รายงานไว้ในชาวตะวันตก โดยยังไม่พบความแตกต่างเนื่องจากเพศดังที่เชื่อกันทั้งนี้จำนวนกะโหลกศีรษะที่เป็นหญิงยังมีจำนวนน้อยเกินไป

Increasing numbers of craniofacial disorders are being diagnosed in Thailand. Orbital involvement is a common finding, e.g. orbital hypertelorism in Frontoethmoidal Encephalomeningocele, craniosynostosis syndrome, frontonasal dysplasia, facial clefts. The orbital pathology can influence patients' clinical appearance, treatment, and outcome. The severity must be objectively determined by measured medial inter-orbital distance (IOD) which has been one of the most important measurements among the orbital landmarks of surgical interest. All corrective operations are certainly designed to maintain the patients' IOD as normal into their adulthood. Orbital shape and size are known to vary with ethnic origin so comparisons must be made within appropriate groups. Nevertheless, measurement of the distance has been compared exclusively to normative values analyzed from Western

Materials and methods

Cleaned-dried identifiable cadaveric skulls from the Department of Anatomy were used in this study. Inclusion specimens were skulls 1) without any congenital anomaly, 2) with intact medial orbital walls, especially lamina papyracea and lacrimal bones, 3) which were identifiable as Orient, and 4) mature (age > 25).

Age and sex of the specimens were determined by the use of forensic anthropology. Skull is one of most reliable skeletal indicator of sex (Table 1), while there are no skeletal clues that allow a specific age such as 12 years or 25 1/2 years. Dental development is an important determinant of age in this study for it virtually stops after age 25. Characters of permanent dentition and skull sutures can also differentiate the age ranges with good accuracy.

Table 1. Sexual characteristics of the skull.

Trait	Male	Female
Supraorbital ridge (ridge above the eyes)	Robust	Gracile
Occipital protuberance (base of skull)	Robust	Gracile
Mastoid process (bony process behind ear canal)	Long, broad	Short
Chin	U - shaped, square	V - shaped

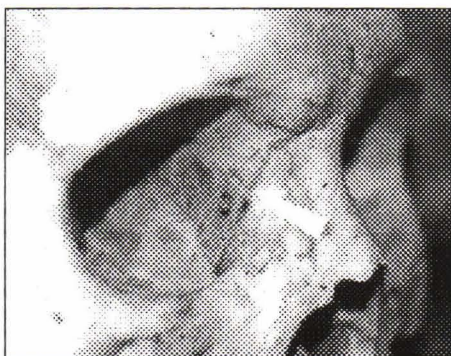
populations. These standards do not fit as Oriental's real reference and may lead to improper reconstruction. Moreover, there has never existed direct skull measurements for IOD in spite of many radiographic studies for normative values made in wide age ranges.<sup>(1-7)</sup> We therefore tried to establish local normative values of IOD, at least in adults, as a baseline.

Desired measurement was achieved by one individual using a Thorpe caliper normally used in our operating rooms and the scale was read to the nearest 0.1 mm. (Figure 1) Intra-observer, repeated measurement reliability was calculated at  $p < 0.01$  on a randomly drawn sample (20 percent) of skulls before the study.



**Figure 1.** Thorpe caliper, angled - slide rule type caliper, graduated 0 mm to 80 mm in 1 mm increments and 0 to 3 inches in 1/16 inch increments. Features 3 mm, angled tips and thumbscrew for locking caliper (Padgett Instruments, inc.)

The medial interorbital distance (IOD) is defined as the distance between bilateral dacryons (junction of the frontal, lacrimal, and maxillary bones)<sup>(8)</sup>(Figure 2). Measured data was collected, summarized, and analyzed as mean and standard deviation according to sex and age.



**Figure 2.** Dacryon (point of IOD measurement)

## Results

There were 212 available skulls examined in this study and all were oriental. Most were from men (86.3%). 188 skulls were in the adult age range (>25 yrs) and included in this study. (Table 2)

**Table 2.** Skulls examined

Estimated age	Male	Femal	Total
> 25	169	19	188
18-25	8	6	14
16-18	5	3	8
14 -16	-	1	1
< 14	1	-	1
<b>Total</b>	<b>183</b>	<b>29</b>	<b>212</b>

Mean IOD in adult skulls was  $23.04 \pm 2.30$  mm. (18.0 - 30.0 mm). There was no statistical difference of IOD between sexes,  $23.20 \pm 2.26$  mm. and  $21.61 \pm 2.26$  mm. in males and females respectively ( $p > 0.05$ ). (Table 3)

**Table 3.** Mean IOD in 188 skulls

	Male	Femal
IOD	$23.20 \pm 2.26$ mm.	$21.61 \pm 2.26$ mm.
	$23.04 \pm 2.30$ mm	(18.0 - 30.0 mm.)

## Discussion

Abnormal distance between the bony orbits has been of medical consideration since the recognition of many related diseases that cause hypertelorism or hypotelorism.<sup>(8, 9)</sup> Measurements based on soft tissue landmarks may reflect soft tissue pathology but not the bone and it is nearly impossible to take them in a

child. Increased soft tissue in the nasoorbital area can create the appearance of “pseudohypertelorism” or telecanthus.

The bony interorbital distance (BIOD) or medial interorbital distance (MIOD) was first defined by Cameron<sup>(10)</sup> in dried skulls as the maximum distance between the medial walls of the bony orbits measured at the juncture of the crista lacrimalis posterior with the frontolacrimal suture.

In 1960, Currarino and Silverman<sup>(11)</sup> proposed a distance between the dacryons (juncture of lacrimal, frontal, and maxillary bones), as viewed in the postero-anterior radiograph (Caldwell view), to be an index for assessing orbital hypertelorism and hypotelorism. This point has become an accepted reference to later evaluations. The bony interorbital distance is easy to obtain and accurate in assessing the degree of orbital separation. Since then, investigators have reported normative data of IOD for clinical usage (Table 4).

Costaras et al.<sup>(4)</sup> also examined cephalograms from 100 normal subjects corrected for sex, age, head

width (BIOD/CW index), and radiographic enlargement. They thus created another database of the IOD in a normal population from 2-20 years of age.

Such measurements based on conventional postero-anterior projection and cephalometric radiograms may be useful in the study of normal subjects, but their utility in pathologic states is questionable. Another major problem of a conventional film is a composite of various structures at different planes. Cephalometric roentgenography is subject to its intrinsic error and problematic to interpretation. Later implementation of CT scans therefore obviated those studies by its more-detailed information. CT scan also provides associated soft tissue pathology and, if necessary, any other linear or angular measurements.

IOD increases gradually from newborn to adult only 8-10 mm. by a number of factors acting synchronously and in concert. These include: 1) early enlargement of the neurocranium with passive growth at the metopic suture; 2) early growth at the frontoethmoidal suture; 3) anteroposterior cranial base

**Table 4.** Previous interorbital measurement studies.

Radiographic		
Currarino & Silverman 1960 <sup>(11)</sup>	PA view	Caucasian, birth to 12.5 yrs., adult
Morin et al. 1963 <sup>(12)</sup>	PA view	Caucasian,
Hansman 1966 <sup>(2)</sup>	Waters view	Caucasian, birth - 25 yrs. (longitudinal)
Siedband 1966 <sup>(3)</sup>	Waters view	Caucasian, birth to 15 yrs.
Costaras et al. 1982 <sup>(4)</sup>	PA view	Caucasian, 2 - 20 + yrs.
Marin MCC et al. 1988 <sup>(6)</sup>	PA view	Spanish, newborn
CT scans		
MaFee et al 1986 <sup>(5)</sup>	Different CT level	Caucasian, 17 - 88 yrs.
Waitzman et al. 1992 <sup>(13)</sup>	5 - mm CT with 1-cm overlap	Caucasian, birth to 17 yrs.

growth at the sphenothmoidal and sphenofrontal sutures; 4) passive growth at the internasal and frontomaxillary suture; and 5) bone apposition on the medial orbital walls with resorption on their underlying surfaces.<sup>(11)</sup> Interorbital growth is 50% completed by 3 years of age<sup>(12)</sup> and 85-90% of the normal adult interorbital distance is achieved at 5-8 years of age.<sup>(8,13)</sup> The growth levels off at about 13 years of age in girls and 21 years of age in boys, similar to other areas of the upper face and midface.<sup>(2)</sup> Generally, facial growth changes minimally after late adolescenc (17-20 years of age).<sup>(13)</sup>

It is not ethical to obtain numerous CT scan from a wide-age range of normal population especially in children whose congenital diseases are the problems.

Mean IOD in adults reported by different authors is 22-25 mm. in women and 23-28 mm. in men (Table 5). The IOD we observed is on the lower limit of those previously reported. This is not surprising for Orientals are usually smaller in body size than Caucasians. Most previously believed the IOD for girls is narrower than for boys.<sup>(2-5, 12)</sup> Our data does not substantiate this but the number of female skulls in our study may have been too small to reach the statistical significance, and there are a few authors contradicting the difference.<sup>(1, 13)</sup> Most specimens derived from those after accidental events where the imbalance in sex can be explained by the higher risk men are usually subject to.

**Table 5.** Mean IOD in adults (age > 24) reported by different authors.

	Male	Female	Number
Hansman <sup>(2)</sup>	28.4	25.8	55
Costaras et al. <sup>(4)</sup>	23.4 +/- 2.5	22.0 +/- 1.6	28
MaFee et al. <sup>(5)</sup>	26.7 (22.9 - 32.1)	25.6 (22.9 - 32.0)	400

There has been no direct measurement of IOD from human skulls in spite of the large collections of normative data developed by many authors.<sup>(1-7, 11, 12)</sup> Thus, adequate skull specimens from older (> 25 years of age) normal local people should at least set a local standard for various diagnostic and therapeutic plans. Any recon-structive orbital surgery carried out after 5-8 years of age may not result in serious subsequent growth disturbance. Preferred osteotomy movement and the orbital anatomical position, IOD, can then be planned to match the closest margin of proper appearance in the future.

## Conclusion

This is the first study in which the measurement of the IOD was taken directly from the skull specimens. The purpose was to begin to establish local normative data for the interorbital distance. In the study it was determined that Oriental IOD's are smaller than those measured in Caucasians but there was no difference between men and women. As specimen collection expands and there is a suitable balance in sex and age ranges, the resulting quantitative data should have clinical use to those who care for patients suffering with abnormal configurations in Thailand.



## Acknowledgements

Acknowledgement is gratefully made to Dr.Charan Mahatumarat (Unit of Plastic and Reconstructive Surgery, Department of Surgery, Chulalongkorn University) for his great advice, to Ms. Preeyaporn Rerkpinay (Chulalongkorn University Library) for the literature collection, to Mrs.Wongwan Wongsupha (Chulalongkorn University Library) for the manuscript review, and to the Department of Anatomy for providing the specimens and help throughout the study.

## References

1. Currarino G, Silverman FN. Orbital hypotelorism, arhinencephaly and trigonocephaly. *Radiology* 1960 Feb; 74 (2): 206-17
2. Hansman CF. Growth of interorbital distance and skull thickness as observed in roentgenographic measurements. *Radiology* 1996 Jan; 86 (1): 87-96
3. Siedband GN. Roentgen-study of the development of the frontal sinus and the interorbital distance in the half-axial view during infancy and childhood. *Ann Paediat* 1966; 206 (3): 175-87
4. Costaras M, Pruzansky S, Broadbent BH Jr. Bony interorbital distance (BIOD), head size, and level of the cribriform plate relative to orbital height : I. Normal standards for age and sex. *J Craniofac Genet Dev Biol* 1982; 2(1): 5-18
5. Mafee MF, Pruzansky S, Corrales MM, Phatak MG, Valvassori GE, Dobben GD, Capek V. CT in the evaluation of the orbit and the bony interorbital distance. *AJNR : Am J Neuro-radiol* 1986 Mar - Apr; 7(2): 265-9
6. Marin MC, de Talens PC, Perez-Sheriff V, Pellico MG. The interorbital distance in the newborn skull development. *An Esp Pediatr* 1988; 28(2);108-10
7. Quant JR, Woo GC. Normal values of eye position and head size in Chinese children from Hong Kong. *Optom Vis Sci* 1993 Aug; 70 (8); 668-71
8. Fearon JA, Bartlett SP, Whitaker LA. The skeletal treatment of orbital hypertelorism. *Neuro Clin North Am* 1991 Jul; 2(3): 673-81
9. Tessier P. Experiences in the treatment of orbital hypertelorism. *Plast Reconstr Surg* 1974 Jan; 53 (1):1-18
10. Cameron J. Interorbital width. New cranial dimension. Its significance in modern and fossil man in lower mammals. *Am J Phys Anthropol* 1931 Apr - Jun ;15 (2):509-15
11. Cohen MM Jr, Richieri-Costa A, Guion-Almeida ML, Saavedra D. Hypertelorism: interorbital growth, measurements, and pathogenetic considerations. *Int J Oral Maxillofac Surg* 1995 Dec; 24 (6):387-95
12. Morin JD, Hill JC, Anderson JE, Grainger RM. A study of growth in the interorbital region. *Am J Ophthalmol* 1963 Dec; 56 (6):895-913.
13. Waitzman AA, Posnick JC, Armstrong DC, Pron GE. Craniofacial skeletal measurements based on computed tomography : Part II. Normal values and growth trends. *Cleft Palate Craniofac J* 1992 Mar; 29 (2):118-28