

4-1-1999

Mullerian adenosarcoma of the endocervix: A case report

S. Trirattanachart

P. Trivijitsilp

S. Niruthisard

K. Tantayaporn

Follow this and additional works at: <https://digital.car.chula.ac.th/clmjjournal>



Part of the [Medicine and Health Sciences Commons](#)

Recommended Citation

Trirattanachart, S.; Trivijitsilp, P.; Niruthisard, S.; and Tantayaporn, K. (1999) "Mullerian adenosarcoma of the endocervix: A case report," *Chulalongkorn Medical Journal*: Vol. 43: Iss. 4, Article 7.

Available at: <https://digital.car.chula.ac.th/clmjjournal/vol43/iss4/7>

This Case Report is brought to you for free and open access by the Chulalongkorn Journal Online (CUJO) at Chula Digital Collections. It has been accepted for inclusion in Chulalongkorn Medical Journal by an authorized editor of Chula Digital Collections. For more information, please contact ChulaDC@car.chula.ac.th.

Mullerian adenosarcoma of the endocervix: A case report

Surang Triratanachat * Prasert Trivijitsilp*
Somchai Niruthisard* Kitpramuk Tantayaporn*

Triratanachat S, Trivijitsilp P, Niruthisard S, Tantayaporn K. Mullerian adenosarcoma of the endocervix: A case report. Chula Med J 1999 Apr; 43(4): 243-51

This is a report of mullerian adenosarcoma which arose from the endocervix, presented as an endocervical mass polypoid and a left ovarian mucinous cystadenoma. Microscopically, they consisted of a mixture of benign appearing epithelial and mesenchymal components with hypercellularity, moderate atypia and forming cuffs around the epithelial glands. Seven months after a total abdominal hysterectomy with bilateral salpingo-oophorectomy and surgical staging, she was still free of tumor without any adjuvant therapy. However, this tumor may have grave clinical behavior despite the benign or low-grade appearance of its microscopic features. Therefore long-term close follow-up is suggested for all adenosarcomas.

Key words : Mullerian adenosarcoma, Mucinous cystadenoma.

Reprint request : Triratanachat S, Department of Obstetrics and Gynecology, Faculty of Medicine, Chulalongkorn University, Bangkok 10330, Thailand.

Received for publication. January 15, 1999.

สุรางค์ ตริรัตน์ชาติ, ประเสริฐ ตริวิจิตรศิลป์, สมชัย นิรุตติศาสน์, กิจประมุข ดันตยาภรณ์.
เนื้องอกเยื่อประกอบมดลูกชนิด mullerian adenosarcoma: รายงานผู้ป่วย. จุฬาลงกรณ์เวชสาร 2542
เม.ย; 43(4): 243-51

รายงานนี้นำเสนอเนื้องอกชนิด mullerian adenosarcoma ที่เกิดบริเวณเยื่อประกอบมดลูก ในสตรีที่มีอาการแสดงของก้อนติ่งเนื้อปากมดลูก และถุงน้ำรังไข่ข้างซ้ายชนิด mucinous ลักษณะการตรวจพบทางกล้องจุลทรรศน์ประกอบด้วยเยื่อผิวชนิดไม่ร้ายและเนื้อเยื่อเกี่ยวพันชนิดร้ายแรงที่มีจำนวนเซลล์เพิ่มมากขึ้นตลอดจน รูปร่างของนิวเคลียสมีลักษณะหันเหจากภาวะปกติระดับปานกลาง และจัดเรียงตัวเป็นปลอกหุ้มล้อมรอบต่อมเยื่อผิว สตรีรายนี้ได้รับการผ่าตัดมดลูก หลอดมดลูกและรังไข่ทั้งสองข้างออกพร้อมทั้งผ่าตัดตรวจหาการลุกลามของเนื้องอกในช่องท้อง โดยมีได้รับยาเคมีบำบัดหรือรังสีรักษาเพิ่มเติมหลังผ่าตัด ผู้ป่วยยังคงมีสุขภาพแข็งแรงดี ไม่มีการกลับเป็นซ้ำของเนื้องอกในการติดตามเป็นเวลา 7 เดือนที่ผ่านมา อย่างไรก็ตามเนื้องอกชนิดนี้มีโอกาสกลับเป็นซ้ำของโรคได้แม้ว่าจะมีลักษณะการตรวจพบทางกล้องจุลทรรศน์ที่ค่อนข้างดี จึงจำเป็นต้องตรวจติดตามอย่างใกล้ชิดอีกเป็นระยะเวลานาน

Mullerian adenosarcoma was first described in 1974 by Clement & Scully.⁽¹⁾ In the uterus, adenosarcoma is usually of endometrial origin. Extraendometrial origin is quite rare in localities such as the ovary, adnexa, pelvic sidewall or within the myometrium.⁽²⁻⁷⁾ Few primary cervical adenosarcoma have been reported in the literature, and most of them are included in series of uterine adenosarcomas.⁽⁸⁻¹⁶⁾ The mullerian adenosarcoma is an uncommon variant of mixed mullerian tumors which are biphasic neoplasms having both glandular and stromal elements. In adenosarcoma, the glandular component is benign, but the stromal component is malignant.⁽¹⁾ The stromal components may include only elements indigenous to the uterus (homologous) or show differentiation toward elements not normally found in the uterus (heterologous) and the latter can be found in about 22% of all adenosarcomas.⁽⁹⁾ In contrast to malignant mullerian mixed tumors, and in which both epithelial and stromal elements are malignant, adenosarcoma is regarded as a low-grade neoplasm with a favorable prognosis and little metastatic potential.⁽¹⁷⁾ However, in a minority of patients it occasionally shows sarcomatous overgrowth and a distinct malignant clinical course.⁽¹⁸⁾ We report herein a case of mullerian adenosarcoma arising from the endocervix who also had mucinous cystadenoma of the left ovary.

Case report

A 44 year old single Thai female patient presented in July 1998 with a brownish vaginal discharge of 3 weeks duration. Her menstrual cycle was regular and of a 30 day type. She had a negative gynecologic and sexual history. Gynecologic exami-

nation revealed a 3 cm. diameter, well circumscribed, smooth surfaced, soft polypoid mass with a thick stalk protruding from the cervical os. A left ovarian cyst 7 cm. in greatest dimension was also identified from pelvic examination, and was confirmed by abdominal sonogram. Routine laboratory data disclosed hemoglobin of 10 g/100 ml; hematocrit 30 vol %; white blood count of 7,000 cell/mm³ with 27% lymphocytes, 70% neutrophils and 3% monocytes. Urine, stool and blood chemistry studies were unremarkable. The chest roentgenogram and electrocardiogram were normal.

A laparotomy was performed and disclosed a left unilocular ovarian cyst, measuring 7.6 x 6.6 x 6 cm. containing mucous material. The thick stalked polypoid mass (2.5 x 2.5 x 2 cm) protruding from the posterior wall of the endocervix was examined intraoperatively by frozen section and diagnosed as an adenosarcoma. A total abdominal hysterectomy with bilateral salpingo-oophorectomy and pelvic lymph node sampling was performed. The postoperative course was uneventful.

The endocervical mass was spongy and brownish with a yellow cut surface. Microscopic examination revealed a biphasic neoplasm composed of both epithelial and stromal components. The epithelial component was characterized by glands that were frequently cystically dilated and scattered regularly throughout the mesenchymal component of the tumor. The glands were lined by the benign endocervical type epithelium (Figure 1). The stromal component was composed of spindle cell stroma which were hypercellular with 2 mitotic figures per 10 under high power field (HPF), mild nuclear hyperchromasia

and moderate nuclear pleomorphism (Figure 2). The stroma often appeared condensed and with more cellularity around the glands, thus creating a cuff-like appearance (Figure 3). The tumor did not invade underlying cervical tissue. The left ovarian cyst revealed

mucinous cystadenoma. All pelvic lymph nodes were unremarkable. The pathologic diagnosis was mullerian adenosarcoma arising from the endocervix with left ovarian mucinous cystadenoma. The patient was still free of disease seven months after surgery.

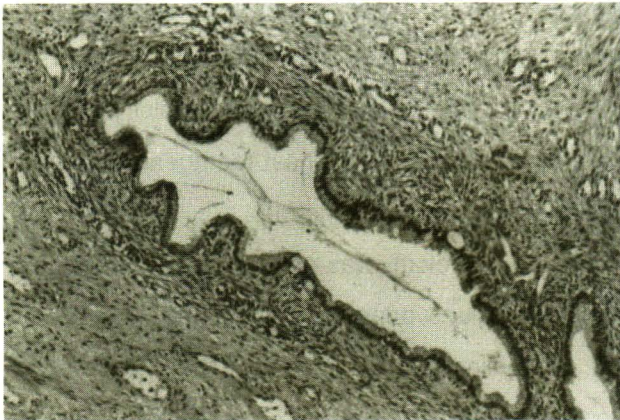


Figure 1. Elongated glands, lining with benign appearing endocervical epithelium and surrounded by a fibrosarcomatous stroma. Note a cuff-like appearance of surrounding stroma. (H & E X 40)

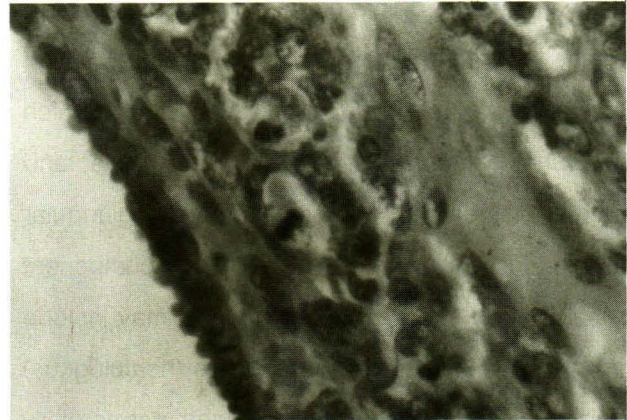


Figure 2. Demonstrated mitotic figure in sarcomatous cells of mullerian adenosarcoma. (H & E X 400)

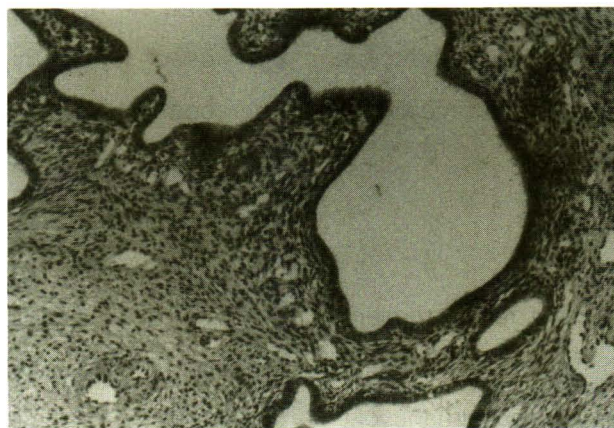


Figure 3. The sarcomatous stroma is condensed around the cystic glands. (H & E X 40)

Discussion

Adenosarcoma is a rare malignant tumor, usually arising in the uterine endometrium in about 87% of cases^(1,9,16) but occasionally in the endocervix in about 9% of cases^(9,11-15,17) or in the myometrium in about 4% of cases.⁽⁹⁾ In extremely rare cases, tumors arising in extrauterine sites, i.e. the peritoneum or pelvis,^(2,3,19) have been reported in the literature. Cervical adenosarcomas are rare and experience with their diagnosis and treatment is limited. The finding of a cervical polyp during a clinical examination often suggests a benign lesion. The microscopic appearance of the stromal component also may vary and often shows areas of unremarkable stroma adjacent to areas with mitotic activity and cytologic atypia. In addition, adenosarcoma are overdiagnosed pathologically because of the benign glandular epithelium and the low grade nature of the malignant stromal component which may have a deceptively benign appearance. However, several cervical adenosarcomas present with recurrent endocervical polyps^(17,18) whereas benign recurrent endocervical or endometrial polyps are unusual in women of reproductive age. A careful evaluation of mitotic activity and nuclear atypia should always be performed, and the possibility of an adenosarcoma considered in a patient with a history of recurrent polyps.

In this presented case, the age was 44 years is not much different from the 37 year mean age of adenosarcoma of the uterine cervix.⁽¹⁷⁾ In comparison, uterine adenosarcomas most often occur in postmenopausal women.⁽¹⁷⁾ This finding was quite similar to a series described by Clement and Scully,⁽²⁾ who pointed out that patients with

extrauterine adenosarcoma tended to be about 10 year younger than those with uterine adenosarcoma (average age 58 years).^(2,8,9,16)

This reported case had both classic initial presentation and findings of cervical adenosarcoma on pelvic examination. These are vaginal bleeding and the finding of a cervical polyp.⁽¹⁷⁾ Both endometrial and cervical adenosarcomas have the same most common symptoms and signs.^(9,17) In reviewing the literature, there are occasional associations of adenosarcoma with hyperestrinism (exogenous estrogen, Stein-Leventhal syndrome, ovarian thecoma) or prior pelvic radiation^(9,20) suggesting a possible etiology in some cases, similar to that suggested for malignant mullerian mixed tumors and other uterine sarcoma.⁽²¹⁻²³⁾ In the last 10 years there have been few reports of adenosarcoma in women who received tamoxifen treatment for carcinoma of the breast.^(24,25) These findings support the conclusion that, in addition to the more common association between hyperestrinism, endometrial hyperplasia and carcinoma, unopposed estrogenic stimulation may also occasionally play a role in the development of endometrial mesenchymal or mixed epithelial-mesenchymal neoplasms.

Histologic findings in this case showed the same features as described in the literature^(2,9) in which most of the glands were widely spaced throughout the stroma and were typically rounded, but in occasional cases forming elongated clefts or slit-like spaces. The glands were generally lined by a variety of benign appearing mullerian epithelia, which in order of frequency were proliferative endometrioid, endocervical, squamous, serous and secretory endometrioid.⁽⁹⁾ Adenosarcomas arising in

endocervix,⁽¹⁷⁾ including this case, were mostly lined by endocervical type epithelium with focal squamous metaplasia. The stromal component which appeared in majority of the cases,⁽⁹⁾ including this case, was more cellular around the glands, resulting in periglandular cuffs. In occasional cases, there was also a zone of increased stromal cellularity, or a cambium layer, beneath the surface epithelium of the tumor. Seventy eight percent of the sarcomatous stromal component consisted of homologous elements which included endometrial stromal sarcoma, fibrosarcoma and nonspecific sarcoma or a mixture of these. The remaining 22% of the sarcomatous component contained heterologous elements which were characterized as rhabdomyosarcoma, adipose tissue or cartilage. In this case, the mitotic index of the stroma was quite low, 2 mitotic figures per 10 under HPF, but it showed hypercellularity and a moderate degree of nuclear atypia. We use criteria proposed by Clement and Scully⁽⁹⁾ in which the diagnosis of adenosarcoma was made when one or more of the following criteria were present:

- 1) a stromal mitotic count of ≥ 2 mitotic figures per 10 under HPF
- 2) marked stromal cellularity
- 3) more than a mild degree of nuclear atypia of the stromal cells.

In addition, Kaku, et al⁽¹⁶⁾ reviewed 31 cases of uterine adenosarcoma and determined that the characteristic periglandular stromal cuffing was a more reliable criterion than the other parameters. Cervical adenosarcoma should be differentially diagnosed from several benign and malignant tumors. The most problematic lesion is adeno-

fibroma, in which both the epithelial and the stromal components are benign. However, a large clinicopathologic study by Clement and Scully,⁽⁹⁾ showed good reasons to use such criteria for diagnosing adenosarcoma in contrast to adenofibromas. Endocervical polyp can be composed of both benign elements. In the presence of inflammation it may show increased stromal cellularity and reactive nuclear atypia, but these changes are focal without mitotic activity.⁽²⁶⁾ Microglandular hyperplasia is a benign polypoid tumor that shows papillary configuration.^(27,28) It consists of glandular proliferation with back-to-back glands and squamous metaplasia. Mitotic activity is low (no more than 1 mitotic figure per 10 under HPF) in both the epithelium and the stroma and only mild cytologic atypia is seen. Embryonal rhabdomyosarcoma is one of the considerable possible candidate tumors because of its appearance as polypoid lesions. However, this tumor usually occurs at an earlier age, in the premenarchal youngster, while adenosarcoma is almost inevitably found in patients much older. Malignant mullerian mixed tumors, which have a grave prognosis, have foci in which the glandular component has frankly malignant features.⁽⁹⁾

Because the malignant potential of adenosarcoma is still undefined, the question of appropriate therapy remains unresolved. The series of Chen,⁽¹⁵⁾ and which had follow-up periods of 3 to 5 years, suggested that the potential for rapid metastatic spread of these tumors was small. It should be emphasized, however, that adenosarcomas are typically slowly growing indolent tumors and recurrence at 5 years or more postoperatively is not unusual.⁽⁹⁾ Long-term follow-up, therefore, is

essential in these patients. The optimal therapy for adenosarcoma of the uterus is hysterectomy, usually accompanied by bilateral salpingo-oophorectomy.⁽⁹⁾ Conservative therapy such as resection alone may be a consideration in younger patients in whom the preservation of reproductive function is important, particularly if the tumor is pedunculated and the resection margin of the tumor is negative.⁽¹¹⁾ Our patient underwent a total abdominal hysterectomy with bilateral salpingo-oophorectomy and surgical staging. Up to 25% of adenosarcoma ultimately recur, and these recurrences typically occur after many years and are often salvageable only through local resection. The only useful prognostic factors for recurrence in uterine adenosarcoma are the depth of the myometrial invasion and the presence of sarcomatous overgrowth (pure sarcoma accounting for at least 25% of the tumor volume).^(17,29) Both of these features could not be found in our case, however the long term follow-up program was still essential for her. Adjuvant therapy does not appear to reduce the risk of recurrence⁽⁹⁾ in adenosarcoma.

Conclusions

Mullerian adenosarcoma is an uncommon variant of mixed mullerian tumors. Adenosarcomas arising in the endocervix are even rarer, occurring in only 9% of all adenosarcomas. This tumor is of low malignant potential with an up to 25% recurrence rate. The most useful prognostic factors are the depth of the myometrial invasion and the presence of sarcomatous overgrowth.

References

1. Clement PB, Scully RE. Mullerian adenosarcoma of the uterus. A clinicopathologic analysis of ten cases of a distinctive type of mullerian mixed tumor. *Cancer* 1974 Oct;34(4): 1138-49
2. Clement PB, Scully RE. Extrauterine mesodermal (mullerian) adenosarcoma: a clinicopathologic analysis of five cases. *Am J Clin Pathol* 1978 Mar; 69(3): 276-83
3. Bard ES, Bard DS, Vargas -Cortes F. Extrauterine mullerian adenosarcoma: a clinicopathologic report of a case with distant metastases and review of the literature. *Gynecol Oncol* 1978 Jun; 6(3): 261-74
4. Russell P, Salvutin L, Lavery CR, Coope -Booth J. Extrauterine mesodermal (mullerian) adenosarcoma. A case report. *Pathology* 1979 Jul; 11(3): 557-60
5. Valdez VA, Planas AT, Lopez VF, Goldberg M, Herrera NE. Adenosarcoma of the uterus and ovary: a clinicopathologic study of two cases, *Cancer* 1979 Apr; 43(4): 1439-47
6. Kao GF, Norris HJ. Benign and low grade variants of mixed mesodermal tumor (adenosarcoma) of the ovary and adnexal region. *Cancer* 1978 Sep; 42(3): 1314-24
7. Oda Y, Nakanishi I, Tateiwa T. Intramural mullerian adenosarcoma of the uterus with adenomyosis. *Arch Pathol Lab Med* 1984 Oct; 108(10): 798-801
8. Zaloudek CJ, Norris HJ. Adenofibroma and adenosarcoma of the uterus: a clinicopathologic study of 35 cases. *Cancer* 1981 Jul 15; 48(2): 354-66

9. Clement PB, Scully RE. Mullerian adenosarcoma of the uterus; a clinicopathologic analysis of 100 cases with a review of the literature. *Haman Pathol* 1990 Apr; 21(4): 363-81
10. Abdul - Karim FW, Bazi TM, Sorensen K, Nasr MF. Sarcoma of the uterine cervix: clinicopathologic findings in three cases. *Gynecol Oncol* 1987 Jan; 26(1): 103-11
11. Gast MJ, Radkins LV, Jacob AJ, Gersell D. Mullerian adenosarcoma of the cervix with heterologous elements: diagnostic and therapeutic approach *Gynecol Oncol* 1989 Mar; 32(3): 381-4
12. Roth LM, Pride GL, Sharma HM. Mullerian adenosarcoma of the uterine cervix with heterologous elements. A light and electron microscopic study. *Cancer* 1976 Apr; 37(4): 1725-36
13. Tang CK, Toker C, Harriman B. Mullerian adenosarcoma of the uterine cervix. *Human Pathol* 1981 Jun; 12(6): 579-81
14. Kerner H, Lichtig C. Mullerian adenosarcoma presenting as cervical polyps : a report of seven cases and review of the literature. *Obstet Gynecol* 1993 May; 81(5 pt 1): 655-9
15. Chen KTK. Rhabdomyosarcomatous uterine adenosarcoma. *Int J Gynecol Pathol* 1985; 4(2): 146-52
16. Kaku T, Silverberg SG, Major FJ, Miller A, Fetter B, Brady MF. Adenosarcoma of the uterus: a Gynecological Oncology Group clinicopathologic study of 31 cases. *Int J Gynecol Pathol* 1992; 11(2): 75-88
17. Jones MW, Lefkowitz M. Adenosarcoma of the uterine cervix: a clinicopathological study of 12 cases. *Int J Gynecol Pathol* 1995 Jul; 14(3): 223-9
18. Inoue M, Fukuda H, Tanizawa O. Adenosarcomas originating from sites other than uterine endometrium: A case report. *Int J Gynecol Obstet* 1995 Mar; 48(3): 299-306
19. Kerner H, Lichtig C, Beck D. Extrauterine mullerian adenosarcoma of the peritoneal mesothelium: a clinicopathologic and electron microscopic study. *Obstet Gynecol* 1989 Mar; 73(3 pt 2): 510-3
20. Hariri J. Mullerian adenosarcoma of the endometrium: review of the literature and report of two cases. *Int J Gynecol Pathol* 1983; 2(2): 182-91
21. Press MF, Scully RE. Endometrial "sarcoma" complicating ovarian thecoma, polycystic ovarian disease and estrogen therapy. *Gynecol Oncol* 1985 Jun; 21(2): 135-54
22. Norris HJ, Taylor HB. Postirradiation sarcomas of the uterus. *Obstet Gynecol* 1965 Nov; 26(5): 689-94
23. Varela -Duran J, Nochomovitz LE, Prem KA, Dehner LP. Postirradiation mixed mullerian tumors of the uterus: a comparative clinicopathologic study. *Cancer* 1980 Apr 1; 45(7): 1625-31
24. Bocklage T, Lee KR, Belinson JL. Uterine mullerian adenosarcoma following adenomyoma in a woman on tamoxifen therapy. *Gynecol Oncol* 1992 Jan; 44(1): 104-9
25. Clement PB, Oliva E, Young RH. Mullerian adenosarcoma of the uterine corpus associated with tamoxifen therapy : a report of six cases and a review of tamoxifen-associated endometrial lesions. *Int J Gynecol Pathol*

- 1996 Jul; 15(3): 222-9
26. Aaro LA, Jacobson LJ, Soule EH. Endocervical polyps. *Obstet Gynecol* 1963 Jun; 21(6): 659-65
27. Govan ADT, Black WP, Sharp JL. Aberrant glandular polypi of the uterine cervix associated with contraceptive pills: pathology and pathogenesis. *J Clin Pathol* 1969 Jan; 22(1): 84-9
28. Leslie KO, Silverberg SG. Microglandular hyperplasia of the cervix: unusual clinical and pathologic presentations and their differential diagnosis. *Prog Surg Pathol* 1984; 5: 95-114
29. Silverberg SG, Kurman RJ. Tumors of the uterine corpus and gestational trophoblastic disease. In: Silverberg SG, Kurman RJ, eds. *Atlas of Tumor Pathology*. 3rd series. Fascicle 3, Washington, DC: Armed Forces Institute of Pathology, 1992: 156-66