

4-1-2000

## Single - dose systemic methotrexate therapy inpatients with suspected ectopic pregnancyA preliminary report

U. Tanslaruk

R. Aeng

P. Wongprachoom

Follow this and additional works at: <https://digital.car.chula.ac.th/clmjjournal>



Part of the [Medicine and Health Sciences Commons](#)

---

### Recommended Citation

Tanslaruk, U.; Aeng, R.; and Wongprachoom, P. (2000) "Single - dose systemic methotrexate therapy inpatients with suspected ectopic pregnancyA preliminary report," *Chulalongkorn Medical Journal*: Vol. 44: Iss. 4, Article 4.

Available at: <https://digital.car.chula.ac.th/clmjjournal/vol44/iss4/4>

This Article is brought to you for free and open access by the Chulalongkorn Journal Online (CUJO) at Chula Digital Collections. It has been accepted for inclusion in Chulalongkorn Medical Journal by an authorized editor of Chula Digital Collections. For more information, please contact [ChulaDC@car.chula.ac.th](mailto:ChulaDC@car.chula.ac.th).

Single - dose systemic methotrexate therapy in  
patients with suspected ectopic pregnancy :  
A preliminary report

Uthai Tanslaruk\*

Rungroj Aeng\* Punnapa Wongprachoom\*\*

Tanslaruk U, Aeng R, Wongprachoom P. Single - dose systemic methotrexate therapy in patients with suspected ectopic pregnancy : A preliminary report. Chula Med J 2000 Apr; 44(4): 267 - 75

- Objective** : *To evaluate the safety and efficacy of single-dose systemic methotrexate in the treatment of ectopic pregnancy*
- Setting** : *Department of Obstetrics and Gynecology, Nopparat Rajathanee Hospital, Bangkok , Thailand.*
- Design** : *Prospective study*
- Subject** : *Sixteen inpatients with an unruptured ectopic pregnancy who met the criteria for methotrexate therapy, from October 1998 to September 1999*
- Intervention** : *Single dose of methotrexate 50 mg/m<sup>2</sup> intramuscular injection. Blood samples for hCG titer were collected weekly until the hCG titer became normal (0 -10 mIU/ml).*
- Results** : *Patients had a mean age of 25.19 ± 6.28 years, a mean gravidity of 2.00 ± 1.03, and a mean parity of 0.69 ± 0.70. The mean human chorionic gonadotropin titer before treatment initiation was 3582.25 ± 3328.19 mIU/ml. The mean time to resolution for the 16 subjects successfully treated was 5.06 ± 2.08 weeks. No biochemical or clinical side effects occurred. Post - treatment hysterosalpingograms demonstrated*

\* Department of Obstetrics and Gynecology, Nopparat Rajathanee Hospital

\*\* Nursing department , Nopparat rajathanee Hospital

*tubal patency on the ipsilateral side in 6 of 7 (85.7%) patients. Two patients were intrauterine pregnant.*

**Conclusions** : *Single - dose systemic methotrexate in the treatment of ectopic pregnancy is safe, effective and can help preserve reproductive capability when used in carefully selected patients.*

**Key words** : *Methotrexate , Ectopic pregnancy.*

Reprint request : Tanlaruk U, Department of Obstetrics and Gynecology, Nopparat  
Rajathanee Hospital

Received for publication. December 2, 1999.

อุทัย ตันศลารักษ์, รุ่งโรจน์ เอง, ปุณณภา วงษ์ประชุม. การรักษาผู้ป่วยตั้งครรภ์นอกมดลูกด้วย Methotrexate ฉีดเข้ากล้ามเนื้อครั้งเดียว : รายงานเบื้องต้น. จุฬาลงกรณ์เวชสาร 2543 เม.ย; 44(4): 267-75

- วัตถุประสงค์** : เพื่อศึกษาความปลอดภัย และประสิทธิภาพของการรักษาผู้ป่วยตั้งครรภ์นอกมดลูกด้วย Methotrexate ฉีดเข้ากล้ามเนื้อครั้งเดียว
- สถานที่ที่ทำการศึกษา** : กลุ่มงานสูติ - นรีเวช โรงพยาบาลนพรัตนราชธานี กรมการแพทย์ กระทรวงสาธารณสุข
- รูปแบบการวิจัย** : การศึกษาไปข้างหน้า
- ผู้ป่วยที่ได้ทำการศึกษา** : ผู้ป่วยตั้งครรภ์นอกมดลูกจำนวน 16 ราย ที่มีคุณสมบัติตามเกณฑ์ที่จะให้ยา Methotrexate ในช่วงเวลาเดือนตุลาคม พ.ศ. 2541 ถึงเดือนกันยายน พ.ศ. 2542
- วิธีการศึกษา - วัตถุประสงค์** : ให้ยา Methotrexate 50 มก./ม.<sup>2</sup> ฉีดเข้ากล้ามเนื้อครั้งเดียว เจาะเลือดดูระดับ hCG ทุกสัปดาห์ จนกว่าผลเลือดจะปกติ (0-10 mIU/ml)
- ผลการศึกษา** : ผู้ป่วยมีอายุเฉลี่ย  $25.19 \pm 6.28$  ปี จำนวนการตั้งครรภ์เฉลี่ย  $2.00 \pm 1.03$  จำนวนบุตรเฉลี่ย  $0.69 \pm 0.70$  ระดับ hCG ก่อนการรักษาเฉลี่ย  $3582.25 \pm 3328.19$  mIU/ml ระยะเวลาที่ใช้รักษาประสบความสำเร็จทุกราย เฉลี่ย  $5.06 \pm 2.08$  สัปดาห์ ไม่พบอาการข้างเคียงจากการให้ยา หลังการรักษาตรวจ Hysterosalpingogram พบว่ามีปีกมดลูกข้างที่เป็นการตั้งครรภ์นอกมดลูกไม่ตัน 6 ใน 7 ราย (ร้อยละ 85.71) ขณะรายงานมีผู้ป่วยตั้งครรภ์ในมดลูก 2 ราย
- วิจารณ์และสรุป** : การรักษาผู้ป่วยตั้งครรภ์นอกมดลูกด้วย Methotrexate ฉีดเข้ากล้ามเนื้อครั้งเดียว มีความปลอดภัยและมีประสิทธิภาพดี ช่วยให้ความสามารถในการมีบุตรยังคงอยู่ โดยเฉพาะเมื่อนำมาใช้ในผู้ป่วยที่ได้รับการคัดกรองด้วยความระมัดระวัง

The combination of sensitive human chorionic gonadotropin (hCG) assays and ultrasonography assists in early diagnosis of unruptured ectopic pregnancies. Early diagnosis and treatment may reduce morbidity and mortality and continue fertility. In the past, after laparoscopy confirmed the diagnosis of ectopic pregnancy, patients underwent laparotomy to complete the surgical treatment. Recent modifications in operative laparoscopic instrumentation and technique have permitted the endoscopic approach to ectopic pregnancy, with potential reduction in morbidity and duration of hospitalization.<sup>(1)</sup>

If the necessity for laparoscopy to diagnose ectopic pregnancy is eliminated, treatment with intramuscular methotrexate can offer the advantages of decreased cost, avoidance of anesthetic and laparoscopic – related morbidity, and less time lost from the patient's daily activities. Many studies of ectopic pregnancy treated with variable dose methotrexate have been reported.<sup>(2-4)</sup> Stovall et al<sup>(4)</sup> reported their experience with minimally invasive diagnostic techniques combined with a single-dose (50 mg/m<sup>2</sup>) intramuscular methotrexate treatment protocol for selected unruptured ectopic pregnancies. The purpose of this study was to evaluate the safety and efficacy of single - dose intramuscular methotrexate in the treatment of selected unruptured ectopic pregnancies.

### Materials and Methods

Between October 1, 1998 and September 30, 1999, all patients presenting to the Emergency Department of Nopparat Rajathanee Hospital and those in the out - patient clinics suspected of ectopic pregnancy underwent a urine pregnancy test. If the

results of the urine pregnancy test were positive, the patients were managed according to their conditions. Patients with signs and symptoms of ruptured ectopic pregnancy who were hemodynamically unstable underwent an emergency laparotomy. If the patients were clinically stable and without signs of hemoperitoneum they were admitted and transabdominal ultrasonography were evaluated to rule out an intrauterine pregnancy and look for pathological signs of ectopic pregnancy. In cases of suspected unruptured ectopic pregnancy, diagnosis was confirmed by transvaginal ultrasonography, then hCG (First International Preparation) and serum progesterone were measured. Patients were diagnosed as having an ectopic pregnancy by means of a nonlaparoscopic diagnostic algorithm (Fig.1) that combines the use of serial hCG titers, serum progesterone, transvaginal ultrasonography, and curettage. The sensitivity and specificity of this diagnostic algorithm is well established.<sup>(4,5,8,9)</sup>

Patients with hCG levels < 2000 mIU/ml and a serum progesterone level < 5.0 ng/ml underwent curettage and were followed according to the diagnostic algorithm. Patients with a rising hCG titer  $\geq$  2000 mIU/ml without an associated intrauterine sac visualized by transvaginal ultrasonography did not require pretreatment curettage.

Inclusion criteria for methotrexate therapy included (1) hCG titer  $\geq$  2000 mIU/ml with no intrauterine pregnancy by transvaginal ultrasonography, (2) the hCG titers increased after curettage, if performed, (3) they were hemodynamically stable, (4) transvaginal ultrasonography demonstrated an unruptured ectopic pregnancy  $\leq$  3.5 cm in greatest dimension and/or absent of fetal cardiac activity in

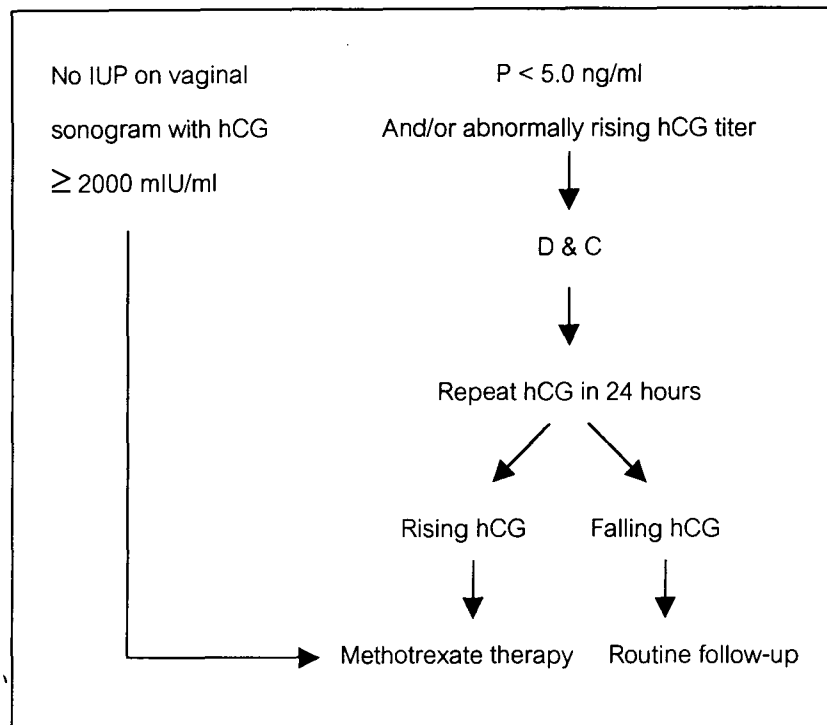


Figure 1. Diagnostic algorithm for ectopic pregnancy.

an extrauterine gestational sac, (5) hCG titer < 10000 mIU/ml, (6) no biochemical evidence of hepatic, renal, or hematologic dysfunction, (7) no evidence of HIV infection (8) they signed an informed consent agreement after clear counselling.

All patients were treated as inpatients with a single - dose intramuscular injection of methotrexate (50 mg/m<sup>2</sup>). Patients were informed that pelvic discomfort after treatment required re-examination to rule out possible tubal rupture and intra-abdominal hemorrhage. Re -examination included a transvaginal ultrasonography, physical examination, and a CBC. Patients were instructed to abstain from alcohol or intercourse until complete resolution of the ectopic pregnancy. Patients were instructed to use oral contraceptive pills for at least 3 months after treatment completion. Serum hCG was repeated on day 4 and weekly thereafter until hCG titer < 10 mIU/ml.

A hysterosalpingogram was performed after the second menstrual cycle after treatment completion. Patients were contacted by telephone or letter every 6 months to seek information regarding any conception that had occurred after treatment.

## Results

During the study period, there were 10,189 deliveries and 110 cases of ectopic pregnancy, giving an overall incidence of 10.8 ectopic pregnancies per 1,000 deliveries. In accordance with the protocol, 16 (14.55%) were treated by intramuscular injection of methotrexate (50 mg/m<sup>2</sup>) and 94 (85.45%) were treated surgically. The 16 women treated by methotrexate included 2 patients where transvaginal ultrasonography demonstrated ectopic pregnancy at the cornu. The diagnosis of ectopic pregnancy was established by rising hCG concentrations after negative endometrial

curettings in 9 of 16 (56.2%) patients treated with methotrexate. Villi was not demonstrated by histologic pathology in all curetting endometrium.

Patients had mean ages of  $25.19 \pm 6.28$  years, a mean gravidity of  $2.00 \pm 1.03$ , and mean parity of  $0.69 \pm 0.70$  (Table 1). The pretreatment hCG titer ranged from 345 - 8975 mIU/ml, with a mean of  $3528.25 \pm 3328.19$  mIU/ml. The mean time to

resolution of hCG was  $5.06 \pm 2.08$  weeks (range 2-9 weeks). Most of them were employees and housewives (Table 2).

All patients demonstrated the pathologic findings by vaginal ultrasonography (Table 3). Most of them were adnexal masses with fluid in a cul de sac.

Table 1. Patient Characteristic.

Patient characteristic	Range	Mean
1. Age (yr.)	17 - 39	$25.19 \pm 6.28$
2. Gravida	1 - 5	$2.00 \pm 1.03$
3. Parity	0 - 2	$0.69 \pm 0.70$
4. Abortion	0 - 2	$0.31 \pm 0.60$
5. Gestational age (day)	28 - 107	$51.15 \pm 21.19$
6. Hematocrit (%)	31 - 38	$33.94 \pm 2.69$
7. Initial hCG (mIU/ml)	345 - 8975	$3582.25 \pm 3328.19$
8. hCG resolution (wks)	2 - 9	$5.06 \pm 2.08$
9. Hospital stay (day)	2 - 7	$3.75 \pm 1.29$

Table 2. Occupation.

Occupation	All ectopic pregnancy	Methotrexate therapy
1. Housewives	31 (28.6 %)	5 (31.25%)
2. Employees	56 (50.9 %)	5 (31.25 %)
3. Business	3 (2.3 %)	1 (6.25 %)
4. Civil servants	6 (5.5 %)	2 (10.5 %)
5. Student	10 (9.1 %)	2 (12.5 %)
6. Other	4 (3.4 %)	1 (6.25 %)
<b>Total</b>	<b>110</b>	<b>16</b>

Table 3. Ultrasound finding.

Ultrasound finding	Number of patient
1. Adnexal sac	2 (12.5 %)
2. Adnexal mass	1 (6.25 %)
3. Fluid in cul de sac	1 (6.25 %)
4. Sac with fetal echo and fluid in cul de sac	1 (6.25 %)
5. Adnexal sac and fluid in cul de sac	1 (6.25 %)
6. Adnexal mass and fluid in cul de sac	10 (62.5 %)
Total	16 (100 %)

All patients meeting the criteria for methotrexate therapy were successfully treated with a single dose of methotrexate. There were no biochemical or clinical side effects noted. Hysterosalpingograms were obtained in 7 patients. Tubal patency was demonstrated on the ipsilateral side in 6 (85.71%). Two patients became intrauterine pregnancies before their hysterosalpingograms were performed.

#### Discussion

The ability to diagnose ectopic pregnancy without laparoscopy coupled with single - dose methotrexate appears to be as effective as the previously studied multidose regimen<sup>(3,4)</sup> but has the advantages of requiring less methotrexate, eliminating side effects, increasing the safety and patient acceptance, and having less cost. In this study, no side effects were detected in any patient, and abdominal pain was improved on the following day.

Stovall et al<sup>(5)</sup> confirmed that most gestational sacs were visualized at an hCG titer of 1,000 mIU/ml, but all were visualized at a level of  $\geq 2,000$  mIU/ml. Some investigators<sup>(6,7)</sup> reported that at an hCG

level between 1,000 – 1,500 mIU/ml, intrauterine gestational sacs could be detected by using transvaginal ultrasonography. In this study we used the discriminatory hCG zone at a level of 2,000 mIU/ml to add a considerable safety margin. Thus, patients with no evidence of an intrauterine pregnancy and hCG level  $\geq 2,000$  mIU/ml were given a diagnosis of ectopic pregnancy and did not require pretreatment curettage. In this group, ectopic pregnancy was diagnosed in 7 of 16 (43.75%) patients. The others had hCG levels  $< 2,000$  mIU/ml and progesterone levels  $< 5.0$  ng/ml and were given the pretreatment curettage. According to Stovall's algorithm,<sup>(8,9)</sup> the patients having unchanged or persistently rising hCG (24 hours after curettage was performed ) were identified as ectopic pregnancies and treated medically.

Some authors<sup>(10,11)</sup> do not recommend the use of methotrexate when an ectopic pregnancy is associated with a serum hCG concentration exceeding 10,000 mIU/ml. The risk of tubal rupture or bleeding in cases of unruptured tubal pregnancy with initial serum hCG concentrations  $> 10,000$  mIU/ml treated with methotrexate is 32 per cent, whereas the risk is



only 3 percent when the initial hCG concentration is < 10,000 mIU/ml. Stovall et al<sup>(2)</sup> suggested that the presence of cardiac activity is a relative contraindication because successful treatments were eighty per cent. In this study, we recommend surgical intervention for those patients with presence of cardiac activity in the ectopic pregnancy as well as those with greater than 3.5 cm in greatest dimension<sup>(2)</sup> to improve of safety and efficacy of the methotrexate therapy.

Although overall success of treatment, measured as no surgical intervention, was 87 - 95 %, <sup>(10)</sup> the risk of secondary surgical intervention after methotrexate therapy was related to the initial hCG concentration, the method of methotrexate administration, methotrexate dosage and presence of cardiac activity. In this study, with more strict inclusion criteria, all patients were successfully treated without second doses of methotrexate. Tubal patency was found : 6 of the 7 (85.71 per cent) patients evaluated, compared with 82.3 per cent reported by Stovall and Ling.<sup>(4)</sup> There were two intrauterine pregnancies, confirmed by using transvaginal ultrasonography before the hysterosalpingography was established.

The potential advantages of systemic methotrexate therapy are a completely nonsurgical management of ectopic pregnancy, if no diagnostic laparoscopy is performed to establish the diagnosis, and an improved homolateral tubal patency rate through avoidance of surgical trauma to the tube. However, the clinician should consider the psychological consequence of methotrexate therapy, especially with patients' health - related quality of life. Methotrexate treated patients had more limitations in physical functioning, role functioning, and social

functioning ; had worse health perceptions, less energy, more pain, more physical symptoms, and a worse overall quality of life, and were more depressed than surgically treated patients.<sup>(12,13)</sup>

The results of our study support the use of single - dose methotrexate for treatment of ectopic pregnancy in carefully selected patients. The key to successful medical therapy and improved reproductive outcome is early diagnosis, which is critical to reducing morbidity and mortality and provides the option of using nonsurgical therapy.

#### References

1. Pouly JL , Mahnes H , Mage G , Canis M , Bruhat MA. Conservative laparoscopic treatment of 321 ectopic pregnancies. *Fertil Steril* 1986 Dec; 46(6): 1093-7
2. Stovall TG, Ling FW, Gray LA, Carson SA, Buster JE. Methotrexate Treatment of unruptured ectopic pregnancy : a report of 100 cases. *Obstet Gynecol* 1991 May; 77(5): 749-53
3. Glock JL, Johnson JV, Brumsted JR. Efficacy and safety of single-dose systemic methotrexate in the treatment of ectopic pregnancy. *Fertil Steril* 1994 Oct; 62(4): 716-21
4. Stovall TG, Ling FW. Single-dose methotrexate : an expanded clinical trial. *Am J Obstet Gynecol* 1993 Jun; 168 (6 pt 1): 1759-65
5. Stovall TG, Ling FW. Ectopic pregnancy. Diagnostic and therapeutic algorithms minimizing surgical intervention. *J Reprod Med* 1993 Oct; 38(10); 807-12
6. Ankum WM, Van der Veen F, Hamerlynck JV, Lammes FB. Laparoscopy: a dispensable tool in the diagnosis of ectopic pregnancy? *Hum*

- Reprod 1993 Aug; 8(8): 1301-6
7. Fossum GT, Davajan V, Kletsky OA. Early detection of pregnancy with transvaginal ultrasound. Fertil Steril 1988 May; 49(5): 788-91
8. Stovall TG, Ling FW, Carson SA, Buster JE. Serum progesterone and uterine curettage in differential diagnosis of ectopic pregnancy. Fertil Steril 1992 Feb; 57(2): 456-8
9. Stovall TG, Ling FW, Carson SA, Buster JE. Nonsurgical diagnosis and treatment of tubal pregnancy. Fertil Steril 1990 Sep; 54 (3): 537-8
10. Kooi S, Kock H C. A review of the literature on nonsurgical treatment in tubal pregnancies. Obstet Gynecol Surv 1992 Nov; 47(11): 739-49
11. Hajenius PJ, Engelsbel S, Mol BW, Van der Veen F, Ankum WM, Bossuyt PM, Hemrika DJ, Lammes FB. Randomised trial of systemic methotrexate versus Laparoscopic salpingostomy in tubal pregnancy. Lancet 1997 Sep 13; 350 (9080): 774-9
12. Nieuwkerk PT, Hajenius PJ, Ankum WM, Vander Veen F, Wijker W, Bossuyt PM. Systemic methotrexate therapy versus laparoscopic salpingostomy in patients with tubal pregnancy. Part I. Impact on patient' health-related quality of life. Fertil Steril 1998 Sep; 70(3):511-7
13. Nieuwkerk PT, Hajenius PJ, Van der Veen F, Ankum WM, Wijker W, Bossuyt PM. Systemic methotrexate therapy versus laparoscopic salpingostomy in tubal pregnancy. Part II. Patient preferences for systemic methotrexate. Fertil Steril 1998 Sep; 70(3): 518-22