

6-1-2000

## Postoperative seizure after intraoperativemyelography with iopamidol

T. Werawatganon

S. Kupniratisaikul

Follow this and additional works at: <https://digital.car.chula.ac.th/clmjjournal>



Part of the [Medicine and Health Sciences Commons](#)

---

### Recommended Citation

Werawatganon, T. and Kupniratisaikul, S. (2000) "Postoperative seizure after intraoperativemyelography with iopamidol," *Chulalongkorn Medical Journal*: Vol. 44: Iss. 6, Article 8.

Available at: <https://digital.car.chula.ac.th/clmjjournal/vol44/iss6/8>

This Case Report is brought to you for free and open access by the Chulalongkorn Journal Online (CUJO) at Chula Digital Collections. It has been accepted for inclusion in Chulalongkorn Medical Journal by an authorized editor of Chula Digital Collections. For more information, please contact [ChulaDC@car.chula.ac.th](mailto:ChulaDC@car.chula.ac.th).

## Postoperative seizure after intraoperative myelography with iopamidol

Thewarug Werawatganon\*

Somsak Kupniratisaikul\*\*

Werawatganon T, Kupniratisaikul S. Postoperative seizure after intraoperative myelography with iopamidol. Chula Med J 2000 Jun; 44(6): 447 - 52

*A 73 year old male patient developed seizures after an intraoperative myelogram with iopamidol, a nonionic water-soluble contrast medium. The seizure was less severe than convulsion after myelogram with ionic contrast media and self-limited after conservative treatment. Physicians should be aware of the risk and use iopamidol with caution.*

**Key words:** *Iopamidol, Seizure, Myelography, Contrast medium.*

Reprint request : Werawatganon T, Department of Anesthesiology, Faculty of Medicine,  
Chulalongkorn University, Bangkok 10330, Thailand.

Received for publication. January 10, 2000.

---

\* Department of Anesthesiology, Faculty of Medicine, Chulalongkorn University

\*\*Department of Orthopedic Surgery, Faculty of Medicine, Chulalongkorn University

เทวารักษ์ วีระวัฒนกานนท์, สมศักดิ์ คุปนิริติชัยกุล. อาการชักหลังผ่าตัดจากการฉีดสารทึบรังสี iopamidol เข้าช่องไขสันหลัง. จุฬาลงกรณ์เวชสาร 2543 มิ.ย; 44(6): 447 - 52

ผู้ป่วยชายอายุ 73 ปี เกิดอาการชักเริ่มจากแขนแล้วกระจายไปทั่วตัวหลังจากการผ่าตัดกระดูกสันหลัง ผู้ป่วยได้รับการฉีดสารทึบรังสีทางช่องไขสันหลังด้วยยา iopamidol ซึ่งเป็นสารทึบรังสีกลุ่ม nonionic water soluble อาการชักไม่รุนแรงและสามารถหายได้เองหลัง 24 ชั่วโมงโดยอาศัยยากันชักเป็นครั้งคราว การฉีดสารทึบรังสีเข้าช่องไขสันหลังในระหว่างผ่าตัดมีความเสี่ยงต่อการชักได้ จึงควรจำกัดการใช้และทำด้วยความระมัดระวัง

A 73 year old patient came to the hospital with chief complaint of pain in the right chest for the prior four months. The pain radiated to the left scapular area and was associated with progressive neurological deficit. The symptoms included hypalgesia from the chest down to the feet and slight weakness of the lower limbs. Finally, there were abnormalities in urination and defecation. The patient had a history of heavy drinking and smoking. A previous operation was a transurethral resection of the prostate gland with pathologic diagnosis of benign prostate hypertrophy. He denied other medical problems or any allergic reaction history to any medications.

Physical examination revealed normal vital signs, blood pressure 100/70 mmHg, pulse rate 70 beats/min, respiratory rate 16 /min, body temperature 36.5°C. A decreased sensation to pin prick from the level of T4 was found with the power of lower extremities grade IV/V. Barbinski and clonus signs were normal.

Magnetic resonance imaging of the spine displayed a collapse of vertebral body at T4. The patient underwent an uneventful anterior decompression and the tissue pathologic report was adenocarcinoma. Four weeks later the symptoms had not improved so he was scheduled for a posterior decompression with intraoperative myelography. The anesthesia was started with thiopental induction and intubation was facilitated by succinylcholine. Maintenance was performed by neuroleptanesthesia with droperidol, fentanyl, nitrous oxide and atracurium. During the operation in the prone position, the blood pressure rose to 180/90 and was interpreted as inadequate anesthesia so sevoflurane was added. An intraoperative myelogram was performed by the

surgeon using 9 ml of iopamidol (300 mg iodine /ml) and did not demonstrate any abnormality. Estimated blood loss was 2500 ml. and had been replaced with five units of whole blood. Total anesthetic time was 5 hours. After termination of the inhalation anesthetic agents, muscle relaxant reversal with neostigmine 2.5 mg and atropine 1.2 mg was given. Five minute later the patient began to convulse from the face down to the hand and generalized convulsions developed. This episode was repeated intermittently every 5 -10 minutes so intravenous diazepam was ordered to control the convulsions. The patient was transferred to the surgical intensive care unit and his ventilation was supported via endotracheal tube. Neurological examination by a neurologist showed unconsciousness without focal neurological deficit. The patient was sent for an emergency computerized tomographic scan of the head. The report from the radiologist on duty was generalized subarachnoid hemorrhage and conservative treatment was chosen by neurosurgeon. The next day the radiological report was corrected by the senior radiologist to be subarachnoid spreading of contrast media (Fig 1). The patient regained consciousness at 24 hours after myelography and was free of convulsions. The condition remained stable until discharge about one month later.

### Discussion

The cause of immediate postoperative convulsions in this patient was a challenging problem. One of the metabolites of atracurium, laudanosine, could induce seizures but there were reports only in renal failure cases who received high doses of atracurium and could not get rid of the metabolite via the kidney.<sup>(1)</sup> This patient had no history of epilepsy

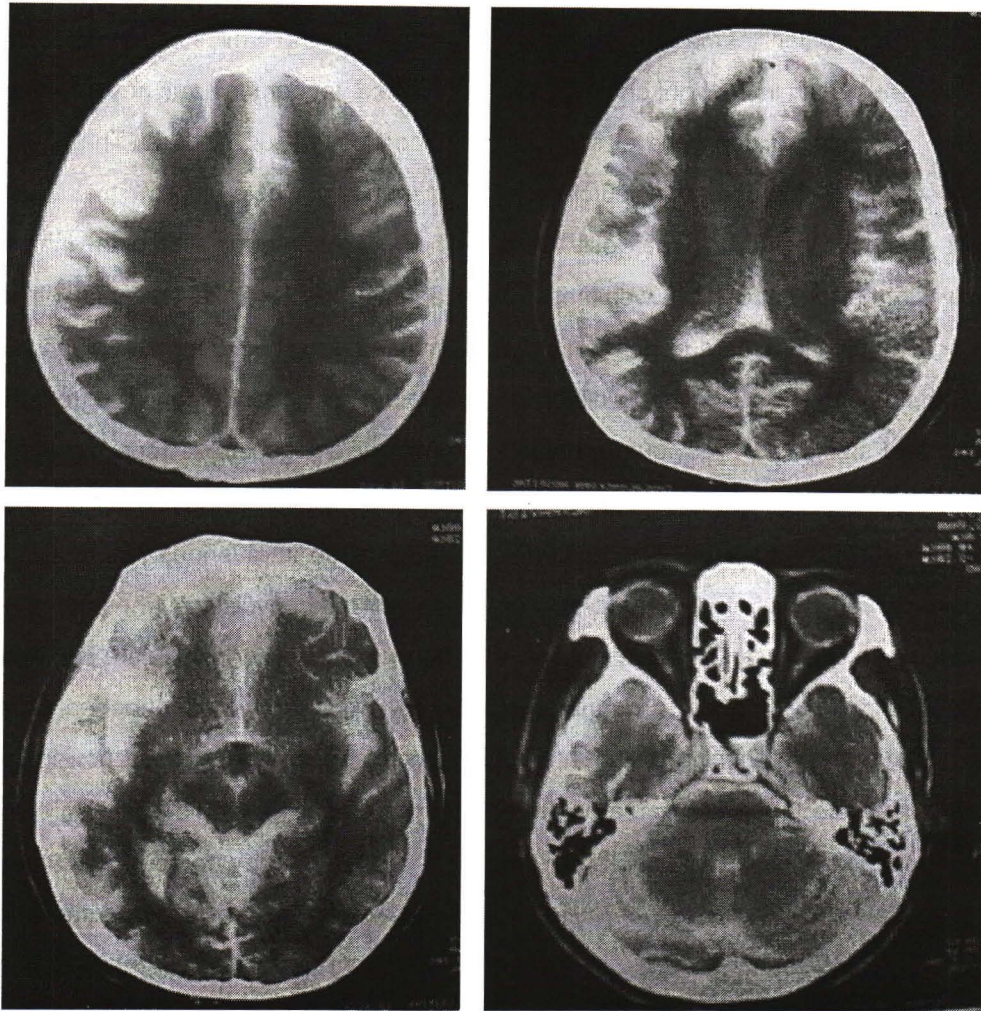


Figure 1. Computerized x-ray tomography report revealed evidence of contrast material remaining in subarachnoid space and ventricles.

and the convulsions started with focal seizure. So there might have been some intracranial lesion such as an intracerebral hemorrhage and epilepsy could be ruled out. The patient had unstable blood pressure throughout the operation and a primary radiological report of subarachnoid hemorrhage made us feel uneasy at first.

There have been were some reports about convulsions after myelogram with ionic contrast media such as meglumine diatrizoate (hypaque).<sup>(2, 3)</sup> Ionic contrast media are more toxic to nervous system than

nonionic contrast media. Osmolality is an adverse factor Ionic contrast media have higher osmolality than nonionic type (Table 1) and therefore more easily disrupt tight junction between the cells of blood-brain barrier, promoting brain edema and decrease cerebral blood flow. Another possible mechanism is the change in neuronal transmitter metabolism. Hypertonicity as well as chemical structure of x-ray media may induce both excitatory and inhibitory effect on neurons. An inadvertent subarachnoid injection of ionic contrast media could result in convulsions and a fatal outcome.<sup>(4)</sup>

Table 1. Comparison of iopamidol and meglumine diatrizoate.

Contrast media	Iopamidol	Meglumine Diatrizoate
Trade name	Iopamine, Solustrast	Hypaque 60
Type	Nonionic	Ionic
Partition coefficient*	0.110	0.045
Osmotic pressure (Mpa)	1.59	3.95
Osmolality (mOsm/ kg H <sub>2</sub> O)	640	1530

\*n - butanol / buffer; pH 7.6; 0.01 mg Iodine/ml

Iopamidol, a water-soluble nonionic contrast medium, has rarely been associated with seizures (1:1138).<sup>(5)</sup> Reported cases had a history of epilepsy and received a high dose (3000 - 6000 mg of iodine) and/or injected at a high cervical level.<sup>(6)</sup> We used this nonionic and low osmolality contrast media injected at lower site of the operative field and with a lower dose of the iodine. But the patient was in a prone position with the head below the horizontal level, so that the contrast medium, which was hyperbaric, could move down with gravity and enter the head. Iopamidol has been found to be epileptogenic in animals and has higher osmolality than cerebrospinal fluid.<sup>(6)</sup> Seizures could occur but are not very severe and require only conservative treatments included anticonvulsants and airway and respiratory support.

If an intraoperative myelogram is unavoidable, there should be some caution. Use only nonionic, low osmolality contrast media with low doses and inject at a low spinal level. Follow the contrast media by fluoroscopy and when it reaches the lesion adjust the operating table so that the head is up and the contrast media does not move up and enter the head.

### Conclusions

We reported a case of iopamidol induced seizures after an intraoperative myelogram. Physicians should be aware of the risks, even though seizures have rarely been noted in clinical trials with nonionic contrast media. So avoid intraoperative myelogram, otherwise perform with caution.

### References

1. Pollard BJ. Neuromuscular blocking drugs and renal failure. *Br J Anaesth* 1992 Jun; 68(6): 545 - 7
2. Bohn HP, Reich L, Suljaga-Petchel K. Inadvertent intrathecal use of ionic contrast media for myelography. *Am J Neuroradiol* 1992 Nov; 13(6): 1515 - 9
3. Karl HW, Talbott GA, Roberts TS. Intraoperative administration of radiologic contrast agents: potential neurotoxicity. *Anesthesiology* 1994 Oct; 81(4): 1068 - 71
4. Hilz MJ, Huk W, Schellmann B, Sorgel F, Druschky KF. Fatal complications after myelography with meglumine diatrizoate. *Neuroradiology* 1990; 32(1): 70 - 3

5. Bassi P, Cecchini A, Dettori P, Signorini E. Myelography with iopamidol, a nonionic water-soluble contrast medium: incidence of complications. *Neuroradiology* 1982; 24(2): 85-90
6. Levey AI, Weiss H, Yu R, Wang H, Krumholz A. Seizures following myelography with iopamidol. *Ann Neurol* 1988 Apr; 23(4): 397 - 9