

Chulalongkorn University

## Chula Digital Collections

---

Chulalongkorn University Theses and Dissertations (Chula ETD)

---

2018

### Chondroprotective efficacy of pcso-524 on canine osteoarthritis secondary to medial patellar luxation

Ratthanan Sathienbumrunkit  
*Faculty of Veterinary Science*

Follow this and additional works at: <https://digital.car.chula.ac.th/chulaetd>



Part of the [Veterinary Medicine Commons](#)

---

#### Recommended Citation

Sathienbumrunkit, Ratthanan, "Chondroprotective efficacy of pcso-524 on canine osteoarthritis secondary to medial patellar luxation" (2018). *Chulalongkorn University Theses and Dissertations (Chula ETD)*. 2671.

<https://digital.car.chula.ac.th/chulaetd/2671>

This Thesis is brought to you for free and open access by Chula Digital Collections. It has been accepted for inclusion in Chulalongkorn University Theses and Dissertations (Chula ETD) by an authorized administrator of Chula Digital Collections. For more information, please contact [ChulaDC@car.chula.ac.th](mailto:ChulaDC@car.chula.ac.th).

CHONDROPROTECTIVE EFFICACY OF PCSO-524 ON CANINE OSTEOARTHRITIS  
SECONDARY TO MEDIAL PATELLAR LUXATION

Miss Ratthanan Sathienbumrunkit



A Thesis Submitted in Partial Fulfillment of the Requirements  
for the Degree of Master of Science in Veterinary Surgery

Department of Veterinary Surgery

Faculty of Veterinary Science

Chulalongkorn University

Academic Year 2018

Copyright of Chulalongkorn University

ประสิทธิภาพในการปกป้องผิวกระดูกอ่อนของพีซีเอสโอห้าสองสี่ในสุนัขที่เป็นโรคข้อเสื่อมที่เกิดจาก  
โรคสะบ้าเคลื่อนด้านใน



วิทยานิพนธ์นี้เป็นส่วนหนึ่งของการศึกษาตามหลักสูตรปริญญาวิทยาศาสตรมหาบัณฑิต  
สาขาวิชาสัตวศาสตร์ทางสัตวแพทย์ ภาควิชาสัตวศาสตร์  
คณะสัตวแพทยศาสตร์ จุฬาลงกรณ์มหาวิทยาลัย  
ปีการศึกษา 2561  
ลิขสิทธิ์ของจุฬาลงกรณ์มหาวิทยาลัย

Thesis Title	CHONDROPROTECTIVE EFFICACY OF PCSO-524 ON CANINE OSTEOARTHRITIS SECONDARY TO MEDIAL PATELLAR LUXATION
By	Miss Ratthanan Sathienbumrunkit
Field of Study	Veterinary Surgery
Thesis Advisor	Assistant Professor KUMPANART SOONTORNVIPART, D.V.M., Ph.D., D.T.B.V.S.

---

Accepted by the Faculty of Veterinary Science, Chulalongkorn University in  
Partial Fulfillment of the Requirement for the Master of Science

..... Dean of the Faculty of Veterinary  
Science

(Professor ROONGROJE THANAWONGNUWECH, D.V.M.,  
M.Sc., Ph.D., D.T.B.V.P.)

#### THESIS COMMITTEE

..... Chairman

(Assistant Professor SUMIT DURONGPHONGTORN, D.V.M.,  
Ph.D., D.T.B.V.S.)

..... Thesis Advisor

(Assistant Professor KUMPANART SOONTORNVIPART,  
D.V.M., Ph.D., D.T.B.V.S.)

..... Examiner

(Assistant Professor NAN CHOISUNIRACHON, D.V.M., M.Sc.,  
Ph.D., D.T.B.V.S.)

..... Examiner

(Associate Professor SAYAMON SRISUWATANASAGUL,  
D.V.M., M.Sc., Ph.D.)

..... External Examiner

(Assistant Professor Monchanok Vijarnsorn, D.V.M., M.Sc.,  
Ph.D., D.T.B.V.S.)

รัฐนันท์ เสถียรบำรุงกิจ : ประสิทธิภาพในการปกป้องผิวกระดูกอ่อนของพีซีเอสโอห้าสอง  
สี่ในสุนัขที่เป็นโรคข้อเสื่อมที่เกิดจากโรคสะบ้าเคลื่อนด้านใน. (

CHONDROPROTECTIVE EFFICACY OF PCSO-524 ON CANINE

OSTEOARTHRITIS SECONDARY TO MEDIAL PATELLAR LUXATION) อ.ที่ปรึกษา

หลัก : ผศ.น.สพ.ดร.กัมปนาท สุนทรวิภาต

การศึกษานี้ประกอบด้วยข้อเข่าจำนวน 50 ข้อเข่า แบ่งออกเป็นข้อเข่าปกติจำนวน 8 ข้อ และข้อเข่าที่เป็นโรคสะบ้าเคลื่อนด้านในจำนวน 42 ข้อ ซึ่งถูกแบ่งออกเป็น 2 กลุ่ม ได้แก่ กลุ่มควบคุมซึ่งได้รับยาหลอก (20 ข้อเข่า) และกลุ่มทดลองซึ่งได้รับพีซีเอสโอห้าสองสี่ (22 ข้อเข่า) โดยสุนัขจะได้รับยาติดต่อกันทุกวันเป็นระยะเวลา 16 สัปดาห์ สุนัขทุกตัวจะได้รับการประเมินระดับการเดินกะเผลก การประเมินทางอัลตราซาวด์ การประเมินข้อเสื่อมจากภาพถ่ายทางรังสีวิทยา และประเมินความเจ็บปวดโดยใช้แบบสอบถาม สำหรับการอัลตราซาวด์ จะทำการประเมินลักษณะต่างๆโดยการให้คะแนน ได้แก่ คะแนนน้ำในข้อเข่า คะแนนกระดูกอ่อน คะแนนผิวกระดูก และคะแนนรวมของทางอัลตราซาวด์ สุนัขที่เป็นโรคสะบ้าเคลื่อนด้านในทุกตัวจะได้รับการตรวจและประเมินคะแนนวันแรกก่อนได้รับยา และหลังได้รับยาสัปดาห์ที่ 2, 4, 8, 12 และ 16 ผลการศึกษาพบว่าคะแนนรวมของการประเมินทางอัลตราซาวด์ คะแนนน้ำในข้อเข่า และคะแนนผิวกระดูกอ่อนที่ด้านบนของคอนไดล์ของกระดูกต้นขาด้านในของสุนัขกลุ่มทดลอง มีการพัฒนาที่ดีขึ้นอย่างมีนัยสำคัญทางสถิติหลังจากได้รับยาเป็นเวลา 4 สัปดาห์ คะแนนภาวะข้อเสื่อมจากภาพถ่ายทางรังสีวิทยาของสุนัขกลุ่มทดลองมีการพัฒนาที่ดีขึ้นหลังได้รับยาเป็นเวลา 12 สัปดาห์ แต่อย่างไรก็ตามคะแนนการเดินกะเผลกและคะแนนความเจ็บปวดโดยใช้แบบสอบถามให้ผลที่ดีขึ้นตั้งแต่สัปดาห์ที่ 2 หลังได้รับยา จากการศึกษาพบว่าพีซีเอสโอห้าสองสี่มีประสิทธิภาพในการปกป้องผิวกระดูกอ่อนในสุนัขที่เป็นโรคข้อเสื่อมที่เกิดจากโรคสะบ้าเคลื่อนได้ สุนัขป่วยควรได้รับการผ่าตัดแก้ไขเพื่อลดโอกาสในการพัฒนาความรุนแรงของโรคข้อเสื่อม อย่างไรก็ตามสุนัขที่ไม่สามารถเข้ารับการผ่าตัดแก้ไขได้ ควรได้รับการออกกำลังกายและจัดการสิ่งแวดล้อมอย่างเหมาะสม ร่วมกับการทานพีซีเอสโอห้าสองสี่ เพื่อส่งเสริมคุณภาพชีวิตให้ดีขึ้น

สาขาวิชา ศัลยศาสตร์ทางสัตวแพทย์

ลายมือชื่อนิสิต .....

ปีการศึกษา 2561

ลายมือชื่อ อ.ที่ปรึกษาหลัก .....

# # 6075310631 : MAJOR VETERINARY SURGERY

KEYWORD: CHONDROPROTECTIVE EFFECTS, DOGS, MEDIAL PATELLAR LUXATION,  
OSTEOARTHRITIS, PCSO-524

Ratthanan Sathienbumrunkit : CHONDROPROTECTIVE EFFICACY OF PCSO-524 ON CANINE OSTEOARTHRITIS SECONDARY TO MEDIAL PATELLAR LUXATION. Advisor: Asst. Prof. KUMPANART SOONTORNVIPART, D.V.M., Ph.D., D.T.B.V.S.

Fifty stifles from Pomeranians and Chihuahuas with over five years old were enrolled in this study, which are 8 normal stifles and 42 medial patellar luxation (MPL) stifles. All MPL stifles were assigned randomly into 2 groups, including control and treatment groups. The control group was received placebo daily for 16 weeks, while treatment group was fed with PCSO-524 for 16 weeks. Lameness score, ultrasonographic findings, radiographic OA score and owner questionnaire (cBPI) were assessed at pre-treatment (D0) and post-treatment at week 2, 4, 8, 12 and 16. The ultrasonographic evaluations consisted of synovial fluid, articular cartilage, bone surface and ultrasonographic score. In treatment group, the ultrasonographic, synovial fluid and articular cartilage score of proximo-medial femoral condyle were found a significant improvement after 4 week of treatment. The radiographic OA score was significant improvement after 12 weeks of treatment while lameness score and cBPI were found a better outcome within 2 weeks. This study revealed that PCSO-524 has an effectiveness of cartilage protection in dogs with OA secondary to MPL. The surgical procedures are remain suggested in order to decreasing progressive OA. However, MPL dogs are recommended for training quadriceps muscle and environmental managements with administration of PCSO-524 for better quality of life.

Field of Study: Veterinary Surgery

Student's Signature .....

Academic Year: 2018

Advisor's Signature .....

## ACKNOWLEDGEMENTS

I would like to deeply acknowledge the 72nd Anniversary of His Majesty King Bhumibala Aduladeja, Chulalongkorn University for the scholarship and the 90th Anniversary of Chulalongkorn University, Rachadapisek Sompote Fund for the research funding.

I would like to express the highest acknowledgement to my dearest thesis advisor, Asst. Prof. Dr. Kumpanart Soontornvipart for giving me a great opportunity to study and conduct the interesting research. He provides an intellectual guidance, stimulating advices, kindness and encouragement. He always attend and help me whenever I ran into a trouble spot about my research. I am also indebted to all my thesis committees, Asst. Prof. Dr. Nan Choisunirachon, Assoc. Prof. Dr. Sayamon Srisuwatanasagul and Asst. Prof. Dr. Monchanok Vijarnsorn, for their interest and in valuable suggestions to my thesis.

My greatest appreciation goes to my lovely friends; Ms. Pacharawan Wanaroonwong, Ms. Waritha Thosaksith, Mr. Sirawich Srisiri, Ms. Tamolwan Anyamaneecharoen, Mr. Supakit Vilaisuntornkiat and Mr. Noppakrit Ekakaraworapong for their sincere friendship and assistance. They also support me during the stressful and difficult times. I am also grateful to all clinicians and staff of the surgery clinic, the Small Animal Hospital, Faculty of Veterinary Science, Chulalongkorn University for their help in the research. I would like to wholeheartedly thank to Dr. Pawit Tangviroon who provide me with unfailing support. He gives me a good advice and continuous encouragement throughout the process of researching and writing this thesis. Finally, I must express my profound gratitude to my dearest family for their attention, understanding and support. Without the guidance and help of them, I would never have been able to finish my dissertation.

Ratthanan Sathienbumrunkit

## TABLE OF CONTENTS

	Page
ABSTRACT (THAI) .....	iii
ABSTRACT (ENGLISH) .....	iv
ACKNOWLEDGEMENTS .....	v
TABLE OF CONTENTS .....	vi
LIST OF TABLES .....	viii
LIST OF FIGURES .....	x
CHAPTER I.....	14
INTRODUCTION.....	14
Important and rationale .....	14
CHAPTER II.....	16
LITERATURE REVIEW .....	16
2.1 Osteoarthritis .....	16
2.2 Medial patellar luxation.....	18
2.3 Nutraceuticals associated with osteoarthritis .....	21
2.4 Ultrasonography in osteoarthritic patients.....	23
2.4.1 Ultrasonographic findings of normal stifle joints.....	25
CHAPTER III.....	28
MATERIALS AND METHODS .....	28
3.1 Animals.....	28
3.2 Study designs .....	32
3.2.1 Lameness score.....	32



3.2.2 Blood profiles .....	33
3.2.3 Ultrasonographic examination .....	34
3.2.4 Radiographic examination .....	42
3.2.5 Owner questionnaires .....	45
3.3 Data presentation and statistical analysis .....	47
CHAPTER IV .....	48
RESULTS .....	48
4.1 Lameness score .....	50
4.2 Blood profiles .....	52
4.3 Ultrasonographic examination .....	54
4.4 Radiographic examination .....	63
4.5 Owner questionnaire .....	64
CHAPTER V .....	67
DISCUSSION .....	67
REFERENCES .....	74
VITA .....	81

## LIST OF TABLES

	Page
Table 1 Classification of medial patellar luxation grades modified from Brinker et al., (1997) and Piermattei et al., (2006).....	29
Table 2 Classification of nine-integer body condition score scale system (Laflamme, 1997).....	30
Table 3 Lameness scoring system modified from Impellizeri et al., (2000).....	33
Table 4 Ultrasonographic standard views for evaluating the stifle joint modified from Kramer et al., (1999).....	35
Table 5 Ultrasonographic scoring system for OA stifle joint: Synovial fluid score.....	35
Table 6 Ultrasonographic scoring system for OA stifle joint: Articular cartilage score modified from Goranov et al., (2013).....	36
Table 7 Ultrasonographic scoring system for OA stifle joint: Bone surface score modified from Goranov et al., (2013).....	36
Table 8 The radiographic scores of radiographic changes modified from Wessely et al., (2017) and Frost-Christensen et al., (2008).....	44
Table 9 Mean $\pm$ SD of age and body weight and the number of gender of dogs in control, treatment and normal groups.....	49
Table 10 Number of dogs categorized from severity of MPL in control and treatment groups .....	49
Table 11 Percentage of the improvement of lameness score at least one degree between adjacent visits: D0-W2, W2-W4, W4-W8, W8-W12 and W12-W16 .....	51
Table 12 Comparison of CBC and the standard blood chemistry profiles between pre-treatment (D0) and post-treatment (W16) within group .....	53
Table 13 Mean $\pm$ SD of ultrasonographic, synovial fluid, articular cartilage and bone surface score of the control and treatment groups.....	58

Table 14 Mean  $\pm$  SD of the articular cartilage thickness of medial, middle and lateral of femoral condyles of the control and treatment groups..... 59

Table 15 Mean  $\pm$  SD of the degrees of pain and life quality, which evaluated by the questionnaire of Canine BPI within group ..... 66



## LIST OF FIGURES

	Page
Figure 1 Ultrasonographic images of the cranial aspect in normal stifle joint. (A) Longitudinal view of the suprapatellar region. The suprapatellar recess (SPR) is appeared at the proximal aspect of the femoral trochlea, cranial to the patella (P) and underneath the quadriceps tendon (arrowheads). (B) Transverse view of the suprapatellar region. The patella (P) and the medial and lateral ridges of femoral trochlea (FT) are appeared. (C-D) Longitudinal sonographic images of the infrapatellar region in the proximal (C) and distal aspects (D). The patellar ligament (arrowheads) connects to the patella (P) and the tibial creast (TC). The infrapatellar fat body (Fat) presented caudal to the patellar ligament. The cartilage is located on the surface of the femoral trochlea (FT). The tibial plateau (TP) is seen caudal to the infrapatellar fat body (From Penninck D and d'Anjou M-A 2015. Atlas of small animal ultrasonography. In: 2nd ed. John Wiley & Sons, New York, United States. 512-516.)	27
Figure 2 Consent form of this study .....	31
Figure 3 Image of normal anatomy of left stifle in dogs. The evaluating areas of articular cartilage and bone surface scores were divided into 4 areas, including proximal and distal aspect of medial and lateral femoral condyles .....	37
Figure 4 Drawings of stifle flexion in each position. (A) Stifle flexion from its axis at an angle of 45 degree. (B) Maximum stifle flexion. (C) Stifle flexion from its axis at an angle of 90 degree with ultrasound probe .....	38
Figure 5 Measurement methods and the ultrasonographic performing of the stifle joint at an angle of 45 degree for evaluating of suprapatellar region. (A) Goniometer were used to measure the stifle joint at an angle of 45 degree before performing the ultrasonography. (B) The ultrasound probe placed on the femoral condyle in sagittal view for determining the appearances of synovial fluid and both aspects of the proximal femoral condyles and the articular cartilage .....	38

Figure 6 Ultrasonographic image of suprapatellar region with sagittal view of the stifle joint shows: SF, synovial fluid; PMFC, surface of the proximal of medial femoral condyle; P, surface of the patella; SPR, suprapatellar recess.....	39
Figure 7 Ultrasonographic performing on the stifle joint at maximum flexion. The ultrasound probe placed on the patellar in transverse plane for determining a thickness of the articular cartilage of the proximal femoral trochlea.....	39
Figure 8 Ultrasonographic image of suprapatellar region with transverse view of the stifle joint shows medial, middle and lateral areas of femoral condyle.....	40
Figure 9 Measurement methods of the stifle joint at an angle of 90 degree for evaluating of infrapatellar region. (A) Goniometer were used to measure the stifle joint at an angle of 90 degree before performing the ultrasonography. (B) The ultrasound probe placed on the femoral condyle in sagittal view for determining the appearances of synovial fluid and both aspects of the distal femoral condyles and the articular cartilage .....	41
Figure 10 Ultrasonographic image of infrapatellar region with sagittal view of the stifle joint shows: SF, synovial fluid; CA, articular cartilage of the femoral condyle; DMFC, surface of distal of medial femoral condyle; TT, tibial tuberosity; FAT, infrapatellar fat body; PL, patellar ligament .....	41
Figure 11 Radiographic image with assessment points in the mediolateral view of the stifle joint: 1, patellar apex; 2, patellar base; 3, proximal trochlear ridge; 4, distal trochlear ridge; 5, femoral condyle; 6, tibial tuberosity; 7, cranial aspect tibial plateau; 8, caudal aspect tibial plateau; 9, central aspect tibial plateau; 10, popliteal surface femur; 11, sesamoid bones .....	43
Figure 12 Radiographic image with assessment points in the caudocranial view of the stifle: 12, lateral tibial and femoral condyle; 13, medial tibial and femoral condyle; 14, intercondylar notch; 15, patella .....	44
Figure 13 Questionnaires of Canine BPI aimed to evaluate the severity of pain modified from Cleeland, (2006).....	46

Figure 14 Mean $\pm$ SD of lameness score of control group in each monitoring week..	50
Figure 15 Mean $\pm$ SD of lameness score of treatment group in each monitoring week. .....	51
Figure 16 Longitudinal view of suprapatellar region of normal stifle joint. Suprapatellar recess (arrows) was seen over the proximal of medial femoral condyle (PMFC). Patella (P) was used as landmark.....	54
Figure 17 Ultrasonographic images of infrapatellar region with sagittal view of the normal stifle joint. (A) Patella (P) and tibial tuberosity (TT) were used as landmark of this view. Synovial fluid (SF) showed anechoic opacity underneath the patellar ligament (arrowheads). (B) This region appeared distal aspect of medial femoral condyle (DMFC). Anechoic band with smooth margin of the articular cartilage (arrows) was seen over its bone surface which appeared as hyperechoic smooth lining.....	55
Figure 18 Ultrasonographic image of suprapatellar region with sagittal view of the normal stifle joint. Proximal aspect of medial femoral condyle (PMFC) was shown. Bone surface (arrowheads) and the articular cartilage (arrows) covering them were seen .....	56
Figure 19 Ultrasonographic image of suprapatellar region with transverse view of the normal stifle joint. Thickness of the articular cartilage of medial and lateral femoral condyles were determined .....	56
Figure 20 Mean $\pm$ SD of the synovial fluid score of the control and the treatment groups in each monitoring week .....	60
Figure 21 Ultrasonographic images of suprapatellar region with sagittal view between pre-treatment (D0) and post-treatment at week 4 <sup>th</sup> . (A) The articular cartilage (arrows) showed heterogeneous opacity with irregular margin (AC = 3) and bone surface (arrowheads) was moderate irregular hyperechoic lining (BS = 2). (B) The articular cartilage (arrows) was hypoechoic appearance with irregular margin (AC = 1) and bone surface (arrowheads) presented mild irregular hyperechoic lining (BS = 1).....	61

Figure 22 Mean  $\pm$  SD of the articular cartilage score of proximal aspect of medial femoral condyle of the control and the treatment groups in each monitoring week 62

Figure 23 Mean  $\pm$  SD of the radiographic OA score of the control and the treatment groups in each monitoring week. .... 63

Figure 24 Comparison of mean  $\pm$  SD of the pain degrees in both control and treatment groups..... 64

Figure 25 Comparison of mean  $\pm$  SD of the life quality degrees in both control and treatment groups..... 65



## CHAPTER I

### INTRODUCTION

#### Important and rationale

Osteoarthritis (OA) has widely known as the most prevalent arthritic disease in dogs and cats. It is considered to be a common cause of chronic pain, leading to physical disability when the progression is occurred. The previous studies demonstrate that OA is characterized by destruction of articular cartilage, inflammation of synovial membrane, subchondral bone sclerosis and osteophyte formation (Johnston, 1997; Burnett et al., 2006).

The varieties of medical therapies and physical managements for OA patients have been increasingly established and developed including long term usage of non-steroidal anti-inflammatory drugs (NSAIDs) or nutraceuticals, weight management and physical rehabilitation. Curtis et al., (2000), Jamikorn and Yibchok-anun, (2014) and Kwananocha et al., (2016) have been reported that nutraceuticals especially in PCSO-524, a New Zealand green-lipped mussel extract, omega-3 polyunsaturated fatty acids (n-3 PUFAs) supplement can reduced inflammation and articular cartilage degradation without any adverse effects. The clinical outcome of the application of PCSO-524 has been evaluated in many different ways such as the use of force plate gait analysis, lameness score, pain score, orthopedic assessment score (OAS), radiographic findings and owner preferences (Mongkon and Soontornvipart, 2012; Kwananocha et al., 2016). Unfortunately, there is no clinical study address in the efficacy of PCSO-524 on the articular cartilage. The degradation of articular cartilage during arthritis is the key point



to indicate the early stage of OA signs using ultrasonography techniques, which is recommended for detection an early OA signs in both humans and dogs (Okano et al., 2016; Ramírez-Flores et al., 2017; Jain and Johar, 2018). Moreover, this technique is desirable as a quick and easy screening method for diagnosis of human knee osteoarthritis with its invasiveness and cost-effectiveness (Jain and Johar, 2018).

In Thailand, a large number of small breed dogs has been diagnosed with a medial patellar luxation (MPL) disease. Many studies have indicated that MPL induces OA in the canine stifle (Martinez, 1997; Alam et al., 2011). Surgical treatment is the best way to cure this disease due to its stability and increasing progression of OA (Martinez, 1997). However, some owners may refuse to let their pets undergo the surgical intervention due to being scared of the anesthetic risks and lack of notification of the symptom as the clinical signs of OA secondary to MPL are not obviously detected. A large number of clinicians also prefer an elective treatment to avoid the risks of anesthesia.

The purpose of this study is to evaluate the chondroprotective effect of PCSO-524, the n-3 PUFAs supplement, in dogs with osteoarthritis secondary to medial patellar luxation by using ultrasonography (US).

## CHAPTER II

### LITERATURE REVIEW

#### 2.1 Osteoarthritis

Osteoarthritis (OA) is a common arthritic disease in dogs and cats. It is characteristically a loss of balance between synthesis and degradation of articular cartilage constituents. It subsequently leads to destruction of articular cartilage, remodeling of the underlying bone, formation of osteophytes, and varying degrees of synovitis (Fujita et al., 2005). There is a high prevalence as 20 percent of adult dogs, which suffered from this symptom (Johnston, 1997). It has been identified as the most important cause of chronic pain leading to physical disability at the final stage. This disorder influenced by multiple factors such as genetics, aging, obesity, overuse, acute trauma and diet (Burnett et al., 2006; Bell et al., 2014). In addition, it often occurs secondary to underlying diseases involving the joint instability, joint incongruity and abnormal loading via the joint such as hip dysplasia, cranial cruciate ligament rupture and patellar luxation (Ramírez-Flores et al., 2017).

Osteoarthritis is a slowly progressive disease caused by different etiologies that finally converge on the same pathogenic pathway. The pathological changes of OA are usually initiated by a disruption of the articular cartilage matrix. Chondrocytes produce several OA-associated cytokines such as interleukin-1 $\beta$  (IL-1 $\beta$ ) and tumor necrosis factor- $\alpha$  (TNF- $\alpha$ ), which stimulates the production of degradation enzymes. Eventually, an imbalance between the synthesis and resorption activities of cartilages

were occurred. These alterations lead to losing of hyaline articular cartilage, synovial membrane inflammation, subchondral bone sclerosis and osteophyte formation (Burnett et al., 2006).

Osteoarthritic dogs present variable clinical signs, depending on breeds, degrees of the disease, and the particular joint affected. The clinical signs consist of inactivity, stiffness, lameness, gait alterations, and behavioral changes. Moreover, exercise intolerance, muscle atrophy, joint swelling, reduced range of motion, crepitus, and pain on joint manipulation are presented.

Diagnosis of OA is traditionally made by radiographic imaging due to its features on providing the information of bony changes such as osteophytosis and subchondral bone sclerosis. However, it is not an ideal assessment method for soft tissue construction and the OA changes related to bony construction occur rather late in the disease processes. Early detection of OA may anticipate in good opportunities to identify the underlying causes of the OA and reduce the progression of OA. There are several reports on early diagnosis methods, including arthroscopy, ultrasonography (US) and biomarkers in joint effusion (Fujita et al., 2005; Ramírez-Flores et al., 2017). Other advanced imaging methods are used increasingly such as magnetic resonance imaging (MRI) and computed tomography (CT). MRI can provide the information of soft tissue such as cartilage, ligaments, tendon, menisci, synovium and bone. CT presents less information about soft tissue abnormalities, it is useful for the stifle joint in assessing the meniscus, and for more complex anatomy joints such as elbow joint, carpus, and tarsus. Even so, both of them are limited in the available of the device and cost-effective.

There is no clinical study completely proved in curing of OA. For a better living of OA patients, a combination therapy such as medical management, weight

management and physical rehabilitation, could be done (Impellizeri et al., 2000). The treatment goals of OA are aim at reducing symptoms, as pain and inflammation, maintain joint mobility and limit the loss of function. Moreover, another purpose of OA management is to prevent the OA progression, which could be served by pharmacologic management. To slow a severe stage of OA, especially as prevention of cartilage damage, several drug classes could be prescribed in a longstanding duration. Although, NSAIDs is the most common medication for OA treatment, its side effects still exist, especially when using in long term. Therefore, nutraceuticals is now widely recommended for OA patients (Henrotin et al., 2011). It can inhibit the inflammatory pathways, which cause a reduction of cartilage degradation with reduced side effects (Curtis et al., 2000; Jamikorn and Yibchok-anun, 2014; Kwananocha et al., 2016).

## 2.2 Medial patellar luxation

Patellar luxation (PL) is one of the most common orthopedic diseases affecting the stifle in dogs (Ness et al., 1996). It is termed as “congenital” due to it early occurring in life and non-traumatic disease (Piermattei et al., 2006; Tobias and Johnston, 2012). Many studies reported that medial patellar luxation (MPL) has been found more often than lateral patellar luxation (LPL) when compare with different breeds and sizes. Small breed dogs, especially in Pomeranian dogs, have been reported with a high prevalence (Roush, 1993; Hayes et al., 1994; Soontornvipart et al., 2013). Wangdee et al., (2005) has found the prevalence of MPL as 87 percent of small breed dogs. This is in accordance with Soontornvipart et al., (2013) that the incidence of MPL is 64 percent from 238 Pomeranians presented at the Small Animal Hospital, Faculty of Veterinary Science, Chulalongkorn University during 2006–2008. However, in recent years, some

reported found an increase prevalence of MPL in large and giant breeds, especially in the Akita, Labrador, husky, and malamute (Piermattei et al., 2006).

Medial patellar luxation is characterized as a developmental orthopedic disease in dogs while the traumatic luxation is less common (Slatter, 2003; Piermattei et al., 2006). The etiologies of MPL have not been elucidated; however, it have been described as a cause of skeleton abnormalities, which include a shallow of trochlear sulcus and medial displacement of the tibial tuberosity (Trotter, 1980; Hulse, 1981; Piermattei et al., 2006; Tobias and Johnston, 2012). Putnam (1968) and Singleton (1969) have indicated that the deformities of femoral head and neck as coxa vara (decreased angle of inclination of femoral neck) and a diminished anteversion angle (relative retroversion) were a commencement of the anatomical abnormalities of the stifle. The degrees of severity of MPL can be classified clinically into four grades according to a description of Singleton (1969) :

Grade I: The patella normally articulates in the trochlear groove. In full extension of the stifle joint, it easily luxates by pressure manipulation and immediately returns to the trochlear groove when released.

Grade II: The luxation of the patella can occur either extension or flexion of the stifle joint. However, in most of the time, it spontaneously reduce to the trochlear groove.

Grade III: The patella rarely locates in the trochlear groove. Although it can be reduced by manipulation, the patella often reluxates to the medial side of the trochlear ridge when the manual pressure releases. This severity presents with shallow trochlear groove, medial rotation of the tibia, and medial deviation of the tibial crest.

Grade IV: The patella is permanently dislocated from the trochlear groove. It neither reduced spontaneously nor manually. The trochlear groove is absent. The tibia is twisted medially, and tibial crest presents more deviation than lesser luxation.

Clinical signs of medial patellar luxation vary depending on the severity of luxation. Lameness signs also vary in each affected dogs in which it may be present intermittently or continuously. Dogs with MPL grade I are typically asymptomatic and incidental finding on routine physical examination. In grade II luxation, dogs show intermittent lameness involved with a luxation of the patella. Dogs mostly present abnormal gait termed “skipping lameness”, suddenly skips, frequently flexes and extends the joint and then start to weight bearing without any lameness. In grade III luxation, semiflexion of affected stifle is usually seen while dogs are walking. A crouched gait is presented with hyperflexion and internal tibial rotation of the stifle joint. Dogs show a variety degree of lameness associated with the degree of cartilage erosion at the articular surface of the patella and the medial trochlear ridge of the femoral condyle. And in grade IV luxation, the most severe condition, a crablike posture is found. Dogs cannot walk without a carrying by their owners. It commonly presents marked conditions of femoral varus, proximal tibial valgus, and internal tibial rotation (Tobias and Johnston, 2012). MPL caused disability, pain, and lameness leading to a degenerative joint disease. Finally, secondary osteoarthritis is commonly occurred (Roy et al., 1992).

Diagnosis of MPL in any severity is primarily based on physical examination. Radiographic examination can be useful to identify the luxation and the degree of degenerative changes in the stifle joint. However, in case of low degree of luxation, radiographs may be result in normal appearances. In case of skeleton deformities is

presented, radiographic examination is necessary to quantify the deformities and evaluate the operation plan (Tobias and Johnston, 2012).

For the treatment of MPL, there is an individual treatment in each patients. The surgical techniques for correction of MPL can be mainly divided into two parts, osseous and soft tissue techniques. All techniques are aim to realignment of the quadriceps mechanism and stabilization of the stifle joint. In grade II luxation dogs with significant clinical signs, surgical procedure is considered. But in case of mild lameness signs and OA degrees, a conservative treatment may be performed. Dogs with grade III and IV patellar luxation, surgical corrections are recommended in order to mitigate progressive skeletal deformity and osteoarthritis (Hayes et al., 1994; Tobias and Johnston, 2012).

### **2.3 Nutraceuticals associated with osteoarthritis**

A term “Nutraceuticals” is derived from “nutrition” and “pharmaceuticals” in 1989 by Stephen DeFelice, MD, founder and chairman of the Foundation for Innovation in Medicine (FIM), Cranford, NJ. Nutraceuticals is a broad term to qualify any product derived from food source, which provides extra health benefits. Though, it looks similarly to a dietary supplement and drug, but it can distinguish by the oral administrated and the bioavailability (Henrotin et al., 2011). The aim of using nutraceuticals is to provide a treatment and prevention against any disorders, especially chronic diseases. Additionally, it can be used for delaying the aging process and improving health. In comparison to other therapeutic agents, nutraceuticals has received considerable interest because of theirs desirable therapeutic outcomes with few side effects (Kalra, 2003; Nasri et al., 2014).

In the last twenty years, the omega-3 polyunsaturated fatty acids (n-3 PUFAs) have had a major impact on medical treatment. It is mainly found in fish, fish oils and from other marine organisms (Sinclair et al., 2000). There are many kinds of n-3 PUFAs, such as eicosapentaenoic acid (EPA), docosahexaenoic acid (DHA) and eicosatetraenoic acid (ETA). Omega-3 polyunsaturated fatty acids have a highly potent anti-inflammatory property. It decreases mainly inflammatory mechanisms, producing proteoglycan degrading enzymes and inflammation-inducible cytokines such as interleukin-1 $\alpha$  (IL-1 $\alpha$ ), tumor necrosis factor- $\alpha$  (TNF- $\alpha$ ) and cyclooxygenase-2 (COX-2) (Curtis et al., 2000). One study reported a reduction in both inflammatory and degradation effects in vitro chondrocytes model (Curtis et al., 2002). For this reason, n-3 PUFAs can be used to treat OA patients.

Many clinical researchers revealed that a non-polar lipid extracted from a New Zealand green-lipped mussel, *Perna canaliculus*, PCSO-524, are a rich source of n-3 PUFAs, including EPA and DHA. The unique PUFAs of PCSO-524 composes of 5,9,12,15-octodecatetraenoic acid (OTA), 5,9,12,16-nonadecatertraenoic acid, 7,11,14,17-eicosatetraenoic acid (ETA), and 5,9,12,15,18-heneicosapentaenoic acid (HPA) (Treschow et al., 2007; Zawadzki et al., 2013). These molecules are similar to arachidonic acid (AA; 5,8,11,14-eicosatetraenoic acid), which is a precursor of the inflammatory agents, prostaglandins and leukotrienes. Therefore, these n-3 PUFAs account for the anti-inflammatory property by competitively inhibiting the active site of enzymes that use AA as a substrate. The lipid extracted of *P. canaliculus* moderately inhibits cyclooxygenase-1 (COX-1) and cyclooxygenase-2 (COX-2) (Zawadzki et al., 2013). PCSO-524 has been proven in efficacy on inhibition of inflammatory and degradation pathways. It has demonstrated as properties of gastroprotective, antihistaminic, antioxidant, anticytokine, anti-inflammatory and antiarthritic affects



(Gibson et al., 1980; Whitehouse et al., 1997). Stammers et al.,(1992), Lau et al., (2004) and Vandeweerdt et al., (2012) have demonstrated the reducing of inflammation, pain and increasing joint mobility in OA patients. Several studies recommend this supplement for the medical treatment of various osteoarthritic diseases, either in animal studies or human trails, due to none of any adverse effects (McPhee et al., 2007; Mongkon and Soontornvipart, 2012; Zawadzki et al., 2013; Jamikorn and Yibchok-anun, 2014). Moreover, it has illustrated that these lipid extracted have more efficacy than the lipid extracted from fish oil or other drugs (Whitehouse et al., 1997; Zawadzki et al., 2013; Soontornvipart et al., 2015).

#### **2.4 Ultrasonography in osteoarthritic patients**

Diagnostic methods of osteoarthritis are commonly determined by orthopedic and radiographic examinations. Radiography has been used as a standard tool for evaluation of OA joints due to its abilities of bone and soft tissue appearances (Innes et al., 2004). However, there is study indicated the lack of agreement between clinical signs and radiographic images of knee OA (Jain and Johar, 2018). It has limited in diagnostic accuracy for soft tissue visualization in OA joints. In early OA patients, the alteration of joint effusion is mostly occurred, which is difficult to detect in radiography. Moreover, there are many changes in soft tissue structures occurred prior to a detection of bony changes in radiographic findings (Chappard et al., 2006; Ramírez-Flores et al., 2017). Over the last few decade, a method for diagnosing and monitoring osteoarthritic disease in dogs has developed, including arthroscopy, magnetic resonance imaging (MRI), computed tomography (CT), scintigraphy, biochemical markers, synovial fluid analysis and ultrasonography (US). Arthroscopy and MRI have

been known as quality imaging assessment methods for all tissues in the joints. Even these techniques have a direct visualization of articular structures, their cost-effective and invasiveness are still concerned. In recent years, many authors have discovered that US is a desirable imaging method for diagnosing OA diseases (Reed et al., 1995; Kramer et al., 1999). Sonography has the abilities of soft tissue visualization without those disadvantages. It reveals the appearances of hyaline cartilage, joint effusion and also bony surface of the joints.

Ultrasonography, both in humans and animals, has been increasingly utilized in aid the evaluation, diagnosing and monitoring of osteoarthritic diseases (Möller et al., 2008). A number of rheumatologists have recommended to use US for assessing several type of articular disorders, including OA (Okano et al., 2016; Jain and Johar, 2018). It allows detection of the pathology of OA joints such as articular cartilage, bony cortex and synovial tissue. The advantages of US have been well described, which involve its non-ionizing radiation, non-invasiveness and visualization of soft tissue structures. Tarhan and Unlu, (2003) have demonstrated the validity of US when comparison with MRI. Karim et al., (2004) indicated US as a valid and reproducible technique for detecting knee synovitis when compare with clinical signs and arthroscopy. In accordance with Keen et al., (2009) who indicated that US has more sensitivity for detection of synovitis in OA than clinical examination, with reasonable sensitivity compared with MRI or histology. Furthermore, in human, it is used as a screening diagnosis of stifle disease, especially for assessing early changes of cartilage in OA patients (Okano et al., 2016; Jain and Johar, 2018).

For osteoarthritic dogs, Ultrasonography has been proposed for detection a subtle change in soft tissue structure in early OA joint (Möller et al., 2008; Arnault et al., 2009; Nishitani et al., 2014). This early detection will help practitioners in curing the

disease before it becomes complicated stage. Moreover, US was useful in evaluating of the presence of fibrous tissue in chronic OA (Gnudi and Bertoni, 2001).

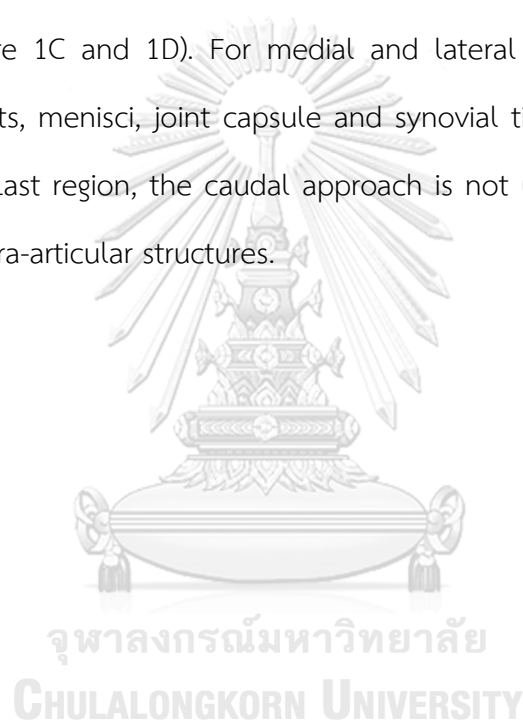
Many experimental studies of stifle OA in dogs recommend using of both radiology and ultrasonography for OA diagnoses (Kramer et al., 1999; Goranov et al., 2013). A clinical study of Ramírez-Flores et al., (2017) found a good diagnostic agreement between synovial fluid effusion and osteophytosis in stifle joint OA. Nowadays, US has been recommended as a screening diagnostic technique for detection of OA (Reed et al., 1995; Kramer et al., 1999; Ramírez-Flores et al., 2017).

#### **2.4.1 Ultrasonographic findings of normal stifle joints**

Recently, there are many evidences, indicating the visualization of US in stifle dogs (Reed et al., 1995; Kramer et al., 1999; Penninck and d'Anjou, 2015). For assessing all structures in the stifle joint, a high frequency linear transducer ( $> 10$  MHz) is usually preferred (Reed et al., 1995; Penninck and d'Anjou, 2015). The standard of ultrasonographic examination procedure of canine stifle has been established by Kramer et al., (1999). They have described the ultrasonographic appearances of 58 normal stifle joints by using 7.5 MHz linear scanner.

For ultrasonography, stifle joint can be sectioned into five regions: suprapatellar, infrapatellar, medial, lateral and caudal. The suprapatellar region can be visualized at 45 degrees of the stifle flexion which the patellar is used as landmark. It appears quadriceps tendon, femoral trochlear and proximal joint recess. The suprapatellar recess is anechoic with thickness of 1-2 mm, located on the cranial border of the femoral cortex (Figure 1A). The articular cartilage is anechoic band with 1-2 mm-thick and smooth hyperechoic margin. It is located above the curvilinear

hyperechoic lining, which is a subchondral surface of the femoral trochlear. For the infrapatellar region, stifle joint is flexed at 90 degrees to examine the patella, patellar ligament, femoral condyles, infrapatellar fat body and cruciate ligament (Figure 1B and 1C). The patella appears as hyperechoic-convex line with strong acoustic shadowing, embedded in the patellar ligament. It presents a hyperechoic band with fibrillar echotexture (Figure 1C and 1D). The infrapatellar fat body is presented beneath the patellar ligament. It appears a triangular structure with hypoechoic and granular in echotexture (Figure 1C and 1D). For medial and lateral aspects of the stifle, the collateral ligaments, menisci, joint capsule and synovial tissue can be visualized by ultrasonography. Last region, the caudal approach is not used routinely due to low visualization of intra-articular structures.



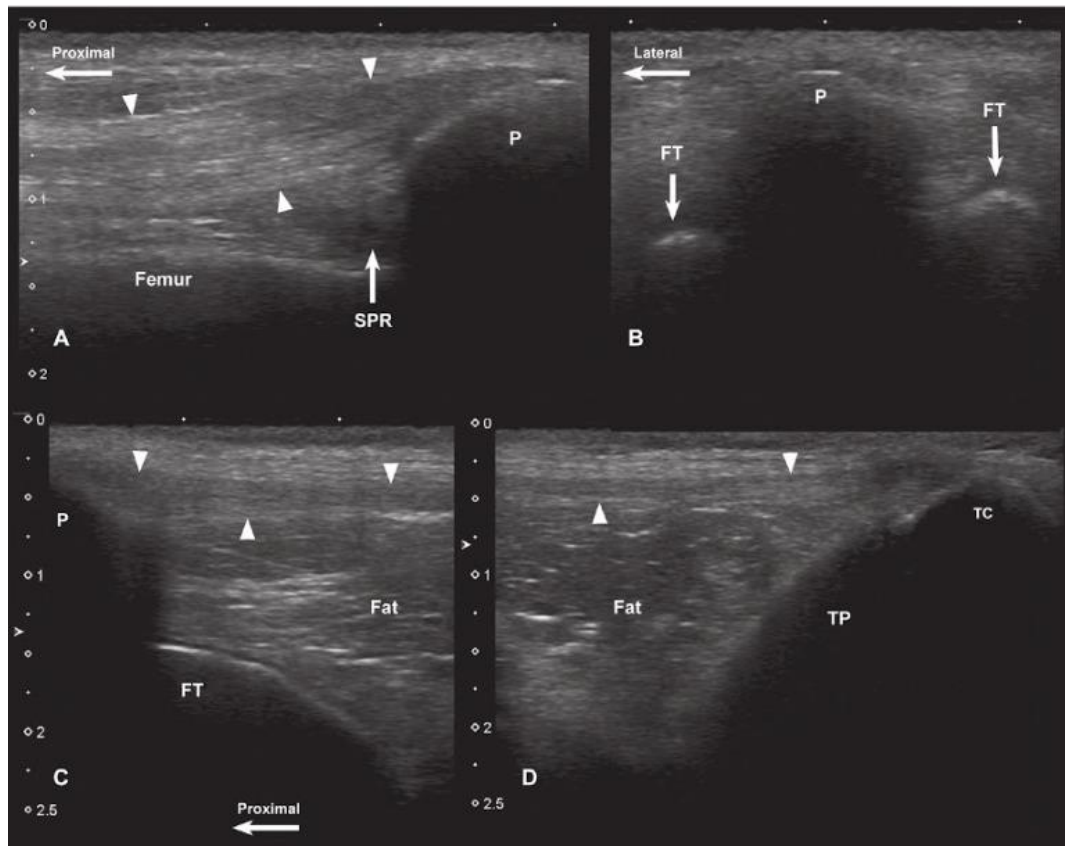


Figure 1 Ultrasonographic images of the cranial aspect in normal stifle joint. (A) Longitudinal view of the suprapatellar region. The suprapatellar recess (SPR) is appeared at the proximal aspect of the femoral trochlea, cranial to the patella (P) and underneath the quadriceps tendon (arrowheads). (B) Transverse view of the suprapatellar region. The patella (P) and the medial and lateral ridges of femoral trochlea (FT) are appeared. (C-D) Longitudinal sonographic images of the infrapatellar region in the proximal (C) and distal aspects (D). The patellar ligament (arrowheads) connects to the patella (P) and the tibial creast (TC). The infrapatellar fat body (Fat) presented caudal to the patellar ligament. The cartilage is located on the surface of the femoral trochlea (FT). The tibial plateau (TP) is seen caudal to the infrapatellar fat body (From Penninck D and d'Anjou M-A 2015. Atlas of small animal ultrasonography. In: 2nd ed. John Wiley & Sons, New York, United States. 512-516.)

## CHAPTER III

### MATERIALS AND METHODS

#### 3.1 Animals

Pomeranian and Chihuahua breed dogs, presented at the Small Animal Hospital, Faculty of Veterinary Science, Chulalongkorn University, were examined for MPL with any severity. The severities of MPL were classified base on Brinker et al., (1997) and Piermattei et al., (2006), which are shown in table 1. Dogs with the age of over 5 years old and weight between 2-6 kilograms were included in the study. MPL dogs (n= 21) were categorized into 2 groups, control and treatment groups. Moreover, the normal group (n= 4), which had the same criteria as both groups except being MPL, were selected in order to represent the normal appearances of the stifle joints.

All dogs were examined for both general physical and neurological examination thoroughly. The body condition score (BCS) was determined based on nine-integer BSC scale system (Laflamme, 1997) shown in table 2. All dogs were fed with commercial standard food only, which did not have any special supplement. In control and treatment groups, the selected patients must not be received NSAIDs, nutraceuticals or pain control drugs at least two weeks before starting the treatment. Exclusion criteria were patients with a history of neurological deficit, systemic diseases or any orthopedic diseases except medial patellar luxation disease. Animal owners needed to sign a consent form to attend the study (Figure 2).

This study was approved by the animal care and use committee of the Faculty of Veterinary Science, Chulalongkorn University Animal Care and Use Committee (CU-ACUC), Bangkok, Thailand. The approval number was 1831085.

Table 1 Classification of medial patellar luxation grades modified from Brinker et al., (1997) and Piermattei et al., (2006)

Grade	Description
I	At full extension of the stifle joint, the patella can be manually luxated and spontaneously returns to the normal position when released.
II	The patella luxated more easily and frequently than grade I luxation. It luxates during stifle joint flexion, extension or rotation of the limb and spontaneously returns to the normal position.
III	The patella is permanently luxated, but can manually be reduced into the trochlear groove when the stifle is extended. However, re-luxation spontaneously occurs after the pressure is released.
IV	The patella is permanently luxated and cannot be reduced into the trochlear groove.

Table 2 Classification of nine-integer body condition score scale system (Laflamme, 1997)

Score	Description
1	Ribs, lumbar vertebrae, pelvic bones and all bony prominences evident from a distance. No observable body fat. Obvious loss of muscle mass.
2	Easily visible of ribs, lumbar vertebrae and pelvic bones. Some evidence of other bony prominences. Minimal loss of muscle mass.
3	Easily palpation of ribs. Evidence of top of lumbar vertebrae and prominence of pelvic bone. Obvious waist and abdominal tuck.
4	Easily palpation of ribs with minimal fat covering. Easily noted of waist from the top view. Abdominal tuck evident.
5	Ribs palpable without excess fat covering. Waist observed behind ribs from the top view. Abdominal tuck up when viewed from side.
6	Ribs palpable with slight excess fat covering. Waist discernible from the top view without prominence. Appearance of abdominal tuck.
7	Difficult palpation of ribs under excess fat covering. Noticeable fat deposits over lumbar area and base of tail. Absent or barely visible of waist. Abdominal distention may be presented.
8	No palpation of ribs without pressure. Heavy fat deposits over lumbar area and base of tail. Absent of waist and abdominal tuck. Obvious abdominal distention may be presented.
9	Massive fat deposits over thorax, spine and base of tail. Absent of waist and abdominal tuck. Fat deposits on neck and limbs. Obvious abdominal distention.





### ใบยินยอมเข้าร่วมโครงการวิจัย (Consent Form)

วันที่.....เดือน.....พ.ศ.....

ข้าพเจ้า.....

อยู่บ้านเลขที่.....หมู่.....ถนน.....

แขวง/ตำบล.....เขต/อำเภอ.....จังหวัด.....

รหัสไปรษณีย์.....โทรศัพท์.....

สุนัขชื่อ.....พันธุ์.....เพศ.....อายุ.....

ข้าพเจ้าได้ลงลายมือชื่อในใบยินยอมเข้าร่วมโครงการวิจัยนี้เพื่อเป็นหลักฐานแสดงว่า

- ข้อ 1. ข้าพเจ้า ได้รับทราบโครงการวิจัยของ สัตวแพทย์หญิง ฐิตินันท์ เสถียรบำรุงกิจ เรื่อง ประสิทธิภาพในการป้องกันกระดูกอ่อนของพินอสีโอทาสองสีในสุนัขที่เป็นโรคข้อเสื่อมที่เกิดจากโรคสะบ้าเคลื่อนด้านใน
- ข้อ 2. ข้าพเจ้า ได้รับการอธิบายจากผู้วิจัยเกี่ยวกับวัตถุประสงค์ของการวิจัย วิธีการวิจัย ประสิทธิภาพ ความปลอดภัย อาการหรืออันตรายที่อาจเกิดขึ้น รวมทั้งแนวทางป้องกัน และแก้ไข ค่าใช้จ่ายที่ข้าพเจ้าจะต้องรับผิดชอบจ่ายเอง อีกทั้งยังได้รับคำอธิบายและตอบข้อสงสัยจากผู้วิจัยเป็นที่เรียบร้อยแล้ว
- ข้อ 3. ข้าพเจ้า ได้รับการรับรองจากผู้วิจัยว่าจะเก็บข้อมูลส่วนตัวเกี่ยวกับสัตว์เลี้ยงของข้าพเจ้าเป็นความลับ จะเปิดเผยเฉพาะผลสรุปการวิจัยเท่านั้น นอกจากนี้การเปิดเผยข้อมูลเกี่ยวกับสัตว์เลี้ยงของข้าพเจ้าต่อหน่วยงานต่าง ๆ ที่เกี่ยวข้องต้องได้รับอนุญาตจากข้าพเจ้าและจะกระทำได้เฉพาะกรณีจำเป็นด้วยเหตุผลทางวิชาการเท่านั้น
- ข้อ 4. ข้าพเจ้า ได้รับทราบแล้วว่าข้าพเจ้ามีสิทธิ์จะบอกเลิกการร่วมโครงการวิจัยนี้ และการบอกเลิกการร่วมโครงการวิจัยจะไม่มีผลกระทบต่อการดูแลรักษาโรคของสัตว์เลี้ยงของข้าพเจ้า
- ข้อ 5. ข้าพเจ้า ได้อ่านและเข้าใจข้อความข้างต้นแล้ว จึงได้ลงนามในใบยินยอมนี้ด้วยความสมัครใจ โดยมีได้มีการบังคับขู่เข็ญ หลอกลวงแต่ประการใด และจะให้ความร่วมมือในการวิจัยทุกประการ

ลงนาม.....ผู้ยินยอม

(.....)

ลงนาม.....พยาน

(.....)

ลงนาม.....ผู้ทำวิจัย

(.....)

Figure 2 Consent form of this study

### 3.2 Study designs

The dogs (n=25 dogs; 50 stifles) were divided into 3 groups which were control, treatment and normal groups. In normal group, there were 4 dogs (n=8 stifles) with the same criteria as treatment and control groups except being MPL. They were performed the ultrasonographic and radiographic examinations to identify the normality of stifles. In treatment and control groups, all dogs (n=22 dogs; 42 stifles) with any severity of MPL were divided into two groups by double blind random sampling technique.

In treatment group, 11 dogs (n=22 stifles) were treated with PCSO-524 at the recommended dose as 50 mg per animal once daily for 16 weeks. Dogs in control group (n=20 stifles) were fed with placebo once daily for 16 weeks. The animals were evaluated for both stifle for clinical outcomes before treatment (D0) and post-treatment program at week two (W2), four (W4), eight (W8), twelve (W12) and sixteen (W16). The clinical evaluations included lameness score, blood profiles, ultrasonographic findings, radiographic findings and owner questionnaires. In each visit, these patients were assessed all the clinical evaluations except the blood profiles, which examined only D0 and W16 for evaluation of any adverse effects and health status. The treatment was terminated at the end of the forth month.

#### 3.2.1 Lameness score

All dogs in control and treatment groups were determined and recorded abnormal gaiting in each appointment. Lameness was scored during walking and trotting. The evaluation of lameness score was modified based on Impellizeri et al., (2000). Lameness scoring system is shown in table 3.

Table 3 Lameness scoring system modified from Impellizeri et al., (2000)

Lameness score	Description
0	Normal gait when walking and trotting
1	Slight algetic gait when walking and normal gait when trotting
2	Obvious algetic gait when walking and normal gait when trotting
3	Difficulty walking and algetic gait when trotting
4	Non weight bearing when walking and algetic gait when trotting
5	Non weight bearing when walking and trotting

### 3.2.2 Blood profiles

A total of approximately 2 ml of blood sample was collected from either cephalic or saphenous veins. The blood sample was divided into two equal portion (1 ml each). The first portion was filled into the tube with ethylenediamine tetraacetic acid (EDTA) for determination of hematology (complete blood count, CBC). Another portion was filled into heparin tube to determine the standard blood chemistry parameters. The parameters of CBC included red blood cell (RBC), hemoglobin, hematocrit, platelet, white blood cell (WBC), neutrophils, eosinophils, lymphocytes and monocytes. The standard blood chemistry parameters were blood urea nitrogen (BUN), creatinine (Cr), alanine transaminase (ALT) or serum glutamate-pyruvate transaminase (SGPT) and alkaline phosphatase (ALP).

CBC and the standard blood chemistry of the dogs were evaluated before (D0) and at the end of the study (W16) for health status and adverse effects of the treatments.

### 3.2.3 Ultrasonographic examination

To assess stifle joint alterations, ultrasonography was performed with real-time 10-MHz linear transducer (Mindray® Z5 Ultrasound Machine) (Kramer et al., 1999; Penninck and d'Anjou, 2015; Ramírez-Flores et al., 2017). It was used with 50 and 1.8 in gain and depth, respectively. Stifle joints were examined following to acoustic approach modified from Kramer et al., (1999) and Penninck and d'Anjou, (2015). Some standard views were listed appropriately according to the objective of this study presented in table 4. The hair was clipped from the distal third of the femur to below the tibial tuberosity 2-3 centimeters. The patients were placed in dorsal recumbent position. The stifle joint was examined from proximally to distally.

The ultrasound evaluation were analyzed base on the modification of ultrasonographic scoring system of Goranov et al., (2013). The evaluation scores consisted of synovial fluid, articular cartilage and bone surface of femoral condyles score (Table 5-7). In each stifle, the femoral condyles were evaluated into 4 parts involving the proximal and distal of both medial and lateral femoral condyles (Figure 3). Individual scores were ranged between 0 and 28 points which were calculated for ultrasonographic score. Moreover, the articular cartilage thickness of the femoral condyles were recorded in millimeters.

Table 4 Ultrasonographic standard views for evaluating the stifle joint modified from Kramer et al., (1999)

Standard regions / views	Implementation
<b>Suprapatellar region</b>	
(A) Parallel view on the femoral trochlea	Knee flexed at an angle of 45 degrees Parallel sagittal image
(B) Suprapatellar views on the femoral trochlea	Knee flexed as far as possible Transverse image
<b>Infrapatellar region</b>	
(C) Infrapatellar view	Knee flexed at an angle of 90 degrees Sagittal image

Table 5 Ultrasonographic scoring system for OA stifle joint: Synovial fluid score

Synovial fluid score	Description
0	Normal appearance of joint fluid; anechoic content
1	Mild increasing opacity of joint fluid
2	Obvious increasing opacity of joint fluid with slightly heterogenous echogenicity
3	Slightly hyperechoic appearance of joint fluid with heterogenous echogenicity
4	Obvious hyperechoic appearance of joint fluid; echogenicity similar to bone

Table 6 Ultrasonographic scoring system for OA stifle joint: Articular cartilage score modified from Goranov et al., (2013)

Articular cartilage score	Description
0	Normal appearance; anechoic band with smooth margin
1	Hypoechoic appearance of the hyaline cartilage with irregular margin
2	Hyperechoic appearance of the hyaline cartilage with irregular margin
3	Heterogeneous appearance of the hyaline cartilage with irregular margin

Table 7 Ultrasonographic scoring system for OA stifle joint: Bone surface score modified from Goranov et al., (2013)

Bone surface score	Description
0	Normal appearance; absent Irregular and/or rounded
1	Mild interruptions of the
2	Moderate hyperechoic boundary of
3	Severe bones

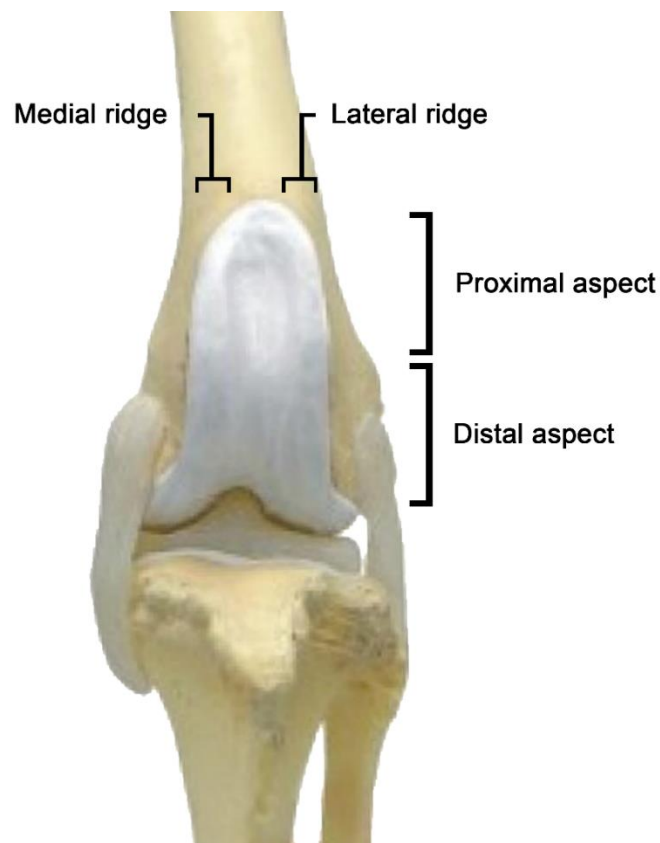


Figure 3 Image of normal anatomy of left stifle in dogs. The evaluating areas of articular cartilage and bone surface scores were divided into 4 areas, including proximal and distal aspect of medial and lateral femoral condyles

To evaluate a suprapatellar region with parallel view on the femoral trochlea, the stifle was flexed from its axis at an angle of 45 degrees by measuring with goniometer. The ultrasound probe was placed on the femoral condyle in a sagittal plane (Figure 4A, 5A and 5B). The synovial fluid, suprapatellar recess, the proximal femoral condyles and the articular cartilage covering them become apparent (Figure 6). Then, synovial fluid, the articular cartilage and bone surface of medial and lateral ridge of femoral condyle were determined and recorded.

When performing a transverse examination under maximal flexion of the stifle, the ultrasound probe was placed up on the patella in a transverse plane (Figure 4B

and 7). Articular cartilage thickness of medial, middle and lateral areas of the femoral trochlea was determined and recorded (Figure 8) (Kramer et al., 1999).

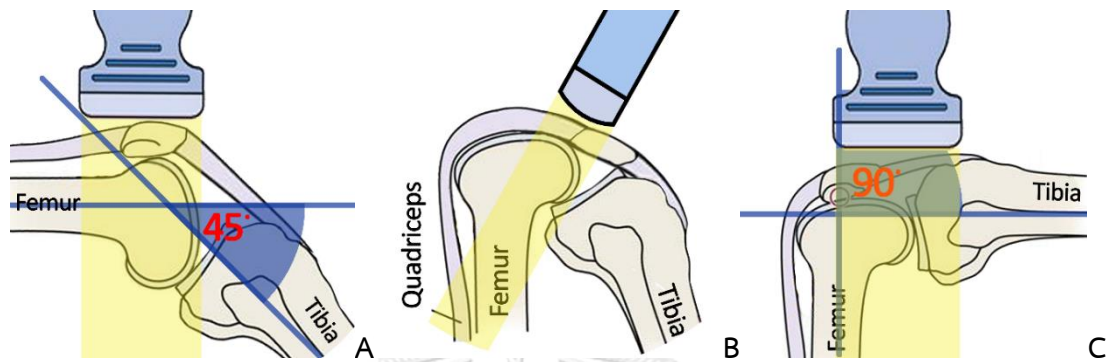


Figure 4 Drawings of stifle flexion in each position. (A) Stifle flexion from its axis at an angle of 45 degree. (B) Maximum stifle flexion. (C) Stifle flexion from its axis at an angle of 90 degree with ultrasound probe

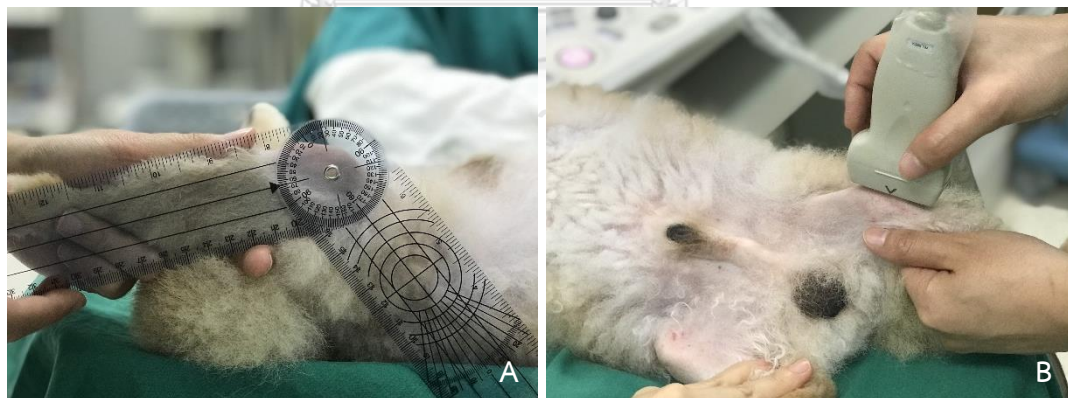


Figure 5 Measurement methods and the ultrasonographic performing of the stifle joint at an angle of 45 degree for evaluating of suprapatellar region. (A) Goniometer were used to measure the stifle joint at an angle of 45 degree before performing the ultrasonography. (B) The ultrasound probe placed on the femoral condyle in sagittal view for determining the appearances of synovial fluid and both aspects of the proximal femoral condyles and the articular cartilage



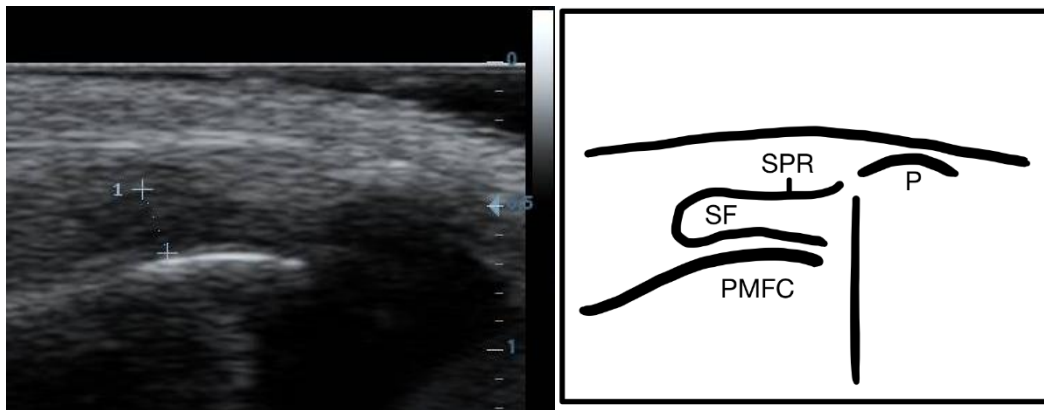

Figure 6 Ultrasonographic image of suprapatellar region with sagittal view of the stifle joint shows: SF, synovial fluid; PMFC, surface of the proximal of medial femoral condyle; P, surface of the patella; SPR, suprapatellar recess

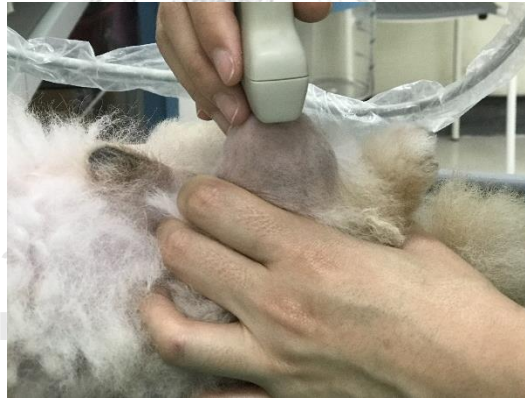

Figure 7 Ultrasonographic performing on the stifle joint at maximum flexion. The ultrasound probe placed on the patellar in transverse plane for determining a thickness of the articular cartilage of the proximal femoral trochlea

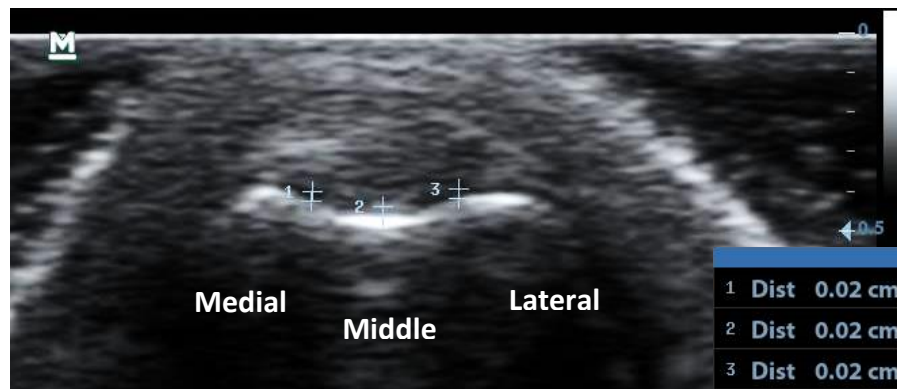


Figure 8 Ultrasonographic image of suprapatellar region with transverse view of the stifle joint shows medial, middle and lateral areas of femoral condyle

For infrapatellar view, knee was flexed from its axis at an angle of 90 degree and the ultrasound probe was placed on the femoral condyle in a sagittal plane (Figure 4C, 9A and 9B). This plane showed the patella, patellar ligament, joint fluid, infrapatellar fat body, articular cartilage and bone surface of femoral condyles (Figure 10). This view was used to evaluate a score of the articular cartilage and bone surface of distal aspect of both ridges of femoral condyle. Synovial fluid was considered in cooperate with the suprapatellar view.

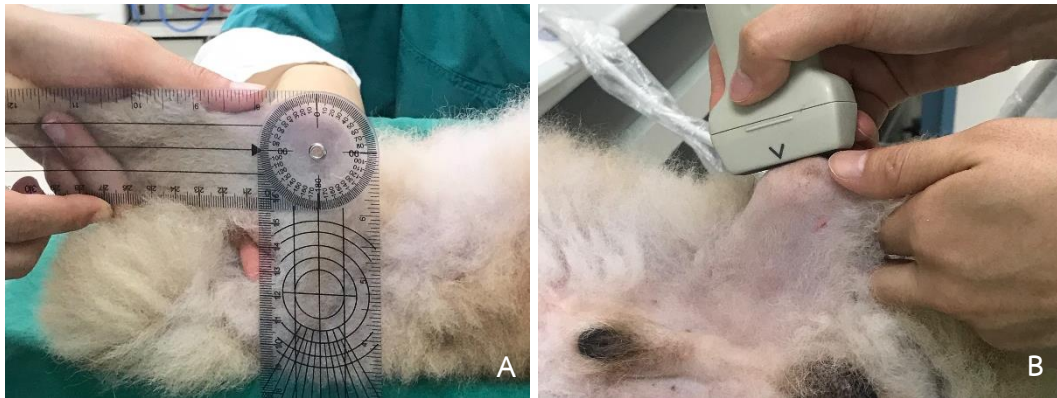


Figure 9 Measurement methods of the stifle joint at an angle of 90 degree for evaluating of infrapatellar region. (A) Goniometer were used to measure the stifle joint at an angle of 90 degree before performing the ultrasonography. (B) The ultrasound probe placed on the femoral condyle in sagittal view for determining the appearances of synovial fluid and both aspects of the distal femoral condyles and the articular cartilage

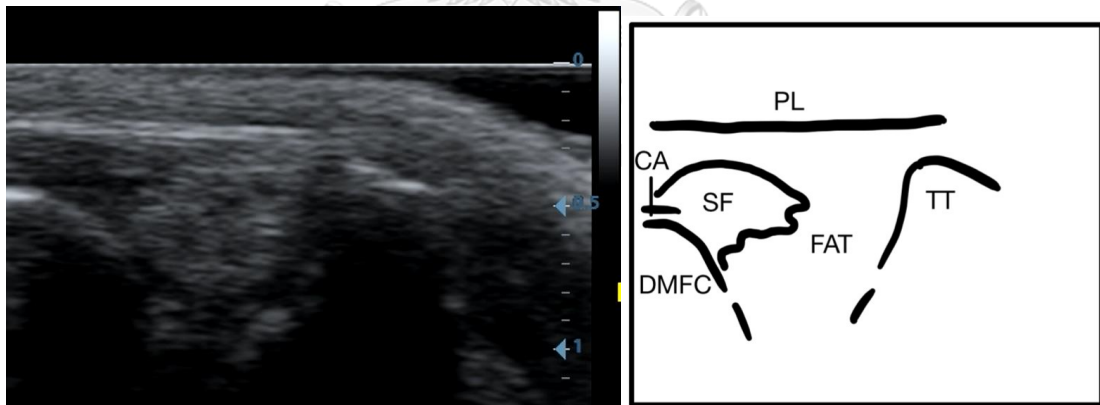


Figure 10 Ultrasonographic image of infrapatellar region with sagittal view of the stifle joint shows: SF, synovial fluid; CA, articular cartilage of the femoral condyle; DMFC, surface of distal of medial femoral condyle; TT, tibial tuberosity; FAT, infrapatellar fat body; PL, patellar ligament

### 3.2.4 Radiographic examination

In a period of the study, a conventional radiographs of interested stifle joints were performed and recorded (FCR CAPSULA V VIEW workstation®) in each visit. Patients were obtained the radiographic examination in two views: mediolateral and caudocranial views for classification of osteoarthritis score. This osteoarthritis score was evaluated based on the modification of Wessely et al., (2017) and Frost-Christensen et al., (2008). There were 15 assessment points in the stifle radiographs, including 11 points in the mediolateral view (Figure 11) and 4 points in the caudocranial view (Figure 12). Each point were graded on a numeric scale from 0 to 3 (Table 8). The overall OA scores were calculated in range between 0 and 45.

To retrieve the standard mediolateral view, dogs were positioned in lateral recumbency with flexion the stifle joint at an angle of 90 degree. The radiographs were accepted when the femoral condyles superimpose. To obtain the standard caudocranial view, the sternal recumbency performed with the affected limb extended along the long axis of the femur and also parallel to the long axis of the tibia.

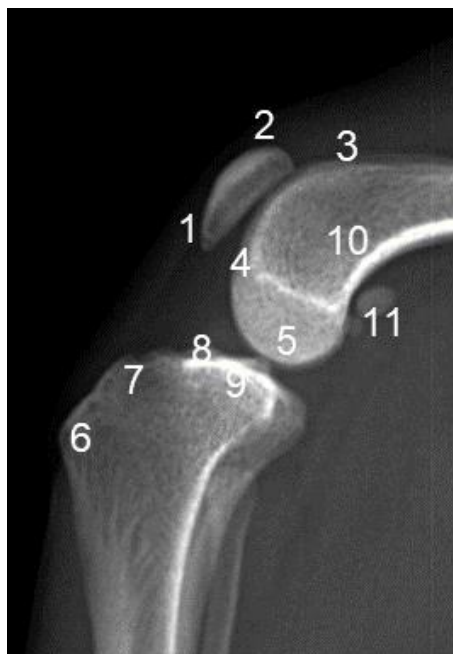

Figure 11 Radiographic image with assessment points in the mediolateral view of the stifle joint: 1, patellar apex; 2, patellar base; 3, proximal trochlear ridge; 4, distal trochlear ridge; 5, femoral condyle; 6, tibial tuberosity; 7, cranial aspect tibial plateau; 8, caudal aspect tibial plateau; 9, central aspect tibial plateau; 10, popliteal surface femur; 11, sesamoid bones

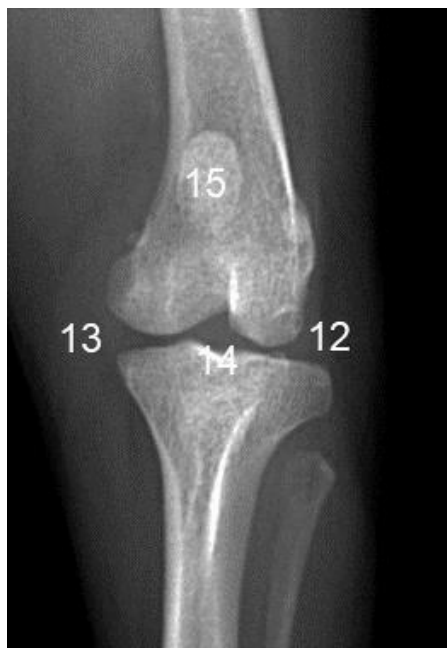

Figure 12 Radiographic image with assessment points in the caudocranial view of the stifle: 12, lateral tibial and femoral condyle; 13, medial tibial and femoral condyle; 14, intercondylar notch; 15, patella

Table 8 The radiographic scores of radiographic changes modified from Wessely et al., (2017) and Frost-Christensen et al., (2008)

Grade	Severity	Radiographic changes
0	No	Radiographically normal or no evidence of osteophyte formation or subchondral sclerosis
1	Mild	Mild osteophyte formation and/or mild subchondral sclerosis (mild arthrosis)
2	Moderate	Moderate osteophyte formation and/or moderate subchondral sclerosis (moderate arthrosis)
3	Severe	Marked osteophyte formation and/or severe subchondral sclerosis (severe arthrosis)

### 3.2.5 Owner questionnaires

The owner will be requested to perform the questionnaires of Canine Brief Pain Inventory (Canine BPI) by University of Pennsylvania, which created by Dr. Dorothy Cimino Brown aimed to detect of the severity of pain (Figure 13) (Cleeland, 1990; Cleeland, 2006). The evaluations of Canine BPI's questionnaires were divided into two parts, including the degree of pain and the satisfaction of life quality in last 7 days. The determination of degrees of pain composed of ten questions. Each question had a total of 10 points therefore the total score of pain degrees was ranged between 0 to 100 points. The degree of life quality was recorded as 1=poor, 2=fair, 3=good, 4=very good and 5=excellent.



แบบสอบถามเกี่ยวกับระดับความเจ็บปวดในโครงการ “ประสิทธิภาพในการปกป้องผิวกระดูกอ่อนของ-  
พืชีเอสโอทำสองสีในสุนัขที่เป็นโรคข้อเสื่อมที่เกิดจากโรคสะบ้าเคลื่อนด้านใน”

ชื่อสุนัข..... ครั้งที่..... วันที่.....

- เกี่ยวกับระดับความเจ็บปวด: ให้คะแนนระหว่าง 0 (น้อยที่สุด) ถึง 10 (มากที่สุด)										
1. ระดับความเจ็บปวดที่ <u>แย่ที่สุด</u> ในช่วง 7 วันที่ผ่าน										
<input type="radio"/> 0	<input type="radio"/> 1	<input type="radio"/> 2	<input type="radio"/> 3	<input type="radio"/> 4	<input type="radio"/> 5	<input type="radio"/> 6	<input type="radio"/> 7	<input type="radio"/> 8	<input type="radio"/> 9	<input type="radio"/> 10
2. ระดับความเจ็บปวดที่ <u>น้อยที่สุด</u> ในช่วง 7 วันที่ผ่าน										
<input type="radio"/> 0	<input type="radio"/> 1	<input type="radio"/> 2	<input type="radio"/> 3	<input type="radio"/> 4	<input type="radio"/> 5	<input type="radio"/> 6	<input type="radio"/> 7	<input type="radio"/> 8	<input type="radio"/> 9	<input type="radio"/> 10
3. ระดับความเจ็บปวด <u>เฉลี่ย</u> ในช่วง 7 วันที่ผ่าน										
<input type="radio"/> 0	<input type="radio"/> 1	<input type="radio"/> 2	<input type="radio"/> 3	<input type="radio"/> 4	<input type="radio"/> 5	<input type="radio"/> 6	<input type="radio"/> 7	<input type="radio"/> 8	<input type="radio"/> 9	<input type="radio"/> 10
4. ระดับความเจ็บปวด <u>ในปัจจุบัน</u>										
<input type="radio"/> 0	<input type="radio"/> 1	<input type="radio"/> 2	<input type="radio"/> 3	<input type="radio"/> 4	<input type="radio"/> 5	<input type="radio"/> 6	<input type="radio"/> 7	<input type="radio"/> 8	<input type="radio"/> 9	<input type="radio"/> 10
- เกี่ยวกับหน้าที่การทำงานของขาในช่วง 7 วันที่ผ่านมา โดยสังเกตว่าความเจ็บปวดส่งผลต่อการ ใช้ขาของสุนัขมากน้อยเพียงใด: ให้คะแนนระหว่าง 0 (ความเจ็บปวดมีผลน้อยที่สุด) ถึง 10 (ความเจ็บปวดมีผลมากที่สุด)										
5. การทำกิจกรรมทั่วไป										
<input type="radio"/> 0	<input type="radio"/> 1	<input type="radio"/> 2	<input type="radio"/> 3	<input type="radio"/> 4	<input type="radio"/> 5	<input type="radio"/> 6	<input type="radio"/> 7	<input type="radio"/> 8	<input type="radio"/> 9	<input type="radio"/> 10
6. ความสนุกในชีวิต										
<input type="radio"/> 0	<input type="radio"/> 1	<input type="radio"/> 2	<input type="radio"/> 3	<input type="radio"/> 4	<input type="radio"/> 5	<input type="radio"/> 6	<input type="radio"/> 7	<input type="radio"/> 8	<input type="radio"/> 9	<input type="radio"/> 10
7. ความสามารถในการลุกยืนหลังจากนอน										
<input type="radio"/> 0	<input type="radio"/> 1	<input type="radio"/> 2	<input type="radio"/> 3	<input type="radio"/> 4	<input type="radio"/> 5	<input type="radio"/> 6	<input type="radio"/> 7	<input type="radio"/> 8	<input type="radio"/> 9	<input type="radio"/> 10
8. ความสามารถในการเดิน										
<input type="radio"/> 0	<input type="radio"/> 1	<input type="radio"/> 2	<input type="radio"/> 3	<input type="radio"/> 4	<input type="radio"/> 5	<input type="radio"/> 6	<input type="radio"/> 7	<input type="radio"/> 8	<input type="radio"/> 9	<input type="radio"/> 10
9. ความสามารถในการวิ่ง										
<input type="radio"/> 0	<input type="radio"/> 1	<input type="radio"/> 2	<input type="radio"/> 3	<input type="radio"/> 4	<input type="radio"/> 5	<input type="radio"/> 6	<input type="radio"/> 7	<input type="radio"/> 8	<input type="radio"/> 9	<input type="radio"/> 10
10. ความสามารถในการเดินขึ้นบันได										
<input type="radio"/> 0	<input type="radio"/> 1	<input type="radio"/> 2	<input type="radio"/> 3	<input type="radio"/> 4	<input type="radio"/> 5	<input type="radio"/> 6	<input type="radio"/> 7	<input type="radio"/> 8	<input type="radio"/> 9	<input type="radio"/> 10
- ความพึงพอใจโดยรวมในด้านคุณภาพชีวิตของสุนัขในช่วง 7 วันที่ผ่านมา										
<input type="radio"/> น้อยมาก <input type="radio"/> น้อย <input type="radio"/> ปานกลาง <input type="radio"/> ดี <input type="radio"/> ดีมาก										

Figure 13 Questionnaires of Canine BPI aimed to evaluate the severity of pain modified from Cleeland, (2006)



### 3.3 Data presentation and statistical analysis

The parameters of breed, gender, age, body weight and the severity of MPL grades were reported as descriptive statistic. D'Agostino & Pearson omnibus and Kolmogorov-Smirnov normality test with Dallal-Wilkinson-Lilliefors P value were used to determine for normal distribution of age and body weight, respectively. Age, body weight, lameness score, CBC, blood chemistry parameters, ultrasonographic score, synovial fluid score, articular cartilage score, bone surface score, cartilage thickness and radiographic OA scores were reported as mean  $\pm$  SD. Ordinary one-way analysis of variance (ANOVA) was used for analyze age, body weight and cartilage thickness among normal, control and treatment groups. Kruskal-Wallis test was used for analyze gender among groups. Mann-Whitney U test was used for assess the differences of the severity of MPL, lameness score, CBC, blood chemistry parameters, ultrasonographic score, synovial fluid score, articular cartilage score, bone surface score and radiographic OA scores between control and treatment groups. Friedman test were used for assess within groups of lameness score, degree of pain, degree of life quality, ultrasonographic score, synovial fluid score, articular cartilage score, bone surface score and radiographic OA score. Repeated-measure one-way ANOVA was used for analyze the differences of cartilage thickness in each visit within group.

Graphpad Prism 8 (version 8.1.0) was used for the statistical analysis. The results were considered statistically significant at a  $p$ -value  $< 0.05$ .

## CHAPTER IV

### RESULTS

Twenty-five dogs (50 stifle joints) were enrolled in this study. They were classified as 42 medial patellar luxation and 8 normal stifles. Forty-two stifles with MPL were divided into control and treatment groups. These stifles were collected from 21 dogs, which were 13 Pomeranians (61.9%) and 8 Chihuahuas (38.1%). Of 21 dogs, 12 (57.14%) were female and 9 (42.86%) were male. The control group composed of 10 dogs (20 stifle joints) from 7 Pomeranians and 3 Chihuahuas, which were 4 males and 6 females. The mean  $\pm$  *SD* of age was  $6.40 \pm 1.27$  years and body weight was  $3.49 \pm 1.04$  kilograms. The treatment group comprised of 11 dogs (22 stifle joints) from 6 Pomeranians and 5 Chihuahuas, including 5 males and 6 females. The mean  $\pm$  *SD* of age was  $6.36 \pm 1.8$  years and body weight was  $3.27 \pm 1.08$  kilograms. In normal group, there is 8 normal stifles collected from 4 dogs. Each two dogs were Pomeranians and Chihuahuas, including 3 males (75%) and 1 females (25%). The mean  $\pm$  *SD* of age was  $5 \pm 2.31$  years and body weight was  $3.72 \pm 0.91$  kilograms. Mean  $\pm$  *SD* of age and body weight of dogs and the number of gender among all groups were not found significant difference, which are shown in table 9. Stifle joints with MPL in control and treatment groups were classified into theirs severity shown in table 10. The severity of MPL was not significantly different among the groups.

Table 9 Mean  $\pm$  SD of age and body weight and the number of gender of dogs in control, treatment and normal groups

Demographic data		Control group (N =10)	Treatment group (N = 11)	Normal group (N =4)	p-value
Age (year)		6.40 $\pm$ 1.27	6.36 $\pm$ 1.80	5.0 $\pm$ 2.31	0.34*
Body weight (kg)		3.49 $\pm$ 1.04	3.27 $\pm$ 1.08	3.73 $\pm$ 0.91	0.74*
Gender (N)	Male (N)	4	5	3	0.498**
	Female (N)	6	6	1	

\*p-value is obtained from ordinary one-way ANOVA.

\*\*p-value is obtained from Kruskal-Wallis test.

Table 10 Number of dogs categorized from severity of MPL in control and treatment groups

Groups	MPL II	MPL III	MPL IV	p-value
Control group (n= 20)	(6/20) 30 %	(13/20) 65 %	(1/20) 5 %	0.37*
Treatment group (n= 22)	(3/22) 13.64 %	(19/22) 86.36 %	(0/22) 0 %	
All stifles	(9/42) 21.43 %	(32/42) 76.19 %	(1/42) 2.38 %	

\*p-value is obtained from Mann-Whitney U test.

#### 4.1 Lameness score

The evaluation of lameness score was performed in all dogs for 6 times within 16 weeks. Results revealed that the lameness score in treatment group showed significant difference ( $p < 0.05$ ) at W8 to W16, while in control group showed no difference in any week of the study. There were significant difference among groups after 12 weeks of the treatment ( $p < 0.05$ ). Mean  $\pm$  SD of lameness score in control and treatment groups are illustrated in figure 14 and 15, respectively. The improvement of lameness score at least one degree between each visit are shown in table 11.

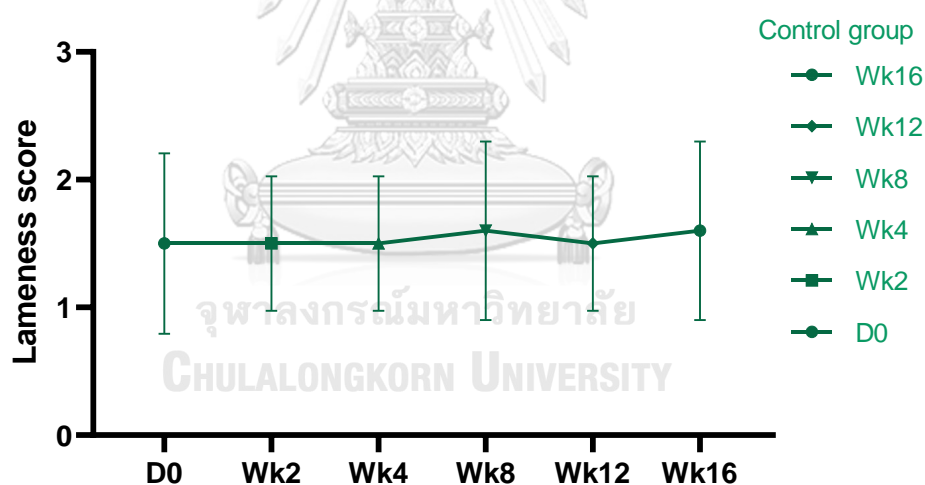


Figure 14 Mean  $\pm$  SD of lameness score of control group in each monitoring week.

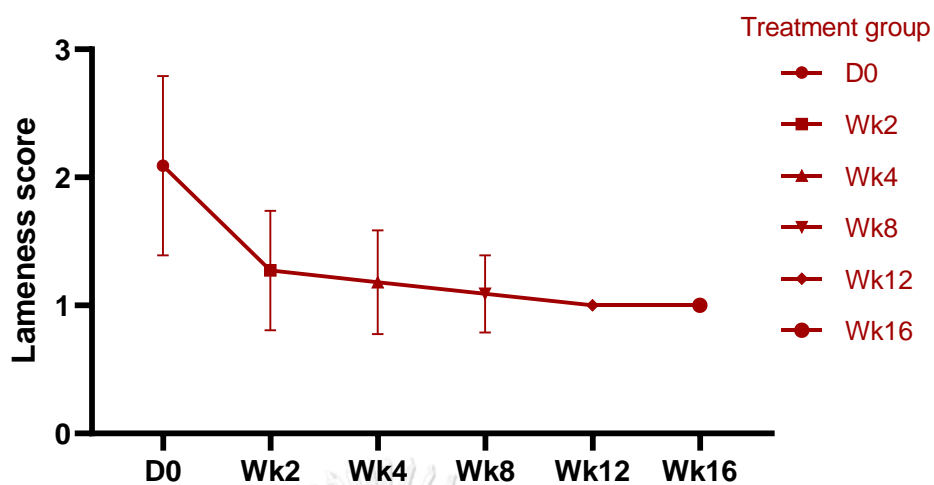


Figure 15 Mean  $\pm$  SD of lameness score of treatment group in each monitoring week.

Table 11 Percentage of the improvement of lameness score at least one degree between adjacent visits: D0-W2, W2-W4, W4-W8, W8-W12 and W12-W16

Groups	D0-W2	W2-W4	W4-W8	W8-W12	W12-W16
Control group (n=10)	(1/10) 10 %	(0/10) 0 %	(1/10) -10 %	(1/10) 10 %	(1/10) -10 %
Treatment group (n=11)	(9/11) 81.82 %	(1/11) 9.10 %	(1/11) 9.10 %	(1/11) 9.10 %	(0/11) 0 %

## 4.2 Blood profiles

All dogs in control and treatment groups were evaluated CBC and the standard blood chemistry parameters before treatment (D0) and after treatment (W16). Each parameter in both groups was not found significant difference between D0 and W16. Mean  $\pm$  SD of these parameters in both groups are shown in table 12. Though most of the parameters were in normal range at both D0 and W16 in the two groups, the value of ALT, the liver parameters, were mild increased in some week of both groups.



Table 12 Comparison of CBC and the standard blood chemistry profiles between pre-treatment (D0) and post-treatment (W16) within group

Parameters	Normal range	D0		W16		p-value	
		Treatment group		Treatment group			
		Control group	Treatment group	Control group	Treatment group		
RBC (×10 <sup>6</sup> /μl)	5.10-8.50	7.10±0.48	6.87±0.72	7.18±0.68	6.90±0.71	0.683	0.781
Hemoglobin (g/dl)	11.0-19.0	17.10±1.12	17.00±2.45	17.10±1.93	17.15±2.09	0.903	0.650
Hematocrit (%)	33.0-56.0	45.6±2.7	45.08±6.53	45.8±3.95	45.91±5.16	0.826	0.324
Platelet (×10 <sup>3</sup> /μl)	117-490	324.4±111.3	363.2±163.6	306.2±102.3	354.5±123.2	0.463	0.791
WBC (×10 <sup>3</sup> /μl)	6.0-17.00	10.32±2.00	9.17±2.70	10.22±2.41	9.28±2.49	0.870	0.880
Neutrophils (×10 <sup>3</sup> /μl)	3.62-12.30	7.28±1.83	5.89±2.46	7.29±2.10	6.16±2.04	0.984	0.880
Eosinophils (×10 <sup>3</sup> /μl)	0.04-1.62	0.53±0.28	0.45±0.15	0.55±0.36	0.49±0.27	0.791	0.644
Basophils (×10 <sup>3</sup> /μl)	0.00-0.12	0.020±0.015	0.018±0.009	0.017±0.009	0.017±0.016	0.616	0.882
Lymphocytes (×10 <sup>3</sup> /μl)	0.83-4.91	1.74±0.47	2.04±0.62	1.52±0.67	2.00±0.82	0.419	0.798
Monocytes (×10 <sup>3</sup> /μl)	0.14-1.97	0.76±0.23	0.77±0.22	0.63±0.29	0.66±0.21	0.102	0.061
BUN (mg/dl)	7.0-30.0	23.4±7.71	22.18±8.54	21.2±5.61	18.90±7.26	0.270	0.164
Creatinine (mg/dl)	0.6-2.0	0.82±0.31	0.76±0.16	0.81±0.21	0.84±0.36	0.811	0.513
ALT(SGPT) (g/dl)	4-91	62.3±41.1	104.5±83.22	110±145	63.00±29.52	0.244	0.125
ALP (g/dl)	43-115	61.3±73.6	85.09±93.01	84.3±120	78.91±70.01	0.165	0.712

All *p*-value are obtained from paired t-test

### 4.3 Ultrasonographic examination

From eight normal stifles, the ultrasonographic findings showed in figure 16 to 19. The characters of the normal stifle joint were as describe as Möller et al., (2008) and Penninck and d'Anjou, (2015). In suprapatellar region, the suprapatellar recess was seen above the femoral condyle which the average thick was 2.4 mm (Figure 16). Synovial fluid was found as anechoic content with homogeneous echogenicity in infrapatellar region (Figure 17A and 17B). Along the aspects of the femoral condyle of suprapatellar and infrapatellar regions, the hyaline cartilage appeared as an anechoic band with smooth and sharp hyperechoic margin (Figure 17B, 18 and 19). The bone surface presented with the uniformity of bone profile and smooth boundary (Figure 17B, 18 and 19). In transverse view of suprapatellar region, medial and lateral femoral condyle were appeared, the average of cartilage thickness of medial, middle and lateral areas were  $0.204 \pm 0.013$ ,  $0.217 \pm 0.026$  and  $0.213 \pm 0.025$  mm, respectively (Figure 19).

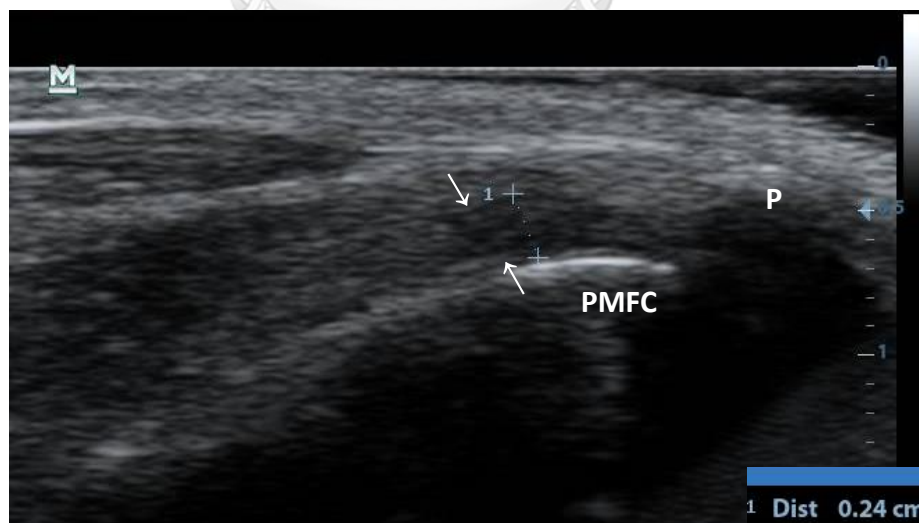


Figure 16 Longitudinal view of suprapatellar region of normal stifle joint. Suprapatellar recess (arrows) was seen over the proximal of medial femoral condyle (PMFC). Patella (P) was used as landmark



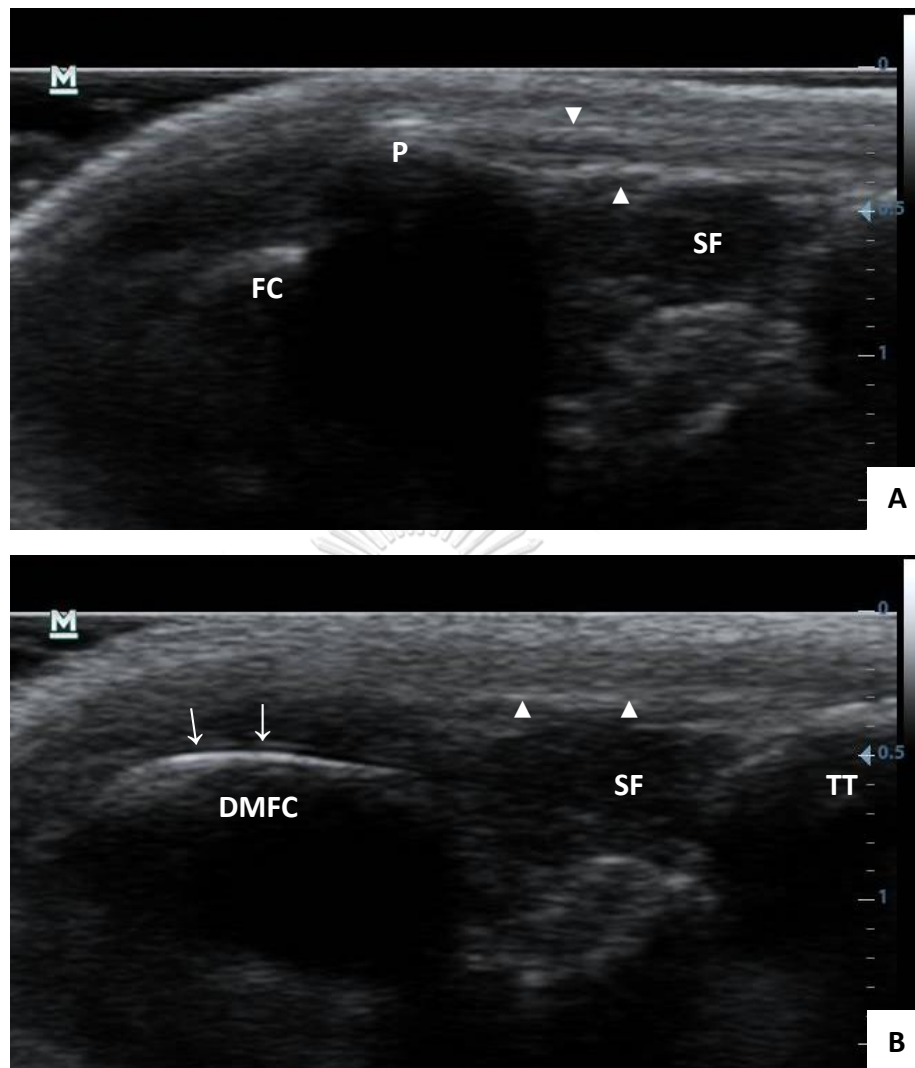


Figure 17 Ultrasonographic images of infrapatellar region with sagittal view of the normal stifle joint. (A) Patella (P) and tibial tuberosity (TT) were used as landmark of this view. Synovial fluid (SF) showed anechoic opacity underneath the patellar ligament (arrowheads). (B) This region appeared distal aspect of medial femoral condyle (DMFC). Anechoic band with smooth margin of the articular cartilage (arrows) was seen over its bone surface which appeared as hyperechoic smooth lining

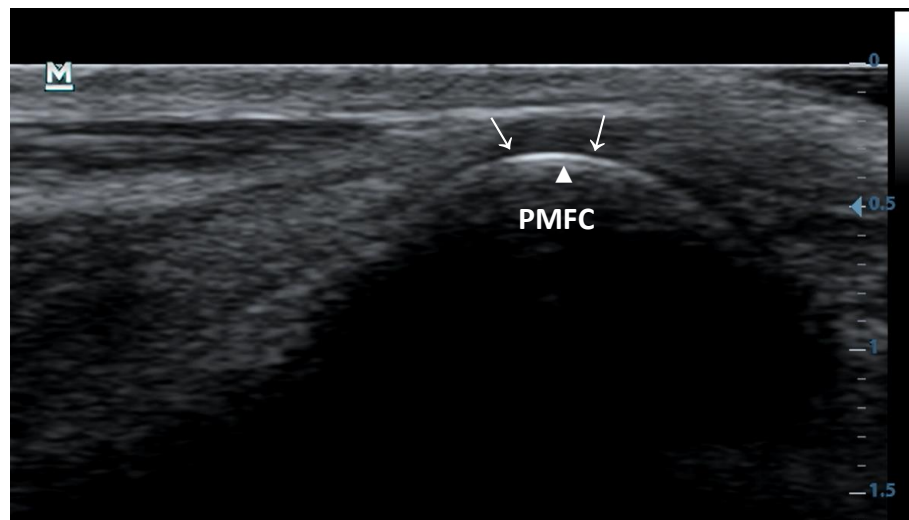


Figure 18 Ultrasonographic image of suprapatellar region with sagittal view of the normal stifle joint. Proximal aspect of medial femoral condyle (PMFC) was shown. Bone surface (arrowheads) and the articular cartilage (arrows) covering them were seen

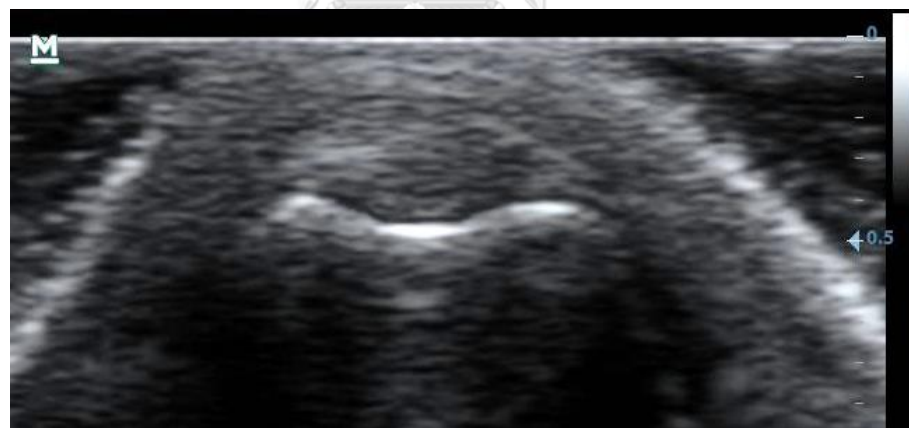


Figure 19 Ultrasonographic image of suprapatellar region with transverse view of the normal stifle joint. Thickness of the articular cartilage of medial and lateral femoral condyles were determined

The evaluations of ultrasonographic scores and the thickness of articular cartilage are calculated in mean  $\pm$  *SD* shown in table 13 and 14, respectively. The ultrasonographic scores of treatment group were significantly different between pre-treatment and W4 to W16 post-treatment ( $p < 0.05$ ) while no significant difference of these parameters was observed in control group. Furthermore, a significant difference was observed between two groups of treatment after 4 weeks post-treatment ( $p < 0.05$ ).

Lesions of the articular cartilage and bone surface were found in all medial ridge of femoral condyles, while there were not detected on both proximal and distal aspects of lateral femoral condyles.

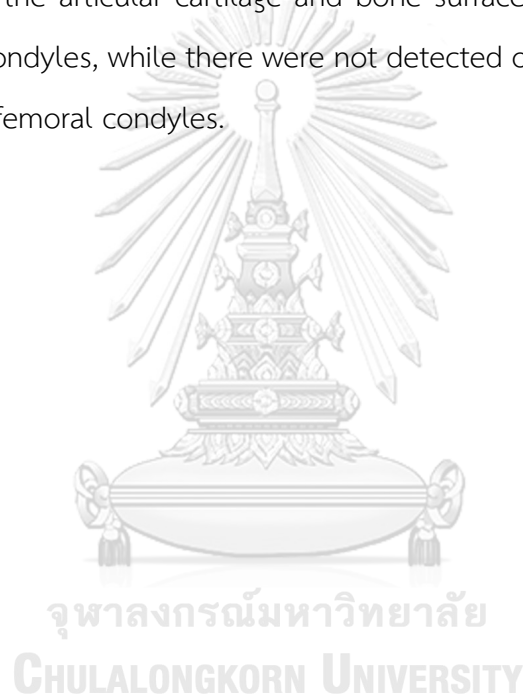

Table 13 Mean  $\pm$  SD of ultrasonographic, synovial fluid, articular cartilage and bone surface score of the control and treatment groups

Ultrasonographic parameters		Day 0	Week 2	Week 4	Week 8	Week 12	Week 16
Ultrasonographic score	Control group	9.10 $\pm$ 2.38 <sup>aA</sup>	9.10 $\pm$ 2.40 <sup>aA</sup>	9.40 $\pm$ 2.21 <sup>aA</sup>	9.65 $\pm$ 2.62 <sup>aA</sup>	9.30 $\pm$ 2.18 <sup>aA</sup>	7.65 $\pm$ 3.98 <sup>aA</sup>
	Treatment group	9.09 $\pm$ 2.91 <sup>aA</sup>	7.91 $\pm$ 2.89 <sup>abA</sup>	6.82 $\pm$ 2.52 <sup>bcB</sup>	5.77 $\pm$ 2.20 <sup>cdB</sup>	5.14 $\pm$ 2.17 <sup>dB</sup>	4.86 $\pm$ 1.93 <sup>dB</sup>
Synovial fluid score	Control group	2.40 $\pm$ 0.68 <sup>aA</sup>	2.45 $\pm$ 0.76 <sup>aA</sup>	2.60 $\pm$ 0.75 <sup>aA</sup>	2.75 $\pm$ 0.79 <sup>aA</sup>	2.55 $\pm$ 0.76 <sup>aA</sup>	2.60 $\pm$ 0.75 <sup>aA</sup>
	Treatment group	2.88 $\pm$ 0.66 <sup>aA</sup>	2.23 $\pm$ 0.61 <sup>abA</sup>	1.91 $\pm$ 0.81 <sup>bB</sup>	1.82 $\pm$ 0.80 <sup>bB</sup>	1.59 $\pm$ 0.85 <sup>bB</sup>	1.59 $\pm$ 0.80 <sup>bB</sup>
Articular cartilage score	Control group	2.95 $\pm$ 0.22 <sup>aA</sup>	2.90 $\pm$ 0.31 <sup>aA</sup>	2.95 $\pm$ 0.22 <sup>aA</sup>	2.85 $\pm$ 0.49 <sup>aA</sup>	2.90 $\pm$ 0.31 <sup>aA</sup>	2.95 $\pm$ 0.22 <sup>aA</sup>
	Treatment group	2.95 $\pm$ 0.21 <sup>aA</sup>	2.55 $\pm$ 0.67 <sup>abA</sup>	2.00 $\pm$ 0.69 <sup>bcB</sup>	1.50 $\pm$ 0.67 <sup>cdB</sup>	1.14 $\pm$ 0.35 <sup>dB</sup>	1.09 $\pm$ 0.53 <sup>dB</sup>
	Control group	1.10 $\pm$ 1.25 <sup>aA</sup>	1.15 $\pm$ 1.27 <sup>aA</sup>	1.15 $\pm$ 1.27 <sup>aA</sup>	1.30 $\pm$ 1.38 <sup>aA</sup>	1.15 $\pm$ 1.27 <sup>aA</sup>	1.20 $\pm$ 1.32 <sup>aA</sup>
	Treatment group	1.00 $\pm$ 1.38 <sup>aA</sup>	0.96 $\pm$ 1.35 <sup>aA</sup>	0.64 $\pm$ 1.00 <sup>abA</sup>	0.50 $\pm$ 0.80 <sup>abB</sup>	0.41 $\pm$ 0.73 <sup>bB</sup>	0.36 $\pm$ 0.66 <sup>bB</sup>
Bone surface score	Control group	2.00 $\pm$ 0.56 <sup>aA</sup>	1.95 $\pm$ 0.61 <sup>aA</sup>	2.00 $\pm$ 0.56 <sup>aA</sup>	2.05 $\pm$ 0.61 <sup>aA</sup>	1.95 $\pm$ 0.61 <sup>aA</sup>	2.15 $\pm$ 0.59 <sup>aA</sup>
	Treatment group	1.64 $\pm$ 0.73 <sup>aA</sup>	1.64 $\pm$ 0.73 <sup>aA</sup>	1.64 $\pm$ 0.73 <sup>aA</sup>	1.50 $\pm$ 0.60 <sup>aA</sup>	1.45 $\pm$ 0.60 <sup>aA</sup>	1.36 $\pm$ 0.58 <sup>aA</sup>
	Control group	0.65 $\pm$ 0.75 <sup>aA</sup>	0.65 $\pm$ 0.75 <sup>aA</sup>	0.74 $\pm$ 0.80 <sup>aA</sup>	0.74 $\pm$ 0.80 <sup>aA</sup>	0.74 $\pm$ 0.80 <sup>aA</sup>	0.74 $\pm$ 0.80 <sup>aA</sup>
	Treatment group	0.50 $\pm$ 0.74 <sup>aA</sup>	0.50 $\pm$ 0.74 <sup>aA</sup>	0.50 $\pm$ 0.74 <sup>aA</sup>	0.46 $\pm$ 0.67 <sup>aA</sup>	0.41 $\pm$ 0.59 <sup>aA</sup>	0.41 $\pm$ 0.59 <sup>aA</sup>

Values in the same row followed by different superscript lowercase letter differ significantly by Friedman test ( $p < 0.05$ ). Values in the same ultrasonographic parameters between two groups followed by different superscript uppercase letter differ significantly by Mann-Whitney U test ( $p < 0.05$ ).

Table 14 Mean  $\pm$  SD of the articular cartilage thickness of medial, middle and lateral of femoral condyles of the control and treatment groups

Groups	positions	Day 0	Week 2	Week 4	Week 8	Week 12	Week 16
Control group	Medial	0.235 $\pm$ 0.032	0.230 $\pm$ 0.038	0.231 $\pm$ 0.030	0.226 $\pm$ 0.024	0.237 $\pm$ 0.030	0.236 $\pm$ 0.035
	Middle	0.227 $\pm$ 0.046	0.222 $\pm$ 0.032	0.216 $\pm$ 0.025	0.227 $\pm$ 0.020	0.220 $\pm$ 0.019	0.220 $\pm$ 0.030
	Lateral	0.258 $\pm$ 0.13	0.217 $\pm$ 0.026	0.227 $\pm$ 0.034	0.224 $\pm$ 0.024	0.231 $\pm$ 0.038	0.226 $\pm$ 0.038
Treatment group	Medial	0.245 $\pm$ 0.045	0.235 $\pm$ 0.048	0.243 $\pm$ 0.042	0.244 $\pm$ 0.033	0.230 $\pm$ 0.036	0.229 $\pm$ 0.036
	Middle	0.226 $\pm$ 0.034	0.231 $\pm$ 0.031	0.266 $\pm$ 0.021	0.226 $\pm$ 0.036	0.222 $\pm$ 0.033	0.210 $\pm$ 0.020
	Lateral	0.211 $\pm$ 0.019	0.225 $\pm$ 0.034	0.230 $\pm$ 0.033	0.225 $\pm$ 0.029	0.224 $\pm$ 0.030	0.218 $\pm$ 0.029

Values in the same row are not significantly different by Repeated-measure one way ANOVA ( $p > 0.05$ ).

Results revealed that the synovial fluid scores in PCSO-524 group were found a significant difference between pre-treatment (D0) and post-treatment at W4 to W16 ( $p < 0.05$ ) while there is no significant difference observed in control group. Synovial fluid score was significant different between two groups of treatment after 4 weeks post-treatment ( $p < 0.05$ ). Mean  $\pm$  SD of synovial fluid scores of both groups are shown in figure 20.

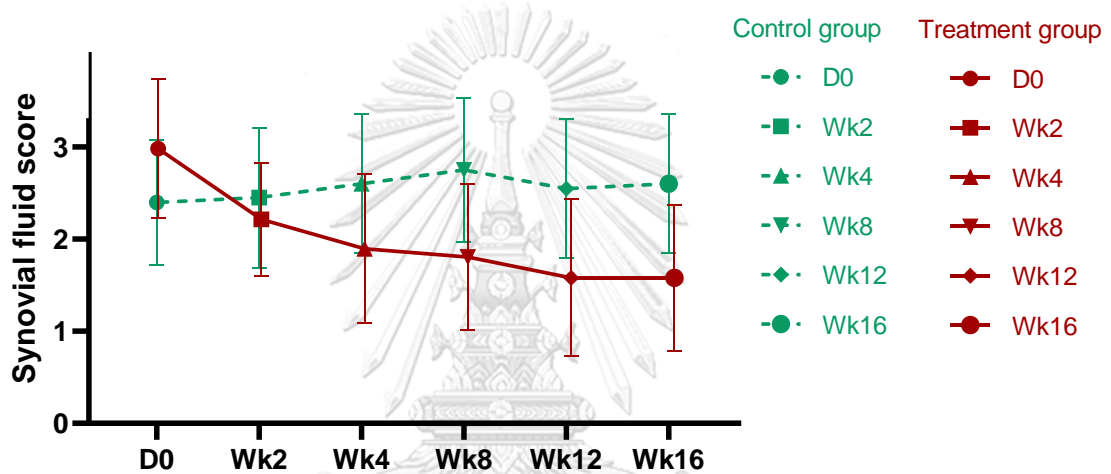


Figure 20 Mean  $\pm$  SD of the synovial fluid score of the control and the treatment groups in each monitoring week

In treatment group, the articular cartilage scores of proximal aspect of medial femoral condyle found significant decreased ( $p < 0.05$ ) between pre-treatment (D0) and post-treatment at week 4 to 16 while in control group were not significant difference. There were significant difference after 4 weeks post-treatment between control and treatment groups ( $p < 0.05$ ). The improvement of the articular cartilage lesion between pre-treatment (D0) and post-treatment at week 4<sup>th</sup> are shown in figure 21. Mean  $\pm$  SD of articular cartilage score of proximal aspect of medial femoral condyle of control and treatment groups are shown in figure 22.

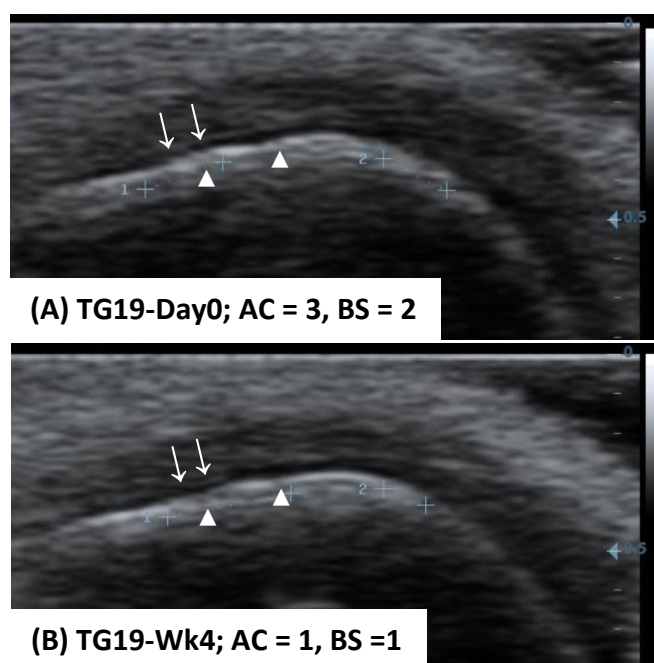


Figure 21 Ultrasonographic images of suprapatellar region with sagittal view between pre-treatment (D0) and post-treatment at week 4<sup>th</sup>. (A) The articular cartilage (arrows) showed heterogeneous opacity with irregular margin (AC = 3) and bone surface (arrowheads) was moderate irregular hyperechoic lining (BS = 2). (B) The articular cartilage (arrows) was hypoechoic appearance with irregular margin (AC = 1) and bone surface (arrowheads) presented mild irregular hyperechoic lining (BS = 1)

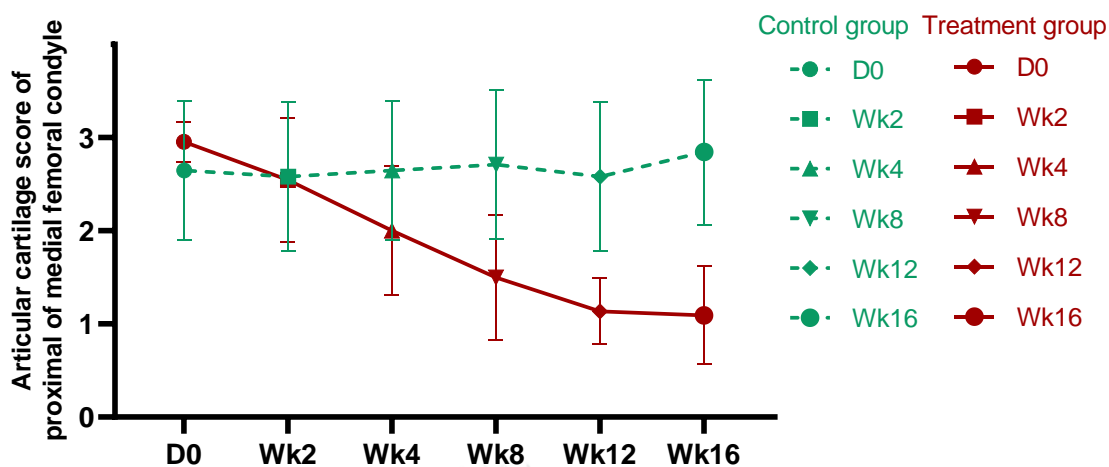


Figure 22 Mean  $\pm$  SD of the articular cartilage score of proximal aspect of medial femoral condyle of the control and the treatment groups in each monitoring week

The eroded cartilage of distal part of medial femoral condyle were found in 10 and 8 stifle joints from control and treatment groups, respectively. There is 42.8 percent of MPL stifles found the erosion at distal portion of medial femoral condyle. The articular cartilage scores of distal aspect of medial femoral condyle showed a significant decrease ( $p < 0.05$ ) between D0 and post-treatment at week 12 and 16 while in control group were not significant difference. There were significant difference after 8 weeks post-treatment between two groups of treatment ( $p < 0.05$ ).

The bone surface scores of both proximal and distal parts of medial femoral condyle were not significant difference in both control and treatment groups. This score was not significant difference between control and treatment groups.



#### 4.4 Radiographic examination

Radiography of stifle joints were performed in two standard orthogonal views, including the mediolateral and the caudocranial views. The OA scores were calculated in range between 0 and 45. The OA scores of control group were a significant increase at W12 and W16 when compare with pre-treatment at D0 ( $p < 0.05$ ). In treatment groups, the OA scores found a significant decrease at W12 and W16 when compare with pre-treatment at D0 ( $p < 0.05$ ). Mean  $\pm$  SD of the radiographic OA score of control and treatment groups are shown in figure 23.

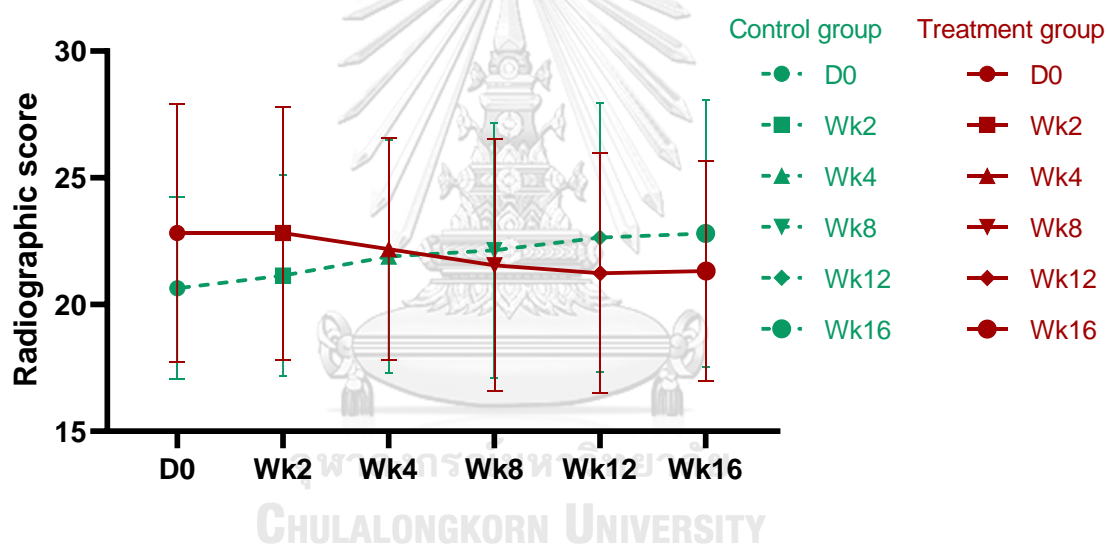


Figure 23 Mean  $\pm$  SD of the radiographic OA score of the control and the treatment groups in each monitoring week.

#### 4.5 Owner questionnaire

The degrees of pain and life quality were statistically significant difference both in control and treatment groups. In control group, the difference of pain degrees showed between D0 and W12 to W16 and the satisfaction of life quality found the difference between D0 and W4, W12 and W16. In treatment group, the degrees of pain and the satisfaction of life quality were found significant increased after 4 weeks of the administration. There were not significant different when comparison between control and treatment groups. Mean  $\pm$  SD of pain and life quality degrees are compared between groups in figure 24 and 25, respectively. Mean  $\pm$  SD of these degrees in control and treatment groups are illustrated in table 15.

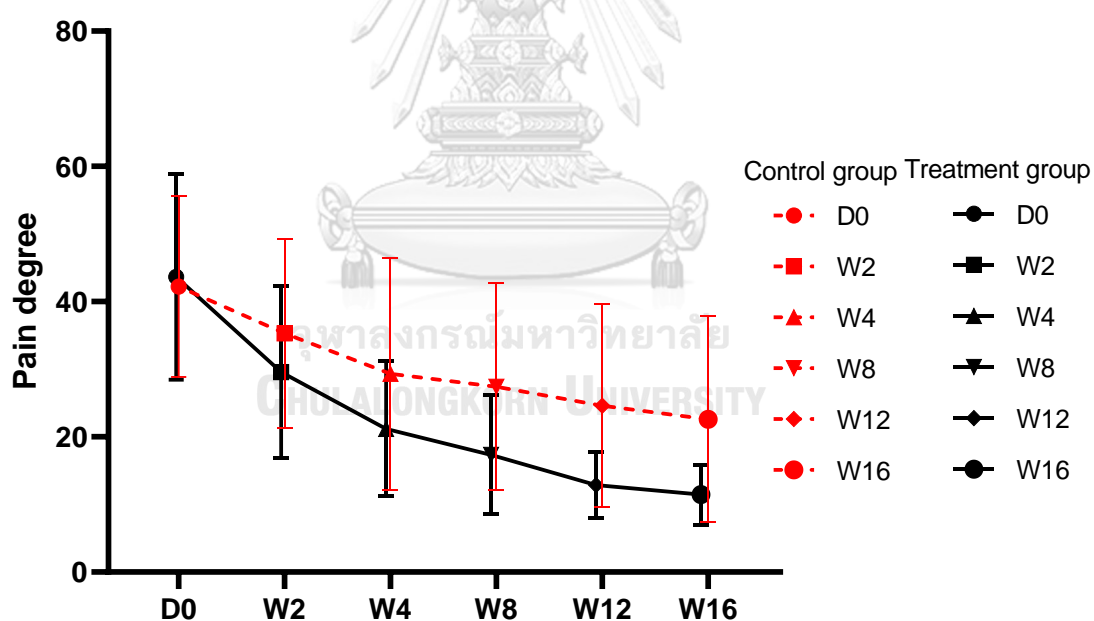


Figure 24 Comparison of mean  $\pm$  SD of the pain degrees in both control and treatment groups

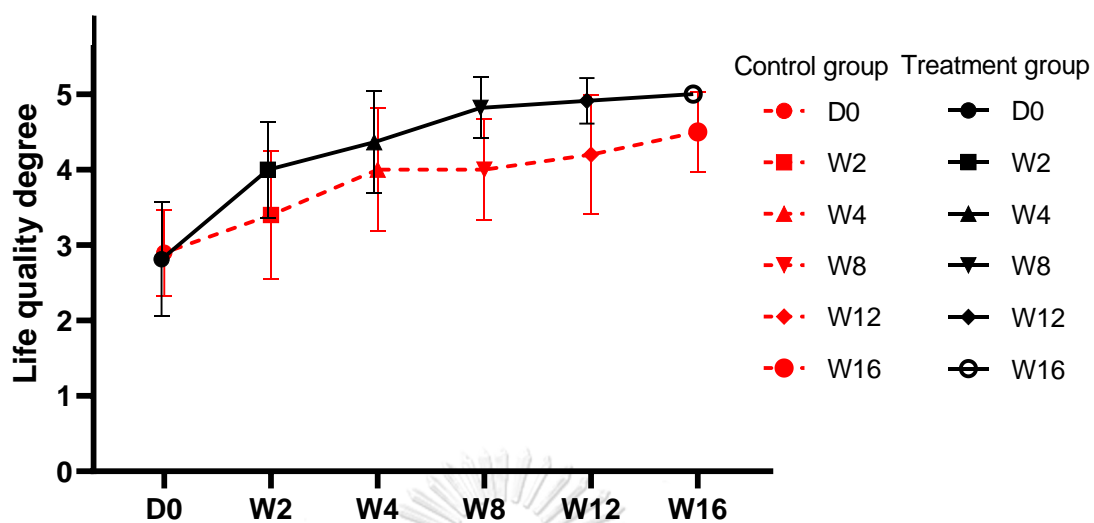


Figure 25 Comparison of mean  $\pm$  SD of the life quality degrees in both control and treatment groups

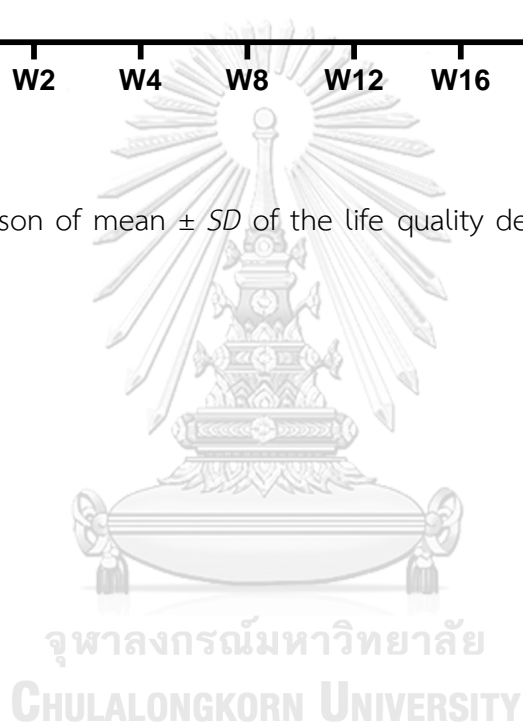


Table 15 Mean  $\pm$  SD of the degrees of pain and life quality, which evaluated by the questionnaire of Canine BPI within group

Canine BPI parameters	Groups	D0	W2	W4	W8	W12	W16
Degree of pain	Control group	42.20 $\pm$ 13.36 <sup>a</sup>	35.30 $\pm$ 13.97 <sup>a</sup>	29.30 $\pm$ 17.22 <sup>a</sup>	27.40 $\pm$ 15.31 <sup>a</sup>	24.60 $\pm$ 15.01 <sup>a</sup>	22.60 $\pm$ 15.21 <sup>a</sup>
	Treatment group	52.45 $\pm$ 18.27 <sup>a</sup>	35.55 $\pm$ 15.27 <sup>ab</sup>	25.45 $\pm$ 12.02 <sup>bc</sup>	20.82 $\pm$ 10.59 <sup>bd</sup>	15.45 $\pm$ 5.91 <sup>cd</sup>	13.73 $\pm$ 5.35 <sup>d</sup>
Degree of life quality	Control group	2.9 $\pm$ 0.57 <sup>a</sup>	3.4 $\pm$ 0.84 <sup>ab</sup>	4.0 $\pm$ 0.82 <sup>bc</sup>	4.0 $\pm$ 0.67 <sup>acd,A</sup>	4.2 $\pm$ 0.79 <sup>bd,A</sup>	4.5 $\pm$ 0.53 <sup>cd,A</sup>
	Treatment group	2.82 $\pm$ 0.75 <sup>a</sup>	4.00 $\pm$ 0.63 <sup>ab</sup>	4.36 $\pm$ 0.67 <sup>b</sup>	4.81 $\pm$ 0.40 <sup>b,B</sup>	4.91 $\pm$ 0.30 <sup>b,B</sup>	5.0 $\pm$ 0 <sup>b,B</sup>

Values in the same row followed by different superscript lowercase letter differ significantly by Friedman test ( $p < 0.05$ ). Values in the same Canine BPI parameters between two groups followed by different superscript uppercase letter differ significantly by Mann-Whitney U test ( $p < 0.05$ ).

## CHAPTER V

### DISCUSSION

Medial patellar luxation (MPL) has been known as one of the most common developmental orthopedic disease in dogs, particularly in small and toy breed dogs (Roy et al., 1992; Alam et al., 2007; Wangdee, 2014). The abnormality of biomechanics and repeated mechanical trauma to the articular cartilage are the main problem of this disease. It commonly leads to secondary OA of stifle joints due to the permanent joint instability and malalignment of the extensor mechanism (Hayes et al., 1994; Alam et al., 2011). Restoring normal stifle function is recommended to prevent the progressive degeneration (Roy et al., 1992). However, a number of dogs suffering from MPL cannot admitted the operation. Therefore, the conservation treatment has been established. This study focus on PCSO-524, nutraceuticals which has potential in relieving OA pain, in the effectiveness in protection of the articular cartilage.

In this study, age, body weight and gender among the normal, the control and the treatment groups were not significantly different. Of all MPL dogs in the study, grade III MPL was mostly found as 76.19% and grade II luxation was secondary found as 21.43%. The distribution of the luxation grades was not in accordance with the recent studies, with grade II of MPL being the most prevalent luxation grade (Daems et al., 2009; Wangdee, 2014). The contrasting reports may be due the differences in the breeds and age of dogs between these studies. The study conducted by Daems et al., (2009) included dogs with any breeds and ages in the range of 0.67-11.17 years (the mean age is 4.08 years), while this study included only Pomeranian and Chihuahua breeds and ages in the range of 5-10 years (the mean age is 6.36 years). The results of

this study can be implied that Pomeranian and Chihuahua over five years visiting at the Small Animal Hospital, Faculty of Veterinary Science, Chulalongkorn University, have a higher prevalence with MPL grade III more than others grade of MPL. Moreover, this study found only one stifle with grade IV luxation. The reason is that dogs with MPL grade IV mostly show more clinical signs; lameness and pain, which make more concern to owners. The conservative treatment or surgical correction are widely needed. Some of them may develop to secondary diseases such as hip joint luxation, cranial cruciate ligament rupture (CCLR) or meniscal tear.

The results of lameness score in treatment group were statistically found to have a significant improvement within 8 weeks after administration of PCSO-524. However, all owners had observed an enhancement of dog's life quality since the second week. This is in accordance with the lameness score results. Over eighty percent of dogs (9/11 dogs) in treatment group were found a better gaiting after two weeks of PCSO-524 administration. The previous studies have also observed the improvement of lameness score and peak-vertical force gait analysis after taking the supplement within 2 weeks in dogs with shoulder and hip OA (Soontornvipart et al., 2015). This is in agreement with the study of Kwananocha et al., (2016) who has reported the effects of PCSO-524 in hip and stifle OA. Since our study was breed specific, the number of patients in this study might not be large enough to obtain the significant difference within 2 weeks.

Regarding the questionnaire of Canine BPI, a significant difference was observed in both groups. In control group, pain degrees were significantly improved after 12 weeks of placebo administration. On the contrary, the statistically significant results of dog's life quality were quite fluctuated. Better results in some visits may be explained by the placebo effects and the other conservative management such as training quadriceps muscle and restriction of over exercise on the slippery floor, which have been recommended to all owners. Furthermore, dogs with MPL show the variety degrees of clinical signs from asymptomatic, mild to moderate lameness, which can

be occurred intermittent or continuous (Wangdee, 2014). A statistically significant improvement of both degrees of pain and life quality, in treatment group, were found after 4 weeks of the administration of PCSO-524. The results are in accordance with the study in human. Zawadzki et al., (2013) had found that PCSO-524 effectively cure the disease within 4 weeks by using visual analogue scale (VAS) for pain determination. However, as mentioned earlier, the owner opinions on dog's life quality had become a better improvement since the 2<sup>nd</sup> week.

After administration of PCSO-524 at the recommended dose for 16 weeks, there was no significant change in CBCs, liver and kidney function values. In accordance with the previous studies, there are no change in these parameters when treated with the supplement for twenty-four weeks (Soontornvipart et al., 2015). The experiment of Jamikorn and Yibchok-anun, (2014) had observed the same results, even though the dogs were treated with tenfold of the recommended dosage in healthy Beagles for eight weeks. This study has also reported that some of the mean values of ALT in both treatment and control groups are higher than the normal range. However, mild increasing of these liver function enzymes could be found in aging patients without any observable changes in feed intake, clinical signs and behaviors.

From the ultrasonographic findings, normal articular cartilage is characterized as thin anechoic band with sharp margin. The heterogeneous or hypoechoic appearance with irregular surface of articular cartilage have been found at the medial femoral ridge. In this study, all MPL stifles were particularly noticed of the cartilage erosions on the proximal part of medial femoral ridge. Of 42 MPL stifles, 18 stifles (42.8 %) found the cartilage erosions on the distal part of the medial femoral condyle. There were no pathological findings on the lateral ridge of femoral condyle. In agreement with the previous studies, the most area of eroded cartilage on femoral condyle were found on the medial trochlear ridge performing by gross examination (Alam et al., 2011; Boonsri et al., 2016; Jahrupatrakorn, 2017). Cartilage lesions are subsequently appeared due to the luxation of patella (Daems et al., 2009; Vollnberg et al., 2012). When stifle

is extended, the patella slides proximally on the trochlear sulcus and glides out of the medial trochlear ridge. During in and out luxation of patella, force is occurred between articular patellar surface and medial ridge of femoral trochlear. Recently, there is high prevalence of patellar erosion found in dogs and humans with MPL. The eroded lesions were mostly presented on the articular surface of the patella (Nomura and Inoue, 2005; Daems et al., 2009; Vollnberg et al., 2012). However, the lesion on the articular surface of the patella could not be observed in this study due to the limitation of US.

According to analyzed data, the ultrasonographic score in treatment group found significant improvement after 4 weeks of PCSO-524 administration. Additionally, significant difference of ultrasonographic score was found between control and treatment groups after 4 weeks of the treatment. Synovial fluid and articular cartilage score of proximo-medial femoral condyle were also statistically significant difference after 4 weeks post-treatment. The disorder of synovial fluid always occurs in osteoarthritic dogs. It impairs in balancing between synthesis and degradation of articular cartilage constituents. This leads to articular cartilage destruction, underlying bone remodeling, osteophytes formation, and varying degrees of synovitis (Johnston, 1997; Fujita et al., 2005). A reduction in degrees of synovial inflammation after treating with PCSO-524 has been reported in many studies (Mongkon and Soontornvipart, 2012; Soontornvipart et al., 2015). Mongkon and Soontornvipart, (2012) reported that serum IL-1 $\beta$  level, a popular biomarker to detect joint inflammation, had been slowly declined during 14 days. Similar to the study of Soontornvipart et al., (2015), level of OA biomarkers (chondroitin sulfate WF6 epitope) was lower within 14 days. The articular cartilage score of distal aspect of medial femoral ridge was found significant difference in treatment group after twelve weeks of PCCSO-524 administration. This is not in accordance with the result in the proximal aspect of medial femoral ridge. Eroded cartilage on distal portion of medial femoral condyle was found in 18 stifles (42.8 %) of all MPL stifles. The lower quantity makes the results to be not statistically significance at the same week as the results of the proximal part.



All dogs were evaluated for cartilage thickness of femoral condyle. The position in cartilage measurement composed of 3 points, involving medial, middle and lateral. After 16 weeks of treatment, there were no change in thickness of the cartilage when comparison to pre-treatment. On the contrary, in surgical-induced OA model in rats have been found significant histological changes of cartilage thinning between 6 and 10 weeks post-surgery (Hayami et al., 2006). However, the difference of species is accountable. It have been taken more than a year to develop cartilage degradation and osteophyte formation in dog model, while disease progresses at a faster rate in the rat models. According to the results, this study revealed that the average of cartilage thickness of femoral condyles in Pomeranian and Chihuahua dogs with MPL was  $0.223 \pm 0.092$  mm. The average of cartilage thickness of distal femoral condyle at medial, middle and lateral areas were  $0.225 \pm 0.051$ ,  $0.227 \pm 0.112$  and  $0.228 \pm 0.102$  mm, respectively.

The clinical evaluations of the articular cartilage destruction in OA patients can be detected from magnetic resonance imaging (MRI), computed tomography (CT) and arthroscopy. These techniques are invasive, expensive and radioactively dangerous especially to operators. Our results reviewed that US can be used for diagnosis and monitoring of the cartilage destruction. However, the error in sonographic evaluation can be occurred. The scanning techniques and normal sonographic anatomy of the stifle joint should be learned and understood. To diminish misinterpretation, using bone prominence as landmark and positioning of the patients are mainly conducted. Moreover, preparation of the patients, restraint patients by the assistance and appropriated setting of the US should be performed.

In ultrasonographic evaluation, the bone surface of medial femoral condyle showed no significant change between before and after treatment in both groups. From the ultrasonographic findings, all MPL dogs were found subchondral lesions on the medial femoral condyle. It presented as irregular hyperechoic lining with interrupted points.

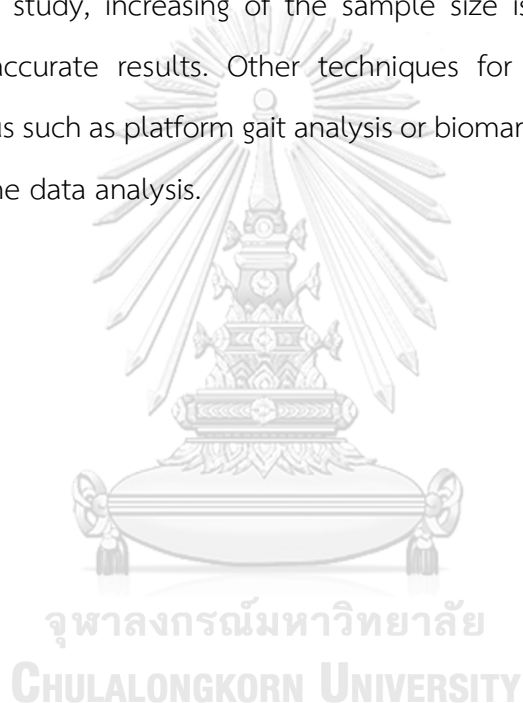
After twelve weeks of the treatment, the radiographic OA scores in control group were significant progression while a significant improvement were observed in treatment group. Mongkon and Soontornvipart, (2012) have reported that dogs with hip, shoulder and stifle OA were little improvement in radiographic OA evaluation after administration of PCSO-524 for 12 weeks. This controversy can be explained by MPL model of this study. MPL dogs always encounter with repetitive luxation of patella, which contributes to abnormal joint motion and cartilage loading. The instability of joint is subsequently developed to OA (Roy et al., 1992). Therefore, MPL is identified as a low grade of OA progression.

The study revealed that ultrasonographic findings of the stifle joint have some advantages over the radiographs. It showed the abnormal characteristics of soft tissue and bone structures in the joints involve synovitis, articular cartilage lesion and bone surface destruction. In medial patellar luxation, mild degree of synovitis are always found, which is difficult to detect from the radiographs. In the experiment of Ramírez-Flores et al., (2017) reported that US gives a better result than the radiography when usage for diagnosis of joint effusion. Ultrasonography has been suggested to investigate the lesions of early OA joints. Nevertheless, the estimation of the articular lesion using US is a novel method in dogs. There is also limit in the information and techniques of US in dog stifles. To archive this technique, a knowledge of the joint anatomy, an angle of the stifles, an angle of the ultrasound probe should be carefully understood.

In conclusion, this present study demonstrated that PCSO-524 has an effectiveness of cartilage protection in dogs with OA secondary to MPL. The cartilage lesion and synovial fluid were improved within 4 weeks of PCSO-524 administration. After 2 weeks of the treatment, a better gaiting of dogs were observed by their owner with satisfaction. The radiographic OA evaluation were improved after 12 weeks of the treatment. In MPL dogs, the surgical correction is suggested, otherwise it probably lead to the development of progressive OA. MPL induces joint instability, which can leads to cranial cruciate ligament rupture (CCLR), meniscal tear and finally to chronic OA.

Dogs with MPL are reluctant to stride with the stifle joints, they compensated by overusing of hip and hock joints, which result in hip joint luxation. Unexpectedly, none of these secondary abnormalities were found during four months of the study. However, Pomeranian and Chihuahua over five years old with MPL, which cannot admit the surgical procedures should be recommended for other managements. They were suggested for training quadriceps muscle and environmental managements with administration of PCSO-524 for better quality of life.

For further study, increasing of the sample size is recommended for more significance and accurate results. Other techniques for determining of pain and inflammatory status such as platform gait analysis or biomarkers, are suggested to bring more reliable of the data analysis.



## REFERENCES

- Alam M, Lee H, Kim M and Kim N 2011. Surgical model of osteoarthritis secondary to medial patellar luxation in dogs. *Vet Med (Praha)*. 56(3): 123-130.
- Alam M, Lee J, Kang H, Kim I, Park S, Lee K and Kim N 2007. Frequency and distribution of patellar luxation in dogs. *Vet Comp Orthop Traumatol*. 20(01): 59-64.
- Arnault F, Cauvin E, Viguier E, Kraft E, Sonet J and Carozzo C 2009. Diagnostic value of ultrasonography to assess stifle lesions in dogs after cranial cruciate ligament rupture: 13 cases. *Vet Comp Orthop Traumatol*. 22(06): 479-485.
- Bell A, Helm J and Reid J 2014. Veterinarians' attitudes to chronic pain in dogs. *Vet Rec*. 175(17): 428.
- Boonsri B, Pradit W, Soontornvipart K, Terdsak Y, Chomdej S, Ongchai S and Nganvongpanit K 2016. Prevalence of Cartilage Erosion in Canine Patellar Luxation and Gene Expression in Affected Joints. *Kafkas Universitesi Veteriner Fakultesi Dergisi*. 22(4).
- Brinker WO, Piermattei, D.L., Flo, G.L. 1997. Handbook of Small Animal Orthopedics and Fracture Repair. In: The stifle joint. Ed. Saunders, Philadelphia.
- Burnett BP, Levy R and Cole BJ 2006. Metabolic mechanisms in the pathogenesis of osteoarthritis. A review. *J Knee Surg*. 19(3): 191-197.
- Chappard C, Peyrin F, Bonnassie A, Lemineur G, Brunet-Imbault B, Lespessailles E and Benhamou C-L 2006. Subchondral bone micro-architectural alterations in osteoarthritis: a synchrotron micro-computed tomography study. *Osteoarthritis Cartilage*. 14(3): 215-223.
- Cleeland CS 1990. Assessment of pain in cancer. *Adv Pain Res Ther*. 16: 47-55.
- Cleeland CS 2006. The measurement of pain from metastatic bone disease: capturing the patient's experience. *Clin Cancer Res*. 12(20): 6236s-6242s.
- Curtis CL, Hughes CE, Flannery CR, Little CB, Harwood JL and Caterson B 2000. n-3 fatty acids specifically modulate catabolic factors involved in articular cartilage degradation. *J Biol Chem*. 275(2): 721-724.

- Curtis CL, Rees SG, Cramp J, Flannery CR, Hughes CE, Little CB, Williams R, Wilson C, Dent CM and Harwood JL 2002. Effects of n-3 fatty acids on cartilage metabolism. *Proc Nutr Soc.* 61(3): 381-389.
- Daems R, Janssens L and Béosier Y 2009. Grossly apparent cartilage erosion of the patellar articular surface in dogs with congenital medial patellar luxation. *Vet Comp Orthop Traumatol.* 22(3): 222-224.
- Frost-Christensen L, Mastbergen S, Vianen M, Hartog A, DeGroot J, Voorhout G, van Wees A, Lafeber F and Hazewinkel H 2008. Degeneration, inflammation, regeneration, and pain/disability in dogs following destabilization or articular cartilage grooving of the stifle joint. *Osteoarthritis Cartilage.* 16(11): 1327-1335.
- Fujita Y, Hara Y, Nezu Y, Yamaguchi S, Schulz KS and Tagawa M 2005. Direct and indirect markers of cartilage metabolism in synovial fluid obtained from dogs with hip dysplasia and correlation with clinical and radiographic variables. *Am J Vet Res.* 66(12): 2028-2033.
- Gibson R, Gibson S, Conway V and Chappell D 1980. Perna canaliculus in the treatment of arthritis. *The Practitioner.* 224(1347): 955-960.
- Gnudi G and Bertoni G 2001. Echographic examination of the stifle joint affected by cranial cruciate ligament rupture in the dog. *Veterinary Radiology & Ultrasound.* 42(3): 266-270.
- Goranov N, Paskalev M and Kanakov D 2013. Radiological and Ultrasound Imaging Scores in Experimental Sodium Monoiodoacetate Model of Knee Osteoarthritis in Dogs. *Istanbul Üniversitesi Veteriner Fakültesi Dergisi.* 39(1): 67-75.
- Hayami T, Pickarski M, Zhuo Y, Wesolowski GA, Rodan GA and Duong LT 2006. Characterization of articular cartilage and subchondral bone changes in the rat anterior cruciate ligament transection and meniscectomized models of osteoarthritis. *Bone.* 38(2): 234-243.
- Hayes A, Boudrieau R and Hungerford L 1994. Frequency and distribution of medial and lateral patellar luxation in dogs: 124 cases (1982-1992). *J Am Vet Med Assoc.* 205(5): 716-720.

- Henrotin Y, Lambert C, Couchourel D, Ripoll C and Chiotelli E 2011. Nutraceuticals: do they represent a new era in the management of osteoarthritis?—a narrative review from the lessons taken with five products. *Osteoarthritis Cartilage*. 19(1): 1-21.
- Hulse D 1981. Pathophysiology and management of medial patellar luxation in the dog. *Veterinary medicine, small animal clinician: VM, SAC*. 76(1): 43.
- Impellizeri JA, Tetrack MA and Muir P 2000. Effect of weight reduction on clinical signs of lameness in dogs with hip osteoarthritis. *J Am Vet Med Assoc*. 216(7): 1089-1091.
- Innes J, Costello M, Barr F, Rudolf H and Barr A 2004. Radiographic progression of osteoarthritis of the canine stifle joint: a prospective study. *Veterinary Radiology & Ultrasound*. 45(2): 143-148.
- Jahrupatrakorn S 2017. INTRA-ARTICULAR CHARACTERISTICS OF DOGS WITH MEDIAL PATELLAR LUXATION. Chulalongkorn University.
- Jain R and Johar A 2018. To evaluate the role of high resolution ultrasonography in diagnosis of knee osteoarthritis. *International Journal of Orthopaedics*. 4(1): 69-76.
- Jamikorn U and Yibchok-anun S 2014. Effects of Dietary Polyunsaturated Fatty Acid Supplement on Healthy Beagle Dogs. *The Thai Journal of Veterinary Medicine*. 44(4): 505-511.
- Johnston SA 1997. Osteoarthritis: joint anatomy, physiology, and pathobiology. *Veterinary Clinics: Small Animal Practice*. 27(4): 699-723.
- Kalra EK 2003. Nutraceutical-definition and introduction. *Aaps Pharmsci*. 5(3): 27-28.
- Karim Z, Wakefield R, Quinn M, Conaghan P, Brown A, Veale D, Connor PO, Reece R and Emery P 2004. Validation and reproducibility of ultrasonography in the detection of synovitis in the knee: a comparison with arthroscopy and clinical examination. *Arthritis & Rheumatism: Official Journal of the American College of Rheumatology*. 50(2): 387-394.
- Keen HI, Wakefield RJ and Conaghan PG 2009. A systematic review of ultrasonography in osteoarthritis. *Ann Rheum Dis*. 68(5): 611-619.
- Kramer M, Stengel H, Gerwing M, Schimke Et and Sheppard C 1999. Sonography of the canine stifle. *Veterinary Radiology & Ultrasound*. 40(3): 282-293.

- Kwananocha I, Vijarnsorn M, Kashemsant N and Lekcharoensuk C 2016. Effectiveness of disease modifying osteoarthritis agents and carprofen for treatment of canine osteoarthritis. *The Thai Journal of Veterinary Medicine*. 46(3): 363.
- Laflamme D 1997. Development and validation of a body condition score system for dogs.: a clinical tool. *Canine Pract*. 22: 10-15.
- Lau CS, Chiu P, Chu E, Cheng I, Tang WM, Man R and Halpern G 2004. Treatment of knee osteoarthritis with Lyprinol®, lipid extract of the green-lipped mussel-A double-blind placebo-controlled study. *Progress in Nutrition*.
- Martinez SA 1997. Congenital conditions that lead to osteoarthritis in the dog. *Vet Clin N Am: Small Anim Pract*. 27(4): 735-758.
- McPhee S, Hodges L, Wright P, Wynne P, Kalafatis N, Harney D and Macrides T 2007. Anti-cyclooxygenase effects of lipid extracts from the New Zealand green-lipped mussel, *Perna canaliculus*. *Comparative Biochemistry and Physiology Part B: Biochemistry and Molecular Biology*. 146(3): 346-356.
- Möller I, Bong D, Naredo E, Filippucci E, Carrasco I, Moragues C and Iagnocco A 2008. Ultrasound in the study and monitoring of osteoarthritis. *Osteoarthritis Cartilage*. 16: S4-S7.
- Mongkon N and Soontornvipart K 2012. Preliminary study of the clinical outcome of using PCSO-524 polyunsaturated fatty acid compound in the treatment of canine osteoarthritis and degenerative spinal diseases. *Thai J Vet Med*. 42(3): 311-317.
- Nasri H, Baradaran A, Shirzad H and Rafieian-Kopaei M 2014. New concepts in nutraceuticals as alternative for pharmaceuticals. *Int J Prev Med*. 5(12): 1487.
- Ness M, Abercromby R, May C, Turner B and Carmichael S 1996. Survey of orthopaedic conditions in small animal veterinary practice in Britain. *Veterinary and comparative orthopaedics and traumatology: VCOT*.
- Nishitani K, Kobayashi M, Kuroki H, Mori K, Shirai T, Satake T, Nakamura S, Arai R, Nakagawa Y and Nakamura T 2014. Ultrasound can detect macroscopically undetectable changes in osteoarthritis reflecting the superficial histological and biochemical degeneration: ex vivo study of rabbit and human cartilage. *PLoS One*. 9(2): e89484.

- Nomura E and Inoue M 2005. Second-look arthroscopy of cartilage changes of the patellofemoral joint, especially the patella, following acute and recurrent patellar dislocation. *Osteoarthritis Cartilage*. 13(11): 1029-1036.
- Okano T, Filippucci E, Di Carlo M, Draghessi A, Carotti M, Salaffi F, Wright G and Grassi W 2016. Ultrasonographic evaluation of joint damage in knee osteoarthritis: feature-specific comparisons with conventional radiography. *Rheumatology*. 55(11): 2040-2049.
- Penninck D and d'Anjou M-A 2015. Atlas of small animal ultrasonography. In: 2nd ed. John Wiley & Sons, New York, United States. 512-516.
- Piermattei DL, Flo GL and Decamp CE 2006. Brinker, Piermattei, and Flo's handbook of small animal orthopedics and fracture repair. In: 4th ed. Saunders. 562-632.
- Putman R 1968. Patellar luxation in the dog. presented to the faculty of graduate studies, Ontario, Canada, University of Guelph.
- Ramírez-Flores GI, Del Angel-Caraza J, Quijano-Hernández IA, Hulse DA, Beale BS and Victoria-Mora JM 2017. Correlation between osteoarthritic changes in the stifle joint in dogs and the results of orthopedic, radiographic, ultrasonographic and arthroscopic examinations. *Vet Res Commun*. 41(2): 129-137.
- Reed AL, Payne JT and Constantinescu GM 1995. Ultrasonographic anatomy of the normal canine stifle. *Veterinary Radiology & Ultrasound*. 36(4): 315-321.
- Roush JK 1993. Canine patellar luxation. *Vet Clin N Am: Small Anim Pract*. 23(4): 855-868.
- Roy RG, Wallace LJ, Johnston GR and Wickstrom SL 1992. A retrospective evaluation of stifle osteoarthritis in dogs with bilateral medial patellar luxation and unilateral surgical repair. *Vet Surg*. 21(6): 475-479.
- Sinclair AJ, Murphy K and Li D 2000. Marine lipids: overview" news insights and lipid composition of Lyprinol". *Allerg Immunol (Paris)*. 32(7): 261-271.
- Singleton W 1969. The surgical correction of stifle deformities in the dog. *J Small Anim Pract*. 10(2): 59-69.
- Slatter DH 2003. Textbook of small animal surgery. Vol 1. In: Elsevier health sciences.
- Soontornvipart K, Mongkhon N, Nganvongpanit K and Kongtawelert P 2015. Effect of PCSO-524 on OA biomarkers and weight-bearing properties in canine shoulder



- and coxofemoral osteoarthritis. *The Thai Journal of Veterinary Medicine*. 45(2): 157.
- Soontornvipart K, Wangdee C, Kalpravidh M, Brahmasa A, Sarikaputi M, Temwichitr J, Lavrijsen I, Theyse L, Leegwater P and Hazewinkel H 2013. Incidence and genetic aspects of patellar luxation in Pomeranian dogs in Thailand. *The Veterinary Journal*. 196(1): 122-125.
- Stammers T, Sibbald B and Freeling P 1992. Efficacy of cod liver oil as an adjunct to non-steroidal anti-inflammatory drug treatment in the management of osteoarthritis in general practice. *Ann Rheum Dis*. 51(1): 128-129.
- Tarhan S and Unlu Z 2003. Magnetic resonance imaging and ultrasonographic evaluation of the patients with knee osteoarthritis: a comparative study. *Clin Rheumatol*. 22(3): 181-188.
- Tobias KM and Johnston SA 2012. *Veterinary Surgery Small Animal*. Vol 2. In: Elsevier Inc., USA. 2128.
- Treschow A, Hodges L, Wright P, Wynne P, Kalafatis N and Macrides T 2007. Novel anti-inflammatory  $\omega$ -3 PUFAs from the New Zealand green-lipped mussel, *Perna canaliculus*. *Comparative Biochemistry and Physiology Part B: Biochemistry and Molecular Biology*. 147(4): 645-656.
- Trotter E 1980. Medial patellar luxation in the dog. *Compend Contin Educ Pract Vet*. 2: 58-67.
- Vandeweerd JM, Coisson C, Clegg P, Cambier C, Pierson A, Hontoir F, Saegerman C, Gustin P and Buczinski S 2012. Systematic review of efficacy of nutraceuticals to alleviate clinical signs of osteoarthritis. *J Vet Intern Med*. 26(3): 448-456.
- Vollnberg B, Koehlitz T, Jung T, Scheffler S, Hoburg A, Khandker D, Hamm B, Wiener E and Diederichs G 2012. Prevalence of cartilage lesions and early osteoarthritis in patients with patellar dislocation. *Eur Radiol*. 22(11): 2347-2356.
- Wangdee C 2014. Prevalence, genetics, and surgical treatment of patellar luxation in purebred dogs. University Utrecht.
- Wangdee C, Soontornvipart K and Chuthatep S 2005. The study of the canine patellar luxation surgical treatments. *J. Thai Vet. Pract*. 17(4): 13-25.

- Wessely M, Brüschwein A and Schnabl-Feichter E 2017. Evaluation of Intra-and Inter-observer Measurement Variability of a Radiographic Stifle Osteoarthritis Scoring System in Dogs. *Vet Comp Orthop Traumatol.* 30(06): 377-384.
- Whitehouse M, Macrides T, Kalafatis N, Betts W, Haynes D and Broadbent J 1997. Anti-inflammatory activity of a lipid fraction (Lyprinol) from the NZ green-lipped mussel. *Inflammopharmacology.* 5(3): 237-246.
- Zawadzki M, Janosch C and Szechinski J 2013. Perna canaliculus lipid complex PCSO-524™ demonstrated pain relief for osteoarthritis patients benchmarked against fish oil, a randomized trial, without placebo control. *Mar Drugs.* 11(6): 1920-1935.



## VITA

NAME	Ratthanan Sathienbumrungkit
DATE OF BIRTH	17 March 1993
PLACE OF BIRTH	Bangkok, Thailand
INSTITUTIONS ATTENDED	Department of Veterinary Surgery, Chulalongkorn University
HOME ADDRESS	18/5 Life Boulevard Bangkok village, Nong Khaem sub-district, NongKhaem district, Bangkok 10160

