

11-1-2000

## Painless postpartum sterilization under localanesthesia for training physicians

W. Weerawetwat

Follow this and additional works at: <https://digital.car.chula.ac.th/clmjjournal>



Part of the [Medicine and Health Sciences Commons](#)

---

### Recommended Citation

Weerawetwat, W. (2000) "Painless postpartum sterilization under localanesthesia for training physicians," *Chulalongkorn Medical Journal*: Vol. 44: Iss. 11, Article 4.

Available at: <https://digital.car.chula.ac.th/clmjjournal/vol44/iss11/4>

This Article is brought to you for free and open access by the Chulalongkorn Journal Online (CUJO) at Chula Digital Collections. It has been accepted for inclusion in Chulalongkorn Medical Journal by an authorized editor of Chula Digital Collections. For more information, please contact [ChulaDC@car.chula.ac.th](mailto:ChulaDC@car.chula.ac.th).

## Painless postpartum sterilization under local anesthesia for training physicians

Waraporn Weerawetwat\*

Weerawetwat W. Painless postpartum sterilization under local anesthesia for training physicians. Chula Med J 2000 Nov; 44(11): 839 - 44

- Objective** : *To evaluate postpartum sterilization using a painless procedure with only local anesthesia performed by training physicians.*
- Setting** : *Department of Obstetrics and Gynecology, Phaholpolphayuhasena Hospital, Kanchanaburi province, Thailand.*
- Research design** : *Prospective Analytical Design*
- Patients** : *80 uncomplicated postpartum patients who did not want any more children, treated during January 1998 to December 1999,*
- Method** : *Pomeroy technique was performed after minilaparotomy using only local anesthesia. The abdominal wall was blocked with 2 % lidocaine 6 -10 cc. and the uterine tubes were bathed with 2 % lidocaine using different doses and times until the patient had no pain during tubal identification and resection was done. The patients were evaluated for pain experienced by observation of co-operative relaxation and an intraoperative and postoperative interview. Their satisfaction was also evaluated.*
- Result** : *Training physicians successfully performed painless postpartum TR using only local anesthesia without post-operative complications. The effective method was to use 5 cc. Lidocaine in tubal bath for 2 minutes long. The patients were satisfied with the procedure. All of them recovered immediately with no special nursing care.*

\*Department of Obstetrics and Gynecology, Phaholpolphayuhasena Hospital, Kanchanaburi Province, Thailand.

**Conclusion** : *Postpartum TR under only local anesthesia is a procedure that is inexpensive, safe, simple, and easily learned. Training physicians may appropriately be trained to perform this.*

**Key words** : *Painless postpartum sterilization, Only local anesthesia, Training physicians.*

Reprint request : Weerawetwat W. Department of Obstetrics and Gynecology,  
Phaholpolphayahasena Hospital, Kanchanaburi Province, Thailand.

Received for publication. March 15, 2000.

วราพร วีรเวทวัฒน์. การทำหมันหลังคลอดแบบไม่เจ็บสำหรับผู้ฝึกหัดทำหมันโดยใช้ยาชาเฉพาะที่อย่างเดียว. จุฬาลงกรณ์เวชสาร 2543 พ.ย; 44(11): 839 - 44

**วัตถุประสงค์** : เพื่อหาวิธีการใช้ยาชาเฉพาะที่เพียงอย่างเดียวสำหรับผู้ฝึกหัดทำหมันให้  
ทำหมันหญิงหลังคลอดโดยผู้ป่วยไม่รู้สึเจ็บ

**สถานที่ที่ทำการศึกษา** : หน่วยงานสูติ-นรีเวชกรรม โรงพยาบาลพลพหลพยุหเสนาฯ กาญจนบุรี

**รูปแบบการวิจัย** : การวิจัยเชิงวิเคราะห์แบบไปข้างหน้า

**ผู้ป่วยที่ได้ทำการศึกษา** : ผู้ป่วยช่วงระยะหลังคลอดที่มีบุตรเพียงพอแล้ว ระหว่างเดือนมกราคม  
พ.ศ. 2541 จนถึงเดือนธันวาคม พ.ศ. 2542 จำนวน 80 ราย

**วิธีการศึกษา-วัดผล** : ผู้ป่วยได้รับการทำหมันแบบ Pomeroy ผ่านแผลผ่าตัดขนาดเล็ก ใช้  
ยาชาเฉพาะที่เพียงอย่างเดียวโดยการฉีดยาชาที่ผนังหน้าท้องบริเวณที่จะ  
ผ่าตัดและพ่นยาชาเข้าบริเวณท่อมดลูก หายขนาดยาและระยะเวลาแช่ยา  
ที่ทำให้ผู้ป่วยไม่รู้สึเจ็บ ประเมินผลความรู้สึกและอาการของผู้ป่วยขณะ  
รับการผ่าตัด หลังผ่าตัด ตลอดจนสำรวจความพึงพอใจของผู้ป่วย

**ผลการศึกษา** : ฉีดยาชาที่ผนังหน้าท้องจำนวน 6 -10 ซีซี และใช้ยาชา 5 ซีซี พ่นแช่ท่อม  
ดลูกแต่ละข้างและแช่พักไว้ 2 นาที จึงทำการหาท่อมดลูกเพื่อทำผ่าตัด  
พบว่าผู้ป่วยไม่มีความรู้สึกเจ็บขณะรับการผ่าตัดโดยนักเรียนแพทย์หรือ  
แพทย์ฝึกหัด ไม่พบภาวะแทรกซ้อนใด ๆ จากการผ่าตัด ผู้ป่วยทุกคน  
พึงพอใจและสามารถทำกิจกรรมปกติของตนได้ทันทีหลังการผ่าตัด  
เสมือนไม่ได้ทำหมัน

**สรุป** : ผู้ฝึกหัดทำหมันสามารถทำหมันหลังคลอดด้วยการใช้ยาชาเฉพาะที่  
เพียงอย่างเดียวโดยผู้ป่วยไม่รู้สึเจ็บได้ เป็นวิธีที่สะดวก ปลอดภัย  
ประหยัด ง่ายต่อการเรียนรู้และเป็นสิ่งที่พึงพอใจแก่ผู้ป่วย

**คำสำคัญ** : ทำหมันหลังคลอดแบบไม่เจ็บ ยาชาเฉพาะที่อย่างเดียว ผู้ฝึกหัดทำ

Female sterilization, tubal resection (TR) requires an anesthetic method to relieve pain. Most complications, including death, from TR are caused by the anesthetic methods used.<sup>(1-4)</sup> TR under only local anesthesia has many advantages.<sup>(5, 6)</sup> It is relatively inexpensive, safe, and convenient for the patients, who experience rapid recovery after undergoing TR, without the need for special care.<sup>(6)</sup> Only experienced obstetricians have previously performed it effectively and correctly.<sup>(1-6)</sup> In rural areas, TR has been performed by less skilled service providers. And there were few medical personal who can effectively manage the post operative complications. This study was aimed to ascertain the suitability of painless postpartum TR using only local anesthesia being performed by inexperienced physicians. It was concluded that it should be a useful method of female sterilization particularly for the patients living in rural areas.

#### Patients and Method

The study was performed at the Department of Obstetric and Gynecology, Phaholpolphayusana Hospital, Thailand, during January 1998 to December 1999.

Eighty parturients were included into the study. All of them had no systemic diseases, no complications from labor, and no history of lidocaine allergy. Postpartum TR is usually done within 3 days after delivery.

All women were routinely prepared for TR by nothing per oral (NPO) on the morning of the operation day, shaved skin of the abdomen, and urinated before operation. Pomeroy technique was done by minilaparotomy under only local anesthesia. The sensation of

each woman was evaluated by observation of co-operative relaxation, intraoperative and postoperative interviewed. Severity of pain was estimated into 3 groups. "Mild pain" means that she felt a little bit pain and her abdomen was well relaxed. "Moderate pain" means the feeling of pain with slight bowel distention. "Severe pain" means markedly pain sensation with markedly bowel distention. The operative procedure can be described in the following steps.

Firstly, to completely relieve pain of the incision area, the whole thickness or layer by layer of the abdominal wall was blocked by injection of 2 % lidocaine 6 -10 cc., according to the operator. This step was performed in all subjects.

Secondly, to relieve pain during tubal identification and ligation. After minilaparotomy was done the uterus was exposed clearly from omentum and bowel. If there was abdominal fluid present, a gauze swab was applied to dry the adnexae. The adnexa was exposed clearly again by Army Navy retractor side by side when 2% lidocaine was sprayed through syringe with needle over it (as shown in Figure 1.) to make a pool of lidocaine bath around the tubes. Different amount of lidocaine was sprayed in each client and left for different duration before tubal identification and ligation. The amount of lidocaine used and the least time of tubal bath to make painless procedure for the clients were recorded. It was found that the least time used for tubal bath was 2 minutes. The amount of lidocaine used for effective tubal bath was 2 cc., when the author did TR. The procedure was also trained to training physicians (medical students, interns), but there were still some patients suffered from pain during TR. Thus a larger amount of lidocaine for tubal bath was tried by raising 1 cc. each

time when the subject felt pain until 5 cc. lidocaine resulted complete painless TR in all clients. The 2 group's subjects, 20 cases for each group that TR was done by training physicians were presented.

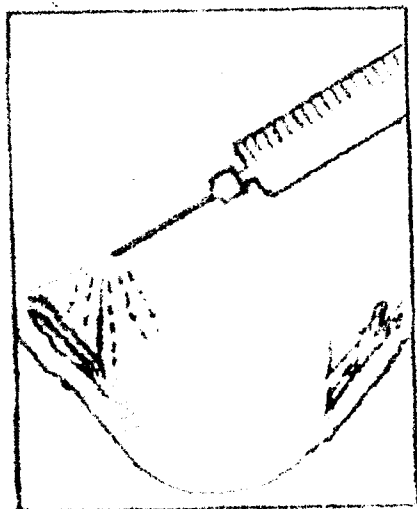


Figure 1. Lidocaine spray over the adnexa.

Group I: 2 cc. of 2 % lidocaine bath, used for 2 minutes.

Group II: 5 cc. of 2 % lidocaine bath, used for 2 minutes.

During the post-operative period, analgesic was supplied according to the patient 's requirement. The clients were interviewed and observed within 24 hours after TR.

### Results

Group I : 5 patients had no pain, 2 cases had severe pain, 10 cases had mild to moderate pain, and 3 cases had a feeling of pressure during tubal identification (40% painless).

Group II : No patients felt pain. 2 cases had a feeling of pressure during tubal identification (100 % painless).

To complete painless tubal identification and resection in all patients is to use 5 cc. of 2 % lidocaine tubal bath each side for 2 minutes. No complication was found in all studied cases. The patients recovered immediately after operation and needed no special nursing care and were able to care for their babies at once. The length of the hospital stay of the studied patients was the same as for those who did not undergo TR. All patients in group II were very satisfied with the procedure.

### Discussion

Anesthetics used for purpose of pain relief during postpartum TR include general anesthesia, total intravenous anesthesia, regional anesthesia, and neuroleptic analgesia with local anesthesia.<sup>(1,2,5-11)</sup> It is widely known that most of the complications from TR are caused by the anesthetic.<sup>(1-4)</sup> TR is also costly, requiring more nursing care after operation, and breast-feeding must be delayed when these techniques are used. TR under only local anesthesia is an inexpensive, safe, and simple method.<sup>(4-6)</sup> It can avoid the above problems, such as complications from the anesthetic used and anesthetic passing into the breast milk, and hospitalization time is also reduced.<sup>(12)</sup> On the other hand, it has been effective only when performed by experienced specialists.<sup>(1,6)</sup> The appropriate method of female sterilization for rural areas in developing countries should be able to be performed by less skilled service providers. There should be a high degree of effectiveness and safety, which is free from immediate complications and it should be easy to learn.<sup>(5)</sup> Thus, effective local anesthesia represent a good alternative.<sup>(1)</sup> Painless postpartum TR with only local anesthesia was accepted as satisfactory among

the clients. <sup>(6)</sup> Using local anesthesia to relieve pain at the incision wound is easily done. This report showed that even training physicians could perform painless postpartum TR, including uterine tube identification and ligation, by using 5 c.c. of a 2 % lidocaine tubal bath on each side for at least 2 minutes. Effectiveness of the procedure is up to clearly exposed the adnexa and dryness of the abdomen before lidocaine spray was done. The method can also be applied to post-abortal TR with a palpable uterus. The patients can return to their usual activity immediately after the operation, with no side – effects. It is a satisfactory procedure for the clients and will help give puerperal TR a non-terrible image.

### Conclusions

Training physicians are able to perform painless postpartum TR using only local anesthesia. The method is simple, inexpensive, safe, effective and easy to learn. Patients recover immediately after operation and needed no special nursing care. It is also a highly satisfactory procedure for the clients.

### Acknowledgement

I am thankful to Professor Nikorn Dusitsin for advising this report.

### References

1. Tantisarin A. Anesthetic Management in Female Sterilization. In: Intaraprasert S, ed. Population/ Family Planning And Contraceptive Technology: Bangkok: Khao fang Publication, 1992; 519-31
2. Cunningham FG, Mac Donald PC, Gant NF. Williams Obstetrics 20<sup>th</sup> Ed, Connecticut : Application & Lange, 1997: 1375 - 81
3. Female Sterilization. Patient update. Contraception Rep 1995 Mar; 6(1 Suppl): 1 - 2
4. Mechcatie E. Sterilization still No.1 surgical option. Obstet Gynecol News 1994 Aug; 29(15): 9
5. Dusitsin N. Specifications for new technologies for female sterilization for use in developing countries. Int J Gynecol Obstet 1995 Dec; 51 Suppl 1: S15 - 6
6. Weerawetwat W. Local Anesthetic Techniques for Postpartum Tubal Sterilization. Bull Dept Med Serv 1991 Sep; 16(9): 476 - 9
7. Leslie M. Sterilizing women. Visiting a minilap Conap in Nepal. Wiphn News 1995 Summer; 8: 1 - 2
8. Nisanian A. Outpatient minilaparotomy sterilization with local anesthesia. J Reprod Med 1990 Apr; 35(4): 380 - 3
9. Blumenthal PD. Laparoscopic sterilization in the supine position using the Ramathibodi uterine manipulator. Fertil Steril 1995 Jul; 64(1): 204 - 7
10. Srinil P. Comparative study of Meperidine and Diazepam with oral Glifanine added for pain relief in postpartum tubal sterilization. Khon Kaen Hosp Med J 1992; 16(1): 13 - 20
11. Reichert JA, Nagel LW, Solberg NS. Sterilization for family planning in a third world country. Minesota Med 1997 Jul; 80(7): 27 - 30
12. Sangare M, Drouf A, Traore B, Diadhion F. Tubal sterilization by minilaparotomy: 74 cases, Med D' Afrique Noire 1993; 40(8 - 9): 549 - 52