

12-1-2000

## Ovarian metastatic human chorionic gonadotropinproducing gastric carcinoma presenting asa primary ovarian tumor : A case report

S. Triratanachat

A. Vasurat

P. Trivijitsilp

S. Niruthisard

Follow this and additional works at: <https://digital.car.chula.ac.th/clmjournal>



Part of the [Medicine and Health Sciences Commons](#)

---

### Recommended Citation

Triratanachat, S.; Vasurat, A.; Trivijitsilp, P.; and Niruthisard, S. (2000) "Ovarian metastatic human chorionic gonadotropinproducing gastric carcinoma presenting asa primary ovarian tumor : A case report," *Chulalongkorn Medical Journal*: Vol. 44: Iss. 12, Article 6.

DOI: 10.58837/CHULA.CMJ.44.12.6

Available at: <https://digital.car.chula.ac.th/clmjournal/vol44/iss12/6>

This Case Report is brought to you for free and open access by the Chulalongkorn Journal Online (CUJO) at Chula Digital Collections. It has been accepted for inclusion in Chulalongkorn Medical Journal by an authorized editor of Chula Digital Collections. For more information, please contact [ChulaDC@car.chula.ac.th](mailto:ChulaDC@car.chula.ac.th).

## Ovarian metastatic human chorionic gonadotropin producing gastric carcinoma presenting as a primary ovarian tumor : A case report

Surang Triratanachai \* Apichai Vasurat \*

Prasert Trivijitsilp \* Somchai Niruthisard \*

Triratanachai S, Vasurat A, Trivijitsilp P, Niruthisard S. Ovarian metastatic human chorionic gonadotropin producing gastric carcinoma presenting as a primary ovarian tumor : A case report. Chula Med J 2000 Dec; 44(12): 939 - 48

*This report describes a case of ovarian metastatic hCG producing gastric carcinoma, a presenting firstly with a pelvic mass and rising serum  $\beta$  - hCG. The patient underwent total abdominal hysterectomy with bilateral salpingo-oophorectomy, partial omentectomy with pelvic and paraaortic lymph node sampling. Histopathological examination revealed Krukenberg tumor. The primary tumor was a poorly differentiated (signet-ring-cell type) gastric carcinoma with multiple bone metastases, detected by bone scan. The ovarian metastatic tumor was positive for  $\beta$ -hCG while the primary tumor yielded negative result. The patient did not receive any further treatment and has been lost to follow up since her discharge.*

**Key words:** Krukenberg tumor, hCG Producing gastric carcinoma, Ovarian metastatic carcinoma

Reprint request : Triratanachai S, Department of Obstetrics and Gynecology, Faculty of Medicine, Chulalongkorn University, Bangkok 10330, Thailand.

Received for publication. September 18, 2000.

สุรางค์ ตริรัตนชาติ, อภิชัย วสุรัตน์, ประเสริฐ ตริวิจิตรศิลป์, สมชัย นิรุตติศาสน์. มะเร็งกระเพาะอาหารชนิดที่สร้างฮอร์โมน hCG แพร่กระจายสู่รังไข่เลียนแบบเนื้องอกรังไข่ชนิดปฐมภูมิ: รายงานผู้ป่วย. จุฬาลงกรณ์เวชสาร 2543 ๖.๓; 44(12): 939 - 48

รายงานนี้นำเสนอ มะเร็งกระเพาะอาหารชนิดที่สร้างฮอร์โมน hCG และแพร่กระจายสู่รังไข่ทั้งสองข้าง โดยมีอาการแสดงนำคล้ายเนื้องอกของรังไข่ คนไข้ได้รับการรักษาด้วยการตัดมดลูก หลอดมดลูก รังไข่ทั้งสองข้างและ omentum บางส่วน ร่วมกับเลาะต่อมน้ำเหลืองบริเวณอุ้งเชิงกราน และหลอดเลือดแดงใหญ่ aorta ผลทางพยาธิวิทยาของชิ้นเนื้อจากรังไข่เป็น Krukenberg tumor จากการสืบค้นทางคลินิกพบว่ามะเร็งแพร่กระจายมาจากกระเพาะอาหาร ซึ่งแสดงลักษณะทางพยาธิวิทยาเป็นเนื้องอกชนิด signet-ring-cell และนอกจากนี้ยังพบว่าการแพร่กระจายไปที่กระดูกหลายแห่ง การย้อมชิ้นเนื้อพิเศษด้วยวิธี immunohistochemistry สำหรับ  $\beta$  - hCG ให้ผลบวกที่รังไข่ และผลลบที่กระเพาะอาหาร คนไข้ไม่ได้รับการรักษาเพิ่มเติมและไม่มาติดตามการรักษาอีกเลยภายหลังออกจากโรงพยาบาล

Human chorionic gonadotropin (hCG) and hCG-like substances have been detected in a variety of malignant tumors other than trophoblastic tumors.<sup>(1,2)</sup> Gastrointestinal tract tumors such as those of the stomach, liver and pancreas are known to produce hCG.<sup>(3)</sup> Three morphologic patterns are seen in gastric cancers that produce hCG, namely gastric choriocarcinoma, mixed trophoblast and adenocarcinoma, and pure adenocarcinoma. The most common of these patterns is that of pure adenocarcinoma. Vaitukaitis<sup>(4)</sup> reported that 23% of patients with adenocarcinoma of the stomach had an elevated serum b-hCG level.

We present the case of an hCG producing gastric adenocarcinoma with wide spread metastases, including both ovaries (the so called Krukenberg tumor).

### Case Report

A married 36 year old Thai female, G2P2 last 8 year, was referred to King Chulalongkorn Memorial Hospital in July 1999 with a pelvic mass and right pleural effusion. She had a regular menstrual cycle while using a combined oral contraceptive pill until 8 months before this admission, was the time of which her last menstrual period. The patient had thought that she was pregnant. Without any antenatal care, 6 months after her last menstrual period, she developed severe cough and excessive weight loss, with no fever or dyspnea. She was firstly investigated at Surin Provincial Hospital from which the significant laboratory data was as follows: sputum AFB negative, serum anti HIV negative, urine pregnancy test positive, chest X-ray : right pleural effusion, pelvic ultrasonography: large pelvic mass without evidence

of intrauterine pregnancy. Diagnostic thoracocentesis was performed which yielded a positive result for adenocarcinoma.

At admission findings were : body temperature 37 °C, pulse rate 96 / min – regular, blood pressure 100 / 70 mm Hg and respiratory rate 30 / min without cyanosis. Chest examination revealed decreased breath sounds in the right lung field, vocal resonance left > right, with no crepitation. The trachea was shifted to the left. The abdomen disclosed moderate distension with a pelvic mass, the upper border at 2 fingers breadth above the umbilicus. The mass exhibited hard consistency, irregular surface, no tenderness and was slightly movable. Pelvic examination revealed a left adnexal mass about 20 cm in its greatest dimension which was confirmed by transabdominal ultrasonography.

Laboratory examination gave the following data: blood group A<sup>+</sup>; complete blood count: hemoglobin 9.7 g/dl, hematocrit 29.1 %, leukocytes 20,830 cell/ml (lymphocytes 7.3 %, monocytes 4.9 %, granulocytes 84.6 %, eosinophils 3.2 %) and platelets 379,000/ml. Urinalysis was within normal limits. Blood chemistry : plasma glucose 118 mg/dl, BUN 14 mg/dl, Cr 0.7 mg/dl. Coagulation profile: prothrombin time 18.9 sec (12 sec), partial thromboplastin time 38.4 sec (36.5 sec). Liver function tests : total bilirubin 0.45 mg/dl, direct bilirubin 0.15 mg/dl, alkaline phosphatase 1,741 U/L, SGOT 96 U/L, SGPT 75 U/L. The serum value of hormones and tumor markers were as followings : b hCG 330 mIU/ml, AFP 1.4 IU/ml, CA 125 487.6 IU/L.

A laparotomy was performed and disclosed 2,000 cc of yellow ascitic fluid which showed a negative result upon cytologic study. Right and left

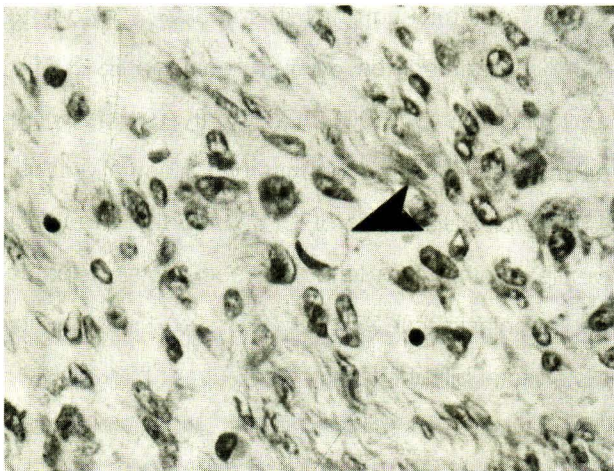
ovaries disclosed solid oval shaped masses, measuring 6 and 20 cm in the greatest dimension, respectively. The uterus was unremarkable. There were multiple omental nodules and multiple small peritoneal seedings in both paracolic gutters, the diaphragmatic surface, the dome of urinary bladder and the cul-de-sac. The right paraaortic and left pelvic lymph nodes were enlarged. A total abdominal hysterectomy with bilateral salpingo-oophorectomy, partial omentectomy, pelvic and paraaortic lymph node sampling was performed. Ovarian pathology revealed Krukenberg tumor (described below) which also involved omentum, peritoneum, pelvic and paraaortic lymph nodes. Postoperatively, intercostal continuous drainage was performed bilaterally due to massive pleural effusion. The primary site of the metastatic carcinoma was searched for. Gastroscopy displayed a large irregularly bordered gastric ulcer at the lesser curvature of which the histology report was poorly differentiated

adenocarcinoma, signet ring cell type (described below). Bone scans showed multiple bone metastases. Thus the final diagnosis was advanced gastric carcinoma with multiple organ metastases (bones, ovaries, omentum, etc.). Serum tumor marker levels at postoperative time were as followings : b hCG < 5 mIU/ml, CA125 61.7 IU/L. No adjuvant treatment was undertaken and unfortunately, she has been lost follow up after discharge.

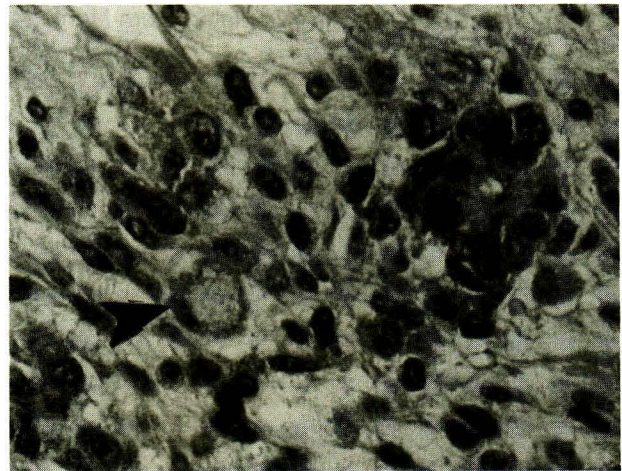
### Pathological findings

#### Ovaries

Grossly, right and left ovaries, weighing 31 and 1,000 gm, measuring 6x3x7.5 and 20x16x10 cm<sup>3</sup> respectively, contained oval well - circumscribed solid tumor with a lobulated smooth surface and firm consistency. The cut sections of both ovaries showed a solid pale yellow appearance with some small cysts and diffuse areas of purple, red discoloration.



**Figure 1.** Ovarian tumor : Demonstration of large round cell with clear cytoplasm and eccentric nucleus, so called signet-ring cell at the center. (H&E x400)



**Figure 2.** Ovarian tumor : One signet - ring cell is seen near the center and one small tubule at right lower part. The tubule is lined by columnar epithelium with large atypical hyperchromatic nuclei at base of cells. (H&E x100)



Microscopic examination of the tumor revealed round large cells with clear cytoplasm and eccentric atypical nuclei (so called signet-ring cells) strewn individually, in small clusters, or in large aggregates within a cellular ovarian stroma. Frequent variations from the above typical appearances including small glands, a prominent tubular architecture, tumor cells with granular eosinophilic cytoplasm singly or in clusters. Trabecular or large masses and abundant collagen formation were also noted. Occasionally small or large cysts lined by minimally atypical-appearing mucinous epithelium were demonstrated (Figure 1, 2). Immunohistochemical study for b-hCG disclosed diffuse moderate cytoplasmic staining in tumor cells (Figure 3)

#### Gastric biopsy

The histology showed antral and oxyntic mucosa with a diffuse infiltration of malignant cells,

characterized by pleomorphic eccentric nuclei and abundant vacuolated cytoplasm. Diffuse cryptitis and abscesses were noted (Figure 4). Immunohistochemical study for b-hCG disclosed a negative result.

#### Discussion

The ovaries provide fertile soil for metastases and are the most commonly involved organs in the female genital tract, regardless of the location of the primary tumor.<sup>(5)</sup> Frequency of metastatic tumors among all ovarian tumors is difficult to establish accurately because of a variety of reasons. Some studies have been based on autopsy findings, others on surgical specimens, and still others on both. In addition some series include silent metastases in prophylactic or therapeutic oophorectomy specimens and ovarian tumors which are associated with uterine carcinomas but not necessarily metastatic. Finally this frequency also varies from one country to another

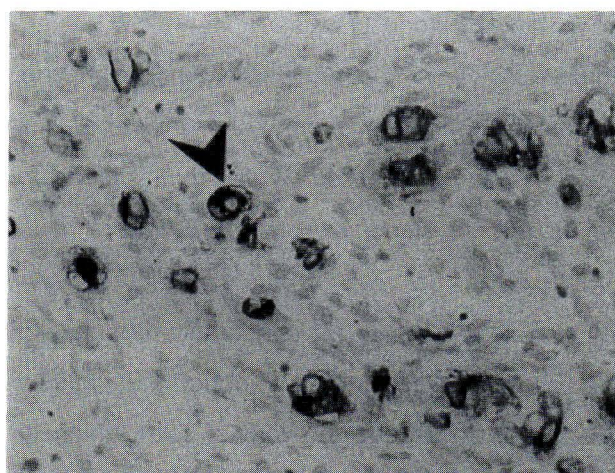


Figure 3. Demonstration of intracytoplasmic staining for b-hCG in ovarian tumor cells, labeled by immunohistochemistry ( $\beta$ -hCG x 400)

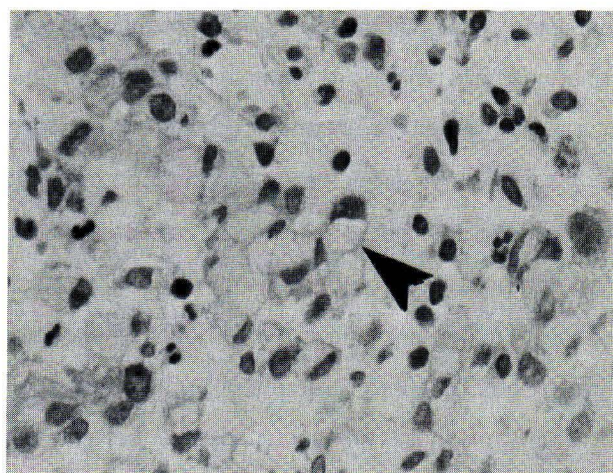


Figure 4. Signet-ring cells from gastric biopsy specimen (H&E x 400)

because of wide differences in the prevalence of the various cancers that are associated with high rates of ovarian spread.<sup>(6)</sup> Despite interseries variation based on geographical, temporal, and case selection, there is general agreement that the bulk of ovarian metastases are from the breast, gastrointestinal tract and female genital tract, these three together constituting up to 90 % of all cases.<sup>(5,7)</sup> In clinical practice, the frequency of possibility that a cancer found in the ovary on exploration of a pelvic or abdominal mass is a metastatic tumor is 6-7 %.<sup>(7)</sup> Overall, in cancer-associated deaths, ovarian metastases are likely to be macroscopically evident in approximately 6 % and histologically identifiable in an additional 6 %.<sup>(8)</sup> Ovarian secondaries are identified at autopsy in 15-50 % of women with gastric carcinoma.<sup>(9)</sup>

Krukenberg tumors account for 3-8 % of all carcinomas metastatic to the ovaries and most commonly originate in the gastrointestinal tract.<sup>(10)</sup> Accordingly, most ovarian metastases of gastric origin are Krukenberg tumor<sup>(11)</sup> which is a carcinoma containing a significant component of mucin-filled signet-ring cells typically lying within a cellular ovarian stroma. However, in current practice the term is applied to any metastatic signet-ring-cell adenocarcinoma whether or not the typical cellular stroma is present.<sup>(11)</sup> Microscopic findings in this case showed both areas typical of Krukenberg tumors and variations including small glands, tubular or trabecular architecture and large tumor masses. The source of Krukenberg tumor in over 70 % of the cases is gastric carcinoma, usually arising in the pylorus.<sup>(12,13)</sup> Carcinomas of the intestine, appendix, breast, urinary bladder, and cervix are the primary tumors in the remaining cases, in an estimated descending order of frequency.<sup>(11)</sup> Gastric signet-ring

cell carcinomas metastasize to the ovary more than twice as often as intestine-type carcinomas of the stomach.<sup>(9)</sup>

The average age of patients with Krukenberg tumor is about 45 years, it is the most common form of ovarian metastatic carcinoma in young women, often found in the fourth decade and occasionally in the third decade<sup>(11)</sup> as in the present case.

Human chorionic gonadotropin (hCG) and hCG-like substances have been detected in a variety of malignant tumors other than trophoblastic tumors.<sup>(1,2)</sup> A number of solid tumor including lung<sup>(14-17)</sup>, liver<sup>(3,18,19)</sup>, adrenal<sup>(20)</sup>, stomach<sup>(3,21)</sup>, prostate<sup>(22)</sup>, breast<sup>(23)</sup>, kidney<sup>(24,25)</sup>, pancreas<sup>(3)</sup> and others have been shown to produce gonadotropin or its subunits. However, these tumors do not necessarily have conspicuous trophoblastic elements.<sup>(26,27)</sup> A high frequency of ectopic hCG production (5.5 %) in nontrophoblastic neoplasms<sup>(28)</sup> was found in patients with carcinomas of stomach, liver, pancreas, breast, multiple myeloma and malignant melanoma.<sup>(28)</sup> Most patients in this group had only modest levels of hCG.<sup>(28,29)</sup> However, high levels of this hormone (180-800 mIU/ml) were found in some patients, all of whom had definite evidence of widespread metastases.<sup>(30)</sup> In gastrointestinal tract tumors, the prevalence of ectopic hCG secretion is as followings: pancreatic tumors 33%<sup>(31)</sup>, gastric carcinomas 10-30 %<sup>(26,28,31-34)</sup> and hepatomas 17 %.<sup>(31)</sup> Interestingly, Vaitukaitis JL<sup>(31)</sup> reported that patients with adenocarcinomas of the stomach had the highest circulating levels of hCG which may be as high as those observed in the first trimester of pregnancy.<sup>(35)</sup> Regarding location of gastric carcinoma, Manabe et al<sup>(3)</sup> found that gastric carcinomas located in the antrum-pylorus and the cardia were more frequently

associated with hCG production. In this case, a malignant ulcer existed at the lesser curvature of the body of the stomach.

The incidence of tumor cells positive for  $\beta$ -subunits of hCG, detected by immunohistochemical techniques in the gastric carcinomas is as follows: overall 32%, advanced stages 30%, and early stages 40%. Although of all histologic type of gastric carcinomas, signet-ring cell type disclosed the highest incidence of positivity (66.7%)<sup>(3)</sup>, in this reported case it showed a negative result for the  $\beta$ -subunit of hCG in the primary tumor. Many factors<sup>(36)</sup> may complicate the relationships between serum levels, tumor contents, and numbers of positively stained tumor cells. First, the serum level may be influenced by the whole tumor volume in vivo and the degree of release from the tumor mass. Second, the tumor contents may represent only the storage capacity of a specific tumor area examined. Third, although immunohistochemical positivity confirms the all storage of a particular substance, its negativity does not invariably exclude the possibility of production by negatively stained cells. Some data<sup>(37)</sup> suggest that the substance produced is not stored in cells in sufficient amounts to render it identifiable by immunohistochemical techniques, while loss of a majority of antigenic sites might occur during the preparation of immunohistochemical tissue sections. Fourth, there is the possibility that some micro-environmental factors of metastatic tissue might accentuate the weak capacity of hCG production of the original gastric carcinoma cells.<sup>(27)</sup> In this case, even though the primary tumor disclosed negative immunohistochemical staining for  $\beta$ -hCG, after debulking of the majority of the tumor mass in the

pelvis, serum  $\beta$ -hCG was significantly decreased.

Yonemura Y, et al<sup>(38)</sup> reported that serum and tissue hCG positive rates were significantly higher for patients with bone metastases than those without bone metastases. They also concluded that the measurement of the tissue and serum hCG in patients with gastric carcinoma could be of extreme value in the search for bone metastases in gastric carcinoma. In accordance, in this case it was found that there were multiple bone metastases. In addition, Ito and Tahara<sup>(34)</sup> found that patients with hCG-positive primary tumors tended to have a worse prognosis than those with negative results, although the difference was not statistically significant.

Interestingly, slightly increased blood levels of this hormone have been found in less than 10 % of patients with inflammatory-bowel disease, gastric or duodenal ulcers and cirrhosis.<sup>(1)</sup> Consequently, if one can exclude those disorders in non pregnant patients with circulating levels of hCG higher than 5 mIU/ml, it is extremely likely that a tumor is present. Unfortunately this knowledge provides no information about the location of the tumor.<sup>(1)</sup>

## References

1. Vaitukaitis JL, Ross GT, Braustein GD, Rayford PL. Gonadotropins and their subunits: basic and clinical studies. *Recent Prog Horm Res* 1976; 32: 289-331
2. Vaitukaitis JL. Immunologic and physical characterization of human chorionic gonadotropin (hCG) secreted by tumors. *J Clin Endocrinol Metab* 1973 Oct; 37(4):505-14
3. Manabe T, Adachi M, Hirao K. Human chorionic gonadotropin in normal, inflammatory and



- carcinomatous gastric tissue. *Gastroenterology* 1985 Dec; 89(6): 1319 - 25
4. Vaitukaitis JL. Secretion of human chorionic gonadotropin by tumor. In : Lehmann FG, ed. *Carcino-Embryonic Proteins; Chemistry, Biology, Clinical Applications*. Vol 1. New York: Elsevier/North-Holland, 1979: 447 - 56
  5. Mazur MT, Hsueh S, Gersell DJ. Metastases to the female genital tract. Analysis of 325 cases. *Cancer* 1984 May 1; 53(9): 1978 - 84
  6. Young RH, Scully RE. Metastatic tumors of the ovary. In : Kurman RJ, ed. *Blaustein's Pathology of the Female Genital Tract*. 4 th ed. New York: Springer-Verlag, 1994: 939 - 74
  7. Ulbright TM, Roth LM, Stehman FB. Secondary ovarian neoplasia. A clinicopathological study of 35 cases. *Cancer* 1984 Mar 1; 23(5): 1164 - 74
  8. Russell P, Farnsworth A. Tumors metastatic to the ovaries-introduction, metastases from the female genital tract and breasts. In : *Surgical Pathology of the Ovaries*. 2 nd ed. New York: Churchill Livingstone, 1997: 597 - 608
  9. Duarte I, Llanos O. Patterns of metastases in intestinal and diffuse types of carcinoma of the stomach. *Human Pathol* 1981 Mar; 12(3): 237 - 42
  10. Metz SA, Karnei RF, Veach SR, Hoskins WJ. Krukenberg carcinoma of the ovary with bone marrow involvement. Report of two cases and review of the literature. *Obstet Gynecol* 1980 Jan; 55(1): 99 - 104
  11. Scully RE, Young RH, Clement PB. Tumors of the Ovary, Maldeveloped Gonads, Fallopian Tube, and Broad ligament. Washington, D.C: Armed Forces Institute of Pathology, 1998: 1-527
  12. Leffell JM Jr, Masson JC, Dockerty MB. Krukenberg's tumors. A survey of forty-four cases. *Ann Surg* 1942 Jan; 115 (1): 102 - 13
  13. Yakushiji M, Tazaki T, Nishimura H, Kato T. Krukenberg tumors of the ovary: a clinico-pathologic analysis of 112 cases. *Acta Obstet Gynecol Jpn* 1987 Mar; 39(3): 479 - 85
  14. Regan JF, Cremin JH. Chorioepithelioma of the stomach. *Am J Surg* 1960 Aug; 100(2): 224-33
  15. Cottrell JC, Becker KL, Matthews MJ, Moore C. The histology of gonadotropin-secreting bronchogenic carcinoma. *Am J Clin Pathol* 1969 Dec; 52(6): 720 - 5
  16. Dailey JE, Marcuse PM. Gonadotropin secreting giant cell carcinoma of the lung. *Cancer* 1969 Aug; 24(2): 388 - 96
  17. Faiman C, Colwell JA, Ryan RJ, Hershman JM, Shields TW. Gonadotropin secreting from a bronchogenic carcinoma. Demonstration by radioimmunoassay. *N Engl J Med* 1967 Dec 28; 277(26): 1395 - 9
  18. Floyd WS, Cohn SL. Gonadotropin producing hepatoma. *Obstet Gynecol* 1973 May; 41(5): 665 - 8
  19. Hung W, Blizzard RM, Migeon CJ, Camacho AM, Nyhan WL. Precocious puberty in a boy with hepatoma and circulating gonadotropin. *J Pediatr* 1963 Nov; 63(5): 895 - 903
  20. Rose LI, Williams GH, Jagger PI, Lauler DP. Feminizing tumor of the adrenal gland with positive "chorionic-like" gonadotropin test. *J Clin Endocrinol* 1968 Jun; 28(6): 903 - 8
  21. Jindrak K, Hochetto JF, Alpert LI. Primary gastric

- choriocarcinoma : case report with review of world literature. *Human Pathol* 1976 Sep; 7(5): 595 - 604
22. Broder LE, Weintraub BD, Rosen RW, Cohen MH, Tejada F. Placental proteins and their subunits as tumor markers in prostatic carcinoma. *Cancer* 1977 Jul; 40(1): 211 - 6
  23. Tormey DC, Waalkes TP, Simon RM. Biological markers in breast carcinoma II. Clinical correlations with human chorionic gonadotropin. *Cancer* 1977 Jun; 39(6): 2391 - 6
  24. Weintraub BD, Scully RE. Diminished libido, gynecomastia and pulmonary lesion. Case records of the Massachusetts General Hospital, case 13-1972. *N Engl J Med* 1972 Mar 30; 286(13): 713 - 9
  25. Golde DW, Schambelan M, Weintraub BD, Rosen SW. Gonadotropin-secreting renal carcinoma. *Cancer* 1974 Apr; 33(9): 1048 - 53
  26. Kodama T, Kameya T, Hirota T, Shimosato Y, Ohkura H, Mukojima T, Kitaoka H. Production of alpha-fetoprotein, normal serum proteins, and human chorionic gonadotropin in stomach cancer : histologic and immunohistochemical analyses of 35 cases. *Cancer* 1981 Oct 1; 48(7): 1647 - 55
  27. Uchida T, Shikata T, Shimizu SI, Takimoto Y, Iino S, Suzuki H, Oda T, Hirano K, Sugiura M. Gonadotropin and alkaline phosphatase producing occult gastric carcinoma with widespread metastasis of generalized bone. *Cancer* 1981 Jul 1; 48(1): 140 - 50
  28. Braunstein GD, Vaitukaitis JL, Carbone PP, Ross GT. Ectopic production of human gonadotropin by neoplasms. *Ann Intern Med* 1973 Jan; 78(1): 39 - 45
  29. Tormey DC, Waalkes TP, Ahmann D, Gehrke CW, Zumwatt RW, Snyder J, Hansen H. Biological markers in breast carcinoma. Incidence of abnormalities of CEA, hCG, three polyamines and three minor nucleosides. *Cancer* 1975 Apr; 35(4): 1095 - 100
  30. Gailani S, Chu TM, Nussbaum A, Ostrander M, Christoff N. Human chorionic gonadotrophins (hCG) in non-trophoblastic neoplasms. Assessment of abnormalities of hCG and CLA in bronchogenic and digestive neoplasms. *Cancer* 1976 Oct; 38(4): 1684 - 6
  31. Rosen SW, Weintraub BD, Vaitukitis JL, Sussman HH, Hershman JM, Muggia FM. Placental proteins and their subunits as tumor markers. *Ann Intern Med* 1975 Jan; 82(1): 71 - 83
  32. Tahara E, Ito H, Nakagami K, Shimamoto F, Yamamoto M, Zumii K. Scirrhous argyrophil cell carcinoma of the stomach with multiple production of polypeptide hormones, amine, CEA, lysozyme and hCG. *Cancer* 1982 May 1; 49(9): 1904 - 115
  33. Blackman MR, Weintraub BD, Rosen SW, Kourides IA, Steinwascher K, Gail MH. Human placental and pituitary gonadoprotein hormones and their subunits as tumor markers : a quantitative assessment. *J Natl Cancer inst* 1980 Jul; 65(1): 81 - 93
  34. Ito H, Tahara E. Human chorionic gonadotropin in human gastric carcinoma. A retrospective immunohistochemical study. *Acta Pathol Jpn* 1983 Mar; 33(2): 287 - 96
  35. Vaitukaitis JL. Human chorionic gonadotropin - a hormone secreted for many reasons. *N*

- Engl J Med 1979 Aug 9; 301(6): 324 - 6
36. Radi MJ, Fenoglio-Preiser CM, Bartow SA, Key CR, Pathak DR. Gastric carcinoma in the young : a clinicopathological and immunohistochemical study. Am J Gastroenterology 1986 Sep; 81(9): 747 - 56
37. Kameya T, Tsumuraya M, Adachi I, Abe K, Ichikizaki K, Toya S, Demura R. Ultrastructure, immunohistochemistry and hormone release of pituitary adenomas in relation to prolactin production. Virchow Arch 1980; 387(1): 31 - 46
38. Yonemura Y, Oyama S, Sugiyama K, Sawa T, Shima Y, Kamata T, Hashimoto T, Miwa K, Miyazaki I. Human chorionic gonadotropin in gastric carcinoma. A useful marker for bone metastasis. Int Surg 1989 Apr-Jun; 74(2): 84-7