

2-1-1993

## Papillary meningiomas: personal experience and review of literature

Samruay Shuangshoti

Follow this and additional works at: <https://digital.car.chula.ac.th/clmjournal>



Part of the [Medicine and Health Sciences Commons](#)

---

### Recommended Citation

Shuangshoti, Samruay (1993) "Papillary meningiomas: personal experience and review of literature," *Chulalongkorn Medical Journal*: Vol. 37: Iss. 2, Article 9.

DOI: 10.58837/CHULA.CMJ.37.2.8

Available at: <https://digital.car.chula.ac.th/clmjournal/vol37/iss2/9>

This Review Article is brought to you for free and open access by the Chulalongkorn Journal Online (CUJO) at Chula Digital Collections. It has been accepted for inclusion in Chulalongkorn Medical Journal by an authorized editor of Chula Digital Collections. For more information, please contact [ChulaDC@car.chula.ac.th](mailto:ChulaDC@car.chula.ac.th).

## Papillary meningiomas: personal experience and review of literature\*

Samruay Shuangshoti\*\*

Shuangshoti S. Papillary meningiomas: personal experience and review of literature. Chula Med J 1993 Feb; 37(2): 133-148

*A review of the literature on 123 papillary meningiomas showed that only 61 of them possessed adequate pathologic and clinical data for analysis. The frequency of occurrence of papillary meningiomas was about 1% of all meningiomas of the central nervous system. Fifty of the sixty-one papillary meningiomas (82%) were malignant; eight of them (16%) metastasized. The rest were benign (18%). The papillary meningiomas must be differentiated from other papillary tumors including ependymoma, astroblastoma, and adenocarcinoma. Some papillary meningiomas were immunohistochemically positive to vimentin, cytokeratin, epithelial membrane antigen, S-100 protein, and glial fibrillary acidic protein. They were distributed, according to recorded age in 55 patients, in the first to eighth decades of life with the peak occurrence (24%) in the fifth decade. Twenty-nine percent of papillary meningiomas were in the first two decades of life suggesting the tendency to strike young individuals. The average age was 29 years for females, 45 years for males, and 34 years for overall. The female to male ratio was 3:2. The papillary meningiomas were most common on the cerebral convexity (46%) followed by the parasagittal region (21%); 10% of them were situated outside the central nervous system (ectopic).*

**Key words :** Brain tumor, Meningioma, Papillary neoplasm.

Reprint request : Shuangshoti S. Department of Pathology, Faculty of Medicine, Chulalongkorn University, Bangkok 10330, Thailand.

Received for publication. October 27, 1992.

\* This work was supported by the Chulalongkorn Faculty of Medicine-China Medical Board Scholar Development Fund (1991-1994)

\*\* Department of Pathology, Faculty of Medicine, Chulalongkorn University.

สำรวย ช่วงโชติ. แพฟิดลารี่เมนิงจิโอมา: ประสพการณ์ส่วนตัวและการทบทวนวารสาร. จุฬาลงกรณ์-  
เวชสาร 2536 กุมภาพันธ์ 37(2): 133-148

มีแพฟิดลารี่เมนิงจิโอมารายงานในวารสารการแพทย์เท่าที่ค้นคว้าได้ 123 ราย มีเพียง 61 ราย ที่มี  
รายละเอียดพอที่จะนำมาวิเคราะห์ทางพยาธิวิทยาและคลินิกได้ พบว่าเนื้องอกชนิดนี้ร้อยละ 82 เป็นชนิดร้ายมีการ  
กลับเป็นขึ้นใหม่หลังผ่าตัดได้บ่อย ๆ และร้อยละ 16 แพร่กระจายไปได้ไกล ๆ แต่ก็มีร้อยละ 18 ที่ไม่ใช่ชนิดร้าย  
ต้องแยกแพฟิดลารี่เมนิงจิโอมา ออกจากแพฟิดลารี่โอเมนดัยโมมา, แอสโตรบลาสโตมา, และแพฟิดลารี่ทูเมอร์  
อื่น ๆ เช่นอเคโนคาร์ซิโนมา เป็นต้น บางรายของแพฟิดลารี่เมนิงจิโอมาให้ผลบวกทางอิมมูโนฮิสโตเคมีต่อไวเมนติน,  
ซัยโตเคอราติน, อีพิธีเลียลเมมเบรนแอนติเจน, S-100 โปรตีน, และเกลียล ไฟบริลลารี่อซิดิกโปรตีน ในผู้ป่วย  
55 รายที่อายุกำกับไว้ในรายงาน, พบว่าเนื้องอกนี้เกิดได้ตั้งแต่อายุต่ำกว่า 10 ขวบจนถึงอายุ 70 ปีเศษ  
โดยพบมากที่สุดในช่วง 40 ปีเศษ เนื้องอกนี้ร้อยละ 29 เกิดในอายุต่ำกว่า 20 ปี แสดงถึงแนวโน้มที่จะพบบ่อย  
ในคนอายุน้อย อายุเฉลี่ยเท่ากับ 29 ปี ในผู้ป่วยหญิง, 45 ปี ในผู้ป่วย และ 34 ปี ในผู้ป่วยทั้งหมด อัตราส่วน  
หญิง : ชายเท่ากับ 3:2 พบเนื้องอกตามส่วนโค้งด้านบนของสมองใหญ่บ่อยที่สุดคือร้อยละ 46 รองลงมาคือ  
ที่บริเวณพาราแซดัล พบร้อยละ 21 เนื้องอกชนิดนี้เกิดนอกกระบบประสาทส่วนกลางร้อยละ 10

## Definition

Meningioma, the term proposed by Cushing and Eisenhardt<sup>(1)</sup> to designate the primary tumor of the meninges, possesses multiple classic types such as meningocytic (meningothelial, meningotheliomatous, syncytial, endotheliomatous, or epitheliomatous), fibroblastic, mixed meningocytic and fibroblastic (transitional), angioblastic etc.

Papillary meningioma is a type of meningioma in which its cells, in part or in whole, form papillae. However, it is usually associated with classic type(s) of meningioma. One, thus, may encounter a papillary meningioma related to a meningocytic, fibroblastic, transitional, or angioblastic meningioma, or to perceive it as a pure papillary meningioma.

A papilla is a structure consisting of a vascular core of connective tissue to be surfaced by cells, especially epithelial cells.

## Historical Consideration

The first case of papillary meningioma was reported by Cushing and Eisenhardt in 1938.<sup>(1)</sup> It was associated with an epitheliomatous meningioma. A 17-year-old woman, Dorothy May Russell, had this intracranial tumor at the left precentral region. During 1919 to 1932, the patient had 20 hospitalizations and 17 craniotomies for removal of the primary meningioma as well as

recurrent meningiomas. She died at 30 years of age. At autopsy, a huge recurrent tumor in the left frontal region and seven secondary nodules, four in the subarachnoid space and three in the upper lobe of the right lung, were papillary meningiomas.

Since the first case was reported in 1938, the number of recorded papillary meningiomas was increased to 123 examples in 1993 (Table 1). Two instances were excluded<sup>(21,22)</sup> because they were apparently included in a series of Ludwin et al.<sup>(4)</sup> A case described by Scotti et al.<sup>(23)</sup> was also not included because of the unclear description concerning the pathologic feature of the lesion and lacking of the illustration. Zülch,<sup>(24)</sup> in 1979, introduced the term "papillary meningioma" into the International Histological Classification of Tumors of the Central Nervous System (CNS) arranged by the World Health Organization.

## Available Data on Papillary Meningiomas from Medical Literature

Sixty-one of 123 primary papillary meningiomas recorded in the literature were summarized based on the available pathologic and clinical data which, of course, were incomplete in some cases (Table 2). The remaining 62 papillary meningiomas were not analysed because of lacking of these data.

Table 1. Reports of Papillary Meningiomas in Literature.

Author(s) & references	No. of cases	Year
Cushing and Eisenhardt <sup>(1)</sup>	1	1938
Kepes et al <sup>(2)</sup>	1	1971
Miller and Ramsden <sup>(3)</sup>	1	1972
Ludwin et al <sup>(4)</sup>	17	1975
Goin <sup>(5)</sup>	1	1979
Allegranza et al <sup>(6)</sup>	1	1980
Stefanko and Mackay <sup>(7)</sup>	6	1981
Deen et al <sup>(8)</sup>	5	1982
Roytta et al <sup>(9)</sup>	5	1982
Kepes et al <sup>(10)</sup>	1	1983
Erignolio and Favero <sup>(11)</sup>	8	1984
Inoue et al <sup>(12)</sup>	2	1985
Kasantikul and Shuangshoti <sup>(13)</sup>	2	1985
Su et al <sup>(14)</sup>	1	1986
Piatt et al <sup>(15)</sup>	1	1986
Pasquier et al <sup>(16)</sup>	7	1986
Buska <sup>(17)</sup>	1	1986
Nakagawa et al <sup>(18)</sup>	1	1989
Russell and Rubinstein <sup>(19)</sup>	60**	1989
Shuangshoti <sup>(20)</sup>	1	1993
<b>Total</b>	<b>123</b>	

\* Cases reported by Russell<sup>(21)</sup> and Ludwin and Conley<sup>(22)</sup> are apparently included in the series of Ludwin et al.<sup>(4)</sup> They, thus, are not included.

\*\* Most cases were consulted to Russell and Rubinstein.

Table 2. Summary of Reported Papillary Meningiomas with Available Pathologic and Clinical Data.

Case No.	Author(s), date & references	Patient's age (yrs) & sex	Location of meningiomas	Treatment	Recurrence(s)	Pathologic features	Patient's outcome
1	Cushing & Eisenhardt, 1938 <sup>(1)</sup>	30 F	L parasagittal	Resection	Recurrences	Epitheliomatous Meningioma with papillary formations in recurrent & pulmonary metastatic tumors	Survived for 13 yrs. Died with recurrent intracranial tumor & secondary tumors in subarachnoid space & R lung found in autopsy
2	Kepes et al, 1971 <sup>(2)</sup>	40 M	Tentorial	Resection	Recurrence	Spindle-shaped cells with elongated nuclei, papillary formations in recurrent & metastatic tumors	Survived for 9 yrs. Died with extensive metastases in lungs, pancreas, kidneys & liver found in autopsy
3	Miller & Ramsden, 1972 <sup>(3)</sup>	45 M	Frontal para-sagittal	Resection & radiotherapy	Recurrences	Syncytial meningioma with angioblastic component & papillary formation, marked nuclear pleomorphism, many mitotic figures, necrosis & invasion of skull	Survived for 2½ yrs. Died with metastases in subarachnoid space, pleura, lungs tracheobronchial & mediastinal lymph nodes
4	Ludwin et al, 1975 <sup>(4)</sup>	41 M	L occipital	Resection	Recurrence	Syncytial and papillary meningioma, mitotic figures	Survived for 16 yrs. Died with residual tumor & metastases in lungs & liver found in autopsy
5	Ludwin et al, 1975 <sup>(4)</sup>	53 M	R frontal	Resection	Recurrence	Transitional & papillary meningioma, mitotic figures & invasion of brain	Survived for 1 yrs. Died with residual tumor & metastases in cerebrospinal axis found in autopsy
6	Ludwin et al, 1975 <sup>(4)</sup>	33 M	L parieto-occipital, attached to falx & transverse sinus	Resection	Recurrence	Angioblastic & papillary meningioma with predominance of the former.	Survived for 8 yrs. Died with metastasis to head of femur
7	Ludwin et al, 1975 <sup>(4)</sup>	46 M	R sphenoid wing	Resection	Recurrence	Syncytial & papillary meningioma, mitotic figures & invasion of brain	Survived for 4 yrs. Died with residual tumor
8	Ludwin et al, 1975 <sup>(4)</sup>	12 F	R parietal para-sagittal	Resection	Recurrence	Angioblastic & papillary meningioma, mitotic figures	Survived for 5 yrs. Died with residual tumor in autopsy

Table 2. Summary of Reported Papillary Meningiomas with Available Pathologic and Clinical Data (Continued).

Case No.	Author(s), date & references	Patient's age (yrs) & sex	Location of meningiomas	Treatment	Recurrence(s)	Pathologic features	Patient's outcome
9	Ludwin et al, 1975 <sup>(4)</sup>	41 F	L parasagittal	Resection	Recurrence	Transitional & papillary meningioma, invasion of brain	Survived for 2 yrs. Died with residual tumor in autopsy.
10	Ludwin et al, 1975 <sup>(4)</sup>	67 M	M R frontal	None	—	Transitional & papillary meningioma, invasion of brain	Incidental autopsy finding.
11	Ludwin et al, 1975 <sup>(4)</sup>	28 F	Posterior fossa attached to clivas	Resection	Recurrence	Syncytial & papillary meningioma, mitotic figures	Survived for 4 yrs. Died with residual tumor
12	Ludwin et al, 1975 <sup>(4)</sup>	5 F	R occipital	Resection	Recurrences	Predominantly papillary meningioma, invasion of brain	Alive for 20 yrs with residual tumor
13	Ludwin et al, 1975 <sup>(4)</sup>	10 F	R frontal	Resection	Recurrence	Predominantly papillary meningioma	Alive for 4 yrs with residual tumor
14	Ludwin et al, 1975 <sup>(4)</sup>	9 F	R temporal	Resection	No report	Syncytial & papillary meningioma with predominance of former, mitotic figures	Alive for 4½ yrs. Clinical metastasis in posterior cranial fossa
15	Ludwin et al, 1975 <sup>(4)</sup>	13 M	R frontal	Resection	Recurrence	Transitional & papillary meningioma with predominance of former, mitotic figures	Alive for 17 yrs without known tumor
16	Ludwin et al, 1975 <sup>(4)</sup>	30 F	Midthoracic, subdural, extramedullary	Resection	No report	Papillary & syncytial meningioma, mitotic figures	Alive for 3 yrs without known tumor
17	Ludwin et al, 1975 <sup>(4)</sup>	9 F	R frontoparietal	Resection	No report	Angioblastic & papillary meningioma, mitotic figures, invasion of brain	Alive for 1½ yrs without known tumor
18	Ludwin et al, 1975 <sup>(4)</sup>	8 F	R parietal	Resection	No report	Syncytial & papillary meningioma with predominance of former, mitotic figures, invasion of brain	Alive for 1.2 yrs without known tumor
19	Ludwin et al, 1975 <sup>(4)</sup>	3 F	L frontal, extending to ventricle	Resection	No report	Angioblastic & papillary meningioma with predominance of latter, mitotic figures	Alive for 1.9 yrs without known tumor

Table 2. Summary of Reported Papillary Meningiomas with Available Pathologic and Clinical Data (Continued).

Case No.	Author(s), date & references	Patient's age (yrs) & sex	Location of meningiomas	Treatment	Recurrence(s)	Pathologic features	Patient's outcome
20	Ludwin et al, 1975 <sup>(4)</sup>	50 M	R occipital parasagittal	Resection	No report	Angioblastic & papillary meningioma with predominance of former	Alive for 4 yrs without known tumor
21	Goin, 1979 <sup>(5)</sup>	28 F	R petrous apex	Resection & radiotherapy	No report	Fibroblastic meningioma with papillary configurations, mitotic figures	Alive for ½ yrs with probable residual tumor
22	Allegranza et al, 1980 <sup>(6)</sup>	30 M	Parietal	Resection & radiotherapy	Recurrence	Endotheliomatous, fibrosarcomatous & papillary meningioma, nuclear pleomorphism & mitotic figures	Alive for 2½ yrs.
23	Stefanko & Mackay, 1981 <sup>(7)</sup>	M	Tentorial	Resection	No report	Papillary meningioma	No report
24	Stefanko & Mackay, 1981 <sup>(7)</sup>	M	Cauda equina	Resection	No report	Papillary meningioma	No report
25	Stefanko & Mackay, 1981 <sup>(7)</sup>	M	No report	Resection	No report	Papillary meningioma	No report
26	Stefanko & Mackay, 1981 <sup>(7)</sup>	F	No report	Resection	No report	Papillary meningioma	No report
27	Stefanko & Mackay, 1981 <sup>(7)</sup>	F	No report	Resection	No report	Papillary meningioma	No report
28	Stefanko & Mackay, 1981 <sup>(7)</sup>	F	No report	Resection	No report	Papillary meningioma	No report
29	Kepes et al, 1983 <sup>(10)</sup>	11 F	L parietal parasagittal to falx attached	Resection & radiotherapy	Recurrence	Meningioma with hemangiopericytomatous, papillary & pseudoglandular formations, mitotic figures	Alive for 5 yrs
30	Brignolio & Favero, 1984 <sup>(11)</sup>	43 M	L frontal	Resection	No	Fibroblastic & papillary meningioma, polymorphism, rare mitotic figures	Alive for 23 yrs with total recovery
31	Brignolio & Favero, 1984 <sup>(11)</sup>	48 F	L sphenoid wing	Resection	No	Papillary meningioma, hypercellularity, focal necrosis, few mitotic figures	Alive for 21 yrs with partial recovery
32	Brignolio & Favero, 1984 <sup>(11)</sup>	62 M	L frontal	Resection	Recurrence	Papillary meningioma, hypercellularity, foci of necrosis, typical & atypical mitotic figures	Survived for 4 yrs & then died

Table 2. Summary of Reported Papillary Meningiomas with Available Pathologic and Clinical Data (Continued).

Case No.	Author(s), date & references	Patient's age (yrs) & sex	Location of meningiomas	Treatment	Recurrence(s)	Pathologic features	Patient's outcome
33	Brignolio & Favero, 1984 <sup>(11)</sup>	65 F	R temporal	Resection	No report	Papillary meningioma, necrosis, mitotic figures	Died 8 days after removal
34	Brignolio & Favero, 1984 <sup>(11)</sup>	61 M	L frontal	Resection	Recurrence ?	Hemangioblastic & papillary meningioma, necrosis, polymorphism, typical & atypical mitotic figures	Died 2½ months after removal
35	Brignolio & Favero, 1984 <sup>(11)</sup>	63 F	R parietal	Resection	Recurrences	Transitional & papillary meningioma, focal necrosis, typical & atypical mitotic figures	Partial recovery. Died 4 yrs later
36	Brignolio & Favero, 1984 <sup>(11)</sup>	43 F	L parieto-occipital	Resection	Recurrences	Transitional & papillary meningioma, necrosis, typical & atypical mitotic figures	Partial recovery. Died 14 yrs later
37	Brignolio & Favero, 1984 <sup>(11)</sup>	38 F	T <sub>9,10</sub>	Resection	Recurrence	Hemangiopericytoma & papillary meningioma, necrosis, typical & atypical mitotic figures	Died 1 yr later
38	Inoue et al, 1984 <sup>(12)</sup>	41 F	Parasagittal	Resection & radiotherapy	No	Papillary meningioma	Alive & well after 11 yrs
39	Inoue et al, 1984 <sup>(12)</sup>	48 F	Frontal convexity	Resection & radiotherapy	No	Papillary meningioma	Alive & well after 7 yrs
40	Kasantikul & Shuangshoti, 1985 <sup>(13)</sup>	27 F	L cerebellopontine angle	Resection	No	Transitional, papillary and glandular meningioma	Postoperative death within 5 days
41	Kasantikul & Shuangshoti, 1985 <sup>(13)</sup>	13 M	L occipital, extradural	Resection	No	Papillary & glandular meningioma	Postoperative death within 3 days
42	Su et al, 1986 <sup>(14)</sup>	48 F	L occipital	Resection & radiotherapy	Recurrence	Hemangiopericytic & papillary meningioma, anaplasia, mitotic figures	Survived for 10 yrs & 2 months. Died with metastases within CNS & to pleura



Table 2. Summary of Reported Papillary Meningiomas with Available Pathologic and Clinical Data (Continued).

Case No.	Author(s), date & references	Patient's age (yrs) & sex	Location of meningiomas	Treatment	Recurrence(s)	Pathologic features	Patient's outcome
43	Piatt et al, 1986 <sup>(15)</sup>	4½ months F	midbrain with invasion of R oculomotor nerve	Resection	No	Papillary meningioma, no mitotic figures	Survived for 1 yrs after removal, R amblyopia, complete palsy of R oculomotor nerve
44	Pasquier et al, 1986 <sup>(16)</sup>	21 F	Paravertebral subcutaneous tissue, eighth intercostal space	Resection	Recurrence(s)	Transitional & papillary meningioma	Survived for 9 yrs. Died with spinal metastases, invasion of muscle & rib.
45	Pasquier et al, 1986 <sup>(16)</sup>	29 M	L parietal parasagittal	Resection	Recurrence(s)	Anaplastic transitional & papillary meningioma	Survived for 6 yrs. Died with pulmonary metastasis confirmed in autopsy
46	Pasquier et al, 1986 <sup>(16)</sup>	67 F	R parietal	Resection	Recurrence	Syncytial, angioblastic, & papillary meningioma	Died 15 months. No autopsy
47	Pasquier et al, 1986 <sup>(16)</sup>	69 F	L frontal parasagittal	Resection	Recurrence	Transitional & papillary meningioma	Died 14 months
48	Pasquier et al, 1986 <sup>(16)</sup>	52 M	L parietal	Resection	Recurrences	Transitional, angioblastic & papillary meningioma	Died 4 yrs. No autopsy
49	Pasquier et al, 1986 <sup>(16)</sup>	38 M	L petrous apex (intraosseous)	Radiotherapy	No report	Papillary meningioma	Alive for 7 yrs with cerebral radionecrosis
50	Pasquier et al, 1986 <sup>(16)</sup>	29 M	L frontal	No report	No report	Transitional & papillary meningioma	Alive for 22 months
51	Budka, 1986 <sup>(17)</sup>	48 F	L frontal parasagittal	Resection	Recurrences	Hemangiopericytic & papillary meningioma with trabecular formations	Survived 1 month after removal
52	Nakagawa et al, 1989 <sup>(18)</sup>	48 F	Occipital sinuum with multidirectional extension through venous sinuses	Resection	No report	Papillary meningioma, mitotic figures	Survive 1 month after resection
53	Russell & Rubin-stein, 1989 <sup>(19)</sup>	5 F	R Occipital	No report	No report	Malignant syncytial & meningioma	No report
54	Russell & Rubin-stein, 1989 <sup>(19)</sup>	8 F	R parietal	No report	No report	Malignant papillary meningioma	No report
55	Russell & Rubin-stein, 1989 <sup>(19)</sup>	30 F	Intraspinal, midthoracic	No report	No report	Syncytial and papillary meningioma	No report

Table 2. Summary of Reported Papillary Meningiomas with Available Pathologic and Clinical Data (Continued).

Case No.	Author(s), date & references	Patient's age (yrs) & sex	Location of meningiomas	Treatment	Recurrence(s)	Pathologic features	Patient's outcome
56	Russell & Rubin-stein, 1989 <sup>(19)</sup>	12 F	R parasagittal	Resection	Recurrence	Papillary meningioma	No report
57	Russell & Rubin-stein, 1989 <sup>(19)</sup>	4 months F	No report	No report	No report	Papillary meningioma	No report
58	Russell & Rubin-stein, 1989 <sup>(19)</sup>	4 months F	No report	No report	No report	Papillary meningioma	No report
59	Russell & Rubin-stein, 1989 <sup>(19)</sup>	86 M	Subcutaneous tissue, gabella	No report	No report	Hemangiopericytic & papillary meningioma	No report
60	Russell & Rubin-stein, 1989 <sup>(19)</sup>	36 M	Subcutaneous tissue, L angle of jaw	No report	No report	Syncytial & papillary meningioma	No report
61	Shuangshoti, 1993 <sup>(20)</sup>	54 F	L optic nerve sheath	Resection	No	Meningocytic, fibroblastic & papillary meningioma, benign, no mitotic figures & necrosis	Well, 2 ½ yrs after resection

Abbreviation: R = Right, L = Left, M = Male, F = Female

## Frequency of Occurrence of Papillary Meningiomas

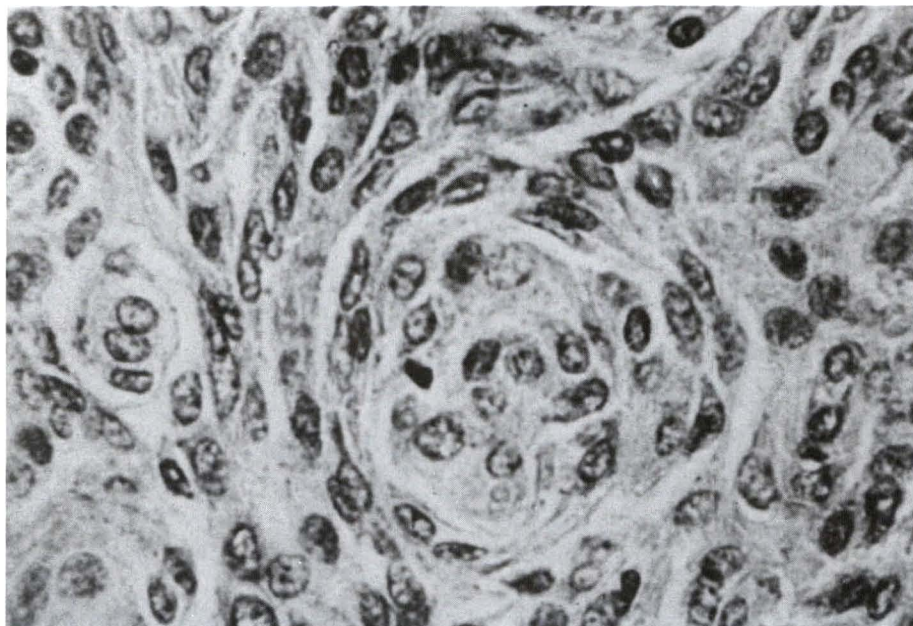
The papillary meningioma comprised one of 313 meningiomas of the CNS (0.3%) in the series of Cushing and Eisenhardt,<sup>(1)</sup> eight of 750 meningiomas of the CNS (1.1%) in the series of Brignolio and Favero,<sup>(11)</sup> and one of 242 meningiomas of the CNS (0.4%) in the series of Su et al.<sup>(14)</sup> A combination of these series depicted a frequency of about 1% of papillary meningiomas among meningiomas of the CNS.

## Pathologic Features of Papillary Meningiomas

The gross appearance of papillary meningiomas is similar to those of classical meningiomas which is usually circumscribed,

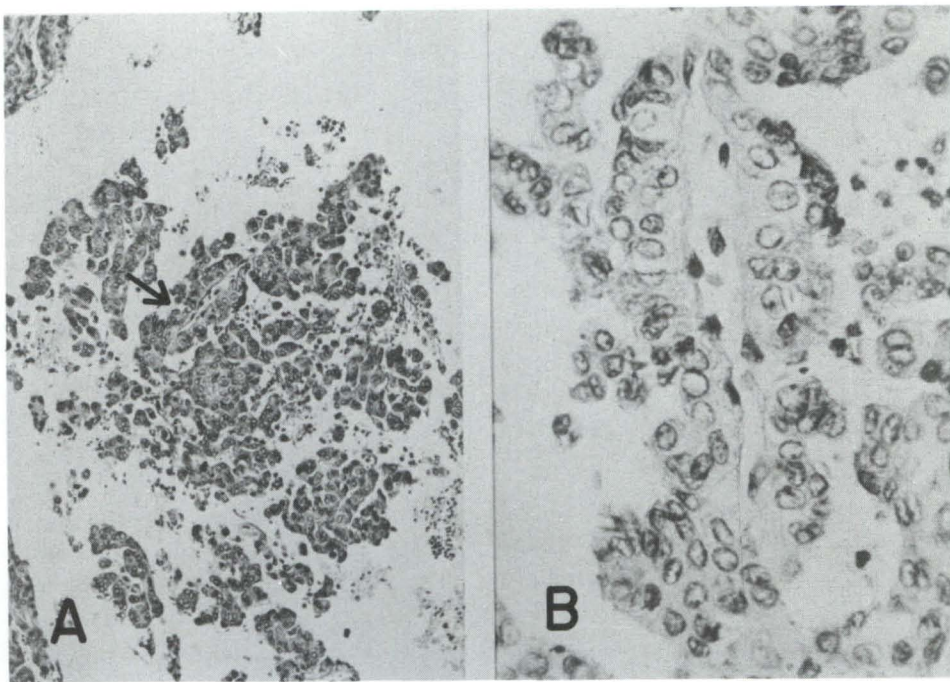
rubbery to firm, and gray in formalin-fixed tissue. The cut surface may be granular, trabecular, whorled, hemorrhagic, necrotic, and sometime cystic.

Microscopically, the classical pictures of meningiomas, such as whorls of meningiocytes and fibroblasts, are frequent (Fig. 1) as well as the papillary formations (Fig. 2). The glandular structures may be included (Fig. 3) as are psammoma bodies. Reticulin fibers are frequent when the angioblastic (hemangiopericytic) and papillary features are mingled. Nuclear pleomorphism, mitotic figures, hemorrhages, necrotic foci, and invasion of surrounding brain are common in malignant papillary meningiomas which are commonly recurrent and occasionally metastasize, either within or outside the CNS or both.<sup>(4)</sup>

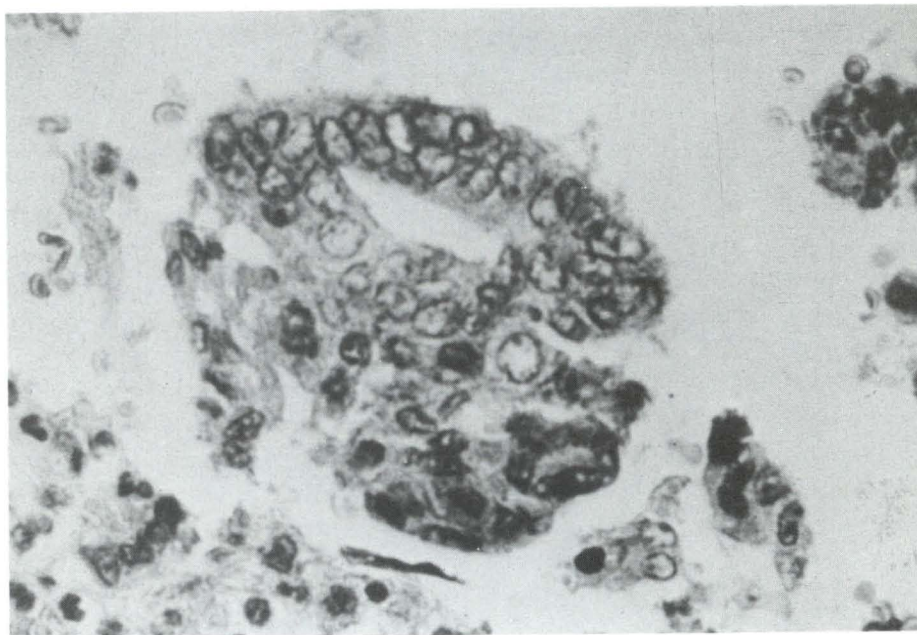


**Figure 1.** Papillary meningioma showing classical feature consisting of whorls of plump syncytial meningiocytes and spindle-shaped fibroblasts. This tumor occurred in the left cerebellopontine angle of a 19-year-old woman who died 5 days after craniotomy.<sup>(13)</sup> Hematoxylin and eosin, x 400.





**Figure 2.** Papillary meningioma, same case as in figure 1.<sup>(13)</sup> (A) Multiple papillae are displayed; one is indicated by an arrow. Hematoxylin and eosin, x 100. (B) The same papilla marked by the arrow in (A) to show vascular core of connective tissue surfaced by syncytial meningocytes with nuclear vacuoles. Hematoxylin and eosin, x 400.



**Figure 3.** This neoplastic gland consisting of syncytial meningocytes with nuclear vacuoles is found in the same papillary meningioma illustrated in figures 1 and 2.<sup>(13)</sup> Hematoxylin and eosin, x 400.

Based on data of 61 cases in Table 2, the current author arbitrarily concluded that there were 50 malignant papillary meningiomas (82%) because of the presence of the aforementioned malignant features.<sup>(1-7,10,11,14,16-19)</sup> Metastasis, the unequivocal malignant evidence, occurred in eight of these malignant papillary meningiomas (16%).<sup>(7,12,15,20)</sup> The lacking of follow-up data made uncertain evaluation on malignancy in three cases.<sup>(11,13)</sup> There were eight benign papillary meningiomas (13%).<sup>(7,12,15,20)</sup> It is interesting to note from Table 2 that patient with malignant papillary meningiomas may live as long as 10 to 25 years with repeated recurrent episodes.

In the absence of a classical morphologic picture, the papillary meningioma may be mixed up with other papillary tumors such as papillary ependymoma, astroblastoma, papilloma of the choroid plexus, and metastatic adenocarcinoma to the CNS. In an autopsy case, the intracranial epidural tumor showed prominent papillary and glandular features without any classical picture of meningioma; the lesion was diagnosed pathologically as a meningioma by detection of interdigitations of the plasma membrane of the neoplastic cells in an electron microscopic study.<sup>(13)</sup> Otherwise it was indistinguishable from an ependymoma by light microscopic examination.

The mechanism is unclear regarding the formation of papillae. Kepes<sup>(25)</sup> suggested the papillary formation to begin with tumor cells surrounding blood vessels or vascular core of connective tissue in perpendicular fashion. Subsequent loosening of the adjacent neoplastic cells results in more distinctive papillary structure. Stefanko and Mackay<sup>(7)</sup> considered the perivascular arrangement of tumor cells as the initial step in papillary formation followed by disintegration of neoplastic cells in the periphery of the involved blood vessels. Such cellular disintegration may be related to deficient nutrition because of vascular changes (vasotropism) as well as weak cohesiveness among tumor cells. Pasquier et al<sup>(16)</sup> regarded the papillary arrangement as a histopathological bridge among syncytial, fibroblastic, and hemangiopericytic meningiomas

but did not offer the idea about the mode of formation of the papillae.

The significance of papillary structures in meningioma has been debated. Many authors regarded papillary formations to represent morphologic malignancy in meningioma because they often observed high rate of nuclear pleomorphism and mitotic figures, necrosis, invasion of surrounding brain, recurrences, and even metastasis in such papillary meningiomas.<sup>(2,4,8,10,11,19,25)</sup>

A few authors, on the other hand, considered papillary structure to be a form of arrangement of tumor cells without malignant indication if the aforementioned malignant features were absent.<sup>(7)</sup> In one of the current author's case, the papillary meningioma of the optic nerve sheath was pathologically and clinically benign. It was within the patient's orbit for 20 years without invasion of the orbital walls and was not recurrent during 2.5-year postoperative period.

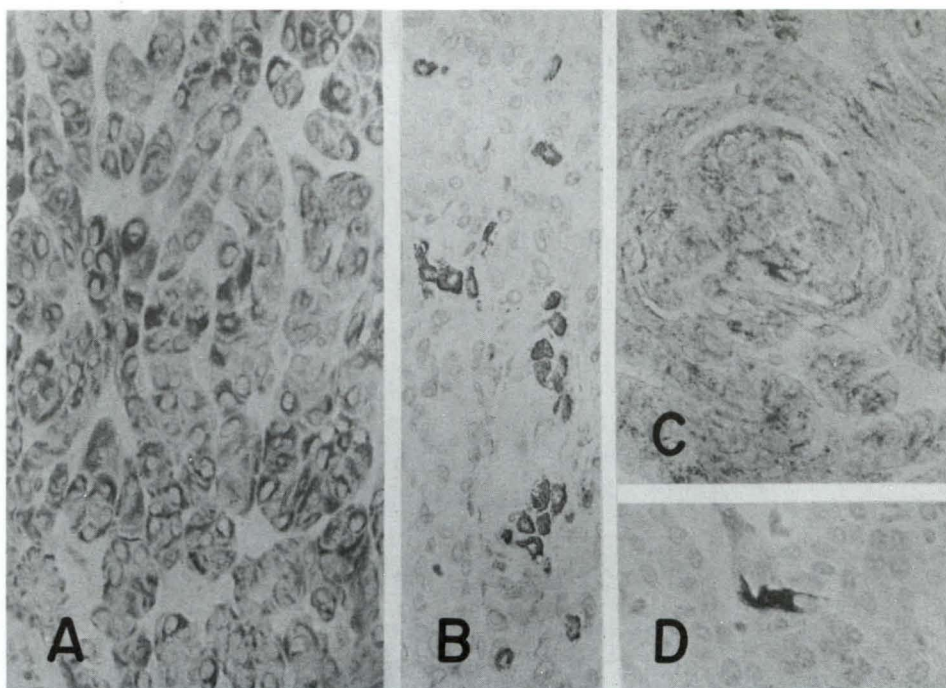
### Immunohistochemical Features of Papillary Meningioma

Immunohistochemically, cytoplasmic positivity to vimentin, cytokeratin, epithelial membrane antigen, and S-100 protein has been reported (Fig 4).<sup>(20)</sup> Cytoplasmic localization of glial fibrillary acidic protein, moreover, has been documented although papillary meningioma is not a neuroepithelial tumor.<sup>(17,19)</sup>

### Age and Sex

The age was known in 55 patients and sex in 61 patients who had primary papillary meningiomas. The frequency on the age and sex distribution is shown in Table 3. The two youngest patients were female; each was 4-month-old.<sup>(19)</sup> The oldest patient was 86-year-old man.<sup>(19)</sup> The mean age was 29 years for females, 45 years for males, and 34 years for overall. The peak occurrence was in the fifth decade of life (24%). About 29% of patients were in the first two decades suggesting a tendency for the papillary meningiomas to occur in young subjects. There were 38 female and 23 male patients, a ratio of 3:2.





**Figure 4.** Immunohistochemical features of a previously reported benign papillary meningioma arising in the sheath of the left optic nerve of a 54-year-old woman for 20 years.<sup>(20)</sup> Darkness of cytoplasm of some tumor cells is related to positivity to (A) vimentin, (B) cytokeratin, (C) epithelial membrane antigen, and (D) S-100 protein. Immunoperoxidase stain, x 400 each.

**Table 3.** Distribution of Age and Sex of Patients with Primary Papillary Meningiomas.

Age (yrs)	No of cases			Percent
	Males	Females	Total	
0 – 10	0	11	11	20
11 – 20	2	3	5	9
21 – 30	3	7	10	18
31 – 40	4	1	5	9
41 – 50	5	8	13	24
51 – 60	2	1	3	5
61 – 70	3	4	7	13
71 – 80	0	0	0	0
81 – 90	1	0	1	2
Unknown	3*	3*	6*	—
<b>Total</b>	<b>20 + 3* = 23</b>	<b>35 + 3* = 38</b>	<b>55 + 6* = 61</b>	<b>100</b>

\* Not included in computing percentage.

Location

Table 4 shows specific location of 54 primary papillary meningiomas. Fourty of 54 tumors (74%) were supratentorial; most of them were on the cerebral convexity (46%) and in the parasagittal region (21%). They were less common at the cranial base, in the posterior

cranial fossa, and in the spinal canal. Interestingly enough, 10% of primary papillary meningiomas were ectopic in such place as subcutaneous tissue of the nasal root,<sup>(19)</sup> neck,<sup>(19)</sup> and paravertebral tissue<sup>(16)</sup> as well as in the petrous apex,<sup>(16)</sup> and optic nerve sheath.<sup>(20)</sup> The cellular origin and mode of occurrence of these ectopic meningiomas have been discussed.<sup>(26-28)</sup>

Table 4. Known Location of Reported Primary Papillary Meningiomas.

Location of meningiomas & references	No of cases	Percent of total
Intracranial		
Supratentorial		
Parasagittal <sup>(1,4,12,19)</sup>	4	7
Frontal parasagittal <sup>(3,16,17)</sup>	3	5
Parietal parasagittal <sup>(4,10,16)</sup>	3	5
Occipital parasagittal <sup>(4)</sup>	1	2
Parieto-occipital parasagittal <sup>(4)</sup>	1	2
Cerebral convexity		
Frontal <sup>(4,11,12,16)</sup>	10	18
Temporal <sup>(4,11)</sup>	2	4
Parietal <sup>(6,11,16,19)</sup>	6	11
Occipital <sup>(4,13,14,18,19)</sup>	6	11
Frontoparietal <sup>(4)</sup>	1	2
Sphenoid wing <sup>(4,11)</sup>	2	4
Petrous apex <sup>(5)</sup>	1	2
Total supratentorial	40	74
Midbrain with involvement of oculomotor nerve <sup>(15)</sup>	1	2
Tentorial <sup>(2,7)</sup>	2	4
Subtentorial		
Cerebellopontine angle <sup>(13)</sup>	1	2
Posterior fossa with attachment to clivus <sup>(4)</sup>	1	2
Total subtentorial	2	4
Intraspinal		
Thoracic <sup>(4,11,19)</sup>	3	5
Cauda equina <sup>(7)</sup>	1	2
Total intraspinal	4	7
Extraneuraxial		
Intraosseous meningioma of petrous apex <sup>(16)</sup>	1	2
Paravertebral soft tissue <sup>(16)</sup>	1	2
Glabella <sup>(19)</sup>	1	2
Angle of jaw <sup>(19)</sup>	1	2
Sheath of optic nerve <sup>(20)</sup>	1	2
Total extraneuraxial	5	10
Total	54	100

## References

1. Cushing H, Eisenhardt L. Meningiomas. Their Classification, Regional Behaviour, Life History, and Surgical End Results. Springfield, Illinois: Charles C Thomas, 1938. 692-719
2. Kepes JJ, MacGee EE, Vergara G, Sil R. Malignant meningioma with extensive pulmonary metastases. A case report. J Kansas Med Soc 1971 Jul; 72: 312-6
3. Miller AA, Ramsden F. Malignant meningioma with extracranial metastases and seeding of the subarachnoid space and the ventricle. Pathol Europ 1972; 7(2): 167-75
4. Ludwin SK, Rubinstein LJ, Russell DS. Papillary meningioma. A malignant variant of meningiomas. Cancer 1975 Oct; 36(4): 1363-75
5. Goin DW. Surgical management of petrous apex meningioma. Laryngoscope 1989 Feb; 89(2): 204-13
6. Allegranza A, Mariani C, Passeriani A, Grazioli L. Meningioma papillare maligno. Istocitopathologia 1980; 2: 193-9
7. Stefanko SZ, Mackay WM. Papillary meningioma. Acta Neuropathol 1981; 7 Suppl: 126-8
8. Deen HG Jr, Scheithauer BW, Ebersold MJ. Clinical and pathological study of meningiomas of the first two decades of life. J Neurosurg 1982 Mar; 56(3): 317-22
9. Røytta M, Vallfore P, Svendsen P, Suorander P. Recurrent meningiomas. A combined clinical, neuroradiological and neuropathological study. Acta Neurol Scand 1982 Jun; 65 Suppl 90: 105-6
10. Kepes JJ, Goldware S, Leoni R. Meningioma with pseudoglandular pattern. J Neuropathol Exp Neurol 1983 Jan; 61(1): 61-8
11. Brignolio P, Favaro M. Consideration of the malignancy of papillary meningioma. Clinicopathological study of eight cases. Zentralbl Neurochir 1984 Jun; 45(6): 79-84
12. Inoue H, Tamura M, Koizumi H, Nakamura M, Nakanuma H, Ohye Ch. Clinical pathology of malignant meningiomas. Acta Neurochir (Wien) 1984; 73(1-4): 179-91
13. Kasantikul V, shuangshoti S. Papillary and glandular meningiomas. Report of two cases. J Med Assoc Thai 1985 May; 68(5): 276-81
14. Su CP, Shin CJ, Tsou CK, Wang YC, Wu JJ, Liu MY, Lee WH, Tu YC. Malignant meningiomas. Clinical and pathological study of 10 cases. J Formosan Med Assoc 1986 Jun; 85(6): 608-23
15. Piatt JH Jr, Campbell GA, Oakes WJ. Papillary Meningioma involving the oculomotor nerve in an infant. Case report. J Neurosurg 1986 May; 64(5): 808-12
16. Paasquier B, Gasnier F, Pasquier D, Keddari E, Morens A, Couderc P. Papillary meningiomas. Clinicopathologic study of seven cases and review of the literature. Cancer 1986 Jul; 58(2): 299-305
17. Budka H. Non-glial specificities of immunocytochemistry for glial fibrillary acidic protein (GFAP). Triple expression of GFAP, vimentin and cytokeratin in papillary meningioma and metastasizing renal carcinoma. Acta Neuropathol 1986; 72(1): 43-54
18. Nakagawa H, Nakajima S, Murasawa A, Niiyama K, Ishiguro S. Papillary meningioma arising from the confluens sinuum with multidirectional extensions through venous sinuses. Surg Neurol 1989 Sep; 32(3): 219-24.
19. Russell DS, Rubinstein LJ. Pathology of Tumours of the Nervous System. 5th ed, London: Edward Arnold, 1989. 460, 481-3
20. Shuangshoti S. Primary papillary meningioma of sheath of optic nerve. Case of unique location and benign pictures. Surg Neurol 1993 (in press).
21. Russell DS. Meningeal tumours: a review. J Clin Pathol 1950; 3: 191-211
22. Ludwin SK, Conley FK. Malignant meningioma metastasizing through the cerebrospinal pathways. J Neurol Neurosurg Psychiatry 1975 Jan; 38(1): 136-42
23. Scotti G, Filizzolo F, Scialfa G, Tampieri D, Versari P. Repeated subarachnoid hemorrhages form a cervical meningioma. Case report. J Neurosurg 1987 May; 66(5): 779-81
24. Zülch KJ. Histological typing of tumours of the central nervous system. In: International Histological Classification of Tumours. No 21. Geneva: World Health Organization: 1979. 53-6
25. Kepes JJ. Meningiomas. Biology, Pathology, and Differential Diagnosis. New York:



- Masson Publishing, 1982. 91-9
26. Shuangshoti S, Netsky MG, Fitz-Huge GS. Parapharyngeal meningioma with special reference to cell of origin. *Ann Otol Rhinol Laryngol* 1971 Jun; 80(3): 464-73
27. Shuangshoti S, Panyathanya R. Ectopic meningiomas. *Arch Otolaryngol* 1973 Aug; 98(8): 102-5
28. Shuangshoti S. Primary meningiomas outside the central nervous system. In: Al-Mefty O, ed. *Medningiomas*. New York: Raven Press, 1991. 107-28