

10-1-1993

Ultrasonographic findings of pancreatic carcinoma

Laddawan Vajragupta

Boonyapom Vasuratna

Kaesom Vajarapongse

Darunee Boonjunwetwat

Follow this and additional works at: <https://digital.car.chula.ac.th/clmjournal>



Part of the [Medicine and Health Sciences Commons](#)

Recommended Citation

Vajragupta, Laddawan; Vasuratna, Boonyapom; Vajarapongse, Kaesom; and Boonjunwetwat, Darunee (1993) "Ultrasonographic findings of pancreatic carcinoma," *Chulalongkorn Medical Journal*: Vol. 37: Iss. 10, Article 3.

DOI: 10.58837/CHULA.CMJ.37.10.3

Available at: <https://digital.car.chula.ac.th/clmjournal/vol37/iss10/3>

This Article is brought to you for free and open access by the Chulalongkorn Journal Online (CUJO) at Chula Digital Collections. It has been accepted for inclusion in Chulalongkorn Medical Journal by an authorized editor of Chula Digital Collections. For more information, please contact ChulaDC@car.chula.ac.th.

Ultrasonographic findings of pancreatic carcinoma

Laddawan Vajragupta * Boonyaporn Vasuratna *

Kaesorn Vajarapongse * Darunee Boonjunwetwat *

Vajragupta L, Vasuratna B, Vajarapongse K, Boonjunwetwat D. Ultrasonographic findings of pancreatic carcinoma. Chula Med J 1993 Oct; 37 (10) : 609-618

The ultrasound examinations of 43 patients with proven adenocarcinoma of pancreas were reviewed. Pancreatic masses were detected in 33 patients. Pancreatic duct and biliary tract obstruction were seen in 20 and 33 patients respectively. Liver metastasis were identified in 10 patients and missed in 10, while regional lymphadenopathy were detected in 14 and missed in 12. Each of portal vein involvement, psoas muscle metastasis and ascites were seen. There was one patient whose ultrasound study was normal. The accuracy rate was 76.7%. The usefulness of ultrasonography as the primary and effective method of investigation is discussed.

Key words : *Pancreatic carcinoma, Ultrasound of pancreas*

Reprint request : Department of Radiology, Faculty of Medicine, Chulalongkorn University, Bangkok 10330, Thailand.

Received for publication. September 8, 1993.

ลัดดาวัลย์ วัชรคุปต์, บุญญาภรณ์ วสุรัตน์, เกษร วัชรพงศ์, ครุณี บุญยืนเวทวัฒน์. ลักษณะทางอัลตราซาวด์ของมะเร็งตับอ่อน. จุฬาลงกรณ์เวชสาร 2536 ตุลาคม; 37(10) : 609-618

ผู้รายงานได้ทำการศึกษาลักษณะทางอัลตราซาวด์ของผู้ป่วยที่เป็นมะเร็งตับอ่อน 43 ราย พบว่าเป็นก้อนที่ตับอ่อน 33 ราย มีการอุดตันของท่อตับอ่อนและระบบทางเดินน้ำดี 20 ราย และ 33 รายตามลำดับการลุกลามของมะเร็งตับอ่อนมาที่ตับ 10 ราย และวินิจฉัยไม่ได้ 10 ราย ในขณะที่พบว่าการลุกลามมาที่ต่อมน้ำเหลืองข้างเคียง 14 ราย แต่วินิจฉัยไม่ได้ 12 ราย นอกจากนี้ยังพบว่าการลุกลามของมะเร็งตับอ่อนเข้าไปในหลอดเลือดดำของตับ (portal vein) กล้ามเนื้อไสแอส (psoas muscle) และน้ำในช่องท้องอย่างละ 1 ราย มีผู้ป่วย 1 รายที่มีผลการตรวจด้วยอัลตราซาวด์ปกติ ความแม่นยำของการศึกษานี้คือ 76.7%

ประโยชน์ของการใช้อัลตราซาวด์ในการตรวจวินิจฉัยมะเร็งตับอ่อนอย่างมีประสิทธิภาพเป็นอันดับแรกจะอภิปรายในรายละเอียด

October 1993

Most patients with pancreatic carcinoma are diagnosed when the tumors are not resectable. Many modalities have been used to diagnose and stage pancreatic carcinoma, including ultrasonography (transabdominal or endoscopic), computed tomography, angiography, endoscopic retrograde cholangiopancreatography and percutaneous transhepatic cholangiography. Ultrasonography is recognized as a sensitive test for diagnosing carcinoma of the pancreas although accuracy is limited by the operator's expertise and the subject's excess bowel gas or obesity. The primary pancreatic tumor has been detected with 69 to 94 percent sensitivity and with 82 to 99 percent specificity.⁽¹⁻³⁾

In this study, we have reviewed ultrasound examinations of 43 patients with proven adenocarcinoma of pancreas in order to see the spectrum of ultrasonographic findings and evaluate the usefulness of ultrasound.

Material and methos

Between Jan. 1, 1987 and Dec. 31, 1991, there were 64 patients of biopsy or surgical-proven pancreatic

adenocarcinoma but 43 ultrasound examinations were available for reviewing. Of the 43 patients, the average age was 56 years with the range of 29-84 years; 19 were men and 24 were women. The presenting symptoms included jaundice (69.77%), weight loss (58.14%), palpable mass (18.6%), abdominal pain (53.49%) and hepatomegaly (34.88%).

All of the ultrasound studies were performed with real-time equipment, 3.5 MHz transducer.

Results

Masses were visualized in 33 of 43 patients; the sites were the head of pancreas in 25 (75.8%), the body in 1, the tail in 2 and combined head and body in 5 (figure 1). The size of the masses ranges from 2-9.5 cm; the largest one is located at the tail of pancreas (table 1). The masses appear to be hypoechoic 64.5 percent, hyperechoic 19.4 percent and isoechoic 16.1% (figure 2). The pancreatic duct was demonstrated to be dilated in 20 patients (figure 3). The accuracy rate of our study was 76.7% (33/43)

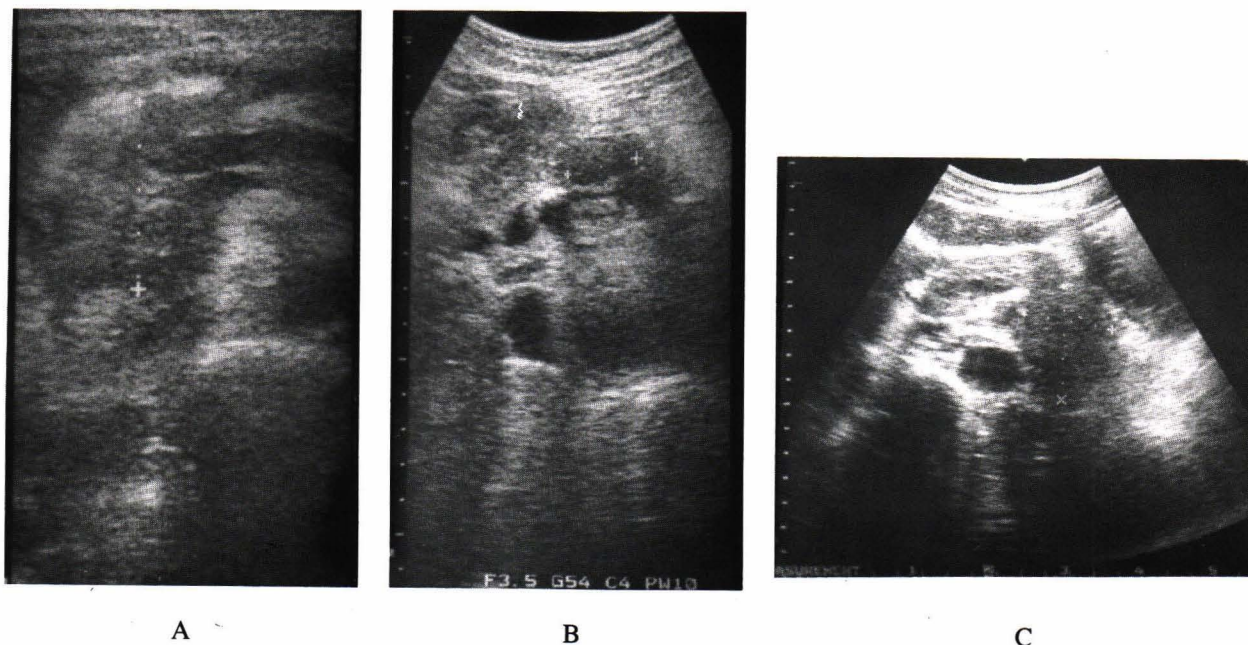


Figure 1. Pancreatic masses.

- (A) An ill-defined mass at pancreatic head was noted with associated dilated pancreatic duct.
- (B) A well-defined mass at body of pancreas was seen.
- (C) Irregular mass at pancreatic tail, continuity with the body was clearly demonstrated.

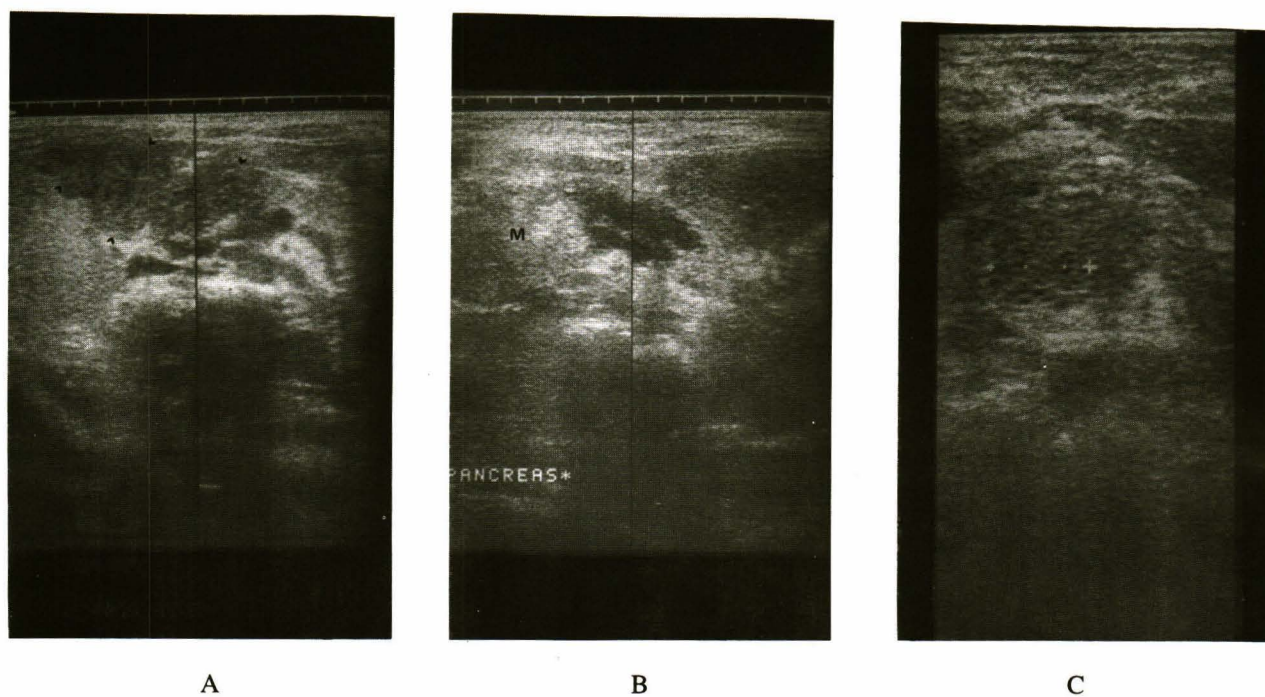


Figure 2. (A) Ultrasonogram of pancreatic region showed irregular hypoechoic mass at head of pancreas with extension to the periportal region (arrowhead)
 (B) An ill-defined hyperechoic mass (M) at pancreatic head with also marked dilatation of the pancreatic duct were depicted.
 (C) Between markers was an isoechoic mass at pancreatic head.

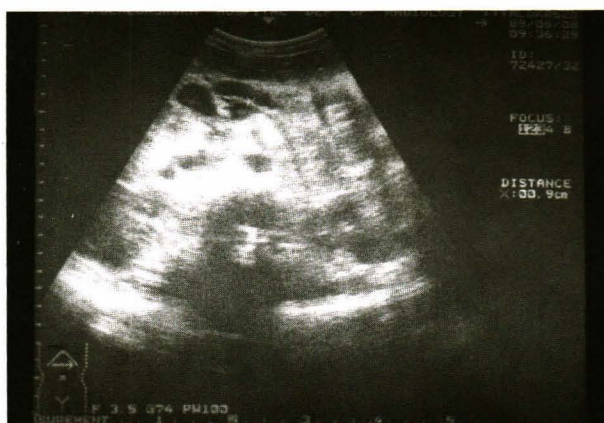

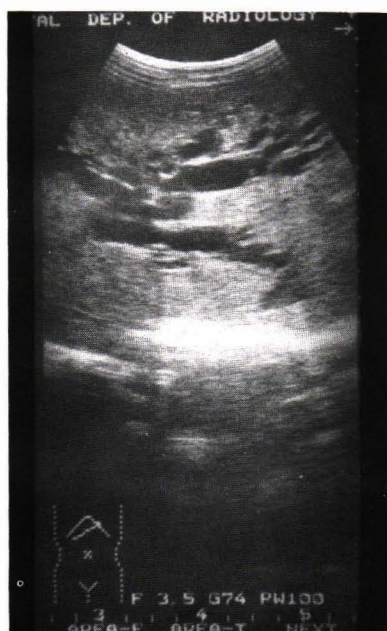Figure 3. Dilated pancreatic duct. The pancreatic duct dilatation was clearly visualized, measured 9 mm. The pancreatic mass was not demonstrated in this figure.

Table 1. Tumor location and size.

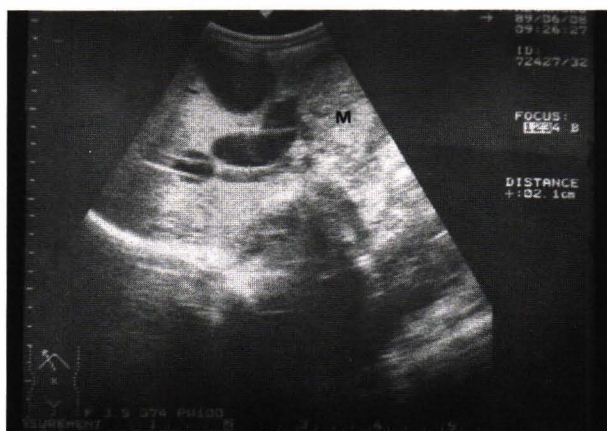
Tumor Location	Number	Tumor size (cm)		
		< 3	3-6	> 6 (exact size)
Head	25	5	19	1 (8)
Body	1	1	-	-
Tail	2	-	1	1 (9.5)
Head + Body	5	-	4	1 (6.5)
Total	33	6	24	3

Biliary tract obstruction (dilated common bile duct greater than 8 mm in diameter or dilated intrahepatic ducts or both) was present in 33 patients (figure 4); 24

with visualized mass (72.73%) and 3 with irregular contour of pancreas (figure 5) and 6 without demonstrable parenchymal abnormality (table 2,3).



A



B

Figure 4. Biliary tract obstruction.

- (A) Moderately severe dilatation of the intrahepatic bile duct was noted.
- (B) There was marked dilatation of the common bile duct with abrupt ending at the pancreatic mass on the right side of the figure (M).

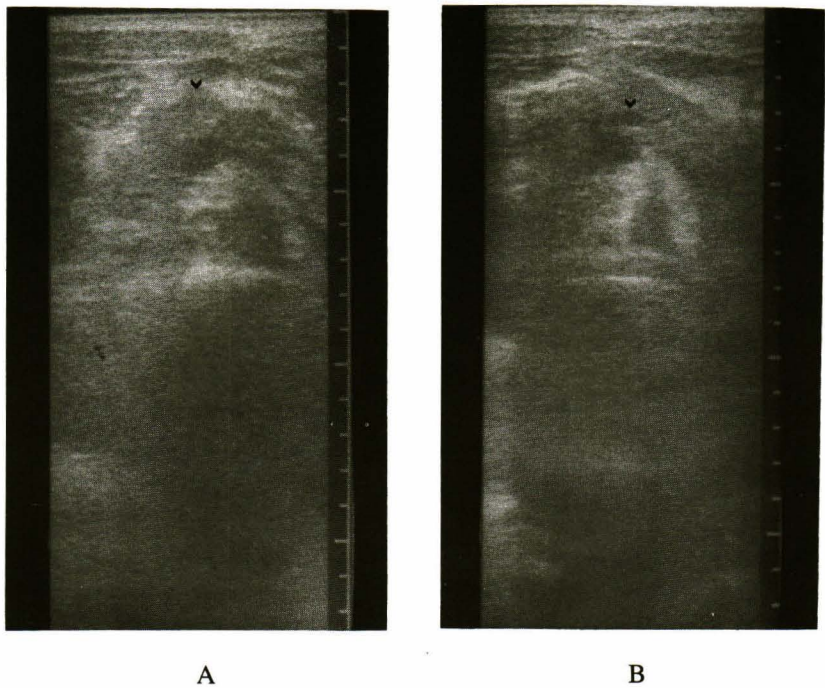


Figure 5. (A) There was mild lobulation of the contour of pancreas without definite mass (arrowhead).
(B) However, slightly moving the transducer showed evidence of pancreatic duct dilatation (arrow head). There was also evidence of biliary tract obstruction in this patient (not shown).

Table 2. Summary of other ultrasonographic findings.

Parenchymal abnormalities	Mass (33)	Lobulate contour (3)	No visualized parenchymal abnormality (7)*
Other signs			
Dilated pancreatic duct	17	-	3
Biliary tract obstruction	24	3	6
Liver metastasis	9	-	1
Regional adenopathy	10	2	2

* One normal study.

Table 3. Summary of primary and secondary signs.

Findings	Number	Percent
Normal	1	2
Tumor identified	9	21
Secondary signs only	9	21
Tumor and secondary signs	24	56

October 1993

Liver metastasis were present in 10 of 43 patients (23.26%). Most hepatic metastasis were hypoechoic and no calcification was noted within lesion (figure 6).

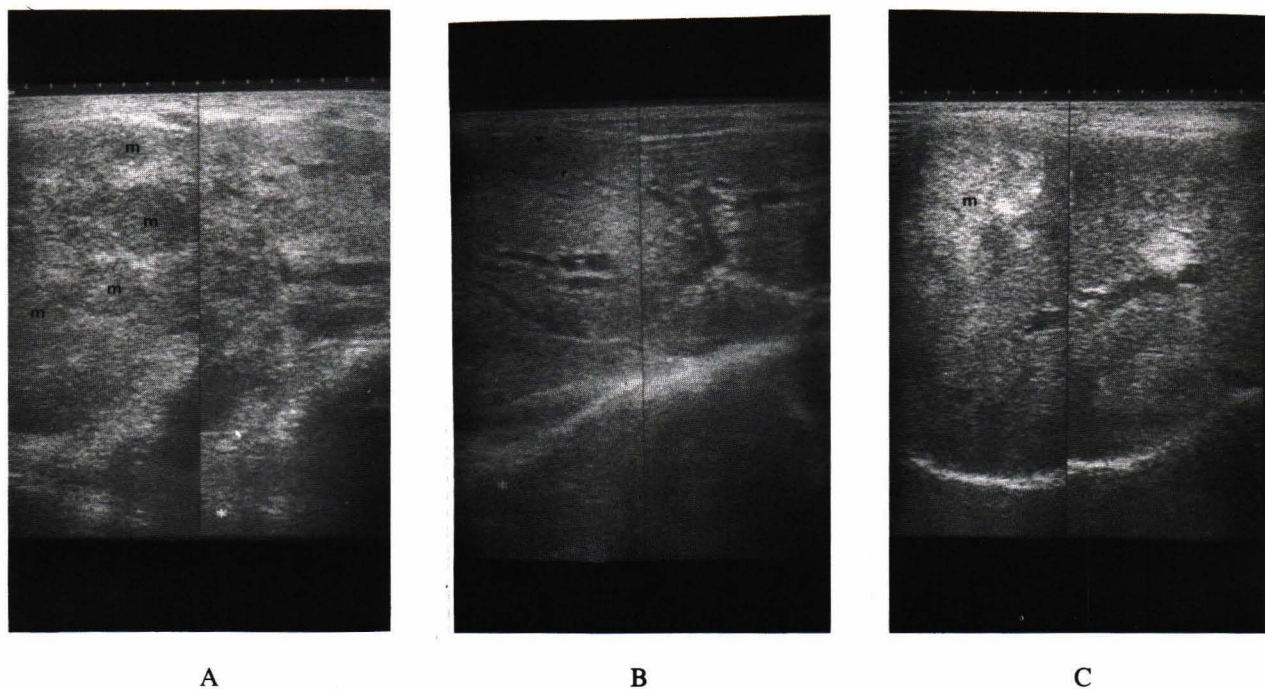


Figure 6. Liver metastasis.

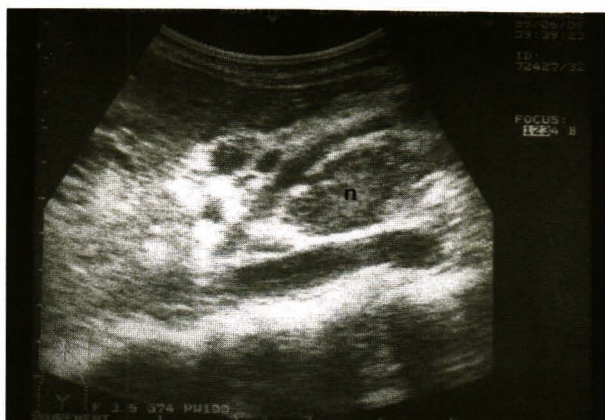(A) Most hepatic metastasis was hypoechoic lesion.

(B) Some appeared as target lesions.

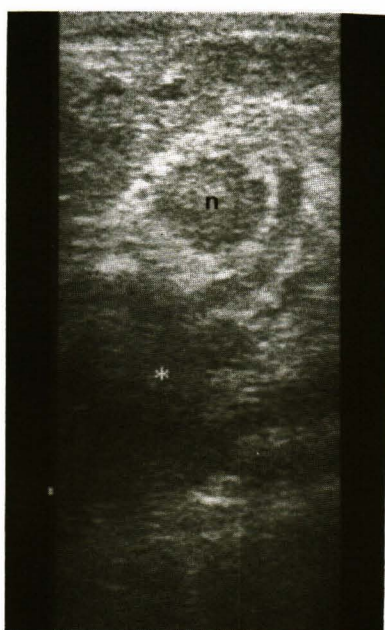(C) Hyperechoic metastasis was also found but less common.

Lymphadenopathy was identified at ultrasound studies in 14 patients (32.56%). These enlarged nodes were seen as well-defined round or ovoid hypoechoic masses and found located around the aorta in six patients, at the area of celiac axis in two and at periportal and

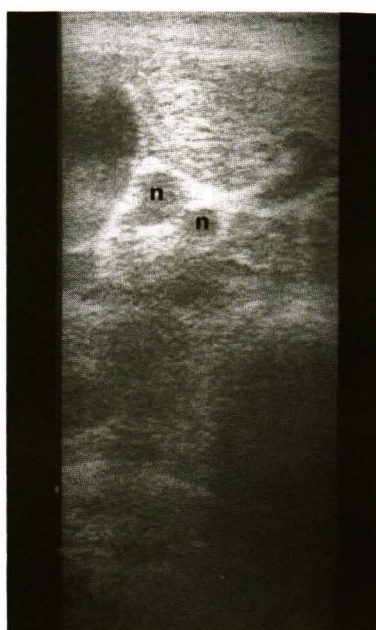
peripancreatic region in three equally (figure 7). During surgery, ten more liver metastasis and twelve more regional lymphadenopathy which were not detected by ultrasound were identified.



A



B



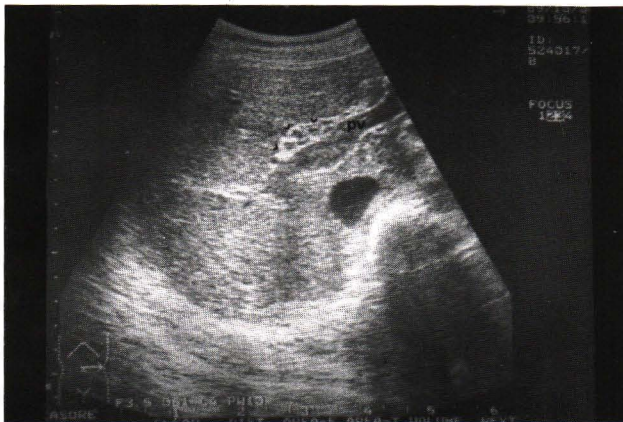C

Figure 7. Lymphadenopathy (N) was found in various sites;

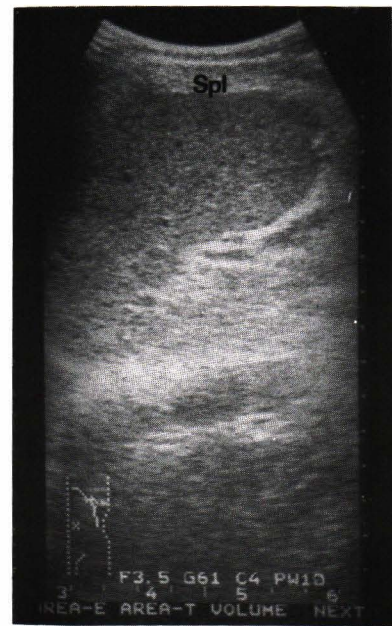- (A) paraaortic region
- (B) peripancreatic region
- (C) periportal region

Ascites, portal vein thrombosis with cavernous transformation and metastasis to right psoas muscle were identified in each patient (figure 8,9). Of

the 43 patients, there was one normal study that infiltrative lesion at the body and tail of pancreas were revealed during operation.



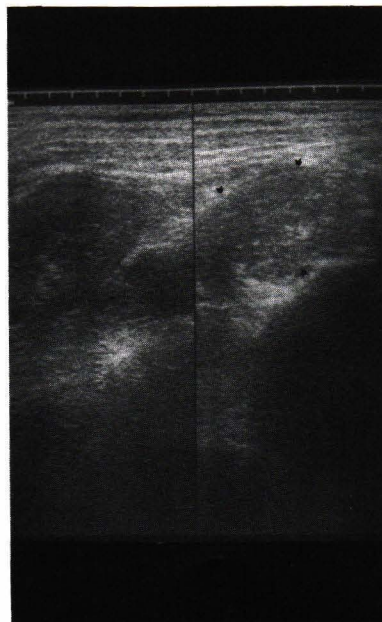A



B

Figure 8. Portal vein thrombosis.

- (A) There was echogenic thrombus in the portal vein (PV) with evidence of cavernous transformation nearby (arrowheads).
- (B) Splenomegaly as sign of portal hypertension was noted in this same patient.

**Figure 9.** There was enlargement of right psoas muscle (arrowheads) which biopsy-proven to be metastatic pancreatic carcinoma.

Discussion

Ultrasound is well accepted as the imaging modality of choice in assessment of the upper abdomen because it is less expensive, most readily available and can be performed in less than 30 minutes.^(3,4) However, there are some limitations as well; it is operator-dependent and limited by excess bowel gas or individual's obesity. In our study, 4 of 9 patients without demonstrable mass by ultrasound were found to have pancreatic masses ranging from 3-7 cm. during surgical exploration. The excess bowel gas can be overcome by scanning in "erect gastric window" technique (an erect sitting position with fluid-fluid- stomach), or the aid of water and glucagon.^(5,6)

In this study ultrasound proved to be very useful in the detection of pancreatic tumor as well as in the evaluation of the extent of disease. Pancreatic masses were detected in 75.8%. The smallest pancreatic tumor detected in this study was 2 cm in diameter. Of all the patients with unidentified mass, the secondary changes were found; evidence of biliary obstruction in all. However, these secondary findings without definite abnormality in the pancreatic region can also be produced by other lesions such as cholangiocarcinoma. With lobulated contour of the pancreas and some focal masses, differentiation from inflammatory mass cannot be certain sometimes.⁽⁷⁾ Ultrasound guided percutaneous fine needle aspiration biopsy performed on an outpatient basis, is useful to confirm the diagnosis and the patients never require hospitalization or more costly investigation.⁽⁸⁾ Liver metastasis and regional lymphadenopathy were underestimated. The moderately to severely dilated intrahepatic bile ducts probably obscured the hepatic metastasis which were mostly hypoechoic lesions.

Many studies reported sensitivity and specificity for computed tomography to be superior to that of ultrasound.^(1,9,10) However better results with ultrasound were achieved by Paivansalo et al.⁽¹¹⁾ In some cases, CT findings may be inconclusive and ultrasonography may offer complementary information with its ability to detect changes of parenchymal echotexture.⁽¹²⁾ The accuracy rate of our study was 76.7%

Since patient with carcinoma of pancreas has a limited life expectancy following diagnosis, a rapid and complete diagnostic work up is important. We agree that ultrasound should be the primary imaging modality for the pancreas and may obviate the need for more costly CT in some cases.^(8,13) However, in patient with normal ultrasound examination or unable to demonstrate pancreas especially at the head region due to overlying bowel gas but with high probability of pancreatic tumor, other investigations such as endoscopic retrograde cholangiopancreatography (ERCP) or computed tomography (CT) should be performed.

References

1. Hessel SJ, Seigelman SS, McNeil BJ, Sanders R, Adams DF, Alderson PO, Finberg HJ, Abrams HL. A prospective evaluation of computed tomography and ultrasound of the pancreas. *Radiology* 1982 Apr; 143(1) : 129-33
2. Taylor KJW, Buchin PJ, Viscomi GN, Rosenfield AT. Ultrasonographic scanning of the pancreas. *Radiology* 1981 Jan; 138(1) : 211-3
3. Pollack D, Taylor KJW. Ultrasound scanning in patients with clinical suspicion of pancreatic cancer : a retrospective study. *Cancer* 1981 Mar 15 Suppl; 47(6) : 1662-5
4. Cohen MM, Switzer PJ, Cooperberg PL. Sensitivity of ultrasonography in the diagnosis of pancreatic cancer. *Can Med Assoc J* 1979 Feb 14; 120(4) : 453-5
5. MacMahon H, Bowie JD, Beezhold C. Erect scanning of pancreas using a gastric window. *AJR* 1979 Apr; 132(4) : 587-91
6. Op den Ortho JO. Sonography of the pancreatic head aided by water and glucagon. *Radiographics* 1987; 7 : 85-100
7. Neff CC, Simeone JF, Wittenberg J, Mueller PR, Ferrucci JT Jr. Inflammatory pancreatic masses : problems in differentiating focal pancreatitis from carcinoma. *Radiology* 1984 Jan; 150(1) : 35-8
8. Campbell JP, Wilson SR. Pancreatic Neoplasms. How useful is evaluation with US? *Radiology* 1988 May; 167(2) : 341-4
9. Husband JE, Meire HB, Kreel L. Comparison of ultrasound and computed-assisted tomography in pancreatic diagnosis. *Br J Radiol* 1977 Dec; 50(600) : 855-62
10. Kamin PD, Bernadino ME, Wallace S, Jing BS. Comparison of ultrasound and computed tomography in the detection of pancreatic malignancy. *Cancer* 1980 Dec 1; 46(11) : 2410-2
11. Paivansalo M, Lahde S. Ultrasonography and computed tomography in pancreatic malignancy. *Acta Radiologica* 1988; 29 : 343-4
12. Ormson MJ, Charboneau JW, Stephens DH. Sonography in patients with possible pancreatic mass shown on CT. *AJR* 1987 Mar; 148(3) : 551-5
13. Shawker TH, Garra BS, Hill MC, Doppman JL, Sindelar WF. The spectrum of sonographic findings in pancreatic carcinoma. *J Ultrasound Med* 1986 Mar; 5(3) : 169-77