

12-1-1975

What is your diagnosis

P. Tuntivanich

Follow this and additional works at: <https://digital.car.chula.ac.th/tjvm>



Part of the [Veterinary Medicine Commons](#)

Recommended Citation

Tuntivanich, P. (1975) "What is your diagnosis," *The Thai Journal of Veterinary Medicine*: Vol. 5: Iss. 4, Article 2.

DOI: <https://doi.org/10.56808/2985-1130.3453>

Available at: <https://digital.car.chula.ac.th/tjvm/vol5/iss4/2>

This Article is brought to you for free and open access by the Chulalongkorn Journal Online (CUJO) at Chula Digital Collections. It has been accepted for inclusion in The Thai Journal of Veterinary Medicine by an authorized editor of Chula Digital Collections. For more information, please contact ChulaDC@car.chula.ac.th.

What is your diagnosis

* P. Tuntivanich D.V.M.,M.S.(in Rad)

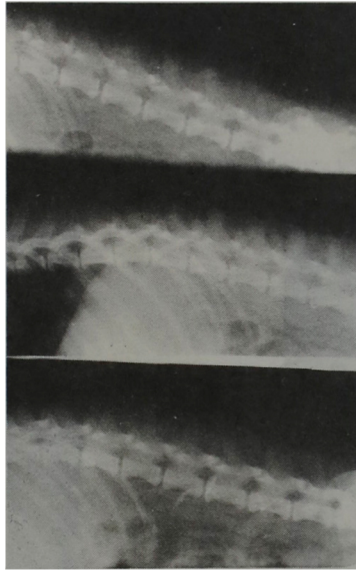


Fig. 1 Spot film of thoraco - lumbar region

History A male, mixed breed dog about six years old, was brought to small animal hospital, Faculty of Veterinary Science , Chulalongkorn University with the history of paralysis of both hind limbs, for one week. On palpation revealed no motor reflex but still have sensory reflex on both hind limbs

Radiograph was taken (Fig. 1)

Give your diagnosis and turn to page ..803.....

* Department of Veterinary Surgery, Faculty of Veterinary Science Chulalongkorn University.