

12-1-1993

Proliferating acephalic cestode larva of central nervous system

Pracha Chayapum

Kobkul Tungsinmunkong

Samruay Shuangshoti

Follow this and additional works at: <https://digital.car.chula.ac.th/clmjournal>



Part of the [Medicine and Health Sciences Commons](#)

Recommended Citation

Chayapum, Pracha; Tungsinmunkong, Kobkul; and Shuangshoti, Samruay (1993) "Proliferating acephalic cestode larva of central nervous system," *Chulalongkorn Medical Journal*: Vol. 37: Iss. 12, Article 6.

DOI: 10.58837/CHULA.CMJ.37.12.6

Available at: <https://digital.car.chula.ac.th/clmjournal/vol37/iss12/6>

This Case Report is brought to you for free and open access by the Chulalongkorn Journal Online (CUJO) at Chula Digital Collections. It has been accepted for inclusion in Chulalongkorn Medical Journal by an authorized editor of Chula Digital Collections. For more information, please contact ChulaDC@car.chula.ac.th.

Proliferating acephalic cestode larva of central nervous system

Pracha Chayapum*

Kobkul Tungsinnmunkong** Samruay Shuangshoti***

Chayapum P, Tungsinnmunkong K, Shuangshoti S. Proliferating acephalic cestode larva of central nervous system. Chula Med J 1993 Dec; 37(12) :743-750

We reported two cases of racemose cysticerci (proliferating acephalic cestode larvae) affecting the central nervous system of two men aging 33 and 36 years respectively. In case 1, the lesion was in the basal subarachnoid space of brain (cerebellopontine angles) and in the thoracic spinal subarachnoid space. In case 2, the lesion lay in the basal subarachnoid space of the brain. Within a cavity as in the cerebral ventricle or subarachnoid space, a cysticercus cellulosae may be expanded and wrinkled to resemble a bunch of grapes, the so-called cysticercus racemosus. Basal cysticercosis of the brain may create clinical manifestations imitating tuberculous meningitis because of involvement of multiple cranial nerves.

Key words : Cysticercosis, Brain, Spinal cord, Central nervous system, Subarachnoid space.

Reprint request : Chayapum P, Department of Surgery, Yala Hospital, Yala province 95000, Thailand.

Received for publication. October 1, 1993.

* Department of Surgery, Yala Hospital, Yala province 95000.

** Department of Pathology, Faculty of Medicine, Prince of Songkhla University. Songkhla Province 90112.

*** Department of Pathology, Faculty of Medicine, Chulalongkorn University Bangkok 10330.

ประชา ชยาภิรม, กอบกุล ตั้งสินมั่นคง, สำราญ ช่างโชติ. โปริเฟอเรติง อเซฟาลิก เซสโทด ลาร์ว่า
ของระบบประสาทส่วนกลาง. จุฬาลงกรณ์เวชสาร 2536 ธันวาคม; 37(12) : 743 - 750

เทอมโปริเฟอเรติง อเซฟาลิก เซสโทด ลาร์ว่า มีความหมายเช่นเดียวกับเรซีโมส ซิสติเซอรัคส์ เป็นซิสติเซอรัคส์ที่ไม่มีสโคเลกซ์ จึงผิดไปจากรูปร่างของซิสติเซอรัคส์เซลลูโลเซ ที่มีสโคเลกซ์ เรซีโมส ซิสติเซอรัคส์ พบน้อยกว่าซิสติเซอรัคส์ เซลลูโลเซ ได้รายงานผู้ป่วยชายไทย 2 ราย อายุ 33 และ 36 ปี ตามลำดับ รายที่ 1 มีซิสติเซอรัคส์ เรซีโมซัส ที่ช่องใต้ชั้นนอแรคนอยด์ของไขสันหลังระดับอกและแอ่งระหว่างเซเรเบลลัมกับพอนส์ รายที่ 2 มีเรซีโมส ซิสติเซอรัคส์ อยู่ในช่องใต้ชั้นนอแรคนอยด์ที่ฐานของพอนส์ ภายในช่องว่าง เช่น ในช่องใต้ชั้นนอแรคนอยด์หรือโพรงสมอง (เวนตริเคิล) ส่วนถุง (แบล็ดเดอร์) ของซิสติเซอรัคส์ อาจพองโตและบิดเบี้ยวเป็นกลุ่มถุงคล้ายพวงองุ่น ส่วนสโคเลกซ์มักสลายตัวไป หรือยากที่จะหาพบ เป็นที่น่าสังเกตว่าผู้ป่วยรายที่ 2 ซึ่งมีถุงพยาธิวิทยาที่ฐานสมองนั้นให้อาการคล้ายกันมากกับวัณโรคของเยื่อหุ้มสมอง จนเกิดการวินิจฉัยคลาดเคลื่อนทางคลินิก จึงควรระมัดระวังที่จะต้องแยกจากกันให้ดี เพื่อการรักษาที่ถูกต้อง

The adult tapeworm infection in human beings is exclusively in the gastrointestinal tract.⁽¹⁾ There were only two reported extragastrointestinal locations of strobilate tapeworm in human. One was in the subcutaneous tissue of a woman in Japan.⁽²⁾ The other was in the spinal cord of a man in Thailand.⁽³⁾ The human cestode larval infections found in Thailand are sparganosis, cysticercosis, and hydatid cyst.⁽¹⁾ Cysticercosis is far outnumbers the other two but is seldom reported because of its commonness. The central nervous system (CNS) cestode larval infections in Thailand are cysticercosis, and three cases of sparganosis.⁽⁴⁻⁶⁾

Cysticercus is probably the most common cystic lesions in the CNS.⁽⁷⁾ It is the larval infection of *Tenia solium*, the pork tapeworm. There are two forms : *cysticercus cellulosae* and *cysticercus racemosus*. The more common *cellulosae* form is a fluid-filled bladder that contains the invaginated head (scolex) of the larva. The *racemosus* form is a proliferating form of the larval tapeworm that consists of multiple interconnected bladders of different sizes that lack scolices. Racemose cysticerci are believed to be aberrant cysticerci of *Tenia solium* or other species of cestode larvae such as *Multiceps multiceps*, and *Multiceps serialis*.⁽⁷⁾

In the proliferating form of the cestode larval infection, the scolex usually cannot be identified; so the term proliferating acephalic cestode larva is used.⁽⁸⁾ In a review of acephalic cestode larva in man, Beaver and Rolon⁽⁸⁾ recognized three distinct types namely sparganum proliferum, *cysticercus racemosus*, and undifferentiated sparganum or tetrathyridium. In no case, however, can the parasite be identified as the larval stage of a recognized species that have been known, or yet to be discovered.⁽⁸⁾

In Thailand, there were two reported cases of *cysticercus racemosus*; the lesions in both instances were removed from the fourth ventricles.⁽⁹⁾ A case was initially diagnosed as a sparganum-like parasite of the brain.^(10,11) After personal consultation with P.C. Beaver, the diagnosis of racemose cysticercus was considered.⁽¹⁾ We are adding two more cases of *cysticercus racemosus* of the brain found in Thailand because of its uncommonness.

Case 1.

This example was previously presented at the International Congress of Neurological Surgery being held by the World Federation of Neurosurgical Societies on October 17-22, 1993 at Acapulco in Mexico.

A 33-year-old male Thai school teacher, the native of Yala province, came from a family of fruit and rubber plantation. He exposed to dogs, cats, pigs and cows as well as to untreated water tapped from a waterfall. He often joined parties with rubber plantation workers where he enjoyed consuming alcohol and uncooked foods. He, nevertheless, was in good health until in 1990 when he first had back pain radiating to buttock and leg on the right side and was aggravated by lifting. Sometimes he felt numbness in the right leg. He was treated symptomatically for disorder of the lumbar disc. In May 1991, he had diplopia when he looked toward the right side, anxiety, insomnia, and weight loss. In September 1991, diplopia disappeared spontaneously. He, however, complained about weakness of the lower limbs. A month later, he was hospitalized because of severe low back pain.

On physical examination, there was mild lateral rectus palsy. Straight leg raising test was 90° bilaterally. Sensation was intact to both pinprick and fine touch. The motor power of legs was weak from iliopsoas downward with muscular atrophy. He could walk with the aid of a walker. Hyporeflexia was noted in his upper extremities. The lower limbs showed areflexia. There was no response in Babinski's test.

Laboratory studies showed 43% of hematocrit, 8,050 leucocytes/mm³ with 51% neutrophils, 10% eosinophils, 1% basophils, and 38% lymphocytes.

After 2 weeks of hospitalization his hearing was decreased in the left ear. An audiometry revealed moderate sensorineural hearing loss in this ear.

Myelography yielded a dry tap. So cisterna puncture through C_{1,2} was performed. The clear and colorless CSF contained 35 mg/100 ml of protein, and 54 mg/100 ml of sugar, but no leukocytes. A repeated myelography showed a small extramedullary subdural defect at the right side of the dural sac at T₆ and complete block at T₁₁ (Fig.1).

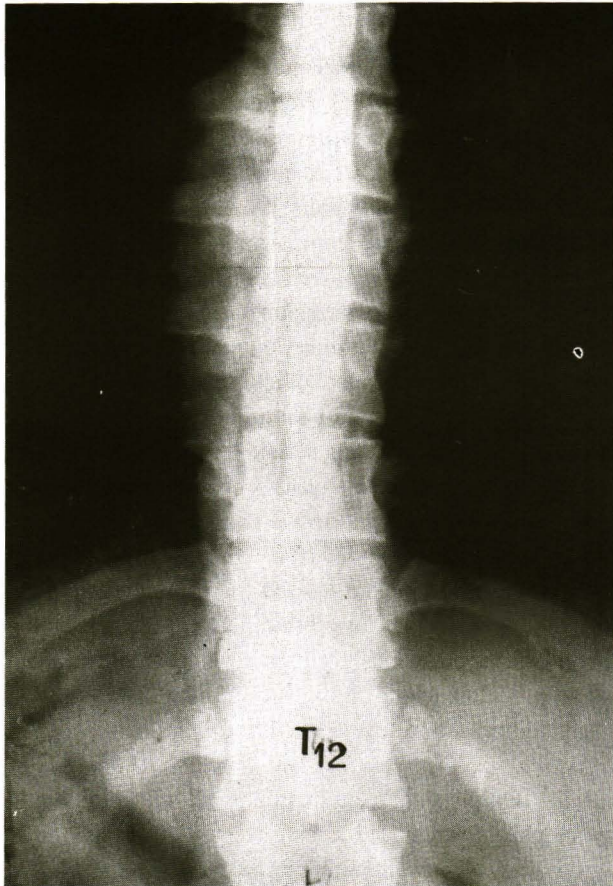


Figure 1. (case 1). Myelography demonstrating a small extramedullary subdural defect of the radiopaque column at T₆ on the right side and complete blockage of the radiopaque column at T₁₁. Note T₁₂.

The magnetic resonance imaging (MRI) of the thoracic and lumbar levels of the spine exhibited a ring appearance at T₁₁, and there was an evidence of abnormal flow of the CSF below the lesion. The findings corresponded well with the myelographic study. The MRI of the brain demonstrated two lesions (Fig. 2). One was at the right cerebellopontine (CP) angle extending to the brainstem and measuring 3.4 x 2.5 cm; another smaller lesion was at the left CP angle. The fourth ventricle was partly obliterated. The third and lateral ventricles were dilated.

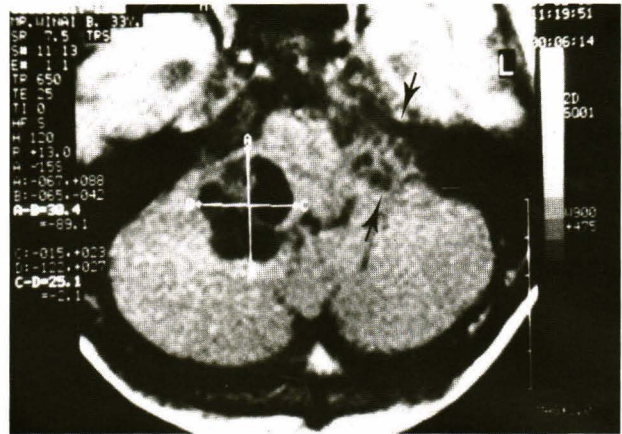


Figure 2. (case 1). MRI of brain showing lesion in each cerebellopontine angle. The large right one is marked by two cross lines (AB and CD). The small left one is between the the arrows. The partially obliterated fourth ventricle lies between two lesions.

A total laminectomy from T₁₀ to T₁₂ disclosed the spinal cord to be wrapped around by chalky fat-like tissue and an encapsulated lesion, 1 cm across at T₁₁ which corresponded with the findings on myelographic blockage and MRI ring appearance. The lesion and chalky tissue were removed.

Histopathologically, the encapsulated lesion was a cystic organism provoking intense granulomatous reaction (Figs. 3-6). Eosinophils were present but not prominent. The worm possessed an eosinophilic homogeneous tegument (syncytium or cuticle), 5 to 10 microns in thickness. Beneath the tegument was nuclear layer of tegumental gland cells. Smooth muscle fibers were rare. The stroma was composed of loose meshes of mesenchymal cells, and connective tissue fibers, interspersed by calcareous bodies and vesicles (lacunae). After careful study, it was concluded that the worm represented a bladder of proliferating cestode larva without scolex (racemose cysticercus) of the spinal cord.

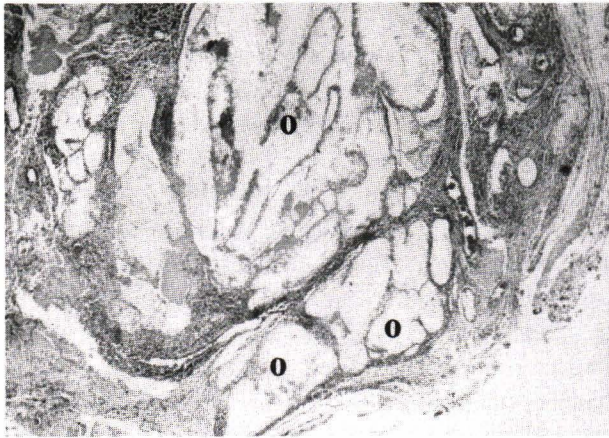


Figure 3. (case 1). Photomicrograph of low magnification showing folded cystic organism (O) being surrounded by dark zone of inflammatory reaction.

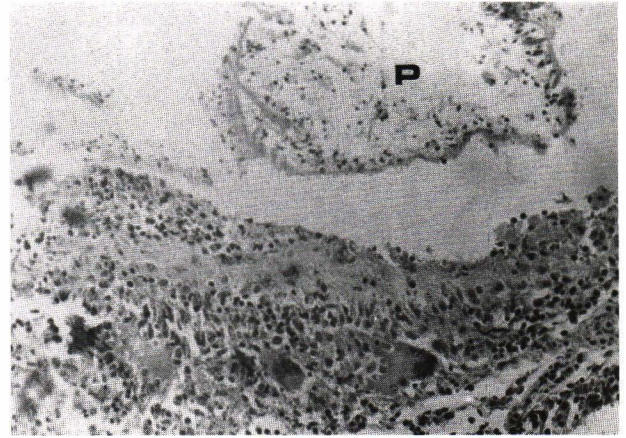


Figure 4. (case 1). Photomicrograph at medium magnification showing granulomatous reaction consisting mainly of histiocytes and foreign body giant cells. A piece of parasite (P) lies above the granuloma.

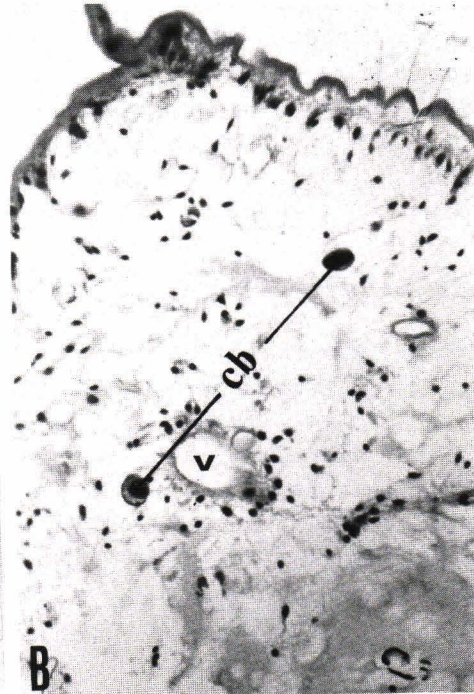
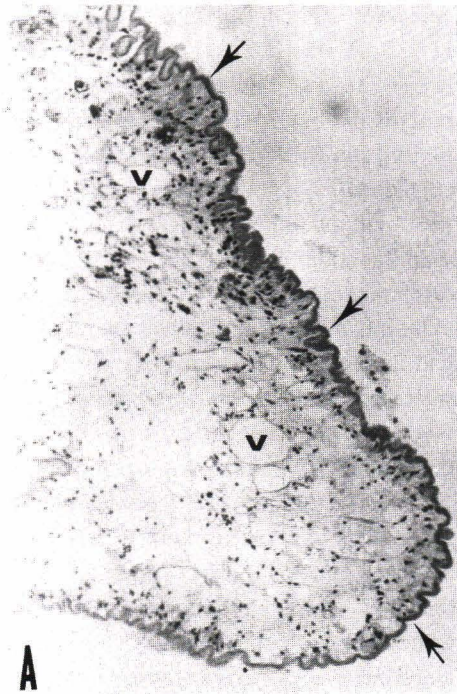

Figure 5. (case 1). Histopathology of cysticercus. A. Three layers of body of parasite are shown. The outer convoluted eosinophilic layer (arrow) is the tegument. The intermediate layer is composed of small, round, dense nuclei of tegument gland cells. The inner layer consists of mesenchymal cells and loose connective tissue fibers interspersed by vesicles (v) or lacunae. B. Distinctive tegument, subjacent tegument gland-cell nuclear layer, loose connective tissue layer, and calcareous bodies (cb) are demonstrated at higher magnification. Again noted vesicle (v).

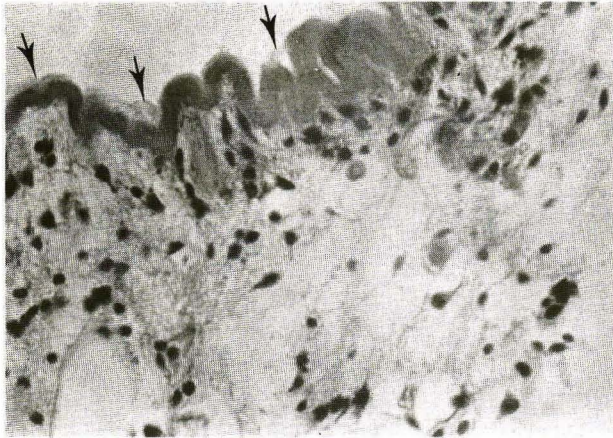


Figure 6. (case 1). Cysticercus showing fine surface processes or microvilli (arrows) on the external aspect of the convoluted tegument at higher magnification.

Postoperatively, the patient was improved in motor power. One month later, however, his motor power and hearing deteriorated again.

In March 1992, a right suboccipital craniectomy was done and the lesion was excised subtotally to relieve the ventricular obstruction. It was also verified as cysticercus of racemose type.

Besides surgical treatment, antihelminthic drugs (yomesan, praziquantel, and mebendazole) were also given.

The patient was eventually deaf bilaterally. There were additional right facial palsy of lower motor neuron type, hoarseness of voice, paraparesis, and neurogenic bladder. He received physiotherapy, occupational therapy, and other supportive regimens with little improvement. He was followed up monthly until March 1993 he aspirated food and died. The total course of his ailment was about 3 years.

Case 2.

This instance was briefly mentioned previously by Pradatsundarasar.⁽¹⁾ A 36-year-old Thai man, the native of Kampangpej province, was hospitalized with blurred vision in the right and left eyes for 6 and 3 months respectively. Additionally, he complained of severe generalized headache without vomiting. Two weeks before hospitalization, he developed mental confusion.

Upon hospitalization, the patient walked with ataxic gait. Divergent squint was present at rest. He was unable to converge his eyes. The right palpebral fissure was smaller than usual. Hypalgesia and weakness were noted on his right face. Fundoscopy revealed bilateral papilledema and atrophic optic discs. There was

stiffness of the neck.

Bilateral carotid angiographies disclosed enlargement of all cerebral ventricles. Pneumoencephalography revealed dilated third ventricle without evidence of obstruction.

Hemoglobin was 11 gm/100 ml. A leukocyte count showed 12,000 cells/mm³ with 65% neutrophils, 10% eosinophils, and 25% lymphocytes. Blood sugar was 74 mg/100 ml. A ventricular puncture disclosed clear and colorless CSF with a pressure of 250 mm of water. It contained 8 cells (3 neutrophils and 5 lymphocytes) /mm³, 25 mg/100 ml of protein, and 22 mg/100 ml of sugar. A lumbar puncture exhibited very slow flowing of the clear and colorless CSF which contained 4 cells (1 neutrophil and 3 lymphocytes) /mm³, 25 mg/100 ml of protein, and 61 mg/100 ml of sugar. Only a few drops of the CSF were obtained in a repeated lumbar puncture a few days later. The pressure of the CSF could not be measured. The fluid contained 400 cells/mm³ with 90% lymphocytes and 10% neutrophils.

With evidence of involvement of multiple cranial nerves, it was believed that the patient had a lesion at the base of the brain. The clinical diagnosis of tuberculous meningitis with communicating hydrocephalus was considered. The patient, then, received full antituberculous treatment including steroids. About 2 months in the hospital, he complained about hard hearing in the right ear. Streptomycin was then no longer given to him. Up to that time, the patient received 39 gm of streptomycin. He had also occasional fever. Penicillin and chloramphenicol were then added. His clinical course was progressively worsening. His mentality became dull. Finally he died in coma after 3.5 months of hospitalization.

At autopsy, the leptomeninges at the base of brain were covered by thick layers of gray and friable exudate. The optic nerves and tracts were also covered by the latter. Coronal sections of a 1,530-gm brain disclosed symmetrical hydrocephalus of all ventricles. The grey and white matters were congested. The spinal dura mater, leptomeninges, and spinal cord were congested. The spinal subarachnoid space was filled with grey and friable materials similar to exudated covering the base of brain.

Microscopically, the leptomeninges at the base of pons were the seat of granulomatous inflammation. Fibroblasts, lymphocytes, plasma cells, histiocytes, multinucleated giant cells, and small blood vessels were mingled in the granulomas. Fragments of cysticercus were embedded in the granulomatous exudate and in the substance of pons. The worm fragments folded upon itself and had microscopic features as described in case 1. Cuticle, nuclear layer, and calcareous bodies were identi-

fied. The scolex was not observed. The lesion was regarded as a racemose cysticercus (proliferating acephalic cestode larva) affecting the subarachnoid space at the base of brain.

Discussion

Although cysticercosis is common in Thailand including those affecting the CNS the racemose form of cysticercus is rare. Generally, cysticercosis of the CNS occurs in four varieties according to locations eg parenchymatous, ventricular, meningeal, and a combination of these situations. The latter, for example, may be represented by combined parenchymatous and ventricular forms. When the parasite is floating in the CSF, such as in the subarachnoid space or in the ventricle, it may be expanded, folded, or wrinkle to become grape-like structure, the so-called racemose cysticercus. Examples of CNS cysticercosis reported by Patharangkura et al⁽⁹⁾ are ventricular racemose cysticerci. An instance described by others^(10,11) can be also regarded as cysticercus racemosus of the basal subarachnoid space of the brain as in our current two cases.

Slais⁽¹²⁾ gave an interesting comparison between cysticercosis and intrauterine development of mammals. He compared the cysticercus cellulosae to normal mammalian embryo and cysticercus racemosus to hydatidiform mole. He regarded the racemose cysticercus to represent pathologic cysticercus cellulosae that become degenerated, expanded, and folded which is similar to degenerated placental villi in hydatidiform mole.⁽¹²⁾

It is interesting to note in our case 2 that the lesion was erroneously considered and treated as tuberculous meningitis. This is related to the location of the lesion at the base of brain to resemble typical location of exudate in tuberculous meningitis.⁽¹³⁾ Moreover, the latter is common in Thailand. The erroneous clinical diagnosis and management for tuberculosis, then, may occur when cysticercosis affects the base of brain. It is, then, suggested in such situation that the diagnosis and management should be revised when there is no clinical response to antituberculous treatment.

The discovery of other human cestode larva, especially sparganosis, is increasing in Thailand and far-east.⁽¹⁴⁾ The diagnosis as cysticercosis is simple in a non-proliferating form, especially in the presence of scolex. In case of a proliferating acephalic cestode larva, it is difficult to pin-point the species because we do not know for certain that these larvae will display their normal features while in a state of uncontrolled proliferation. We, however, do believe that a proliferating cysticercus will have a tegument that will vary in thickness from very thin in some places to thick in others, just below the outer

acellular layer of the tegument (syncytium) there is a row of tegumental gland cells (the cells responsible for forming the tegument) that are evident by their relatively large nucleus. When the tegument is thin, these nuclei are scanty, but when the tegument is thick they are more numerous and closer together. Lying between the syncytial layer and the gland-cell nuclei are very small circular and longitudinal muscle fibers. These are usually not noticeable in most histologic preparations. Other muscles are not observed in the bladder wall of normal or proliferating cysticerci, and this is one of the key diagnostic features. Excretory canals are usually present in proliferating cysticerci and may be quite enlarged. They have a lining membrane and this differentiate them from lacunae which lack a lining membrane. Proliferating cysticerci may appear to have a solid body in some sections through smaller portions while they may have a large lacuna and a thin wall in other sections.

In differential diagnosis, proliferating spargana differ from cysticerci in that nearly all sections show a solid body and there are bundles of muscle fibers that run in different directions through the parenchyma. Seldom are lacunae (vesicles) seen and the tegument is generally thick. In human cases, the skin is almost always involved, although other organs may also be invaded.

The tetrathyridium of *Mesocostoides* is similar to the sparganum in that it has a solid body, but the parenchymal muscle fibers are arranged in a circular band that separate the cortical and medullary regions.

Acknowledgements

We are most grateful to Professors Paul C. Beaver and Maurice D. Little who verified the parasites as racemose cysticerci in both patients. Professor Maurice D. Little, moreover, has commented on the histological differential diagnosis among cysticercus, sparganum, and tetrathyridium of *Mesocostoides*. Dr. Samruay Shuangshoti is in receipt of support from the Chulalongkorn Faculty of Medicine-China Medical Board Scholar Development Fund, 1990-1994.

References

1. Pradatsundarasar A. The larval cestode infections in Thailand. Commemoration of the 20th Anniversary of the Faculty of Tropical Medicine, Mahidol University : Bangkok, 1960-1980. 1980 : 136-41
2. Mory Y, Shirayama T, Agui Y, Fujiwara A, Nishiura T. A case of chestwall tumor brought on by *Hymenolepis nana*. Bull Osaka Med Sch 1967 Apr; 13 : 52-4

3. Bamrungphol V, Little MD, Viriyavejakul A, Sujtanond M, Chaiyaporn V. Juvenile strobilate tapeworm from the human spinal cord : report of a case. *Am J Trop Med Hyg* 1972 Jul; 21(4) : 435-9
4. Pongprasert S. Sparganum mansonii combined with cysticercosis cellulosae infected in pontomedullary junction in the same patient, presented with two clinical stages : a case report. *Bull Lampang Hosp* 1985 Sep-Dec; 6(3) : 225-50
5. Promakupt C, Chayapum P. Cerebral sparganosis : a case report. *Med J Ubon Hosp* 1984 Jan-Mar; 5(1) : 1-6
6. Chamadol W, Thanaphaisal C, Tangdumrongkul S, Sithithaworn P, Chamadol N. Intracerebral hemetoma caused by Sparganum ; a case report. *J Med Assoc Thai* 1992 Oct; 75(10) : 602-5
7. Scully RE, Mark EJ, McNeely BU. Case records of the Massachusetts General Hospital. *N Engl J Med* 1993 Feb 25; 328(8) : 566-73
8. Beaver PC, Rolon FA. Proliferating larval cestode in a man in Paraguay : a case report and review. *Am J Trop Med Hyg* 1981 May; 30(3) : 625-37
9. Patharangkura P, Jariya P, Tandhavadhana C. Cysticercus racemosus in the fourth ventricle: report of two cases. *Southeast Asian J Trop Med Public Health* 1980 Dec; 11(4) : 532-4
10. Tangchai P, Suwanwela C, Shuangshoti S. Clinico-Pathologic-Conference. *Chula Med J* 1971 Oct; 16(4) : 276-81
11. Pradatsundarasar A, Chintanawongs C, Shuangshoti S. Sparganum-like parasite of the brain. *Southeast Asian J Trop Med Public Health* 1971 Dec; 2(4) : 578-9
12. Slais J. The importance of the bladder for the development of the cysticercus. *Parasitology* 1966 Nov; 56(11) : 707-13
13. Shuangshoti S, Tangchai P. Textbook of Neuropathology. 2nd ed, Bangkok : Thai Watana Panich Press, 1980 : 160-6
14. Tesjaroen S. Sparganosis in Thais. *Siriraj Hosp Gaz* 1991 Oct; 43(10) : 743-9