

3-1-1994

Subacute necrotizing encephalomyelopathy (Leigh's disease) in adults clinically diagnosed as multiple sclerosis

Samruay Shuangshoti

Vira Kasantikul

Sukulya Lerdlum

Follow this and additional works at: <https://digital.car.chula.ac.th/clmjournal>



Part of the [Medicine and Health Sciences Commons](#)

Recommended Citation

Shuangshoti, Samruay; Kasantikul, Vira; and Lerdlum, Sukulya (1994) "Subacute necrotizing encephalomyelopathy (Leigh's disease) in adults clinically diagnosed as multiple sclerosis," *Chulalongkorn Medical Journal*. Vol. 38: Iss. 3, Article 6.

DOI: 10.58837/CHULA.CMJ.38.3.6

Available at: <https://digital.car.chula.ac.th/clmjournal/vol38/iss3/6>

This Case Report is brought to you for free and open access by the Chulalongkorn Journal Online (CUJO) at Chula Digital Collections. It has been accepted for inclusion in Chulalongkorn Medical Journal by an authorized editor of Chula Digital Collections. For more information, please contact ChulaDC@car.chula.ac.th.

Subacute necrotizing encephalomyelopathy (Leigh's disease) in adults clinically diagnosed as multiple sclerosis

Samruay Shuangshoti*+

Vira Kasantikul* Sukulya Lerdlum**

Shuangshoti S, Kasantikul V, Lerdlum S. Subacute necrotizing encephalomyelopathy (Leigh's disease) in adults clinically diagnosed as multiple sclerosis. *Chula Med J* 1994 Mar; 38(3): 145-163

A report is made on two women, aged 32 and 40 years respectively who died with subacute necrotizing encephalomyelopathy (adult form of Leigh's disease). These two patients were incorrectly diagnosed clinically to have multiple sclerosis because of diversified neurologic manifestations affecting the visual, motor, sensory, and autonomic systems. The course of ailment lasted about 10 years in case 1, and 1 year and 10 months in case 2. A review of 15 cases of the adult form of Leigh's disease, including these two patients, disclosed that clinically the malady showed psychomotor regression and brainstem dysfunction. The clinical diagnosis is confirmed by demonstrating symmetrical abnormalities in the basal ganglions on computed tomographic brain scan or magnetic resonance imaging. Pathologically, subacute necrotizing encephalomyelopathy is manifested by irregularly defined lesions in the basal ganglions, thalamus, brainstem, and spinal cord. These lesions are often bilateral and symmetrical, and contain proliferating small blood vessels with endothelial hyperplasia as well as relatively intact neurons. The etiology, pathogenesis, and appropriate treatment of Leigh's disease remain to be elucidated.

Key words : Subacute necrotizing encephalomyelopathy, Leigh's disease, Multiple sclerosis.

Reprint request : Shuangshoti S, Department of Pathology, Faculty of Medicine, Chulalongkorn University, Bangkok 10330, Thailand.

Received for publication. January 12, 1994.

* Department of Pathology, Faculty of Medicine, Chulalongkorn University.

** Department of Radiology, Faculty of Medicine, Chulalongkorn University.

+ In receipt of support from the Chulalongkorn Faculty of Medicine - China Medical Board Scholar Development Fund, 1994.

สำราญ ช่วงโชติ, วีระ กษานติกุล, สุกัลยา เลิศล้ำ, เนโครไทซิง เอนเซฟาโลมัยอีโลพาร์ ร่องเฉียบพลัน (โรคของลิจ) ในผู้ใหญ่ที่ได้รับการวินิจฉัยทางคลินิกว่าเป็นมัลติเปิลสเคลอโรซิส. จุฬาลงกรณ์เวช-
สาร 2537 มีนาคม;38(3): 145 - 163

ได้รายงานผู้ป่วยหญิงไทย 2 ราย อายุ 32 และ 40 ปี ตามลำดับ ป่วยด้วยโรคเนโครไทซิง เอน-
เซฟาโลมัยอีโลพาร์ ร่องเฉียบพลัน ซึ่งได้รับการวินิจฉัยทางคลินิกผิดพลาดว่าเป็นมัลติเปิลสเคลอโรซิส
ผู้ป่วยเสียชีวิตหลังป่วยนาน 10 ปี ในรายที่ 1 และ 1 ปี 10 เดือน ในรายที่ 2. การตรวจศพพบพยาธิสภาพ
ที่เข้าได้กับโรคของลิจทั้ง 2 ราย ได้ทบทวนวารสารทางการแพทย์พบมีรายงานโรคนี้เกิดในผู้ใหญ่ 15 ราย
รวมทั้งผู้ป่วย 2 รายที่รายงาน ณ ที่นี้ด้วย

โรคของลิจจะแสดงอาการทางคลินิกที่สำคัญ คือมีการเสื่อมสภาพของทั้งจิตใจและร่างกาย และ
การผิดปกติในหน้าที่ของก้านสมอง ซึ่งถ้าหากได้รับการยืนยันการตรวจพบรอยโรคที่มักเป็นทั้งสองข้างที่
นิวเคลียสลิกของสมองและก้านสมอง ด้วยวิธีเอกซเรย์คอมพิวเตอร์ (CT) และ/หรือ MRI ก็อาจวินิจฉัย
โรคได้ขณะที่ผู้ป่วยยังมีชีวิต

สำหรับทางพยาธิวิทยาจะพบรอยโรคที่ประกอบด้วยการเน่าตายของสมองส่วนที่ประกอบเป็น
นิวเคลียสลิก ธาลามัส ก้านสมอง และ/หรือไขสันหลัง ซึ่งมักเป็นทั้ง 2 ซีก ร่วมไปกับการรุกรานของ
หลอดเลือดขนาดเล็กและเอนโดธีเลียม กับนิวโรนที่ค่อนข้างปกติในรอยโรค และการปลอดพยาธิสภาพใน
แอมมิลลารีบอดี

เนื่องจากโรคของลิจอาจมีอาการดำเนินโรคนานและมีอาการทางคลินิกที่มักแสดงออกมาได้
หลาย ๆ รูปแบบ เพราะรอยโรคเกิดหลาย ๆ แห่งในระบบประสาท ซึ่งอาจทำให้วินิจฉัยโรคนี้ทางคลินิกว่า
เป็นมัลติเปิลสเคลอโรซิส จึงควรต้องแยกกันให้ดี

สาเหตุ พยาธิกำเนิด และการรักษาที่เหมาะสม สำหรับโรคของลิจยังไม่เป็นที่ทราบกันดีนัก

Multiple (disseminated) sclerosis is generally acknowledged as extremely rare in Thailand. The Thai physician, nevertheless, has repeatedly attempted to make the clinical diagnosis of this disease. However, it is difficult to be certain of the clinical diagnosis of multiple sclerosis when there is no pathological confirmation. At Chulalongkorn Hospital, a general hospital of about 1,370 beds in Bangkok, only a single postmortem proven case of multiple sclerosis has been found in more than 30 years⁽¹⁾ indicating the true rarity of this malady. Two patients recorded here have also been clinically diagnosed to have had multiple sclerosis. But the postmortem findings in these two cases show that they did not have multiple sclerosis, but are indeed examples of subacute necrotizing encephalomyelopathy in adult patients (adult form of Leigh's disease).⁽²⁻¹⁴⁾

Case reports

Case 1.

A 32-year-old nun was hospitalized because of progressive weakness in all limbs. Ten years earlier, she had been hospitalized because of bilaterally blurred vision. This symptom progressed slowly and she was informed to have degenerated optic nerves.

Five years later, she began to develop weakness in all limbs but still could walk.

One year ago, she had occasional headaches without nausea and vomiting.

Three weeks prior to hospitalization, she had headaches and difficulty in respiration. Two weeks prior to admission, numbness ensued at the distal parts of the hands and feet. Ten days prior to admission, weakness of all extremities became more severe. She entered a provincial hospital where she was found to have visual field defects, moderate weakness of the muscles in all limbs, and two plus deep tendon reflexes. Her consciousness was good. Cerebellar sign and stiff neck were absent. A leucocyte count showed 7,100 cells/mm³ with 77% neutrophils and 23% lymphocytes. A lumbar puncture revealed 99 lymphocytes/mm³ 20 mg/100 ml of protein, and 66 mg/100 ml of glucose in the cerebrospinal fluid (CSF). She was transferred to Chulalongkorn Hospital a week later.

On admission here, her body temperature was 39.3°C, pulse rate 100/min, respiratory rate 32/min, and blood pressure 120/80 mmHg. The patient was conscious. Each pupil, 3 mm in diameter, was reactive to light. The visual acuity remained at finger count at 1 foot. There was impaired function of the seventh and twelfth cranial nerves. The other remaining cranial nerves were intact. Motor power was absent in all extremities. Pain and touch sensations were absent. There was no plantar response in Babinski's maneuver. The ankle clonus was negative. Per rectal examination revealed loose sphincter tone. Detected throughout the lungs were medium to coarse crepitations.

Hemoglobin was 10.8 to 12 gm/100 ml and leukocyte counts revealed 8,200 to 15,800 cells/mm³ with 84 to 85% neutrophils, 13 to 16% lymphocytes, and 0 to 2% monocytes. A urinalysis disclosed a trace of protein, 5 to 10 leucocytes/high power field (HPF), numerous yeast cells/HPF, and few fungal filaments/HPF. Blood chemical studies revealed 141 to 159 mg/100 ml of sugar, 10 to 20 mg/100 ml of BUN, 1.2 to 2.0 mg/100 ml of uric acid, 123 to 135 mEq/L of sodium, 3.8 to 5.5 mEq/L of potassium 87 to 97 mEq/L of chloride, and 14 to 28 mEq/L of carbon dioxide.

The first lumbar puncture, 1 day after hospitalization, revealed opening and closing pressures to be 220 and 170 mm of water, respectively. The clear CSF contained 130 lymphocytes/mm³, 90 mg/100 ml of protein, and 61 mg/100 ml of sugar (blood sugar was 100 mg/100 ml). VDRL of CSF was negative. The second lumbar puncture, 10 days after hospitalization, showed 30 mg/100 ml of protein and 52 mg/100 ml of sugar (blood sugar was 141 mg/100 ml). Stain for acid-fast bacilli of the CSF sediment was negative.

A sputum culture exhibited heavy growth of *Pseudomonas aeruginosa*. A urine culture showed growth of *Escherichia coli* and yeast cells.

A computerized tomographic (CT) scan of the brain disclosed a lesion of low density in the right thalamus. A CT scan of the spinal cord showed a homogeneous and dense intramedullary lesion at the cervical region (Fig. 1). A myelogram showed an enlarged cervical segment of the spinal cord from C₅ to C₇.

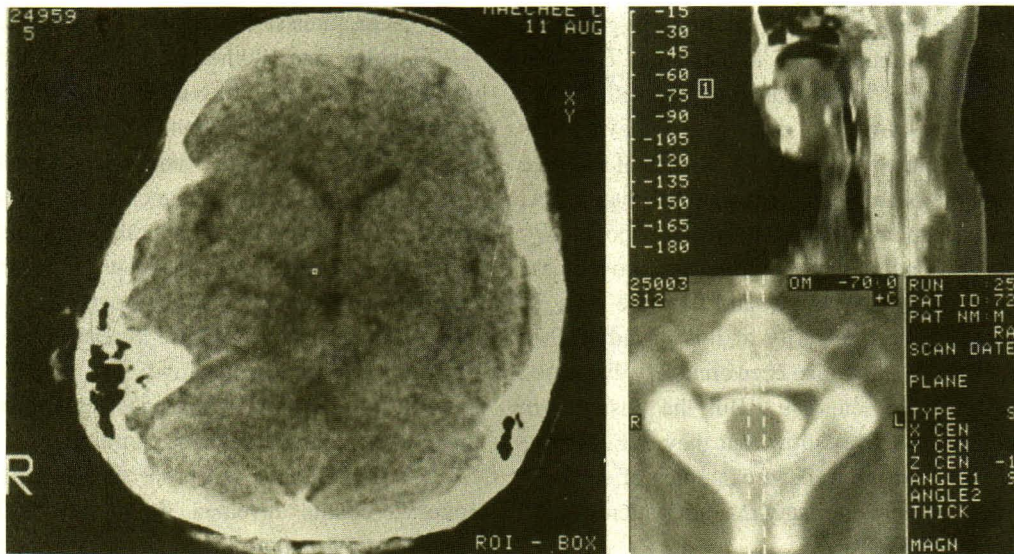


Figure 1. (Case1). CT scan of brain and spinal cord.

- (A) CT scan of brain in horizontal plane shows small areas of decreased density in the thalamus on the right side.
 (B & C) Intrathecal contrast-enhanced CT of the spinal cord in sagittal plane (B) and coronal plane (C) demonstrate enlargement of the cervical segment.

The treatment consisted of the administration of antibiotics (penicillin and gentamycin), antituberculous drugs, (INH and rifampicin), steroid, and other supportive measures. The patient had fever (38° to 41°C) and fluctuated blood pressure (60/30 and 140/90 mmHg). The respiration became laborious and this eventually required artificial oxygenation. She died 15 days after hospitalization. The total course of illness was about 10 years. The clinical impression was multiple sclerosis.

Postmortem Examination

The autopsy findings included bilateral bronchopneumonia and acute cystitis. A 1,330-gm brain showed thin and clear leptomeninges, and thin optic nerves with opaque sheaths. Coronal sections of the brain revealed necrotic foci in the thalamic nuclei, right temporal lobe (Fig. 2), right cerebral peduncle, and bilateral substantia nigra. Each necrotic zone was about 1.5 cm in diameter. The mammillary bodies were intact (Fig. 2), as was the hypothalamus. There was also necrosis of the mesencephalon and pons, as well as the periaqueductal gray matter.

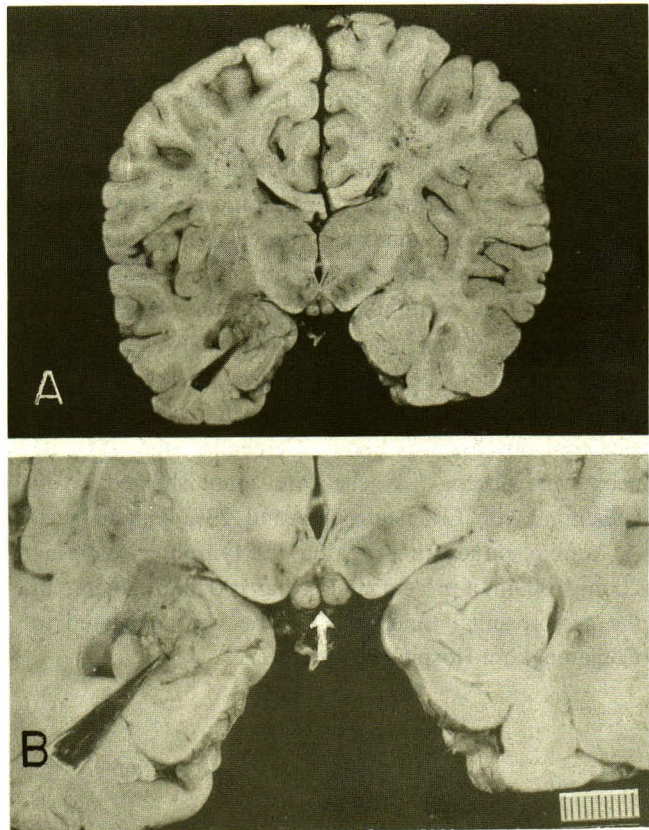


Figure 2. (Case 1). Lesion of brain.

- (A) Coronal section shows hemorrhagic spots, especially in bilateral centrum semiovale and thalami. An arrow points toward a necrotic focus in the right temporal lobe.
 (B) Higher magnification of the necrotic region is shown (left arrow). Note intact mammillary bodies (right arrow). The scale is 1 cm in length.

The cervical segment of the spinal cord was soft, friable, and swollen (Fig.3). The rest of the spinal cord was unremarkable.

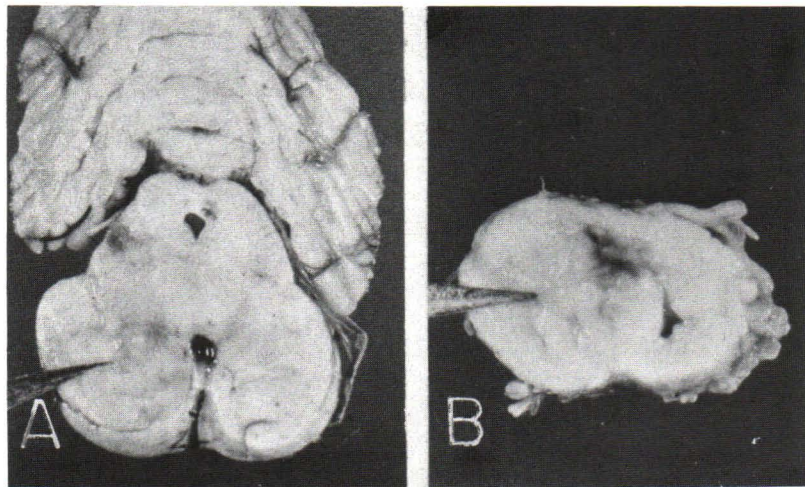


Figure 3. (Case 1). Lesion of brain and spinal cord.
(A) Midbrain and cerebellum show necrotic zone in the right side of the former (arrow).
(B) Cervical segment of the spinal cord displays necrosis (arrow).

Tissues in this case, as well as in the other instance, were fixed in 10% formalin, embedded in paraffin, and stained with hematoxylin and eosin (H & E). Luxol-fast blue stain for myelin sheath and Gomori's stain for reticulin fibers were also done. Frozen sections with oil-red-O stains on formalin-fixed tissue were also conducted to detect lipid.

Microscopically, the following alterations were encountered in the central nervous system (CNS), namely necrosis and status spongiosus of neuropil, vascular

proliferation and endothelial hyperplasia, infiltration of microglia, gliosis, and relatively preserved neurons. These pathologic changes were similar in the brain (Fig. 4) and spinal cord (Fig. 5). It was unfortunate that the optic nerves were lost in the routine processing of tissue; hence, the pathologic changes in them could not be described.

The pathologic diagnosis of the CNS lesions was subacute necrotizing encephalomyelopathy (Leigh's disease) in an adult woman.

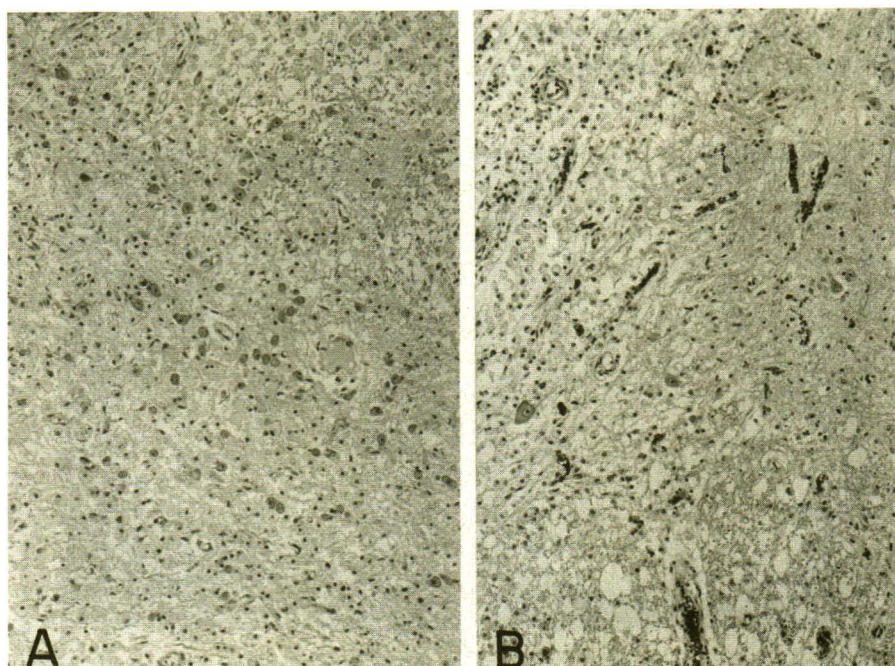


Figure 4. (Case 1). Microscopic picture from pons.

- (A) Necrotic zone is presented especially on the upper part as revealed by loose neuropil to be infiltrated by mononuclear and foamy cells. Many intact neurons are scattered. H & E, x 50.
- (B) More advanced necrosis and vascular proliferation are shown. Note few intact neurons lying in necrotic zone and status spongiosus of neuropil particularly in lower half of the photomicrograph. H & E, x 100.

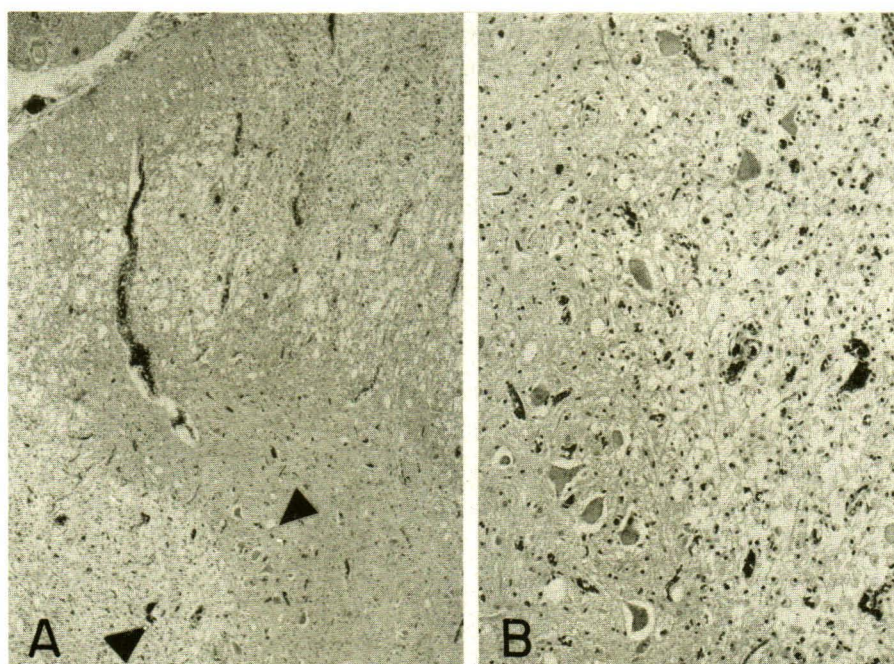


Figure 5. (Case 1). Microscopic pictures from cervical segment of spinal cord.

- (A) Spongy degeneration, vascular proliferation and intact anterior horn cells are demonstrated. The area between arrowheads is further shown in B. H & E, x 50.
- (B) Small blood vessels and infiltration of foamy macrophages are seen in loose necrotic zone. Intact neurons lie in necrotic area and at the edge. H & E, x 100.

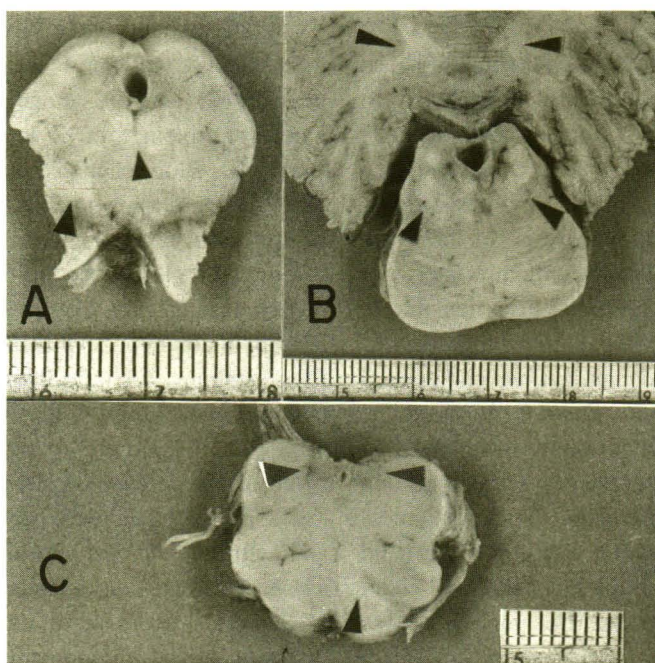


Figure 6. (Case 2). Brain in Leigh's disease. Scale is in centimeter.

- (A) Mesencephalon exhibits gray-white necrotic areas (arrowheads), especially beneath the cerebral aqueduct (upper arrowhead).
- (B) Pons and cerebellum demonstrates symmetrical necrotic zones (arrowheads) in each.
- (C) Medulla shows necrotic foci (arrowheads).

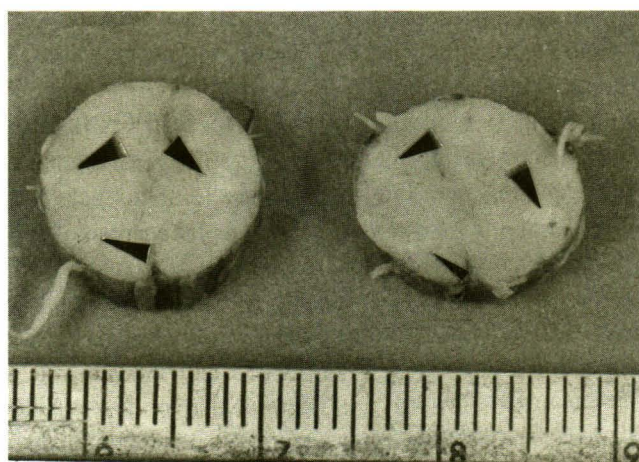


Figure 7. (Case 2). Whitish necrotic areas (arrowheads) are scattered in the upper cervical segment of the spinal cord. Scale is in centimeter.

These necrotic zones tended to be symmetrical, especially in the dorsum of pons. They were 0.5 to 2.0 cm across, soft, dull, and friable. The right mammillary body was grossly intact. The optic nerves were not available for study. They were presumably attached to the left half of the brain that was taken away by the neurologist.

Microscopically, various necrotic foci contained numerous small blood vessels which were well outlined in Gomori's stain for reticulin fibers (Fig. 8). Some blood vessels showed endothelial proliferation and infiltration of the walls by lymphocytes, plasma cells, and histiocytes

(Fig. 9). Numerous lipid-laden macrophages (Fig. 10) and microglia were also observed in the necrotic region, along with gliosis (Fig. 11). Neurons, however, were relatively intact in these zones of necrosis (Fig. 12). Focal chronic nonspecific meningitis was also detected (Fig. 13). The pathologic changes of the cervical segment of the spinal cord were strikingly similar to those seen in the brain. Foci of necrosis with neovascularization, gliosis, and relatively intact anterior horn cells were observed (Fig. 14).

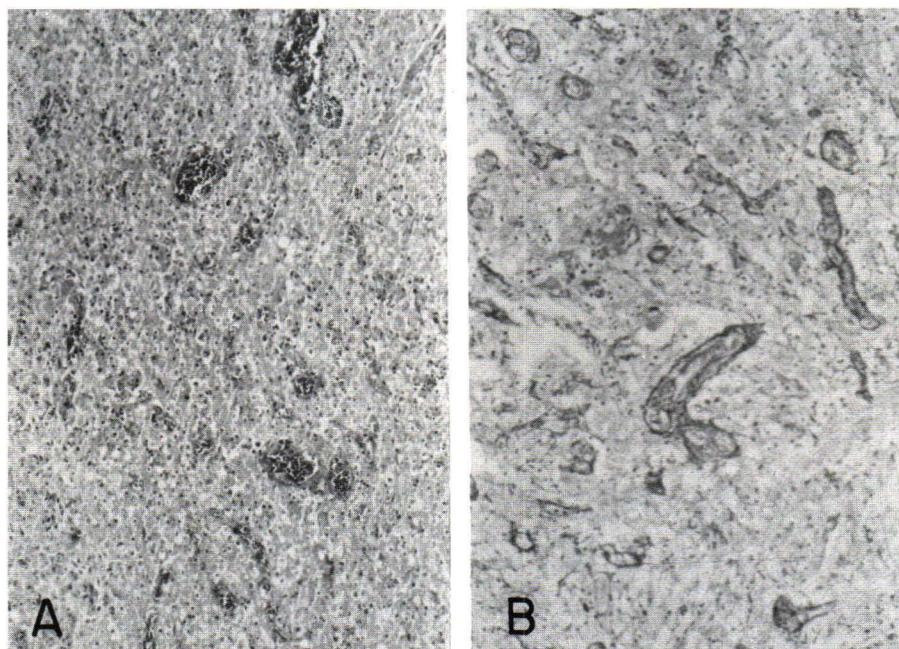


Figure 8. (Case 2). Histopathologic features.
(A) Necrotic focus contains numerous reactive cells and small blood vessels. H & E, x 50.
(B) Plentiful blood vessels are well outlined in Gomori's silver impregnation x 50.

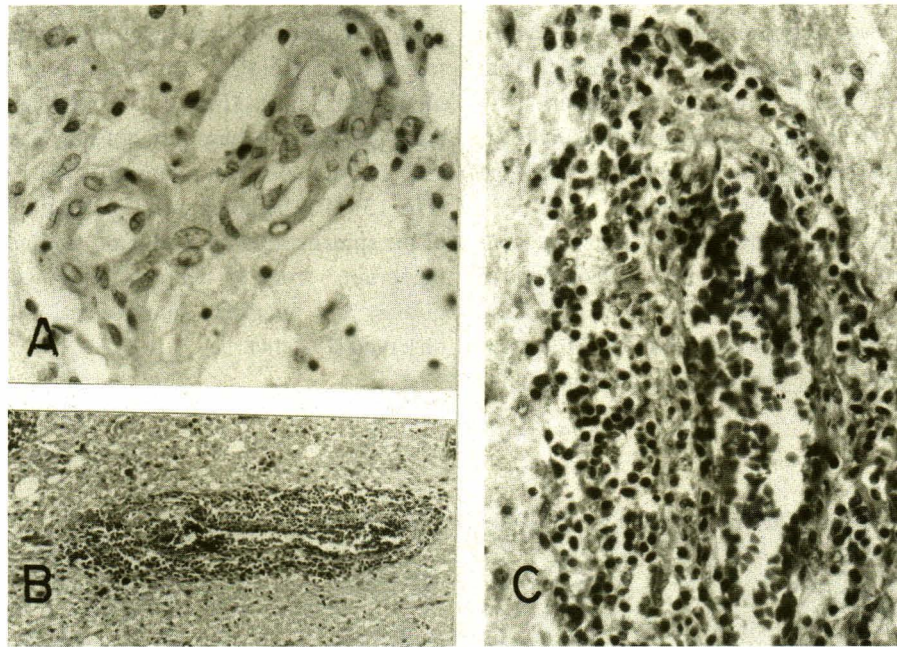


Figure 9. (Case 2.). Vascular changes.

(A) Endothelial hyperplasia is shown. H & E, x 100.

(B) Vasculitis is depicted. H & E x 50.

(C) A part of the same blood vessel in B shows numerous cellular infiltrates mainly lymphocytes. H & E, x 100.

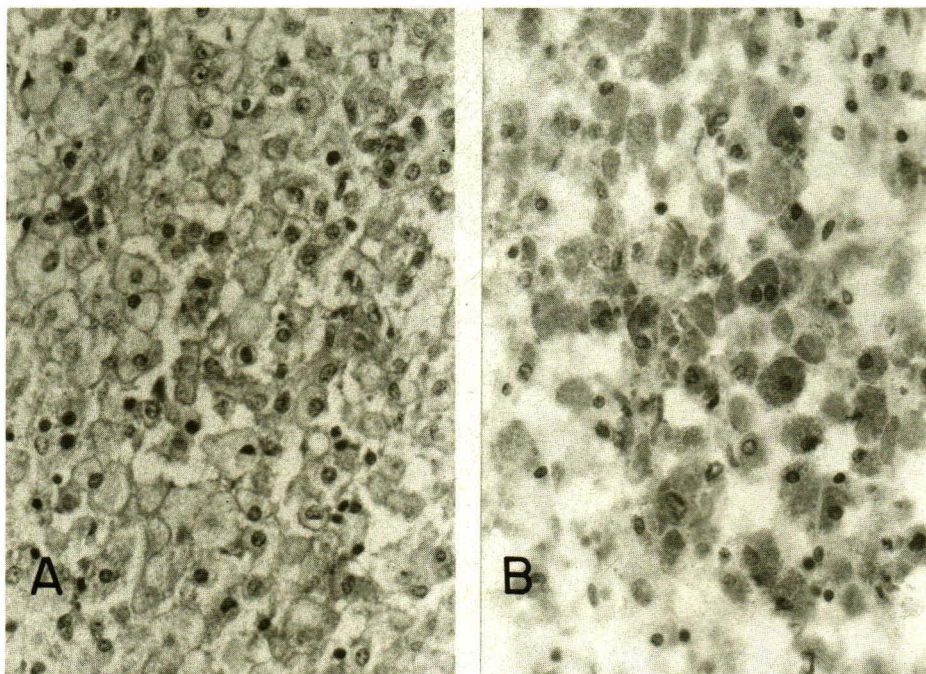


Figure 10. (Case 2). Necrotic foci.

(A) Numerous foamy histiocytes are concentrated in an area of necrosis. H & E, x 400.

(B) Dark perikaryon of the histiocytes in necrotic zone is related to lipid content. Frozen section with oil-red-O stain, x 400.

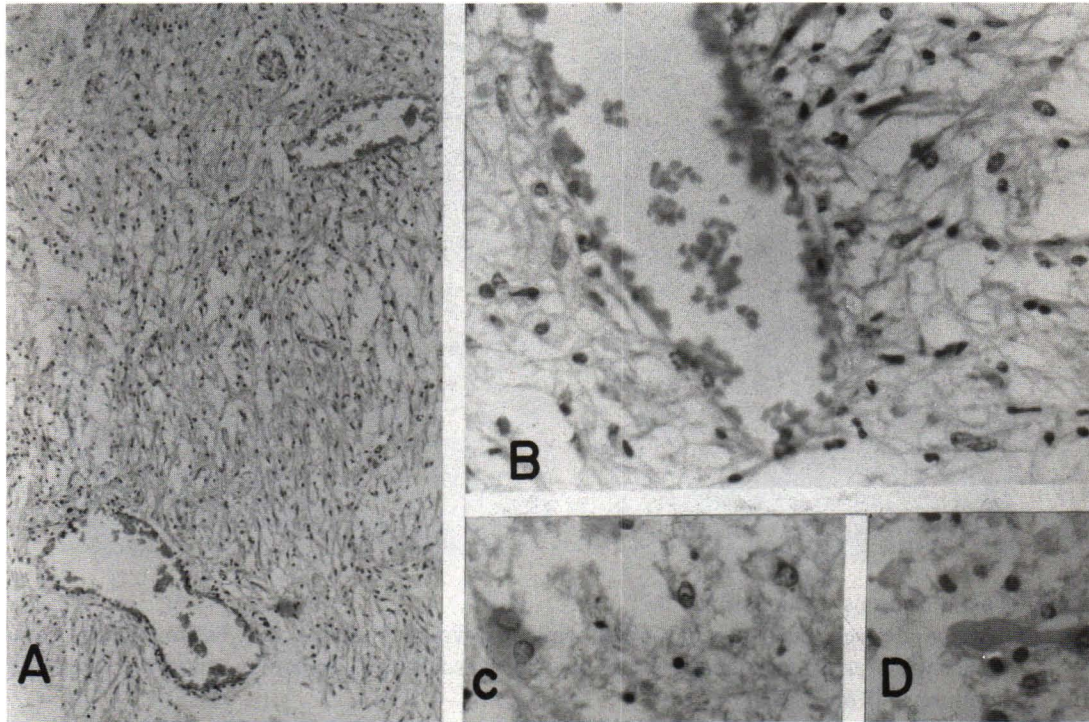


Figure 11. (Case 2). Gliosis within lesion.

- (A) Astrocytes with delicate processes are numerous in a lesion. Many of them are attached to the vascular walls by processes. H & E, x 50.
- (B) Higher magnification of the area in the right upper corner in A shows astrocytes with delicate processes in relation to the vascular wall. H & E, x 100.
- (C) A few plump astrocytes are demonstrated in a necrotic area; one of them has two vesicular nuclei. H & E, x 100.
- (D) A bizarre astrocyte with homogeneous and glassy cytoplasm and eccentric vesicular nucleus lies in a necrotic zone. H & E, x 100.

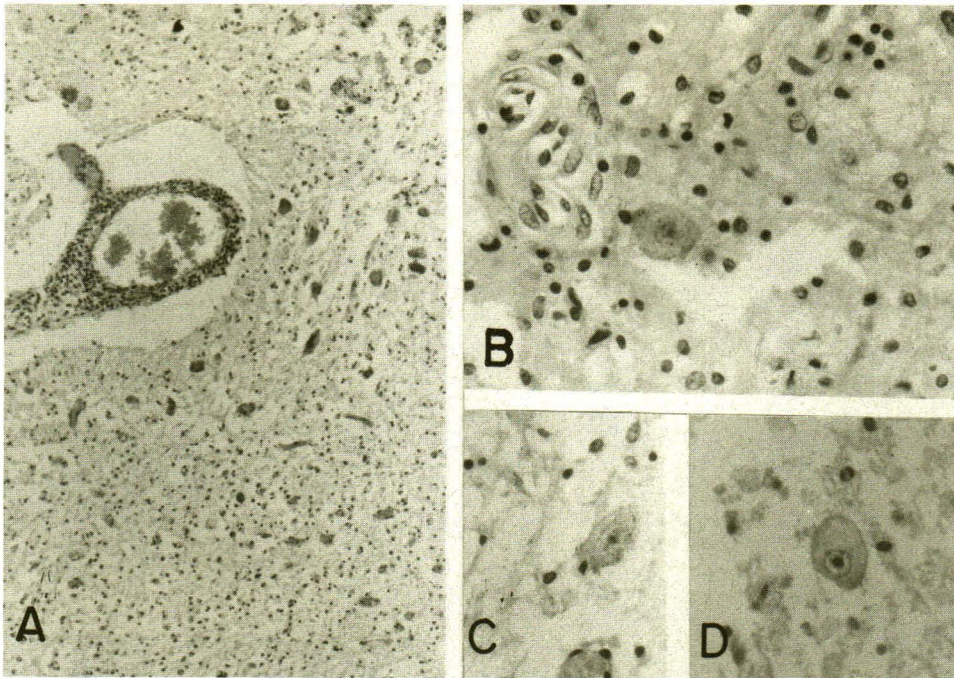


Figure 12. (Case 2). Neurons within lesion.

- (A) Many relatively intact neurons are disseminated within a necrotic zone as are plentiful mononuclear cells which are smaller than neurons. Also note vasculitis. This photomicrograph is taken from a locus celureus. H & E, x 50.
- (B) A necrotic focus shows a relatively intact neuron, a cluster of blood vessels, and scattered lymphocytes and microglia. H & E, x 400.
- (C) and (D) Two neurons with nuclei having distinct nucleoli creating fish-eye appearance lie within the liquefied neuropil, x 400 each.

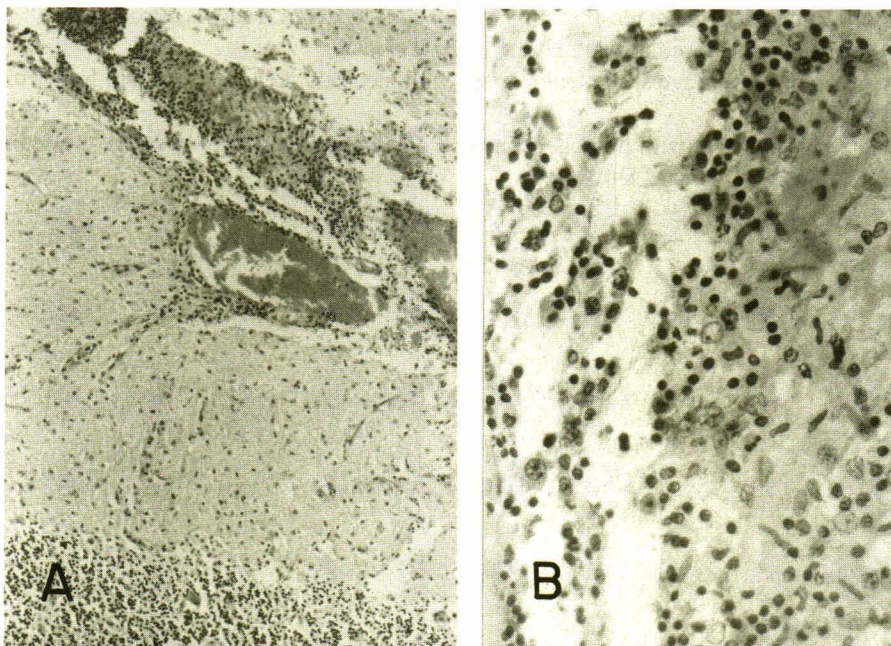


Figure 13. (Case 2). Nonspecific inflammatory changes.

- (A) The leptomeninges over cerebellar folium is infiltrated by many reactive cells. Layer of granular neurons is seen below. H & E, x 50.
- (B) Higher magnification of the same lesion in A shows many lymphocytes, histiocytes, rod-shaped microglia, and few plasma cells representing nonspecific meningitis H & E, x 100.

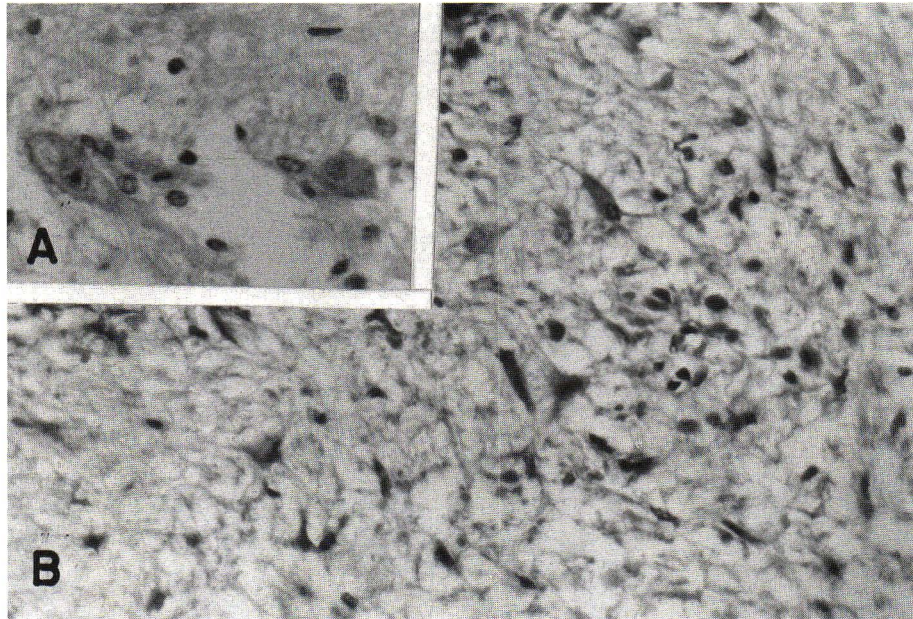


Figure 14. (Case 2). Histopathologic changes in cervical segment of spinal cord.

(A) Two relatively intact motor neurons lie within necrotic gray matter. H & E, x 400.

(B) This photomicrograph is taken from the white matter to show gliosis. Note several plump star-shaped astrocytes. H & E, x 100.

The pathological diagnosis was subacute necrotizing meningo-encephalomyelopathy (Leigh's disease) in an adult woman.

Discussion

Typical pathologic features of Leigh's disease consist grossly of necrotic lesions which can be seen with the unaided eye in the mesencephalon and brainstem. They appear as gray, soft, friable, and slightly sunken zones which are often, but not always, symmetrical.⁽²⁻¹⁸⁾ The tegmentum of the midbrain and pons, periaqueductal gray matter, and posterior colliculi are often affected. Medullary lesions may affect the floor of the fourth ventricle and the inferior olivary nuclei. The lesions, moreover, may be located in the basal ganglions, especially putamen and substantia nigra. They are less common in the thalamus, centrum semiovale, and optic pathways. Sparing of the mammillary bodies is typical. Concerning the cerebellum, the lesion is common in the dentate nuclei and white matter, but is less frequent in the cortex and peduncles. The spinal cord may be affected. Involvement of the peripheral nerves is inconsistent.

Microscopically, severe sponginess of neuropil, necrosis, and infiltration of such cells as lymphocytes, polymorphonuclear cells, histiocytes, plasmacytes, and microglia are often seen as are glioses. Lipid-laden histiocytes are numerous in active lesions but are infrequent in less active or old lesions. Prominent

proliferation of small blood vessels with endothelial hyperplasia is the most characteristic feature of Leigh's disease, as is relatively intact neurons even in the necrotic area.⁽²⁻¹⁸⁾ Such gross and microscopic features were present in the brain and spinal cord of our two patients. Hence, we are certain about our pathologic diagnosis of subacute necrotizing encephalomyelopathy. Although the optic nerves were not studied pathologically, it is not essential that they must be examined in rendering the pathologic diagnosis of Leigh's disease. When variously described pathologic features are detected in any part of the CNS, the pathologic diagnosis of Leigh's disease can be made. The diagnosis, thus, can be rendered by biopsy of lesions such as from the brainstem.⁽¹³⁾

Although the pathologic features in our two patients are quite similar to those of Wernicke's encephalopathy we do not consider our cases to represent Wernicke's encephalopathy. Both patients were not alcoholic and the mammillary bodies were intact. Thus we exclude from our review cases of Leigh's disease described as associated with chronic alcoholism and with involvement of the mammillary bodies.⁽¹⁹⁻²¹⁾

Although confusion between multiple sclerosis and Leigh's disease has occurred clinically^(4,11) the two conditions can be distinguished pathologically. Multiple sclerosis is chiefly the disease of white matter; most lesions are scattered in the latter. Lesions of Leigh's disease involve both gray and white matter, especially

Table 1. Summary on 15 cases of subacute necrotizing encephalomyelopathy (Leigh's disease) in adults.

No	Author(s) & year of report	Age (yrs) at onset at death	Sex	Neurologic manifestations	Topography of CNS lesions	Histopathology	CT	MRI	General autopsy findings
1	Solheid et al, 1971 ⁽²⁾	21 23	M	Psychomotor retardation & focal seizures. Terminal L focal seizures, L hemiparesis, nystagmus, relapsing stupor & coma	Putamen, subthalamic nucleus, substantia nigra, brainstem, L cerebellum & spinal cord	Necrosis, capillary proliferation, demyelina- tion in brainstem & spinal cord	ND	ND	Angioma of cerebellum
2	Martin, 1972 ⁽³⁾	43 43	M	Depression, loss of appetite & malaise. Terminal R hemiparesis & generalized seizures	Cortex, optic chiasm, putamen, hypothalamus, subthalamic nucleus & brainstem	Necrosis, capillary proliferation & neuronal preservation	ND	ND	Insignificant
3	Ulrich & Fankhauser Mauri, 1978 ⁽⁴⁾	31 31 4/12	M	Visual impairment, palsy of CN VI, ptosis & tremor of hands	Midbrain & brainstem	Necrosis, capillary proliferation & neuronal preservation	ND	ND	Tracheobronchitis, pulmonary hemorrhage & cardiac dilatation
4	Ho et al, 1979 ⁽⁵⁾	54 54	F	Sudden onset of saddle paresthesias & incontinence of urinary bladder. Terminal paraparesis, flaccidity of legs, absence of reflexes & loss of all sensations below T ₁₀	Midbrain, upper pons, periaqueductal gray matter, floor of fourth ventricle, medulla oblongata & spinal cord.	Loosening of ground substance, gliosis, necrosis, proliferation of microglia, formation of microcysts, proliferation of small blood vessels & endothelial cells & preserved neurons	ND	ND	Confluent broncho- pneumonia
5	Kalimo et al, 1979 ⁽⁶⁾	22 23	F	Bilateral optic atrophy, hyperactive tendon reflexes, L plantar extensor response, paresthesia of L upper limb, ataxia, L hemiparesis, depression, paranoid, dementia & R hemiplegia	Old necrosis of head of R caudate nucleus & R occipital lobe. Optic atrophy	Hemorrhagic necrosis, spongy neuropil, proliferation of capillaries, gliosis & preserved neurones	—	—	—
6	Ho et al, 1982 ⁽⁷⁾	34 34	F	Blurred vision, malaise, sudden unconsciousness & associated with Addison's disease, Hashimoto's disease & diabetes mellitus	Well demarcated, gray & dusky symmetrical lesions in tegmentum of midbrain & pons, floor of fourth ventricle, optic chiasm & cervical segment of spinal cord	Proliferation of small blood vessels with occasional perivascular lymphocytic infiltration, astrocytosis, proliferation of microglia & preserved neurons	Normal	ND	Idiopathic adrenitis fibrosis of & thyroid gland

Table 1. Summary on 15 cases of subacute necrotizing encephalomyelopathy (Leigh's disease) in adults (continued).

No	Author(s) & year of report	Age (yrs) at onset at death	Sex	Neurologic manifestations	Topography of CNS lesions	Histopathology	CT	MRI	General autopsy findings
7	Hegedus & Nemeth, 1984 ⁽⁸⁾	49 49	M	L progressive hemiparesis, instable gait, ataxia, frequent loss of consciousness, mild bilateral papilledema, exaggerated tendon reflexes, L pyramidal tract signs, lethargic disorientation, confusion & akinetic mutism	Brainstem, periaqueductal gray matter, L inferior colliculus, L cerebellar hemisphere, thalamic nuclei, subthalamic bodies, R pallidum, L superior frontal gyrus, hydrocephalus due to narrowing of cerebral aqueduct	Severe proliferation of small blood vessels, foamy cells, necrosis, astrocytosis, proli- feration of microglia, marked narrowing of cerebral aqueduct & demyelination of optic nerves and tracts	ND	ND	Urocystitis, thrombosis of R iliac vein, massive pulmonary embolism
8	Gray et al, 1984 ⁽⁹⁾	21 31	F	Visual impairment, ptosis, bilateral CN VI palsy, R facial palsy & R extensor plantar response. Terminal drowsy, chewing movement, pinpoint & nonreactive pupils, bilateral facial palsy, bilateral extensor plantar response, hyperthermia, respiratory failure & death	Bilateral necrosis of head of caudate nuclei, thalami, internal capsules & walls of third ventricle. Old lesions in posterior parts of cerebral peduncles, atrophy of optic chiasm & preserved mammillary bodies	Two types of lesions namely chronic changes of optic chiasm & cerebral peduncles characterized by myelin loss, status spongiosus, astrocytosis, marked proliferation of capillaries & endothelial hyperplasia; Recent changes characterized by necrosis of neuropil with edema, lipid-laden macrophages, lymphocytic cuffing of blood vessels, capillary proliferation & preserved neurons	Area of low den- sity of thalamii, anterior limbs of internal capsules & sple- nium of corpus callosum	ND	Mild bronchopneumonia
9	Maso et al, 1984 ⁽¹⁰⁾	57 57	M	Slurred speech, ataxia, nystagmus, extrapyramidal rigidity, decreased tendon reflexes, bilateral optic atrophy & clonic jerks	Softening of striated nuclei, pons & medulla oblongata. Focal cerebellar atrophy. Preserved mammillary bodies	Cavitary necrosis, moderate capillary proliferation & neuronal preservation. Patchy demyelination of optic nerves & tracts. Severe gliosis, cerebellar atrophy & demyelination of dentate region	Normal at be- ginning. Slow enlarge- ment of fourth ventricle at later period	ND	Bronchopneumonia

Table 1. Summary on 15 cases of subacute necrotizing encephalomyelopathy (Leigh's disease) in adults (continued).

No	Author(s) & year of report	Age (yrs) at onset at death	Sex	Neurologic manifestations	Topography of CNS lesions	Histopathology	CT	MRI	General autopsy findings
10	Kissel et al, 1987 ⁽¹¹⁾	21 21	F	Difficulty in balancing body, gait disturbance, intermittent diplopia, speech disturbance, urinary incontinence, decreased alertness, impaired extraocular movements, nystagmus, impaired upper gaze & general motor weakness	Cavitary lesions of thalami, basal ganglia, midbrain, periaqueductal gray matter, floor of fourth ventricle, substantia nigra & mild atrophy of optic nerves	Cavitation in basal ganglia bridged by blood vessels, gliosis, neuronal depletion but preservation of neurons & midbrain tegmentum	Normal	Focal area of increased signal intensity in region of periaqueductal gray matter & midbrain tegmentum	—
11	Cummiskey et al, 1987 ⁽¹²⁾	34 34	F	Automatic respiratory failure, limited upward gaze, bilateral facial weakness & decreased gag reflex	Diencephalon, periaqueductal gray matter in pons, floor of fourth ventricle (medulla) & cervical segment of spinal cord	Not described but gave diagnosis of subacute necrotizing encephalomyelopathy	ND	—	—
12	Sahni et al, 1987 ⁽¹²⁾	36	F	Not described	Medulla oblongata	Status spongiosus & astrocytosis seen in CT-guided stereotactic biopsy	Contrast enhancing lesion of posterior medulla	Low intensity T1 & high intensity T2 lesion in medulla	—
13	Reynaud et al, 1988 ⁽¹⁴⁾	35 35	M	Behavioral changes, epileptic fits, ataxia, autonomic disorders, abnormal alimentary behavior & dementia	Caudate nuclei, R putamen & pallidum	Necrosis, hyperplasia of capillaries, severe status spongiosus & preserved neurons.	—	—	—

Table 1. Summary on 15 cases of subacute necrotizing encephalomyelopathy (Leigh's disease) in adults (continued).

No	Author(s) & year of report	Age (yrs) at onset at death	Sex	Neurologic manifestations	Topography of CNS lesions	Histopathology	CT	MRI	General autopsy findings
14	Shuangshoti et al, current case 1	22 32	F	Bilaterally blurred vision, weakness of all limbs, numbness of hands & feet	Thalamus, R temporal lobe, R cerebral peduncle, substan- tia nigra, pons, medulla oblongata & cervical segment of spinal cord	Necrosis, proliferation of small blood vessels & endothelium, gliosis & preserved neurons	Low density lesion in R thalamus. Homogeneous & dense intra- medullary lesion of cervical segment of spinal cord	—	Broncho- pneumonia
15	Shuangshoti et al, current case 2	38 40	F	Paraparesis of lower limbs, difficulty in urination, optic neuritis, dysphagia, hyperesthesia & formication of skin, blurred vision in R eye, bilateral extensor plantar responses, stupor & coma	Thalamus, basal ganglion, centrum semiovale, mesencephalon, pons, medulla oblongata & cervical segment of spinal cord	Necrosis, microglial proliferation, vascular proliferation & endothelial hyperplasia, astrocytosis & preserved neurons	—	—	Tracheobronchitis & decubiti

CNS = Central Nervous System, CN = Cranial Nerve, R = Right, L = Left, M = Male, F = Female, CT = Computerized Tomogram,
MRI = Magnetic Resonance Imaging, ND = Not Done.

the midbrain and brainstem around or near the cerebral aqueduct. To our knowledge, vascular changes as we have described previously and in the current study which were characterized by an increase in the number of blood vessels and proliferation of endothelial cells⁽¹⁸⁾ have not yet been observed in multiple sclerosis.

The clinical confusion between multiple sclerosis and Leigh's disease is probably related to the fact that both diseases have lesions disseminated in various parts of the CNS. Similar clinical manifestations, then, develop when some of these lesions are distributed in the same or similar region of the CNS although they are morphologically different.

To the best of our knowledge, only 15 adult forms of subacute necrotizing encephalomyelopathy have been recorded,⁽²⁻¹⁴⁾ including our two cases presented here (Table 1). Some examples having initial symptoms in childhood which should be recognized as a juvenile form of Leigh's disease who survived to adulthood are excluded.⁽²²⁻²⁴⁾

Briefly, lesions of Leigh's disease in adults are frequently multiple. Basal ganglions, thalamus, brainstem, optic nerves, and spinal cord are often affected. Motor weakness and visual impairment are common, followed by ataxia, seizures, psychiatric disturbances, sensory manifestations, palsies of cranial nerves, and sleep disturbances. Most patients have been subacute with periods of remission and exacerbation in their clinical course as noted in our patients. The clinical diagnosis, thus, should be considered when patients develop an acute or subacute neurological manifestation beginning with visual impairment followed by brainstem dysfunction.

Only a few adult patients with Leigh's disease have been studied using CT brain scans. For instance, Whetsell and Plaitakis⁽²²⁾ reported edema of the midbrain in one of their three patients. Gray et al⁽⁹⁾ described bilateral hypodensities in both thalami and anterior limb of the internal capsule. Maso et al⁽¹⁰⁾ noted enlarged fourth ventricle and cerebellar atrophy. Low density lesions in the right thalamus was also observed in our case 1. Delgado et al⁽²⁴⁾ showed low density lesions of the striatum bilaterally in their questionable case of Leigh's disease. Kissel et al⁽¹¹⁾ and Davis et al⁽²⁶⁾ have studied subacute necrotizing encephalomyelopathy using magnetic resonance imaging (MRI). Symmetrical involvement of lesions had been noted in the basal ganglions, midbrain, and around the cerebral aqueduct with sparing of the mammillary bodies. These lesions showed increased signal intensity.

The cause of subacute necrotizing encephalomyelopathy is unclear but believed to be a metabolic

disease associated with various defects in oxidative phosphorylation or mitochondrial DNA mutations.^(14,27) Kepes⁽²⁴⁾ observed oncocytic transformation of the choroid plexus epithelium of a patient who died with Leigh's disease. Electron-microscopically he noted numerous abnormal mitochondria within the choroidal epithelial cytoplasm. There is no specific treatment for subacute necrotizing encephalomyelopathy. The patient invariably succumbs to the disease.

References

1. Shuangshoti S, Tangchai P. Neuropathology. 2nd ed. Bangkok : Thai Watana Panich Press, 1983 : 239
2. Solheid CL, Stoupe N, Martin JJ. La forme adulte a evolution chronique ed l' encephalopathie necrosante de Leigh. Acta Neurol Belg 1971; 71 : 282-95
3. Martin JJ. Sur la delimitation clinicopathologique de l' encephalopathie de Gayet-Wernicke et de la forme adulte ed l' encephalopathie de Leigh. Acta Neurol Belg 1972 Sep-Oct; 72 : 347-54
4. Ulrich J, Fankhauser-Mauri C. Subacute necrotizing encephalopathy (Leigh's disease) in an adult. Eur Neurol 1978; 17(5) : 241-6
5. Ho KL, Piligian JT, Chason JL. Adult form of subacute necrotizing encephalomyelopathy. Arch Pathol Lab Med 1979 Jul; 103(7) : 344-7
6. Kalimo H, Lundberg PO, Olsson Y. Familial subacute necrotizing encephalomyelopathy of the adult form (adult Leigh's syndrome). Ann Neurol 1979 Sep; 6(3) : 200-6
7. Ho KL, Sabharwal S, Juncker JB. Adult form of Leigh's disease in a patient with Addison's disease and Hashimoto's disease. Arch Pathol Lab Med 1982 Feb; 106(2) : 102
8. Hegedüs K, Nemeth G. The adult form of subacute necrotizing encephalopathy. Surg Neurol 1984 Jun; 21(6):572-6
9. Gray F, Louarn F, Gherardi RL, Elizenbaum JF, Marsault C. Adult form of Leigh's disease: a clinicopathological case with CT scan examination. J Neurol Neurosurg Psychiatry 1984 Nov; 47(11): 1211-5
10. Maso E, Ferrer I, Herraiz J, Roquer J, Serrano S. Leigh's syndrome in an adult. J Neurol 1984; 231(5):253-7
11. Kissel JT, Kolkin S, Chakeres D, Boesel C, Weiss K. Magnetic resonance imaging in a case of autopsy-proved adult subacute necrotizing encephalomyelopathy (Leigh's disease). Arch Neurol 1987 May; 44(5):563-6

12. Cummiskey J, Guilleminault C, Davis R, Duncan K, Golden J. Automatic respiratory failure: sleep studies and Leigh's disease. *Neurology* 1987 Dec;37(12):1876-8
13. Sahni KS, Ghatak NR, Gulati AN, Leshner RT, Apberico A, Young HF. CT-guided stereotactic biopsies of lesions in the medulla and a case of Leigh's disease. *Appl Neurophysiol* 1987;50 (1-6): 203-9
14. Reynaud P, Loiseau H, Coquest M, Vital C, Loiseau P. Un cas adult encephalomyelopathie necrosante subaigue de Leigh, *Rev Neurol (Paris)* 1988; 144(4):259-65
15. Namiki H. Subacute necrotizing encephalomyelopathy: case report with special emphasis on associate pathology of peripheral nervous system. *Arch Neurol* 1965 Jan;12(1):98-107
16. Dunn HF, Dolman CL. Necrotizing encephalomyelopathy: report of a case with relapsing polyneuropathy and hyperalaninemia and with manifestations resembling Freidreich's ataxia. *Neurology* 1969 Jan;19(6):536-50
17. Montpetit JA, Andermann F, Carpenter S, Fawcett JS, Zborowska-Sluis D, Giberson HR. Subacute necrotizing encephalomyelopathy (a review and a study of two families). *Brain* 1971 Jan;94(1) 1-30
18. Kasantikul V, Shuangshoti S. Infantile form of subacute encephalomyelopathy (Leigh's disease): report of two cases. *J Med Assoc Thai* 1987 Oct;70(10):596-603
19. Feigin I, Goebel HH. "Infantile" subacute necrotizing encephalomyelopathy in adult. *Neurology* 1969 Aug;19(8):749-59
20. Feigin I, Budzilovich GN. Further observatoins on subacute necrotizing encephalomyelopathy in adults. *J Neuropathol Exp Neurol* 1977 Jan;36(1):128-39
21. Fulham M, Lawrence C, Harper C. Diagnostic clues in an adult case of Leigh's disease. *Med J Aust* 1988 Sep;149(6):320-2
22. Sipe JC. Leigh's syndrome: the adult form of subacute necrotizing encephalomyelopathy with predilection for the brainstem. *Neurology* 1973 Oct;23(10):1030-8
23. Whetsell WO Jr, Plaitakis A. Leigh's disease in an adult with evidence of "inhibitor factor" in family members. *Ann Neurol* 1978 Jan;3(6):519-21
24. Kepes JJ. Oncocytic transformation of choroid plexus epithelium. *Acta Neuropathol* 1983;62 (1-2)145-8
25. Delgado G, Gallego J, Tunon T, Zarranz JJ, Villaneuva JA. Necrotizing haemorrhagic encephalomyelopathy in an adult: ?Leigh's disease. *J Neurol Neurosurg Psychiatry* 1987 Feb;50(2):224-7
26. Davis PC, Hoffman JC Jr, Braun IF, Ahmann P, Krawiecki N. MR of Leigh's disease (subacute necrotizing encephalomyelopathy). *AJNR* 1987 Jan-Feb;8(1):71-5
27. Shoffner JM, Fernhoff PM, Krawiecki NS, Caplan DB, Holt PJ, Koontz DN, Takei Y, Newman NJ, Ortiz RG, Polak M, Ballinger S, Lott MT, Wallace DC. Subacute necrotizing encephalomyelopathy: oxidative phosphorylation defects and the ATPase 6 point mutation. *Neurology* 1992 Nov;42(11):2164-74