

9-1-1994

Unusual neurological features in leukocytoclastic vasculitis

Erawady Mitrabhakdi

Kammant Phanthumchinda

Nopadon Nopakoon

Follow this and additional works at: <https://digital.car.chula.ac.th/clmjournal>



Part of the [Medicine and Health Sciences Commons](#)

Recommended Citation

Mitrabhakdi, Erawady; Phanthumchinda, Kammant; and Nopakoon, Nopadon (1994) "Unusual neurological features in leukocytoclastic vasculitis," *Chulalongkorn Medical Journal*: Vol. 38: Iss. 9, Article 7.

DOI: 10.58837/CHULA.CMJ.38.9.7

Available at: <https://digital.car.chula.ac.th/clmjournal/vol38/iss9/7>

This Case Report is brought to you for free and open access by the Chulalongkorn Journal Online (CUJO) at Chula Digital Collections. It has been accepted for inclusion in Chulalongkorn Medical Journal by an authorized editor of Chula Digital Collections. For more information, please contact ChulaDC@car.chula.ac.th.

Unusual neurological features in leukocytoclastic vasculitis

Erawady Mitrabhakdi*

Kammant Phanthumchinda* Nopadon Nopakoon*

Mitrabhakdi E, Phanthumchinda N, Nopakoon N. Unusual neurological features in leukocytoclastic vasculitis. Chlua Med J 1994 Sep; 38(9): 537-543

Two cases of leukocytoclastic vasculitis with nervous system involvement were reported. The cutaneous manifestations were confirmed by skin biopsy. Nervous system manifestations included retinal vasculitis, subarachnoid hemorrhage, aseptic meningitis, encephalopathy, generalized seizures with postictal focal neurological deficit, cranial nerve palsy, and positional vertigo. The fundoscopic findings were classic and reflected the pathological changes in small vessels, especially venules. The precipitating agents were a non - specific viral infection in one case and mumps in the anther case. The neuroloigical as well as the cutaneous changes responded dramatically to systemic corticosteroid.

Key words: *Leukocytoclastic vasculitis, Nervous system manifestations.*

Reprint request: Phanthumchinda K. Department of Medicine, Faculty of Medicine
Chulalongkorn University, Bangkok 10330, Thailand.

Receved for publication. August 18, 1994.

* Department of Medicine, Faculty of Medicine, Chulalongkorn University.

เอระวดี มิตรภักดี, กัมมันต์ พันธุมจินดา, นพดล นพคุณ. อาการแสดงทางระบบประสาทซึ่งไม่พบบ่อยในโรคอักเสบของหลอดเลือดชนิดลิวโคไซโตคลาสติค. จุฬาลงกรณ์เวชสาร 2537 กันยายน; 38(9): 537-543

รายงานผู้ป่วย leukocytoclastic vasculitis 2 ราย ที่มีภาวะแทรกซ้อนทางระบบประสาท รอยโรคทางผิวหนังยืนยันจากการทำการตรวจชิ้นเนื้อผิวหนัง อาการแทรกซ้อนทางระบบประสาทที่พบ ได้แก่ หลอดเลือดในจอตาอักเสบ การตกเลือดในห้วงใต้เยื่ออะแรคนอยด์ เยื่อหุ้มสมองอักเสบแบบปราศจากเชื้อ สมองอักเสบ ภาวะชักทั่วตัว และมีอาการแสดงเฉพาะที่หลังชัก เส้นประสาทสมองพิกการ และอาการเวียนศีรษะเมื่อมีการเปลี่ยนท่า การตรวจจอตามีลักษณะเด่นที่สำคัญคือ การอักเสบของหลอดเลือดดำเล็ก ๆ สาเหตุที่กระตุ้นให้เกิดการอักเสบของหลอดเลือดดังกล่าวพบว่าเป็นการติดเชื้อไวรัสที่ไม่จำเพาะ 1 ราย และเป็นผลตามมาของการติดเชื้อไวรัสคางทูม 1 ราย อาการทางระบบประสาทและทางผิวหนังในผู้ป่วยทั้ง 2 ราย ตอบสนองอย่างรวดเร็วต่อการรักษาด้วยการให้คอร์ติโคสเตียรอยด์

The clinical spectrum of vasculitis comprises some of the most interesting and diverse syndromes in clinical medicine.⁽¹⁻³⁾ Leukocytoclastic vasculitis includes a heterogeneous group of clinical syndromes and is characterized by inflammation of small vessels such as postcapillary venules, capillaries, arterioles and venules.⁽⁴⁾ Patients with cutaneous leukocytoclastic vasculitis have rarely been reported to have coincident neurologic diseases. We wish to report neurological presentations of this vasculitic syndrome in the form of neuro-ophthalmologic findings, encephalopathy, convulsion and transient focal neurological deficit, cranial neuropathy, positional vertigo, aseptic meningitis and subarachnoid hemorrhage. The neuro-ophthalmologic manifestation should be considered as an important diagnostic clue for this disease.

Case reports

Case 1.

A 30 year-old woman presented with headache, blurring of vision, position related vertigo and skin rash. Eight days prior to admission she had a low grade fever, diffuse dull aching headache, blurring of vision and enlarged left submandibular lymph nodes. Four days later she developed vertigo aggravated by changing to the erect position which improved by lying down. Three days before admission she had a tender erythematous rash distributed in patches on all extremities but predominantly on her legs. Her headache increased and marked stiffness of the neck was noted.

Her past medical history was unremarkable. The temperature was 38.3°C, the pulse 84/min, the respiration 20/min and the blood pressure 120/80 mmHg. Systemic examination disclosed two enlarged left submandibular lymph

nodes, 1 X 2 cm in diameter. Tender erythematous papules 0.5-1.5 cm in diameter were observed along both arms and legs. Neuro-ophthalmologic examination revealed visual acuity of 20/20 (right), 20/100 (left), vasculitis (mainly phlebitis, rare arteritis), sheathing of retinal veins, candle-wax exudates along affected retinal vessels, intraretinal hemorrhage and exudates on the left optic disc (Figure 1). Meningeal signs were also detected. No other focal neurological deficits were present.

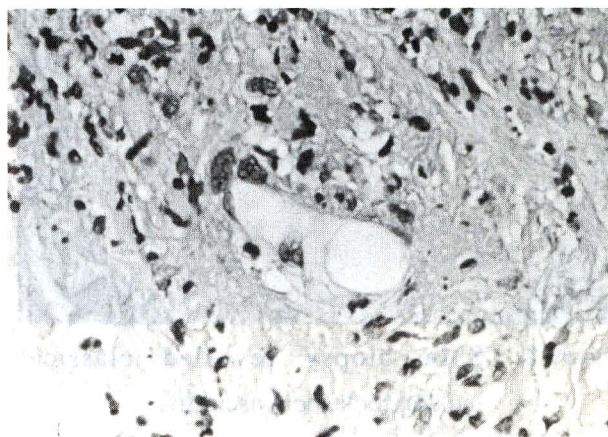


Figure 1. Retinal vasculitis (mainly phlebitis, rare arteritis), Sheathing of retinal veins, candle wax exudates along affected retinal vessels and intraretinal hemorrhage and exudates.

The urine was normal. The hemoglobin was 16.1 g/dl, the hematocrit was 44%, the white blood cell count was 7,200/mm³ with 78% neutrophils, 15% lymphocytes and 7% monocytes. The erythrocyte sedimentation rate was 100 mm/hr. Blood chemistries were normal. VDRL and FTA-ABS were non-reactive. Anti-HIV and HBsAg were negative. ANA and cryoglobulin were negative and complement levels were normal. Chest x-ray and CT-scan of the brain were unremarkable. CSF was xanthochromic and contained 12 lymphocytes and 2,520 red cells/mm³. CSF

protein was 100 mg/dl, CSF glucose 53 mg/dl. A skin biopsy was compatible with leukocytoclastic vasculitis (Figure 2). She dramatically responded to prednisolone 60 mg/day. The vision improved in one day and was normal within 3 days. The eyeground abnormality, vertigo, headache and neck stiffness returned to normal within 2 weeks. The rash disappeared on the fourth day of admission.

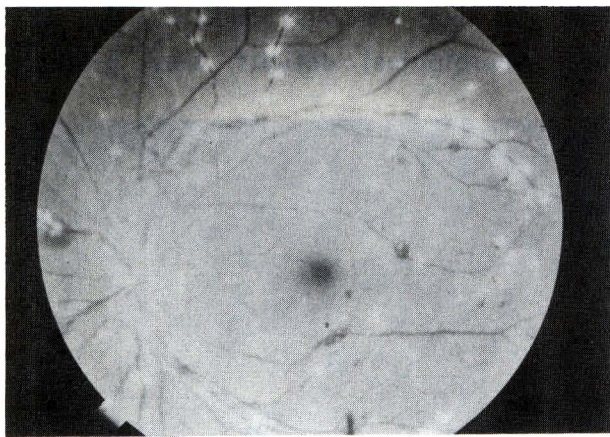


Figure 2. Skin biopsy revealed classical leukocytoclastic vasculitis.

Case 2.

A 13 year-old boy presented with a history of fever, myalgia, sore throat and headache 2 weeks before admission. Cervical lymphadenopathy was detected 2 days later. Ten days before admission he developed a high grade fever and a persistently severe headache predominantly between the eyebrows. Eight days prior to admission painful swollen testes were observed and he was diagnosed as a case of mumps orchitis. Two days later he became confused, restless and had nausea and vomiting. Four days prior to admission he had two episodes of generalized seizures. He also experience postictal right hemiparesis together with diplopia and medial squint of both eyes. His past medical history was unremarkable and no history of febrile seizures was disclosed.

The temperature was 37.8°C, the pulse 84/min, the respiration 16/min and the blood pressure 110/70 mmHg. Systemic examination reveals a generalized erythematous maculopapular eruption on the trunk and on all extremities. Neuro-ophthalmologic examination revealed normal visual acuity, normal optic discs, periphlebitis with candle-wax exudates around the retinal veins and retinal hemorrhage, all of which were more marked on the left. Pupillary light reflexes were normal. Paresis of cranial nerve VI was observed on the left.

The hemoglobin was 12.5g/dl, hematocrit 39%, white cell count 8,600/mm³ with 81% neutrophil and 19% lymphocytes. The erythrocyte sedimentation rate was 65 mm/hr. A urinalysis was normal. Blood chemistries, serologic tests for syphilis, anti-HIV and HBsAg were all negative. ANA, cryoglobulin and complement tests were normal. CSF was clear and contained 65/mm³ red blood cells, 42/mm³ white blood cells (80% plasma cells, 20% lymphocytes). Protein was 35 mg/dl and CSF glucose were 58 mg/dl. Chest x-ray, CT-scan of the brain and EEG were normal. A skin biopsy was compatible with leukocytoclastic vasculitis.

He was treated with prednisolone 60 mg/day. The skin rash, eye ground abnormalities and neurological deficits as well as fever subsided within 3 days, 2 weeks and 1 week respectively.

Discussion

The diagnosis of leukocytoclastic vasculitis is established by findings of small vessel inflammation, usually with a leukocytoclastic pattern.⁽¹⁻⁵⁾ Although the skin is the most common and readily available site for biopsy, the vasculitic changes seen in neuro-

ophthalmologic examinations may be one of the diagnostic clues. Both of our cases had retinal vasculitides paralleled with the skin lesions. Retinal changes in collagen disease have been reported in lupus erythematosus, scleroderma, dermatomyositis, polyarteritis nodosa and rheumatoid arthritis.⁽⁶⁾ The main abnormality consists of cotton-wool spots which are more numerous than the number of hemorrhages. This fundoscopic picture suggests a microarteriolar as opposed to a venular process.⁽⁶⁾ In contrast, the retinal vasculitis detected in our cases consisted of inflammatory changes occurring mainly in relationship to retinal venules. These ophthalmologic changes have been detected in sarcoidosis, Behcet disease, infectious diseases (tuberculosis, cytomegaloviral infection, syphilis), multiple sclerosis with phlebitis, autoimmune vasculitis and some cases of SLE, periarteritis nodosa, Wegener's granulomatosis and Goodpasture's syndrome.⁽⁶⁾ However, clinical profiles and laboratory investigations could exclude these diseases in our cases.

Recently, anti-neutrophil cytoplasmic autoantibodies (ANCA) have been reported as a serologic marker for various types of vasculitides, ranging from multisystemic vasculitis, such as Wegener granulomatosis and polyarteritis nodosa, to idiopathic crescentic glomerulonephritis.^(7,8) In the series of 70 ANCA-positive patients reported by Falk et al,⁽⁸⁾ fifteen of their patients had clinical manifestations of polyarteritis nodosa involving skin, peripheral nervous system, joints, upper respiratory tract and kidneys. 37 of their patients had clinical and pathological findings consistent with Wegener granulomatosis. Positive ANCA may also be present in the active

phase of allergic granulomatosis.⁽¹⁰⁾ None of our patients had clinical and pathological manifestations of Wegener granulomatosis or allergic granulomatosis. Even though polyarteritis nodosa could not be totally ruled out, the biopsy from our cases definitely showed leukocytoclastic vasculitis of the small blood vessels, not the medium-sized artery typically involved in polyarteritis nodosa.

Positive ANCA had been reported in patients who had leukocytoclastic vasculitis and palpable purpura.⁽⁸⁾ But all of these patients had renal involvement. To the best of our knowledge, there has been no report in the literature of an association between positive ANCA and neurological complications in cutaneous leukocytoclastic vasculitides without renal diseases as in our cases. Unfortunately, we could not perform the tests for ANCA in our hospital during the period of this study. Otherwise, it would be very interesting to see whether there is any association between ANCA and cutaneous leukocytoclastic vasculitis with neurological complications.

A wide range of conditions may cause leukocytoclastic vasculitis which may in turn produce neurological damage.⁽¹¹⁻¹⁶⁾ One of our patients had nonspecific viral prodromes prior to the development of vasculitis and one patient had the clinical syndrome of mumps. The possibility that both cases are related to the initial viral illness could be raised. Neurological involvement is not a prominent feature of the cutaneous leukocytoclastic vasculitis.⁽¹⁷⁻²⁰⁾ Encephalopathy, hemiparesis, polyneuropathy, mononeuritis multiplex, diplopia and dysphagia have been reported.^(11-13,17-20) We have added neuro-ophthalmologic changes, aseptic meningitis, subarachnoid hemorrhage, encephalopathy, convulsion with

postictal hemiparesis, and positional vertigo as unusual neurological features in this entity.

The prognosis of leukocytoclastic vasculitis is related to the extent and severity of systemic diseases⁽¹⁾, but it is generally not a life-threatening process. Certain leukocytoclastic vasculitis syndrome manifests a tendency toward spontaneous resolution and there are few data to indicate that any mode of therapy consistently alters the course of the disease. However, in patients with significant systemic involvement, as in ours, prednisolone given orally with tapering off according to the disease activity should be employed. The response in our cases was dramatic and the duration of medication was 3-4 weeks. No recurrent attacks of the disease occurred after more than two years of follow-up.

References

1. Cupp TR, Fauci AS. The Vasculitides. Philadelphia: WB Saunders, 1981
2. Wolff K, Winkebank RK, Vasculities, Major Problems in Dermatology. Vol 10. London; Loyd-Luke, 1980
3. Fauci AS, Haynes BF, Kartz P. The spectrum of vasculitis. Clinical, pathological, immunologic and therapeutic considerations. *Ann Intern Med* 1978 Nov; 89(5pt 1):660-76
4. Cox AJ. pathologic changes in hypersensitivity angiitis. In: Helwing EB, Mostofi FK, eds. The Skin. Baltimore: William & Wilkins, 1971:279-92
5. Gammon R. Leukocytoclastic vasculitis. *Clin Rheum Dis* 1982 Aug; 8(2):397-413
6. Cogan DG. Fundus signs in systemic vascular disease. In: Cogan DG, ed. Ophthalmic Manifestations of Systemic Vascular Disease. Philadelphia: W.B. Saunders, 1974:74-101
7. Jennette JC, Falk RJ. Antineutrophil cytoplasmic autoantibodies and associated diseases: a review. *Am J Kidney Dis* 1990; 15:517-29
8. Jennette JC, Wilkman AS, Falk RJ. Anti-neutrophil cytoplasmic autoantibodies-associated glomerulonephritis and vasculitis. *Am J Pathol* 1989 Nov; 135(5):921-30
9. Falk RJ, Hogan S, Carey TS, Jennette JC. Clinical course of anti-neutrophil cytoplasmic autoantibody-associated glomerulonephritis and systemic vasculitis. *Ann Intern Med* 1990 Nov; 113(9):656-63
10. Wathen CW, Harrioon DJ. Circulating anti-neutrophilic antibodies in systemic vasculitis. *Lancet* 1987 May 2; 1 (8540): 1037
11. Ramsay C, Fry L. Allergic vasculitis: Clinical and histological features and incidence of renal involvement. *Br J Dermatol* 1969 Feb; 81(2):96-102
12. Sams WM Jr., Thorne EG, Small P, Mass MF, McIntosh RM, Standrod RE. Leukocytoclastic vasculitis. *Arch Dermatol* 1976 Feb; 112(2): 219-26
13. Miller DH, Maas LF, Teague C, Neale TJ. Small vessel vasculitis presenting as neurological disorder. *J Neurol Neurosurg Psychiatry* 1984 Aug; 47(8):791-4
14. Heath-Homes M, Eahradka SL. Bachge BA. Wolf RE. Leukocytoclastic vasculitis associated with hepatitis C. *Am J Med* 1991 Jun; 90(6):765-6
15. Vernier RL, Worthen HG, Petersan RD, Colle E, Good RA. Anaphylactoid purpura I: Pathology of the skin and

- kidney and frequency of streptococcal infection. *Pediatrics* 1961 Feb; 27(2): 181-93
16. Puavilai S, Timpaṭanapong P, Rajatanavin N, Charuwichitratana S, Polnikom N. Cutaneous leukocytoclastic vasculitis: clinical and laboratory features of 45 patients seen in Ramathibodi hospital. *J Med Assoc Thai* 1990 May; 73(5): 269-73
17. Riggs JE. Neurological consequences of systemic disease. In: Bradly WG, Daroff RB, Fenichel GM, Marsden CD, eds. *Neurology in Clinical Practice* II. Boston: Butterworth Heinemann, 1991:841-60
18. Moore PM, Fauci AS. Neurologic manifestations of systemic vasculitis: a retrospective and prospective study of the clinicopathologic features and response to therapy in 25 patients. *Am J Med* 1981 Oct; 71(4):517-24
19. Moore PM, Cupps TR. Neurological complications of vasculitis. *Ann Neurol* 1983 Aug; 14(2):155-67
20. Sigal LH. The neurologic presentation of vasculitis and rheumatologic syndromes: a review. *Medicine* 1987 May; 66(3): 157-80