

2-1-1995

## Lower lip reconstruction :(Modified Webster-Bernard Technique)

Prayuth Chokrungruanont

Follow this and additional works at: <https://digital.car.chula.ac.th/clmjournal>



Part of the [Medicine and Health Sciences Commons](#)

---

### Recommended Citation

Chokrungruanont, Prayuth (1995) "Lower lip reconstruction :(Modified Webster-Bernard Technique)," *Chulalongkorn Medical Journal*: Vol. 39: Iss. 2, Article 6.

DOI: 10.58837/CHULA.CMJ.39.2.6

Available at: <https://digital.car.chula.ac.th/clmjournal/vol39/iss2/6>

This Case Report is brought to you for free and open access by the Chulalongkorn Journal Online (CUJO) at Chula Digital Collections. It has been accepted for inclusion in Chulalongkorn Medical Journal by an authorized editor of Chula Digital Collections. For more information, please contact [ChulaDC@car.chula.ac.th](mailto:ChulaDC@car.chula.ac.th).

## **Lower lip reconstruction : (Modified Webster-Bernard Technique)**

Prayuth Chokrungruanont\*

**Chokrungruanont P. Lower lip reconstruction : (Modified Webster-Bernard Technique). Chula Med J 1995 Feb; 39(2): 119-127**

*Cancer of the lower lip is not uncommon in Thailand. After wide excision of the lesion, the resulting defect requires reconstruction for restoration of function and appearance.*

*A simple and reliable technique of lower lip reconstruction is presented.*

**Key words :** *Lip, Reconstruction.*

Reprint request : Chokrungruanont P. Department of Surgery, Faculty of Medicine,  
Chulalongkorn University, Bangkok 10330, Thailand.

Received for publication. January 10, 1995.

---

\*Department of Surgery, Faculty of Medicine, Chulalongkorn University.

ประยุทธ์ โขครุ่งวรานนท์. การเสริมสร้างริมฝีปากล่าง โดยดัดแปลงเทคนิคของเว็บสเตอร์-เบอร์นาร์ด. จุฬาลงกรณ์เวชสาร 2538 กุมภาพันธ์ ; 39(2): 119-127

มะเร็งของริมฝีปากพบได้ไม่น้อยในประเทศไทย การรักษาเพื่อหวังผลให้หายขาดนั้น จำเป็นต้องตัดก้อนมะเร็งนั้นพร้อมกับเนื้อเยื่อรอบๆ ก้อนมะเร็งออกเป็นบริเวณกว้าง ทำให้เกิดการแห้วหายไของริมฝีปากนั้นๆ ซึ่งจำเป็นต้องได้รับการสร้างเสริมขึ้นมาใหม่ เพื่อให้รูปร่างและการทำงานของริมฝีปากนั้นๆ ใกล้เคียงกับปกติมากที่สุด

นำเสนอผู้ป่วยที่ได้รับการผ่าตัดเสริมสร้างริมฝีปากล่างโดยใช้เทคนิคที่คิดว่าง่าย, เชื่อถือได้ และได้ผลดี

The lip is responsible for many important functions such as:

- Act as an airtight sphincter to contain liquids and solids at rest as well as during chewing.
- It is important in speech to form sounds such as "b", "p", "m", "w", "f", and "v".
- It has important social functions in the forming of facial expressions and kissing.
- The mouth must be large enough for normal eating and to insert and remove dentures.

Any lip deformity will create both physical and psychological disabilities which require reconstruction. We would like to present some cases of lower lip reconstruction using the modified Webster-Bernard technique.

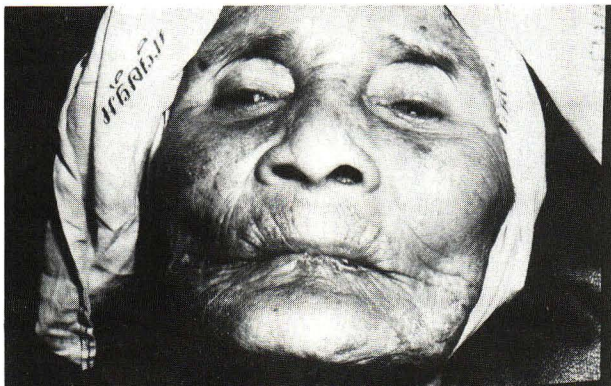

Figure 1,2. Shows the lesion at the lower lip.

**Case 1:** A 77 year old female presented with a painful 1 x 3 cm. ulcerative nodular mass on the lower lip for 8 months (Figures 1 & 2). There were no palpable cervical lymph nodes. The pathological biopsy report was a well-differentiated squamous cell carcinoma.

Figure 3. shows the defect created after excision which involved about 90% of the lower lip. The protruding tongue and the remaining lower lip near the commissure are clearly visible. Lip reconstruction using the modified Webster-Bernard technique was undertaken (Figure 4). The technical details are as follows.

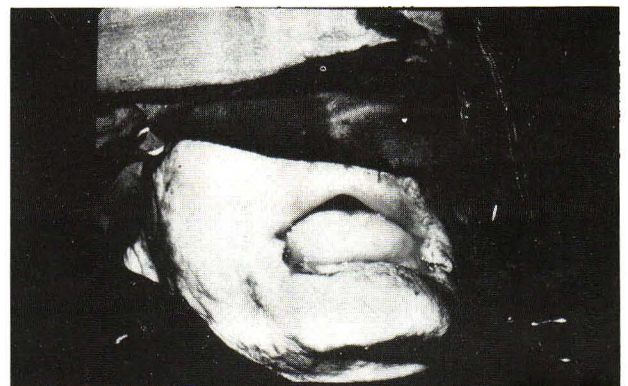

Figure 3. Shows the defect about 90% of the lower lip.

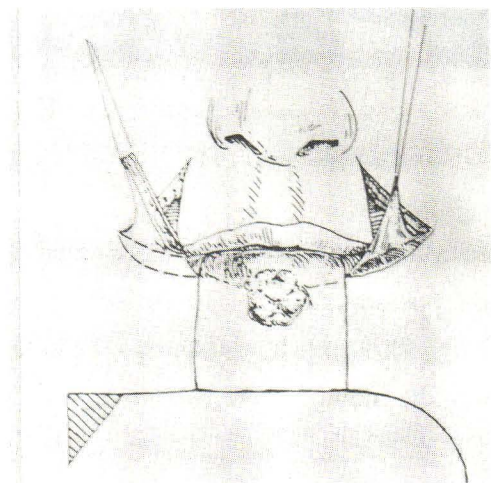
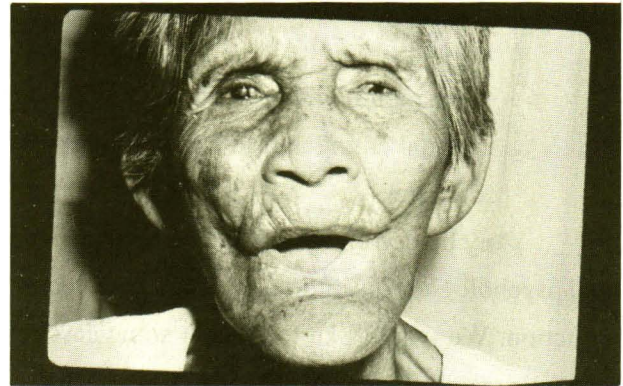



Figure 4. The modified Webster-Bernard technique.

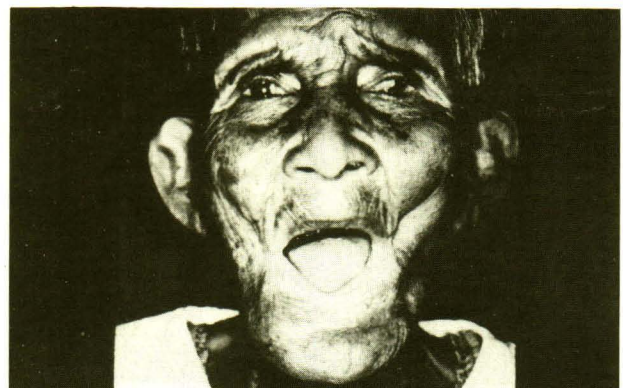
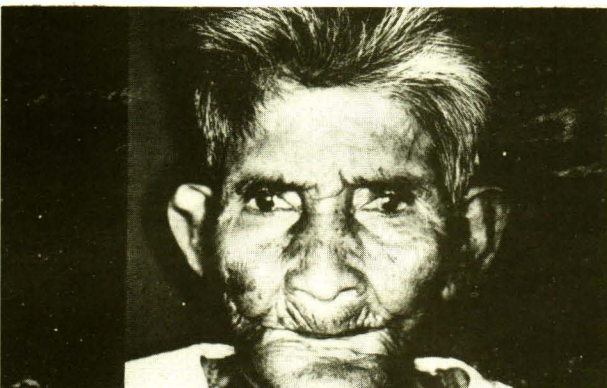

- The tumor was excised as a quadrilateral segment.
- Incisions were extended outward from the commissures.
- The triangulars of the skin were removed lateral to the upper lip and this provided relief space to advance the bilateral lower cheek flaps medially.

- The flaps of the buccal mucous membrane were left to provide the new vermillion for the lip.
- The lower cheek flaps incisions were extended inferiorly along the mental fold. In this way innervated muscle was brought into the new lip to provide a sensate, cosmetically superior, water-tight and functioning lip.



**Figure 5,6.** The appearance 3 months post-operation.



**Figure 7,8.** The appearance 2 years after operation.

Figure 5 and 6 show the patient's appearance 3 months post-operation. The patient could speak and eat well despite some degree of limitation in opening the mouth. There was no drooling.

Figure 7 and 8 show the appearance 2 years after operation. The patient could open her mouth wider. There was no recurrence of the cancer.



### CONCLUSIVE FIGURES:

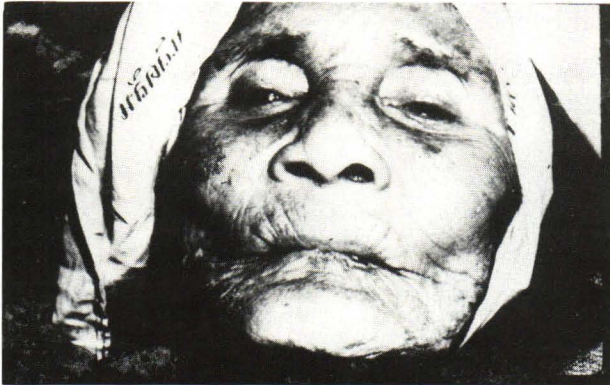

Figure 9. The appearance before operation.

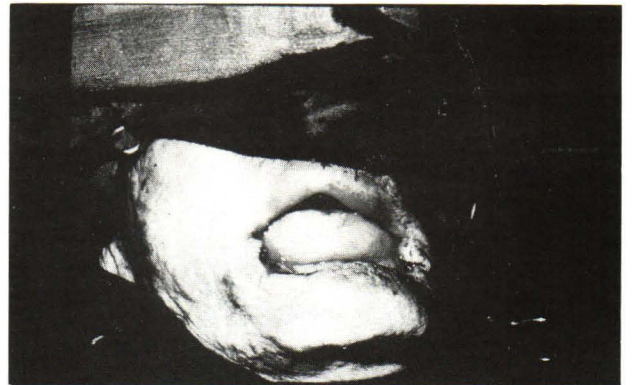

Figure 10. The defect after excision the cancer at the lower lip.

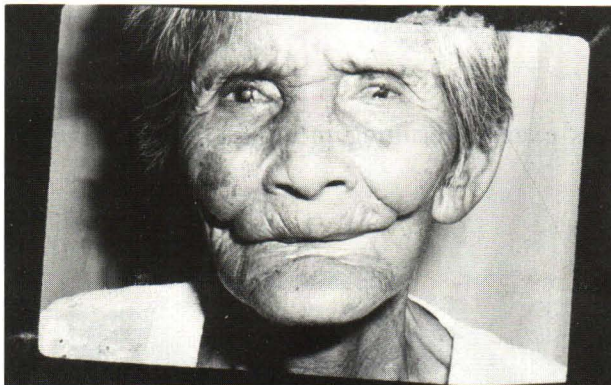


Figure 11. The appearance 3 months post-operation.

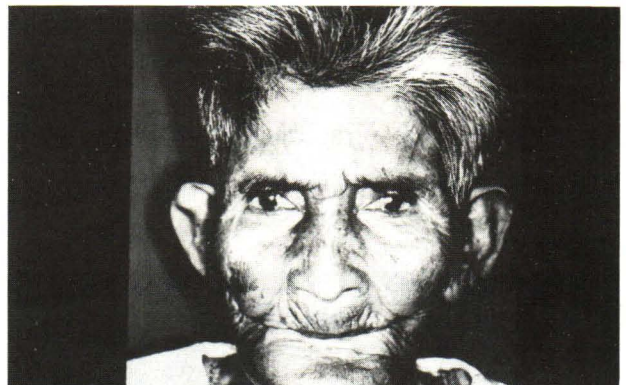

Figure 12. The appearance 2 years post-operation.

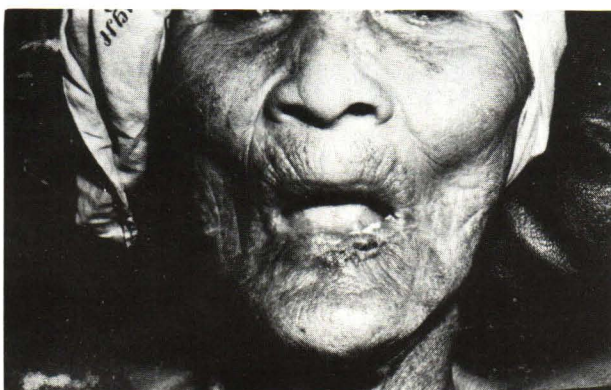

Figure 13. The lesion before operation.

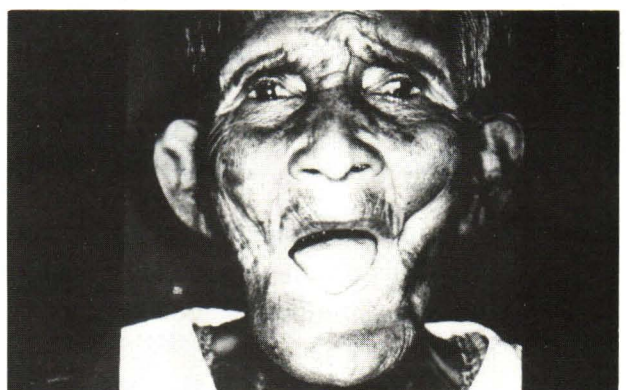
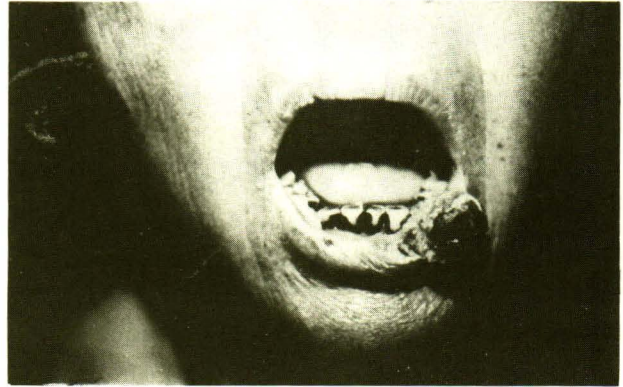
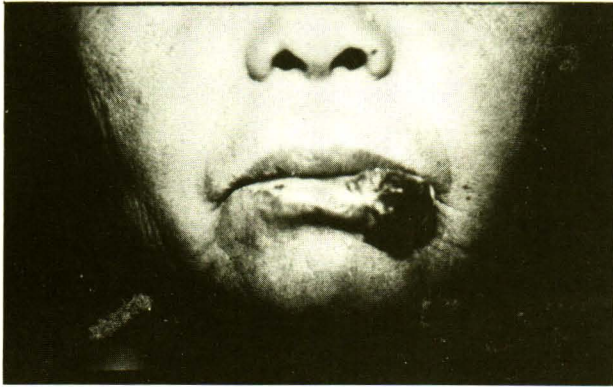
Figure 14. The appearance 2 years after operation.

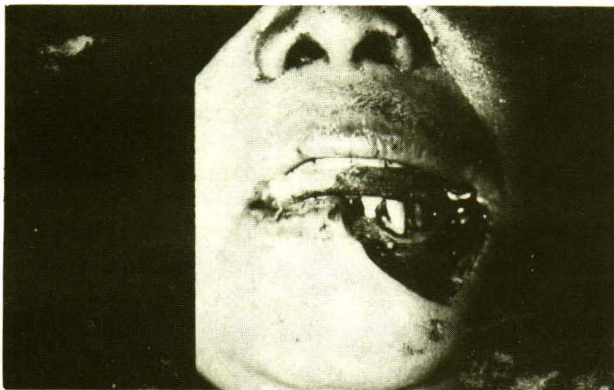


**Case 2:** A 58 year-old female presented with a slow growing nodular mass 2 cm. in diameter which had been on the lower lip for about 2 years (Figures 15 & 16). The biopsy result was a well-differentiated squamous cell carcinoma. There were no palpable cervical lymph nodes.

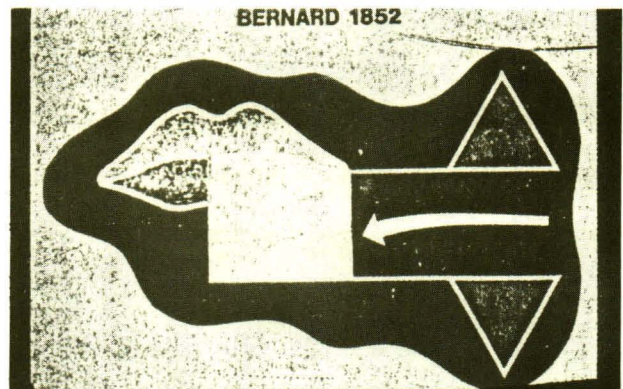


**Figure 15,16.** The lesion before the operation.

Under mental and infraorbital nerve block, the mass was excised resulting in an approximately 60% defect of the lower lip (Figures 17 & 18 ).



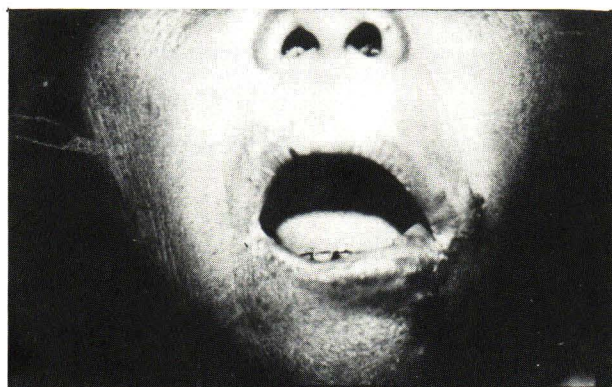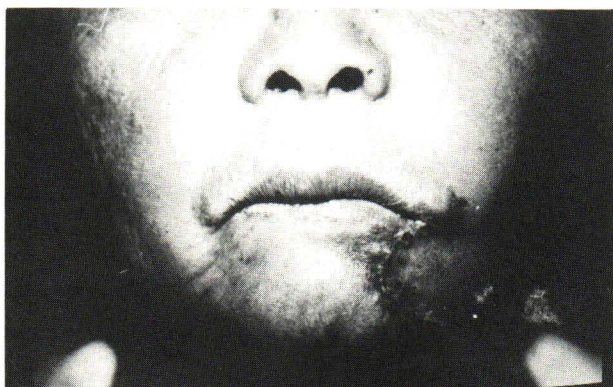**Figure 17.** The defect about 60% of the lower lip. This operation undertaken under mental and infraorbital nerve block.



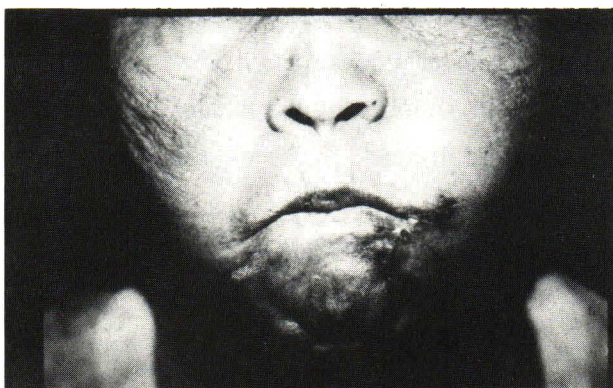**Figure 18.** The modified Wedster-Bernard technique.



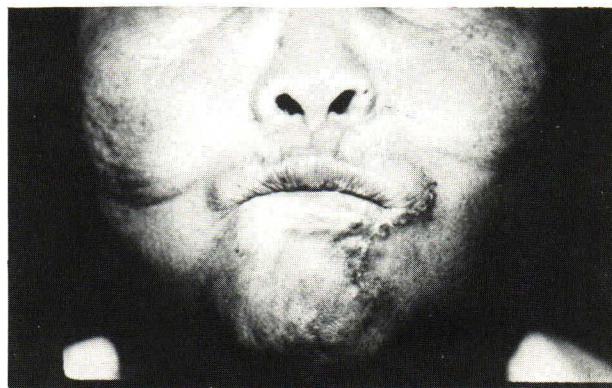The patient looked well 2 weeks after operation. She could use the orbicularis oris for such things as blowing and kissing (Figures 19, 20, 21, 22).



**Figure 19, 20.** The appearance 2 weeks after operation.



**Figure 21.** The patient used the orbicularis oris for blowing at 2 weeks after operation.



**Figure 22.** The patient used the orbicularis oris for kissing at 2 weeks post-operation.

## Discussion

A wide variety of procedures for repair of lip defects have been described and redescribed over the past 2,000 years.<sup>(1-3)</sup>

1000 B.C. - Sushruta

First mention of labial repair.

25 B.C. - Celsus

First wedge excision and direct suture.

1834 - Dieffenbach

Lower lip repair with two inferiorly based cheek flaps lined with mucosa.

(Modified by May 1941.)



1853	- Bernard	Lower lip repair with advancement of laterally-based cheek flaps.
	(Modified by	- Burow 1855.
		- Freeman 1958.
		- Webster 1960.
		- Meyer-Abul-Failat 1982. <sup>(4)</sup> )
1857	- Von Brun	Nasolabial flaps for lower lip defect, curvilinear incision for oral sphincter reconstruction.
1872	- Estlander	Lateral triangular upper lip flap for lower lip reconstruction.
1898	- Abbe	A portion of upper lip flap for lower lip reconstruction.
1957	- Gilles fan flap	An extended version of the Estlander flap.
1969	- Bakamjian	Deltpectoral flap for lower lip defect.
1974	- Johanson <sup>(5)</sup>	Lateral full-thickness advancement flaps from the remaining parts of the lower lip prepared in stepwise fashion.
1974	- Karapandzic	Emphasis on oral sphincter reconstruction.
1980	- Fujimuri <sup>(6)</sup>	Nasolabial "Gate Flap" supplied by the facial vessels.
1983	- Stranc & Robertson <sup>(7)</sup>	"Steeple Flap" using a full-thickness cheek island flap based on the facial vessels.
1983	- McGregor <sup>(8)</sup>	Modified fan flap supplied by the superior labial vessels.
1984	- Nakajima <sup>(9)</sup>	Modified the McGregor flap based on the facial vessels.

### The goals of the lip reconstruction are

- 1) Restoration of the appearance.
- 2) Reinstitution of functions such as
  - eating
  - speech
  - prevention of drooling

**To achieve these goals,** the procedure should be comprised of:

- 1) Reconstitution of the oral sphincter
- 2) Reconstruction of an adequate lip sulcus
- 3) Preserving good sensation and muscle tone without any narrowing

Since no single flap technique is ideal for every instance, surgeons undertaking lip reconstruction should be acquainted with and experienced in a wide range of procedures available and they should be aware of the various indications and limitations.

We have used the modified Webster-Bernard technique to reconstruct lower lip defects in our patients. The results were very satisfactory both in terms of appearance and functions as shown in this paper. The patients were very happy with the results. They could speak and eat well without any drooling.

## Conclusion

The modified Webster-Bernard technique in lower lip reconstruction is a simple and one-stage operation which gives good results. The author recommends this procedure for suitable patients.

## References

1. Hugo N. Basic principles of reconstruction of the lip, oral commissure, and cheek. In: Georgiade GS, Georgiade NG, Riefkohl R, Barwick WJ, eds. Textbook of Plastic, Maxillofacial and Reconstructive Surgery. Baltimore: Williams & Wilkins, 1992: 527-30
2. Zide BM. Deformities of the lips and cheeks. In: McCarthy JG, ed. Plastic Surgery. Philadelphia: WB, Saunders, 1990:2009-56
3. Tobin GR. Lip reconstruction. In: Marsh JL, ed. Current Therapy in Plastic and Reconstructive Surgery. Philadelphia: BC, Decker 1989:357-62
4. Meyer R, Abul Failat AS. New concepts in lower lip reconstruction. Head Neck Surg 1982 Jan-Feb; 4(3):240-5
5. Johanson B, Aspelund E, Breine U, Holmstrom H. Surgical treatment of non-traumatic lower lip lesions with special reference to the step technique. A follow-up on 149 patients. Scand J Plast Reconstr Surg 1974; 8(3):232-40
6. Fujimori R. 'Gate flap' for the total reconstruction of the lower lip. Br J Plast Surg 1980 Jul; 33(3):340-5
7. Stranc MF, Robertson GA. Steeple flap reconstruction of the lower lip. Ann Plast Surg 1983 Jan; 10(1):4-11
8. McGregor IA. Reconstruction of the lower lip. Br J Plast Surg 1983 Jan; 36(1):40-7
9. Nakajima T, Yoshimura Y, Kami T. Reconstruction of the lower lip with a fun-shaped flap based on the facial artery. Br J Plast Surg 1984 Jan; 37(1):52-4