

3-1-1995

## Ovarian mass : an initial manifestation of malignant lymphoma

Vira Kasantikul

Prasert Trivijitsilp

Pongsak Wannakrairot

Follow this and additional works at: <https://digital.car.chula.ac.th/clmjournal>



Part of the [Medicine and Health Sciences Commons](#)

---

### Recommended Citation

Kasantikul, Vira; Trivijitsilp, Prasert; and Wannakrairot, Pongsak (1995) "Ovarian mass : an initial manifestation of malignant lymphoma," *Chulalongkorn Medical Journal*: Vol. 39: Iss. 3, Article 6.

DOI: 10.58837/CHULA.CMJ.39.3.5

Available at: <https://digital.car.chula.ac.th/clmjournal/vol39/iss3/6>

This Case Report is brought to you for free and open access by the Chulalongkorn Journal Online (CUJO) at Chula Digital Collections. It has been accepted for inclusion in Chulalongkorn Medical Journal by an authorized editor of Chula Digital Collections. For more information, please contact [ChulaDC@car.chula.ac.th](mailto:ChulaDC@car.chula.ac.th).

## Ovarian mass : an initial manifestation of malignant lymphoma.

Vira Kasantikul\*

Prasert Trivijitsilp\*\* Pongsak Wannakrairot\*

**Kasantikul V, Trivijitsilp P, Wannakrairot P. Ovarian mass : an initial manifestation of malignant lymphoma. Chula Med J 1995 Mar; 39(3): 207-212**

*Two cases of ovarian mass as the initial manifestation of malignant lymphoma are described. The diagnosis of the disease depended on the characteristic microscopic and immunohistochemical features. The lesion in one instance was unusual, showing diffuse large cells and signet-ring cells of B-cell lineage in association with serous cystadenoma of the opposite ovary. Review of the literature revealed that such malignant tumors were uncommon in children or patients older than 70 years. The most common symptoms were abdominal mass and/or pain. Radical surgery should be avoided in high risk patients with bilateral ovarian masses and when there is evidence of multiple lymph node or other organ involvement. Chemotherapy is useful particularly for diffuse large cell lymphoma. Therapy selection should depend on clinical staging and histological typing of the tumors. A poorer prognosis is expected in patients with generalized disease as opposed to patients with a localized lesion at the time of diagnosis.*

**Key words:** Ovarian lymphoma, B-cell lineage, Signet-ring cell, T-cell lineage.

Reprint request : Kasantikul V. Departments of Pathology, Faculty of Medicine,  
Chulalongkorn University, Bangkok 10330, Thailand.

Received for publication. February 28, 1995.

---

\* Department of Pathology, Faculty of Medicine, Chulalongkorn University.

\*\* Department of Obstetric Gynecology, Faculty of Medicine, Chulalongkorn University.

**วีระ กษานติกุล, ประเสริฐ ตริวิจิตรศิลป์, พงษ์ศักดิ์ วรรณไกรโรจน์. ก้อนรังไข่ : อาการนำของลิมโฟมา. จุฬาลงกรณ์เวชสาร 2538 มีนาคม; 39(3): 207-212**

ได้รายงานผู้ป่วย 2 รายที่มีก้อนของรังไข่เป็นอาการเริ่มแรกของลิมโฟมา การวินิจฉัยอาศัยลักษณะทางจุลพยาธิวิทยาและกรรมวิธีทางอิมมูโนฮิสโตเคมี รอยโรคในผู้ป่วยรายหนึ่งประกอบด้วยเซลล์มะเร็งขนาดใหญ่ และเซลล์คล้ายหัวแหวน (signet-ring) ของรังไข่ข้างหนึ่งร่วมกับ ถุงน้ำของรังไข่ด้านตรงข้าม การทบทวนวารสารพบว่า ลิมโฟมาของรังไข่พบได้น้อยในเด็ก หรือผู้ป่วยอายุมากกว่า 70 ปี อาการที่พบบ่อยที่สุดคือก้อนในช่องท้องและ/หรืออาการปวด การผ่าตัดใหญ่ควรหลีกเลี่ยงในผู้ป่วยที่มีความเสี่ยงสูง อาทิเช่น พบเนื้อร้ายที่รังไข่ทั้งสองข้างร่วมกับมะเร็งของต่อมน้ำเหลือง หรือแพร่ไปยังอวัยวะอื่น ๆ เคมีบำบัดมีประโยชน์สำหรับลิมโฟมาชนิด diffuse large cell แนวทางรักษาร่วมกับการกลูกลามของเนื้อร้าย และชนิดของเซลล์มะเร็ง การพยากรณ์โรคในผู้ป่วยที่มี การแพร่กระจายจะเลวกว่าผู้ป่วยที่มีเนื้อร้ายเฉพาะที่

Lymphoma is a malignant disease characterized by proliferation of neoplastic lymphocytes in lymph nodes and lymphoid tissue of various organs such as the spleen, liver, gastrointestinal tract, etc. The disease usually first appears as enlarged peripheral lymph nodes. Ovarian involvement may be either as part of a generalized lymphoma or the initial manifestation of the disease.<sup>(1,2)</sup> The latter finding is extremely uncommon.<sup>(1)</sup> In this article we report on two patients in whom the ovarian mass was the initial clinical evidence of the disease.

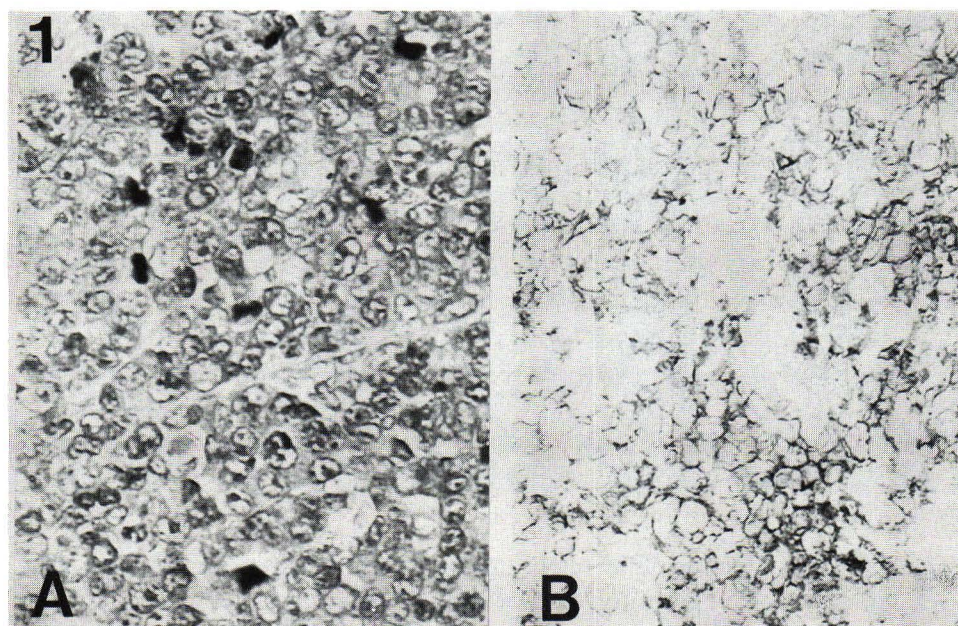
### Case Reports.

**Case 1.** An 8-year-old girl was hospitalized because of the progressive enlargement of an abdominal mass and jaundice for 1 week's duration. Examination revealed icteric sclera, bilaterally. A large movable suprapelvic mass was detected, as well as small lymph nodes in the left axilla, left cervical area, and both inguinal regions.

Routine laboratory data was unremarkable. The tests included hemoglobin, erythrocyte, and leukocyte counts as well as differential count. An abdominal sonogram disclosed a large adnexal mass. The chest roentgenogram was normal. Laparotomy revealed a 5×6 cm. hard, nodular mass of the left ovary which was removed along with several retroperitoneal nodes. The right adnexa was normal.

The surgical specimen in this case as well as in the other, was fixed in 10 per cent formalin, embedded in paraffin, and stained with hematoxylin and eosin (H&E) and Gomori's silver impregnation for reticulin fibers. Sections of the paraffin-embedded tissue were further processed by an indirect immunohistochemical method (avidin-biotin technique) using unlabelled antibodies to keratin, leukocyte common antigen (LCA) and immunophenotyping of lymphocytes including CD 45, CD 26, and UCHL-1.

Microscopically, the ovarian tissue was diffusely infiltrated with large neoplastic cells with scanty cytoplasm and indistinct borders (Figure 1A). The nuclei were slightly larger than that of histiocytes. The nuclear membrane was irregular and occasionally cleaved. Mitotic figures were prominent. The neoplastic cells were negative to the keratin and UCHL-1 but strongly reacted with LCA and L26 along the cytoplasmic membrane (Figure 1B). The final pathological diagnosis was malignant lymphoma, B-cell, diffuse large cell type involving the left ovary, retroperitoneal and inguinal nodes. The patient was at stage IV according to the criteria of the Federation International of Gynecologists and Obstetricians (FIGO) and at stage III following the Ann Arbor criteria.



**Figure 1.** A. Case 1 : Photomicrograph showing a highly cellular tumor with mitosis. (H&E × 200).  
B. Diffuse positivity for L-26 along the cytoplasmic membrane (Immunostain × 400).



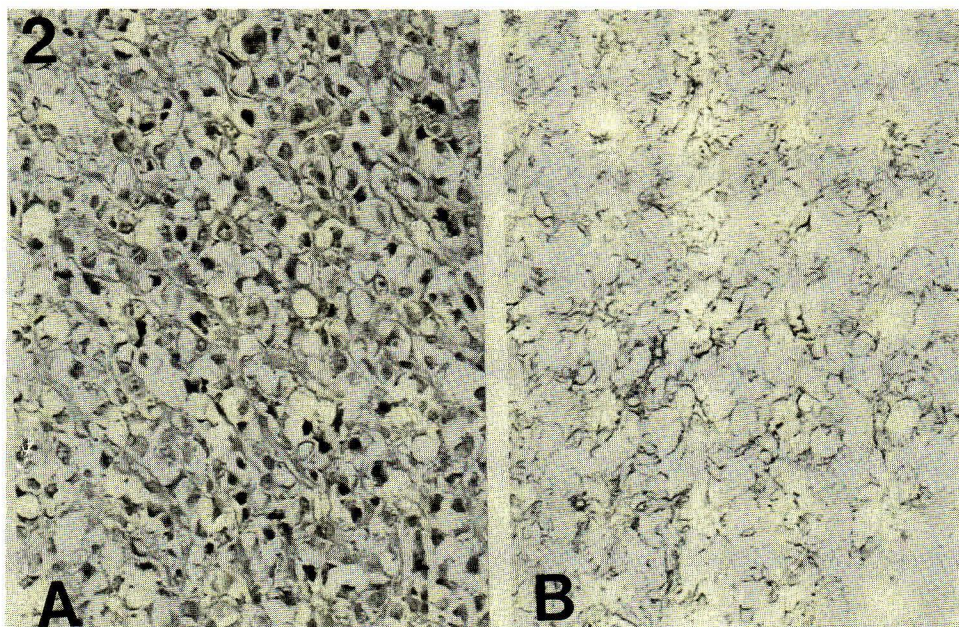
The postoperative course was uneventful. The patient had good responses to a combination of chemotherapy using prednisolone, vincristine, cyclophosphamide, and methotrexate. She was well, without clinical recurrence of lymphoma when seen one year after the diagnosis was made.

**Case 2.** Four months before hospitalization, this 71-year-old postmenopausal woman, gravida-9, para-9, noticed a tender, progressive growing pelvic mass. Three months later, small lumps appeared in the inguinal and axilla, bilaterally. Her weight had decreased during the past few months. Physical examination revealed a thin old woman who was moderately emaciated and appeared chronically ill. Several inguinal and axillary nodes were easily palpated. The lower abdomen was filled with an ill-defined, nodular, hard mass. The abdominal sonogram disclosed bilateral ovarian masses. A barium enema revealed pelvic mass that caused the lateral displacement of the rectum and rectosigmoid colon. The chest film was unremarkable.

At laparotomy, a 10 cm cystic mass of the left ovary containing serous fluid was noted, as well as a 5×4 cm solid nodular mass of the right ovary.

The latter lesion also invaded the round ligament and the anterior surface of the uterus. Several mesenteric and paraaortic nodes were found. The patient underwent subtotal hysterectomy with bilateral salphingo-oophorectomy and dissection of the adjacent nodes.

Microscopically, the left ovarian cyst was lined by flat and cuboidal epithelial cells. It was interpreted as serous cystadenoma. The right ovarian tissue, uterine surface, and lymph nodes were infiltrated with vacuolated neoplastic cells resembling signet-ring cells. The eccentric nuclei were small and hyperchromatic with prominent nucleoli (Figure 2A). The nuclear membrane was distinct. Additionally, there were large round cells that displayed large nuclei with clumps of chromatin. Mitoses were frequently observed. The neoplastic cells were negative to the keratin and UCHL-1. Either signet-ring cells or round neoplastic cells were stained positively with LCA and L-26 along the cytoplasmic membrane (Figure 2B). The final pathological diagnosis was malignant lymphoma, B-cell, diffuse large cell and signet-ring type. Her clinical stage was FIGO IV, and Ann Arbor IV B.



**Figure 2.** A. The histological feature of the tumor in case 2. It is a signet-ring cell type. (H&E × 200)  
B. The tumor cells have a positive marker for L-26 (Immunostain × 400).

The postoperative course was complicated by multiple bone pain and bronchopneumonia. A bone scan disclosed foci of bone lesions involving the right acetabulum, right proximal femur, right sphenoid, and the thoracic vertebrae (T 11). The condition rapidly deteriorated and the patient died 23 days after hospitalization. An autopsy was not permitted.

## Discussion

The diagnosis of malignant lymphoma in our cases was based on the characteristic gross and microscopic features, and the immunohistochemistry. It should be noted that the presence of retroperitoneal lymphadenopathy in the absence of peritoneal or omental involvement are findings suggestive of lymphoma.<sup>(4)</sup> Results of the light microscopic appearance and immunostains also help to distinguish from other ovarian neoplasms such as granulosa cell tumor, dysgerminoma, and metastatic small cell carcinoma.<sup>(3)</sup> The immunophenotyping of neoplastic cells provided even more convincing verification of the nature of the disease than the use of other chemical dyes.

Clinically, the age distribution of patients with ovarian lymphoma is wide, as was noted in our two cases. The disease, however, tends to occur in the third and fourth decades of life in most series.<sup>(1,3,5,7)</sup> The lesion is uncommon in children. Only about 8.5% to 10% of ovarian lymphomas affect patients under the age of 10 years.<sup>(3,5,7)</sup> The occurrence in a 71-year-old woman (case 2) is also unusual. Osborne et al, in their series of 40 cases, found only two patients in their seventh decade (aged 70 and 74 years).<sup>(3)</sup> Woodruff et al, noted only one 73-year-old woman among 35 patients with this disease.<sup>(7)</sup> Generally, the presenting symptoms for patients with ovarian lymphoma are pelvic mass and/or pain, as was found in our examples. It should be noted that involvement of the ovary at necropsy is about 25% in patients with generalized lymphoma but ovarian mass as the presenting symptom is extremely uncommon (0.3%).<sup>(1,2)</sup> It is also interesting to note that our case 1 showed evidence of hepatic dysfunction when the adnexal mass was discovered. The findings of liver and lymph node involvement indicate the multifocal or wide dissemination of the disease in our patients.

The question arises as to whether lymphomas of the ovary are indeed "primary" in the ovary or merely a localized manifestation of a generalized process. The word "primary" means

one origin only with "secondary" metastatic foci. Chorlton et al described a 32-year-old woman with localized lymphoma in one ovary.<sup>(1)</sup> The patient underwent hysterectomy with bilateral salpingo-oophorectomy and radiotherapy. She was alive without evidence of disease 17 years after therapy. The authors considered their patient as being "primary" ovarian lymphoma.<sup>(1)</sup> On the other hand, the findings which might suggest that the disease had not arisen in the ovary are bilateral ovarian involvement and/or enlarged regional lymph nodes, as noted in most examples at the time of laparotomy.<sup>(3)</sup> We consider that the terms "primary" and "secondary" are misleading in a discussion of lymphoma of the genital tract because there is doubt cast on the accuracy of clinical staging of the disease without histological proof. Therefore, it is reasonable to suggest that ovarian lymphoma can represent an initial manifestation of the disease process rather than a true "primary" ovarian lymphoma although the latter entity may exist. The most important view is that lymphomas can be presented in unusual ways when the genitals are affected.

Pathologically, the incidence of bilateral ovarian lesions ranges from 40% to 57% of cases in most series.<sup>(3,7)</sup> The size of the tumor is variable, the smallest lesion was 2 cm while the largest mass weighed 5,280 grams.<sup>(1,7)</sup> According to Woodruff, et al, the tumor in more than half of his 35 cases was as large as 15 cm in the greatest diameter.<sup>(7)</sup> Osborne, et al, recorded the median diameter of the bilateral ovarian masses as 8 cm; the unilateral lesion was 15 cm.<sup>(3)</sup> Most tumors are nodular with a solid gray white to pink cut surface and fish-flesh like in consistency. Foci of hemorrhages and necrosis as well as small cysts may be seen.<sup>(3)</sup> Concerning the histological typing, diffuse large cell lymphoma as noted in our cases is the most common cell type.<sup>(1,6)</sup> Osborne et al, however, suggested that small noncleaved cell lymphoma was the most frequent type.<sup>(3)</sup> The findings of signet-ring cells in our case 2 is extremely unusual. Furthermore, the occurrence of unilateral serous cysts in association with the opposite ovarian lymphoma (case 2) is at least uncommon and we are not aware of its previous description.

There is continuing debate over the choice of an ideal therapy, and this is partly related to the unpredictable course of the disease regardless of therapeutic modalities. Surgery is still useful because debulking will at least relieve the pressure symptom, in addition to establishing the tissue

diagnosis and to determine the extent of the tumor.<sup>(8)</sup> If the patients are young and only one ovary is involved, unilateral oophorectomy and adjunctive chemotherapy should be considered, as noted in our case.<sup>(1,3)</sup> Radical surgery should be avoided in high-risk patients with both ovaries and multiple node involvement because it may result in high rates of operative death.<sup>(8)</sup> Chemotherapy is essential, particularly for diffuse lymphoma because this regimen can induce complete remission.<sup>(8)</sup> Hence the selection of therapy should depend on several factors including age, clinical stage, and histological typing of the disease.<sup>(8)</sup> These factors also affect the outcome of the patients. A poorer prognosis may be expected in patients with generalized disease at the time of diagnosis than among patients with localized tumors. Survival is also influenced by histological cell types. For example the follicular lymphomas have a more favourable outcome than the diffuse form.<sup>(3)</sup> B-cell lineage is more responsive to treatment than the T-cell lymphomas which are more aggressive and less responsive to chemotherapy. It should be noted that patients who have no clinical evidence of systemic spread one to two years after therapy tend to have a high probability of long term survival.<sup>(3,8)</sup>

### Acknowledgment

Dr. Vira Kasantikul is currently in receipt of financial support from the Chulalongkorn Faculty of Medicine China Medical Board Scholar Development Fund.

### References

1. Chorlton I, Norris HJ, King FM. Malignant reticuloendothelial disease involving the ovary as a primary manifestation : A series of 19 lymphomas and 1 granulocytic sarcoma. *Cancer* 1974 Aug; 34 (2): 397-407
2. Freeman C, Berg JW, Cutler S. Occurrence and prognosis of extranodal lymphomas. *Cancer* 1972 Jan; 29(1): 252-60
3. Osborne BM, Robboy SJ. Lymphomas or leukemia presenting as ovarian tumors. An analysis of 42 cases. *Cancer* 1983 Nov; 52(10): 1933-43
4. Lathrop JC. Malignant pelvic lymphomas. *Obstet Gynecol* 1967 Jul; 30(1): 137-45
5. Nelson GA, Dockerty MB, Pratt JH, ReMine WH. Malignant lymphoma involving the ovaries. *Am J Obst Gynecol* 1958 Oct; 76 (4): 861-71
6. Paladugu RR, Bearman RM, Rappaport H. Malignant lymphoma with primary manifestation in the gonad. *Cancer* 1980 Feb; 45(3): 561-71
7. Woodruff JD, Noli Castillo RD, Novak ER. Lymphoma of the ovary. A study of 35 cases from the ovarian tumor registry of the American Gynecological Society. *Am J Obst Gynecol* 1963 Apr; 85(7): 912-8
8. Crisp WE, Surwith EA, Grogan TM, Freedman MF. Malignant pelvic lymphoma. *Am J Obstet Gynecol* 1982 May; 143(1): 69-74