

6-1-2022

Feline inductive odontogenic tumor in a young cat

Chakkarin Saththathum

Sunee Kunakornsawat

Chaiyan Kasorndorkbua

Follow this and additional works at: <https://digital.car.chula.ac.th/tjvm>



Part of the [Veterinary Medicine Commons](#)

Recommended Citation

Saththathum, Chakkarin; Kunakornsawat, Sunee; and Kasorndorkbua, Chaiyan (2022) "Feline inductive odontogenic tumor in a young cat," *The Thai Journal of Veterinary Medicine*: Vol. 52: Iss. 2, Article 23.

DOI: <https://doi.org/10.56808/2985-1130.3233>

Available at: <https://digital.car.chula.ac.th/tjvm/vol52/iss2/23>

This Report is brought to you for free and open access by the Chulalongkorn Journal Online (CUJO) at Chula Digital Collections. It has been accepted for inclusion in The Thai Journal of Veterinary Medicine by an authorized editor of Chula Digital Collections. For more information, please contact ChulaDC@car.chula.ac.th.

Feline inductive odontogenic tumor in a young cat

Chakkarin Satthathum^{1*} Sunee Kunakornsawat² Chaiyan Kasorndorkbua³

Abstract

A 6-month-old, 4.45 kg, intact, male domestic shorthair cat was presented with a gingival mass located on the left rostral maxilla and second left upper premolar tooth. Intraoral x-ray of the left rostral maxilla revealed left maxilla bone lysis with a unilocular cystic lesion. The cytology result revealed an epithelial cell tumor. A left rostral maxillectomy was performed and the tumor was submitted for histological assessment. Histopathological diagnosis of the tissue revealed a feline inductive odontogenic tumor. There was no evidence of tumor recurrence 24 months after surgery.

Keywords: inductive, odontogenic, cat

¹*Surgery Unit, Kasetsart University Veterinary Teaching Hospital, Faculty of Veterinary Medicine, Kasetsart University, Phahon Yothin Road, Chatuchak, Bangkok 10900, Thailand (foetcrs@ku.ac.th)**

²*Department of Companion Animal Clinical Sciences, Faculty of Veterinary Medicine, Kasetsart University, Phahon Yothin Road, Chatuchak, Bangkok 10900, Thailand*

³*Department of Pathology, Faculty of Veterinary Medicine, Kasetsart University, Phahon Yothin Road, Chatuchak, Bangkok 10900, Thailand*

**Correspondence:* foetcrs@ku.ac.th (C. Satthathum)

Received: December 1, 2021

Accepted: April 6, 2022

<https://doi.org/10.14456/tjvm.2022.48>

Introduction

The feline inductive odontogenic tumor is a benign gingival proliferation arising from the odontogenic tissue (Liptak and Withrow, 2013). It is an epithelium-derived odontogenic tumor that superficially resembles ameloblastic fibroma described in humans and cattle. This tumor is characterized by aggressive local behavior and frequently invades bone of the underlying mandible or maxilla. It usually manifests as a gross swelling with a distortion of bone; however, the presenting complaint may be notable tooth displacement or malocclusion (Thomas and Milinda, 2012). Radiographically, the feline inductive odontogenic tumor most often appears as an osteolytic, unilocular cystic lesion around tooth roots, with well-defined, sclerotic margins (Sakai H, 2008). Wide surgical excision is the treatment of choice (Walsh *et al.*, 1987). The feline inductive odontogenic tumor is a rare neoplasm in a cat (Gardner DG, 1995; Beatty J, 2000; Sakai H, 2008). The report revealed that tumors have occurred in cats in the range of 7 to 18 months, affected both sexes, both jaws and various breeds. This study aimed to report a young case (6-month-old) in a domestic shorthair cat with oral feline inductive odontogenic tumor and discuss this in terms of clinical signs, radiographic and histological findings, as well as the surgical treatment and postoperative care.

Case Description

A 6-month-old intact male domestic shorthair cat weighing 4.45 kg was referred to the Dentistry and Maxillofacial Surgery Unit of Kasetsart University Veterinary Teaching Hospital for evaluation of a gingival mass discovered by the owner 3 weeks before presentation. No obvious signs of oral discomfort were reported. Cytology performed prior to presentation showed no evidence of malignancy. An epithelial cell tumor was suggested at the time. The physical examination finding was a gross swelling of the left facial with painlessness on palpation (Fig.1). The bilateral mandibular lymph nodes were normal. The complete blood count and serum biochemistry profile disclosed no abnormalities. Serological screening tests for feline leukemia virus and feline immunodeficiency virus were negative. The oral examination found an approximately 3 cm in diameter, raised, firm, smooth gingival mass on the buccal aspect of the left rostral maxilla and the second left upper premolar extending into the left nasal cavity (Fig.2). The left maxillary canine tooth was missing. Gingiva were slightly inflamed and plaque accumulation was more evident on premolar and molar teeth when compared with the incisor and canine teeth. Intraoral dental radiograph of the left maxilla revealed left maxilla bone lysis, unilocular cystic lesion, with well-defined, sclerotic margin. The missing left maxillary canine tooth was found from the radiograph to have been displaced to the palatal site and suspended in the mass (Fig.4).

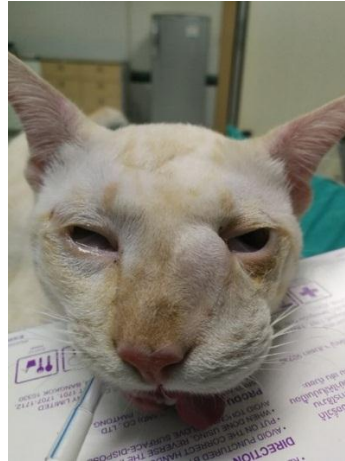


Figure 1 Photograph of a painless swollen mass of the left facial.

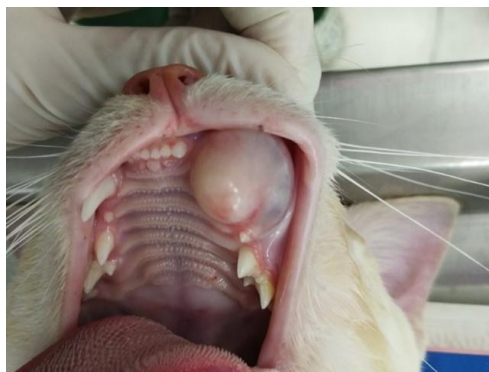

Figure 2 Photograph of a gingival mass on the buccal aspect of the left rostral maxilla and the second left upper premolar approximately 3 cm in diameter, with a raised, firm, smooth surface.

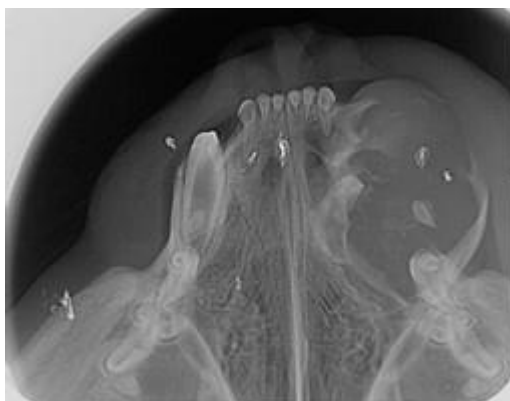


Figure 3 Photograph of intraoral dental radiograph of left maxilla .The left maxilla bone lysis, unilocular cystic lesion, with well-defined, sclerotic margin and the left maxillary canine tooth displaced to the palatal site and suspended in the mass.

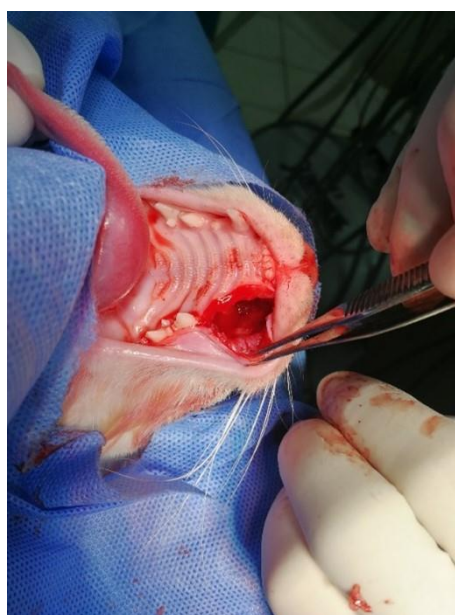


Figure 4 Photograph of left unilateral rostral maxillectomy .The maxilla was section rostral to the left upper third premolar and caudal to the left upper third incisor.

The cat underwent general anesthesia for the excision of the gingival mass. Anesthetic induction with 4 mg/kg of propofol was intravenously administered to the cat .General anesthesia was maintained with 2-3 %isoflurane. Prior to surgery, morphine sulfate (0.3 mg/kg) was intramuscularly administered and a left maxillary nerve block was performed for augmented pain control, using 0.5% bupivacaine. Amoxicillin-clavulanic acid (8.5 mg/kg, subcutaneous) was used for prophylaxis antibiotic and tolfenamic acid (4 mg/kg, subcutaneous) was administered postoperatively .The oral cavity was rinsed with chlorhexidine gluconate 0.12% solution followed by supragingival and subgingival scaling and polishing was performed before the mass removal. Then, a left unilateral rostral maxillectomy was performed, including 5 mm of normal tissue away from the visible tumor margins. A full-thickness incision was performed with a #15 blade on a round scalpel handle No 3. Alveolar and buccal mucosa was elevated with a molt periosteal elevator to expose the underlying bone. Osteotomy of the left rostral maxilla was performed with a long #701 taper fissure bur on a

sterile water-cooled highspeed dental handpiece .The maxilla was section rostral to the left upper third premolar and caudal to the left upper third incisor (Fig.5). A 3 cm mass was removed and submitted for histopathological examination .A buccal mucosal flap was repositioned in place and sutured with 5-0 monofilament absorbable suture material (Monosyn Quick; B. Braun surgical S.A) using a simple interrupted suture pattern (Fig.6). The cat recovered from the anesthesia normally and was hospitalized with intravenous fluid for the first 24 h after the surgery .A portion of soft food and water was offered 24 h after surgery and the cat ate and drank normally . The cat was given an oral amoxicillin-clavulanic acid (12.5 mg/kg, q12 h) for 7 days, tolfenamic acid (4 mg/kg q 24 h) for 3 days. The owner was instructed to feed it a softened diet and to clean the oral cavity with antiseptic (0.12% chlorhexidine solution) twice daily for 14 days .The assessment of mucoperiosteal flap healing was performed at 2 weeks postoperatively.

The specimen was immersed in 10 %neutral buffered formalin and dehydrated in graded ethanol series .After paraffin embedding, serial sections of 4µm thickness were cut and stained in hematoxylin and

eosin .Histopathological examination showed a gingival mass covered by gingival mucosa and poorly defined, non-encapsulated submucosa mass (Fig.6). The mass was composed of islands of basaloid epithelial cells among dense sheets of stellate cells and loose fibrous tissue. The mitotic index of both cell types

was low (Fig.7). The histopathological diagnosis was feline inductive odontogenic tumor. Histopathology confirmed complete removal of the mass .No recurrence of the tumor was noted by the owner 24 months after surgery.

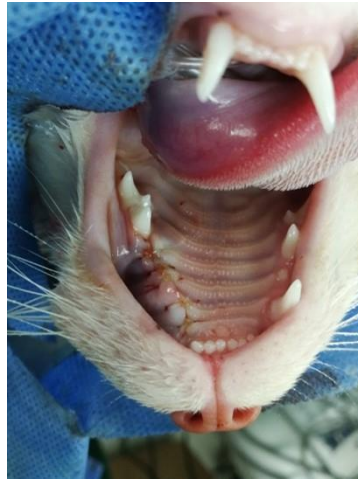

Figure 5 A buccal mucosal flap at surgical defect using 5-0 monofilament absorbable suture material with a simple interrupted suture pattern.

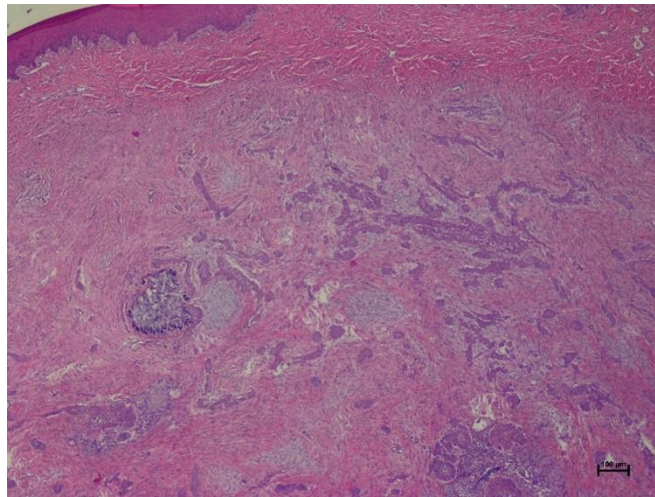


Figure 6 Photomicrograph)4x magnification (of a gingival mass stained with hematoxylin and eosin stain) H&E (revealed a non-encapsulated, poorly demarcated, submucosal mass covered by gingival mucosal epithelium.

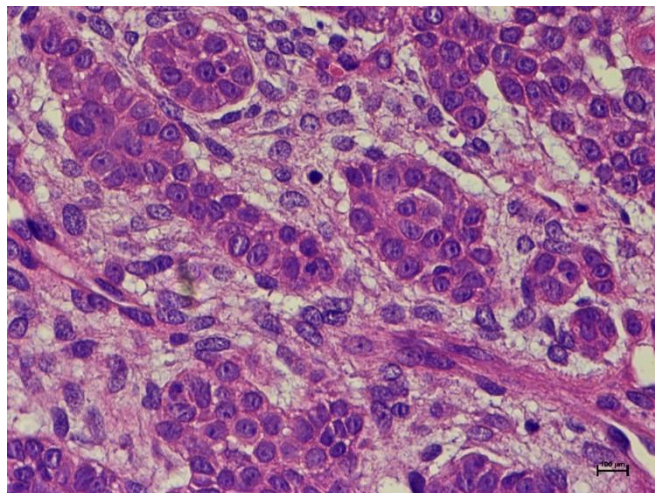


Figure 7 Photomicrograph of the gingival neoplasm, H & E, 60x showing islands of basaloid epithelial cells among dense sheets of stellate cells and loose fibrous tissue.

Discussion

Oral neoplasia has been reported to account for 3% of all feline cancers (M Cray *et al.*, 2020). In a recent study, the majority of feline oral tumors were classified as malignant (58.1%) and only a few benign (2.5%). Squamous cell carcinoma is the most common oral malignancy in cats and odontogenic tumors are the majority of feline oral benign tumors (Regezi JA *et al.*, 2012). Odontogenic tumors originate from the remnants of odontogenic epithelium, odontogenic mesenchyme or a combination of the cellular elements that comprise the tooth forming apparatus (Regezi *et al.*, 2008; Verstraete, 2003; Gardner DG, 1992). There are ameloblastoma, ameloblastic fibroma, peripheral odontogenic fibroma, feline inductive odontogenic tumor and amyloid-producing odontogenic tumors found in cats (Boehm and Breuer, 2011; Poulet *et al.*, 1992; Gardner DG, 1998). The feline inductive odontogenic tumor is an epithelial tumor that originates from remnants of the dental organs, dental lamina, cells of epithelial origin lining odontogenic cysts or possibly from basal epithelial cells of the oral mucosa and occurs in the tooth-bearing areas of the mandible and maxilla bone (Thomas and Milinda, 2012). The terms adamationma and inductive fibroameloblastoma have been used diversely to describe this tumor. Presently, feline inductive odontogenic tumor is suggested as being a more appropriate designation than previous terms.

This study is described a case of feline inductive odontogenic tumor in a young cat. Clinical features typically are a locally invasive, slowly growing neoplasm that does not metastasize. It usually presents as a gross swelling with distortion of the bone; however, the presenting complaint may be remarkable tooth displacement or malocclusion. Intraoral radiographs allowed initial access to the mass in this case, however, a computed tomography scan may provide better anatomical detail and structural resolution in the maxillary area. The radiographic finding of neoplasm appears as an osteolytic, unilocular cystic lesion with well-defined, sclerotic margins. Even though the feline inductive odontogenic tumor is a benign tumor, complete excision is considered the treatment of choice, including the affected teeth and peripheral osteotomy to prevent tumor recurrence (Murray *et al.*, 2010; Verstraete, 2005). Surgical resection is recommended to a gross surgical margin of 10 mm (Brain *et al.*, 2020) however the surgical margin of 5 mm, in our case, was enough for a complete margin without cosmetic defects. Adjuvant therapy for odontogenic tumors in the cat is radiation therapy. The previous report used radiation therapy for treatment in cases of feline inductive odontogenic tumors where the tumor was incompletely excised (Moore *et al.*, 2000). The cat received orthovoltage radiation with a half-value layer of 2.9 mm Cu using a single portal, in 12 fractions of 4.0 Gy to the skin surface, given three times a week. Histopathological examination of tumors is necessary to differentiate feline inductive odontogenic tumor from other focal oral masses with similar gross lesions. The feline inductive odontogenic tumor is a mixed tumor consisting of different odontogenic tissue elements –

neoplastic odontogenic epithelium, induced ectomesenchyme of the dental papilla and supportive fibrous stroma reminiscent of the dental follicle (Moore *et al.*, 2000). The histological characteristic of the tumor, in this case, was composed of islands of basaloid epithelial cells among dense sheets of stellate cells and fibrous tissue. The feline inductive odontogenic tumor has been confused in the part with two other feline odontogenic tumors: ameloblastoma and the amyloid-producing odontogenic tumor. The histopathological features and clinical features of feline inductive odontogenic tumor differ from the other two tumors. Ameloblastoma occurring in cats over the age of 6 years, affects both sexes, both jaws and various breeds. Two microscopic variants have so far been reported, namely, the follicular pattern and the keratinizing pattern, which is similar to the keratinizing ameloblastoma in dogs (Gardner DG, 1998). Ameloblastic fibroma, the amyloid-producing odontogenic tumor is a cellular epithelial tumor. The epithelium in some areas shows palisading of the basal cells, reverse polarization of nuclei, stellate reticulum and collagenous matrix are variable focal findings. This tumor exhibits amyloid which tends to calcify present in some parts of the tumor (Gardner DG, 1996).

In conclusion, feline inductive odontogenic tumor should be considered in a juvenile cat. Histopathological findings are necessary for final diagnosis and surgical treatment is required. The wide marginal excision combined with partial ostectomy is considered a curative method. Rapid identification and treatment are necessary to achieve remarkable success.

Acknowledgments

Special thanks to our colleagues and staff from the Dentistry and Maxillofacial Surgery Unit of Kasetsart University Veterinary Teaching Hospital for participation in the study and their technical support.

References

- Beatty J, Charles J, Malik R, France M, Hunt GB 2000. Feline inductive odontogenic tumour in a Burmese cat. Australian veterinary journal. 78:452-455.
- Brain G .Murphy, Cynthia M .Well and Jason W . Soukup 2020 .Veterinary Oral and Maxillofacial Pathology. 1st ed. Hoboken, NJ: Wiley-Blackwell. 243pp.
- B Boehm , W Breuer and W Hermanns 2011. Odontogenic tumours in the dog and cat. Tierarztl Prax Ausg K Kleintiere Heimtiere .39: 305–312.
- Gardner DG 1992 .An orderly approach to the study of odontogenic tumours in animals. J Comp Pathol. 107: 427–381.
- Gardner DR and Dubielzig RR 1995. Feline inductive odontogenic tumor(inductive fibroameloblastoma) – a tumor unique to cats. J Oral Pathol Med. 24: 185-190.
- Gardner DG 1996. Epulides in the dog: a review. J Oral Pathol Med. 25: 32–37.
- Gardner DG 1998 .Ameloblastomas in cats :a critical evaluation of the literature and the addition of one example. J Oral Pathol Med. 27: 39–42.

- Liptak JM and Withrow SJ 2013 .Cancer of the gastrointestinal tract .In :Withrow and MacEwen's Small Animal Clinical Oncology. 5th ed. SJ Withrow and DM Vail (ed). St .Louis: Elsevier Science. 381–398.
- M Cray, LE Selmic and A Ruple 2020. Demographics of dogs and cats with oral tumors presenting to teaching hospitals: 1996-2017. *Journal of Veterinary Science* .21: e70.
- Moore AS, Wood CA, Engler SJ and Bengtson A 2000 . Radiation therapy for long-term control of odontogenic tumours and epulis in three cats . *J Feline Med Surg*. 2: 57–60.
- Murray RL, Aitken ML and Gottfried SD 2010 .The use of rim excision as a treatment for canine acanthomatous ameloblastoma . *J Am Anim Hosp Assoc* .46: 91–96.
- Poulet FM, Valentine BA and Summers BA 1992 .A survey of epithelial odontogenic tumors and cysts in dogs and cats . *Vet Pathol* .29: 369–380.
- Regezi JA, Sciubba JJ and Jordan RK 2008 .Odontogenic Tumors .In :Oral pathology clinical pathologic correlations .5th ed. Frank J M Verstrate and Milinda J Lommer (ed) St .Louis, MO :Saunders Elsevier. 261–282.
- Regezi JA, Sciubba J and Jordan J 2012 .Clinical pathologic correlations :In :Oral and maxillofacial surgery in dogs and cats, 1st ed. Frank J M Verstrate and Milinda J Lommer (ed). St .Louis, MO : Saunders Elsevier .381-385.
- Sakai H, Mori T, Tokuma Y, Maruo K, Masegi T 2008. Immunohistochemical feature of proliferative marker and basement membrane components of two feline odontogenic tumors. *Journal of feline medicine and surgery*. 10: 296-299.
- Thomas P. Chamberlain & Milinda J. Lommer 2012. Clinical behavior of odontogenic tumors. In: *Oral and maxillofacial surgery in dogs and cats, 1st edn.*, Frank J M Verstrate and Milinda J Lommer, eds., Elsevier Ltd. p. 403-410.
- Verstraete FJM .Oral pathology 2003 .In :Textbook of small animal surgery .3rd ed. Slatter DH(ed). Philadelphia, PA :WB Saunders .2638–2651.
- Verstraete JM 2005 .Mandibulectomy and maxillectomy . *Vet Clin Small Anim*. 35: 1009–1039.
- Walsh KM, Denholm LJ and Cooper BJ 1987 .Epithelial odontogenic tumours in domestic animals . *J Comp Pathol* .97:503–521.