

6-1-2022

## Oxygenated dressing quickens skin wound healing of Bama miniature pigs

Yingqiu Wang

Limin Qiao

Hong An

Zhenhao Zhang

Yan Zheng

*See next page for additional authors*

Follow this and additional works at: <https://digital.car.chula.ac.th/tjvm>



Part of the [Veterinary Medicine Commons](#)

---

### Recommended Citation

Wang, Yingqiu; Qiao, Limin; An, Hong; Zhang, Zhenhao; Zheng, Yan; Chen, Chang; Zhang, Jingrui; and Wang, Xiangguo (2022) "Oxygenated dressing quickens skin wound healing of Bama miniature pigs," *The Thai Journal of Veterinary Medicine*: Vol. 52: Iss. 2, Article 18.

DOI: <https://doi.org/10.56808/2985-1130.3228>

Available at: <https://digital.car.chula.ac.th/tjvm/vol52/iss2/18>

This Short Communication is brought to you for free and open access by the Chulalongkorn Journal Online (CUJO) at Chula Digital Collections. It has been accepted for inclusion in The Thai Journal of Veterinary Medicine by an authorized editor of Chula Digital Collections. For more information, please contact [ChulaDC@car.chula.ac.th](mailto:ChulaDC@car.chula.ac.th).

---

## Oxygenated dressing quickens skin wound healing of Bama miniature pigs

### Authors

Yingqiu Wang, Limin Qiao, Hong An, Zhenhao Zhang, Yan Zheng, Chang Chen, Jingrui Zhang, and Xiangguo Wang

# Oxygenated dressing quickens skin wound healing of Bama miniature pigs

Yingqiu Wang<sup>1#</sup> Limin Qiao<sup>2#</sup> Hong An<sup>1</sup> Zhenhao Zhang<sup>1</sup> Yan Zheng<sup>3</sup>

Chang Chen<sup>1</sup> Jingrui Zhang<sup>1</sup> Xiangguo Wang<sup>1\*</sup>

## *Abstract*

Oxygen is a vital factor in the process of wound healing and is involved in collagen synthesis, synthesis and the release of growth factors, angiogenesis and epidermal cell contraction. Hence, local oxygen control of wounds plays an important role in skin wound healing. Herein, we developed a novel oxygenated dressing for the treatment of skin wound healing in Bama miniature pigs. The oxygenated dressing was mainly composed of potassium iodide, glucose, glucose oxidase, polyvinyl alcohol, polypropylene, polyvinylpyrrolidone and water. The oxygenated dressing significantly quickens the healing of full-thickness skin wounds in Bama miniature pigs and promotes the proliferation of epidermal cells, basal and spinous cells, dermal vascular endothelial cells and fibroblasts, and then promote the benign healing of wounds.

---

**Keywords:** Bama miniature pigs, skin, full-thickness wound, oxygenated excipients, wound healing

---

<sup>1</sup>College of animal science and technology, Beijing University of Agriculture, Beijing 102206

<sup>2</sup>Department of Animal Husbandry and Veterinary, Beijing Vocational College of Agriculture, Beijing 102442

<sup>3</sup>Beijing Langxin Ruiming Biotechnology Co., Ltd, Beijing 102299

#These authors contributed equally to this work

\*Correspondence: xiangguo731@163.com (X. Wang)

Received February 11, 2022

Accepted April 5, 2022

<https://doi.org/10.14456/tjvm.2022.43>

## Introduction

As the first line of human body defense, the skin plays a role in protecting human tissues and organs from external mechanical and chemical stimuli, bacteria and viruses. The skin is mainly composed of three layers, which are the epidermis, dermis and subcutaneous tissue from outside to inside. In addition, blood vessels, lymphatic vessels, nerves, muscles and some accessory organs (such as sweat glands, hair and sebaceous glands) are also distributed in the skin (Kamoun *et al.*, 2017). After skin injury, wound healing is a physiological process involved in the *in vivo* repair of tissue injury, restoration of its anatomical integrity and the functioning of the injured site (Sarheed *et al.*, 2016). The wound healing process can be divided into four stages in chronological order, namely hemostasis, inflammation, hyperplasia and maturation (Martin *et al.*, 2013). Generally, wound exposure will cause bacterial infection, easy loss of water and protein, endocrine dysfunction and destruction of the immune system. In severe cases, it will also cause a series of clinical complications. In this case, covering the wound with wound accessories and maintaining the wound in a healing microenvironment is very important for wound healing and later clinical treatment.

In addition to maintaining the best humidity of the wound environment, ideal wound accessories also have the functions of avoiding secondary infection of the wound, absorbing wound exudate, reducing wound surface necrosis, preventing wound dryness, stimulating growth factors, appropriate elasticity, non-antigenicity and good biocompatibility. At present, with the support of "wet healing theory", the treatment of wounds has undergone revolutionary changes. For the present, more and more new biomaterials are being used in wound healing research (Guan *et al.*, 2022; Lei *et al.*, 2021a; Yang *et al.*, 2021b; Yang *et al.*, 2021a). In clinical treatment, foam accessories, high pressure excipients, negative pressure accessories, nano silver particles used for anti-infection accessories, hydrogel excipients, sodium alginate accessories, polyurethane accessories and other excipient excipients (new wound accessories) have gradually replaced passive accessories (such as dry gauze and oil gauze, etc.) (Dhivya *et al.*, 2015; Huang *et al.*, 2018; Liu *et al.*, 2019; Qu *et al.*, 2018; Vowden and Vowden, 2014). These dressings allow oxygen to permeate, absorb excess tissue exudates as well as maintain the moist wound environment. Based on the reasoning that growth factors are essential for regulating cellular responses in the wound healing process, some investigators have proposed novel multifunctional biohybrid microspheres that enable the first one-step protein isolation and its application in chronic wound healing (Lei *et al.*, 2022; Lei *et al.*, 2021b).

Oxygen is a vital factor in the process of wound healing and is involved in collagen synthesis, synthesis and the release of growth factors, angiogenesis and epidermal cell contraction. Oxygen also plays an irreplaceable role at each stage of wound healing. It has been demonstrated that adequate oxygen is a prerequisite for successful wound healing, which can promote cell proliferation and tissue remodeling

(Zhang *et al.*, 2020). The oxygen supply of wounds goes through the stages from hyperbaric oxygen storage to local oxygen supply. In recent years, with the development of bioengineering technology, new biological materials have been used to supply oxygen to the wounds and new types of oxygen-containing dressings have emerged. In addition to providing necessary oxygen to the wound, oxygen dressings also have the function of inhibiting bacteria, keeping the wound surface moist and insulating the wound to promote wound healing.

In this study, a new oxygenated dressing was constructed, which is mainly composed of potassium iodide, glucose, glucose oxidase, polyvinyl alcohol, polypropylene, polyvinylpyrrolidone and water (Fig. 1). The Bama miniature pig was selected to prepare the full-thickness skin defect wound model and its healing effect on the full-thickness skin wound was studied with oxygenated dressing. The effectiveness of oxygenated dressing in promoting wound healing was determined through the analysis of the wound area, wound cavity volume, healing time and the pathological, biochemical and molecular biology of wound tissue, so as to lay a foundation for its application in human skin surgery.

## Materials and Methods

**Materials:** Oxygenated dressing (Produced by Beijing Langxin Ruiming Biotechnology Co., Ltd.). The Bama miniature pigs weighed 20 kg and were 9 months old (Purchased from Beijing Tonghe Litai Biological Technology Co., Ltd.). Feed was the standardized small-sized pig feed produced by Beijing Keyao Xieli Co., Ltd. Each head was given 3% of its body weight twice a day with free drinking water. All of the pigs were treated strictly according to the guidelines of the Animal Ethics Committee of Beijing University of Agriculture (Permit no.: SYXK(JING)2015-0004).

**Preparation of oxygenated dressing:** The dressings were divided into two parts. The first part consisted of an anti-leakage protective film, a polymer gel containing water, a protective film and a protective layer. The second part consisted of a protective layer, a calcium peroxide membrane, an air permeable membrane and a perfluorinated naphthalene gel preparation from top to bottom. The structure of the calcium peroxide film had a microcapsule controlled release process and the air leakage protection film was made of air permeable and impervious material. The film was partly coated with medical adhesive glue. The protective film fixed the polymer gel containing water in the required range so that it would not exudate before use and would avoid damaging the viscosity of the adhesive glue on the protective film. At the same time, the protective layer was set to bond with the anti-leakage protective film, which can be removed only when in use, so as to ensure that there is no liquid leakage when not in use (Fig. 1A and B).

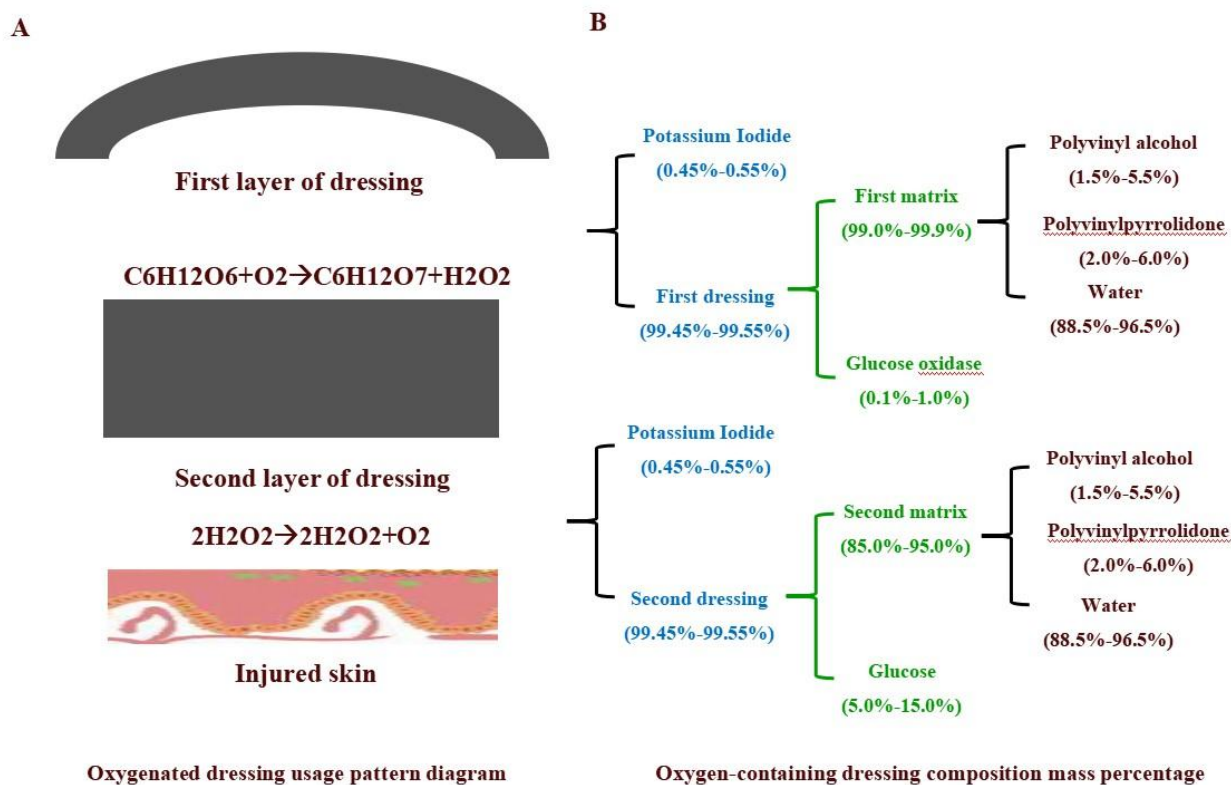
**Animal model preparation and grouping:** Five Bama miniature pigs were fasted for 12 h and had no water for 4 h before the operation, and were then weighed and intramuscularly injected with 0.05 mg/kg atropine

and 0.1 mL/kg silazine hydrochloride. After the limb movement of the miniature pigs was stable, they were fixed on the operating table in a prone position. A breathing mask with an anesthesia ventilator was connected and 5% isoflurane inhaled for anesthesia induction. When the limbs of the miniature pigs had relaxed and activity had disappeared, endotracheal intubation was performed in time and perform 0.5% isoflurane was used for anesthesia maintenance. (1) Wound planning: The backs of miniature pigs was shaved in an area of 40 cm × 25 cm. After disinfection, four square wounds with a side length of 5 cm were planned from front to back, with the back spine as the median line, and 2 cm left open on both sides, with a total of 8 wounds. (2) Peeling operation: Skin was taken from the planned area with a special wounding device (18 mm diameter punch), drilled down to the muscle fascia perpendicular to the skin, the wounding device pulled out, the drilled skin cut off and 8 square full-thickness skin defect wounds formed deep in the muscle fascia. (3) Wound dressing: The wounds prepared on the left and right sides of the median line were the control group and the experimental group. The wounds of the control group were bandaged with ordinary gauze and the wounds of the experimental group were bandaged with oxygen paste. The wound recovery was observed at 0, 7, 14 and 21 days after the operation (Fig. 2A).

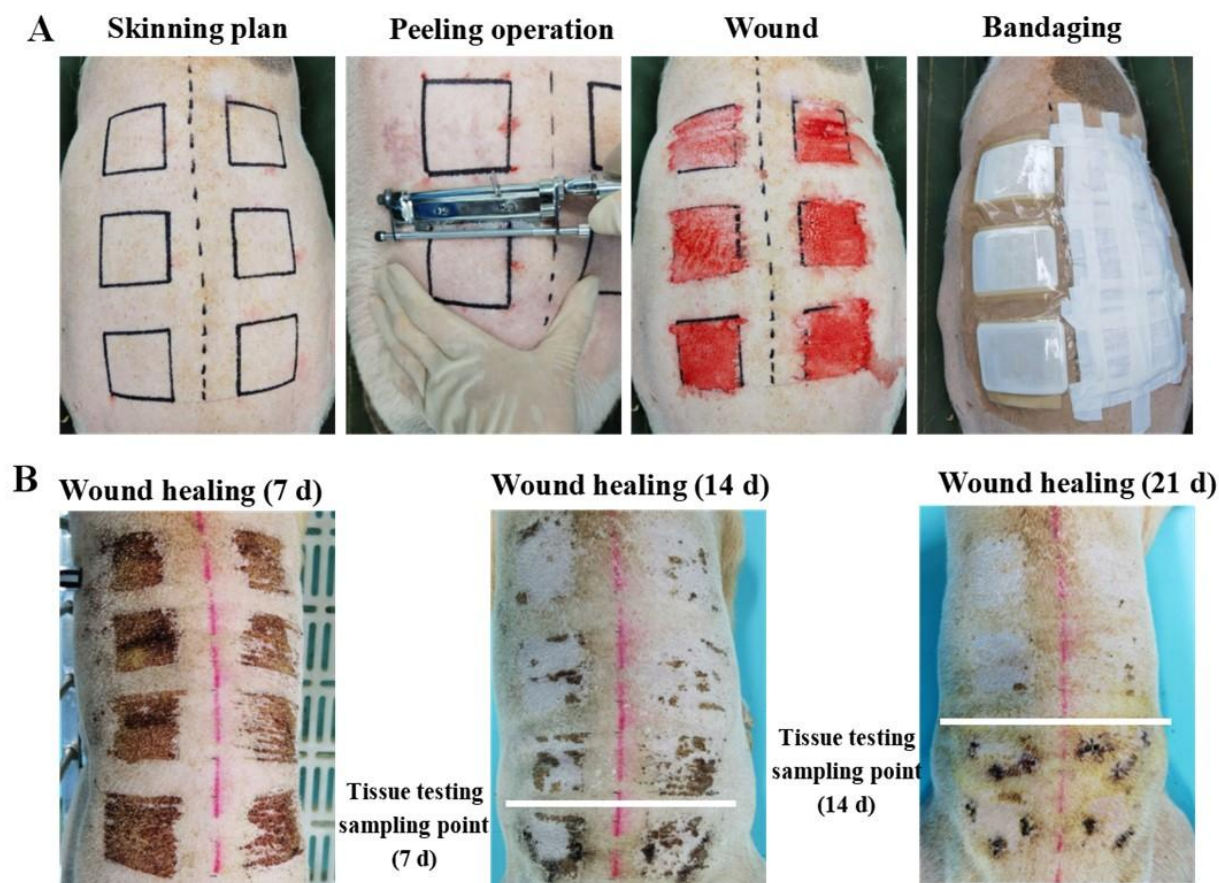
**HE staining:** At 0, 7, 14 and 21 days after the operation, five columnar tissue blocks with a diameter of 1 mm were evenly taken from each wound with a sampler with a diameter of 1 mm. Then the tissue blocks were fixed with 10% formaldehyde solution, embedded and

sliced in conventional paraffin, stained with hematoxylin eosin (HE), the tissue sections observed under microscope and photographed.

**CD31 immunohistochemical staining:** Ordinary bandages and oxygen-containing auxiliary materials treated the full-thickness skin of the pigs for 7, 14, and 21 days, embedded in paraffin and sectioned and the paraffin sections deparaffinized in water. Then, incubated with 3% H<sub>2</sub>O<sub>2</sub> at room temperature for 5~10 minutes to eliminate endogenous peroxidase activity, rinsed with distilled water and soaked in PBS for 5 minutes (if antigen retrieval were needed, it could be carried out after this step). 5~10% of normal fetal bovine serum (diluted in PBS) was blocked and incubated at room temperature for 10 minutes. The serum was poured out, left unwashed, the primary antibody or primary antibody working solution diluted in an appropriate proportion and incubated at 37 °C for 1 ~ 2 h or 4 °C. PBS flushing, 5 minutes × 3 times. Biotin labeled secondary antibody (diluted with 1% bsa-pbs) was added dropwise and incubated at 37 °C for 10 ~ 30 minutes or the second generation biotin labeled secondary antibody working solution dropped and incubated at 37 °C or room temperature for 10 ~ 30 minutes, with PBS flushing for 5 minutes × 3 times. Streptavidin labeled with horseradish enzyme (diluted with PBS) was added dropwise and incubated at 37 °C for 10 ~ 30 minutes or the second generation horseradish enzyme labeled Streptomyces ovalbumin working solution was incubated at 37 °C for 10 ~ 30 minutes with PBS flushing for 5 minutes × 3 times and developer development (DAB or AEC), full washing with tap water, redyeing, sealing and photography.



**Figure 1** Composition of oxygenated dressing. (A) A schematic diagram of the use of oxygen-containing auxiliary materials. (B) The mass percentage of oxygen-containing auxiliary materials



**Figure 2** Establishment and nursing of the full-layer damage model. (A) The full-thickness skin defect wounds of miniature pigs with their own control. (B) The general observation of the full-thickness skin defect wounds of each group of miniature pigs at different time points after surgery. Note: The left side is an ordinary gauze dressing, the right side is an oxygen-containing accessories dressing.

**Masson staining analysis:** Paraffin sections were deparaffinized in water, chromated or precipitated with mercury removal (this step could be omitted for tissues fixed with formaldehyde), washed with tap water and distilled water in turn, the nucleus stained with Regaud hematoxylin dye or Weigert hematoxylin for 5-10 minutes and washed thoroughly. If overstained, it could be differentiated with hydrochloric acid and alcohol. Then washed with distilled water and then Masson Ponceau acid reddening solution used for 5-10 minutes. Soaked with 2% glacial acetic acid aqueous solution for a moment, differentiated with 1% phosphomolybdic acid aqueous solution for 3-5 minutes and dyed directly with aniline blue or light green solution for 5 minutes without water washing. Then soaked in 0.2% glacial acetic acid aqueous solution for a while and sealed with 95% alcohol, anhydrous alcohol, transparent xylene and neutral gum, and the pictures taken.

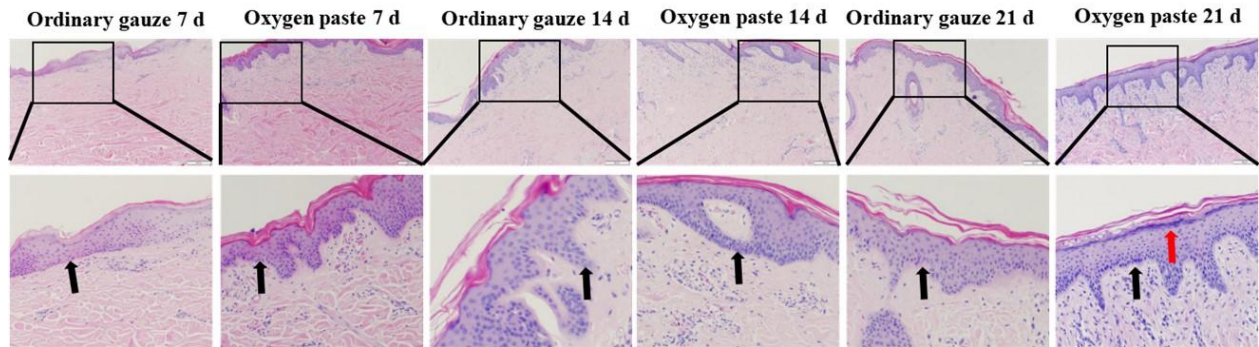
**Data analysis:** All pictures are representative pictures selected after 3 independent repeated trials. All data was expressed as mean  $\pm$  standard deviation (SD). The data was analyzed by unpaired t-test with Excel and GraphPad Prism 6 software. Differences were considered significant when  $*P < 0.05$  and  $**P < 0.01$ .

## Results and discussion

**General observation:** At 7 days after the operation, all wounds treated with ordinary gauze and oxygenated dressing had scabbed. The wounds in the ordinary gauze bandage group (the control group) formed dry scabs with a dark color, which were hard and dry to touch. The scabs in the oxygenated dressing group (experimental group) were light, soft and wet to touch (Fig. 2B). At 14 days after the operation, part of the scab had fallen off. The scar tissue in the control group grew unevenly after the scab fell off and part of the scar tissue in the experimental group was relatively flat after the scab fell off (Fig. 2B). At 21 days after the operation, the scabs of the treated wounds in the two groups had basically fallen off. The wound scar in the control group was dry, hard and uneven, while the wound scar in the experimental group was soft, elastic and flat (Fig. 2B). The oxygenated dressing also has the effect of keeping the wound surface moist but it will not cause the wound surface to be overly moist and cause the endurance of the healing tissue to decrease, thereby improving the healing speed of the wound. Many studies have also confirmed that "wet healing" is conducive to wound healing. The wet environment promotes tissue fibrinolysis and capillary formation, regulates wound oxygen tension, promotes the release of a variety of growth factors and up regulates their activities, so as to accelerate the healing speed (Vowden and Vowden, 2014).

**Oxygenated dressing promotes granulation tissue formation:** The results of HE staining showed that a large number of deep-colored inflammatory cells infiltrated and aggregated in the dermal cell layer of both the control group and the experimental group at 7 days after the operation. The basal layer was still incomplete and the epidermal layer was poorly formed in the control group. In the experimental group, a complete monolayer of basal was formed in the basal layer of the epidermis, with proliferative capillaries and fibroblasts. The number of nuclei in the epidermal spinous layer in the experimental group was significantly higher than that in the control group

(black arrow). At 14 days after the operation, granulation tissue had formed and grew into the wound. The number of epidermal cell layers in the experimental group was significantly more than that in the control group, the epidermal structure was relatively complete and the structure of each layer was regular and orderly. 21 days after the operation, the cells in each layer of the epidermis both in the control group and in the experimental group had been repaired but the repair of the dermal papilla in the experimental group was significantly better than that in the control group (Fig. 3, black arrow).



**Figure 3** Observation of hematoxylin eosin staining results of full-thickness skin defect wounds of miniature pigs in each group at different time points after operation (Scale bar, 200  $\mu$ m). The black indicates the dermal papilla.

The newly formed blood vessels mix with fibroblasts, macrophages and matrix proteins to form "granulation tissue", a soft pink substance that appears at the bottom of the healing wound. Moreover, at the end of the proliferation phase, fibroblasts will differentiate into actin rich and contractile myofibroblasts, pulling the wound edges together (Sun *et al.*, 2014). Histological results confirmed that at 7 days after the operation, a large number of vascular endothelial cells had proliferated in the wound of the experimental group, which were used for the synthesis of new capillaries to create a good tissue growth environment for wound healing. After 14 days, the number of capillaries in the wound of the experimental group was more than that of the control group. Good local blood circulation can ensure the nutrients and oxygen required for wound repair, facilitate the absorption and transportation of necrotic substances and control local infection. Studies have found that the content of wound collagen, wound strength and tissue oxygen tension and tissue perfusion are positively correlated. If the wound tissue is in a state of continuous hypoxia, the inflammation symptoms of the wound will be maintained or even severe, thereby organizing the process of wound healing. In addition, dressing the wound with oxygenated dressing can also maintain the oxygen partial pressure of wound tissue, maintain leukocyte activity, inhibit bacteria and promote collagen synthesis and cell regeneration. However, 21 days after the operation, the number of fibroblasts in the wound of the control group was much greater than that of the experimental group. Although the excessive proliferation of fibroblasts is conducive to the synthesis of collagen, it also promotes the overgrowth of granulation tissue and leads to the formation of scars in the wound. The oxygenated

dressing can ensure the moderate proliferation of granulation tissue and reduce the formation of scar tissue.

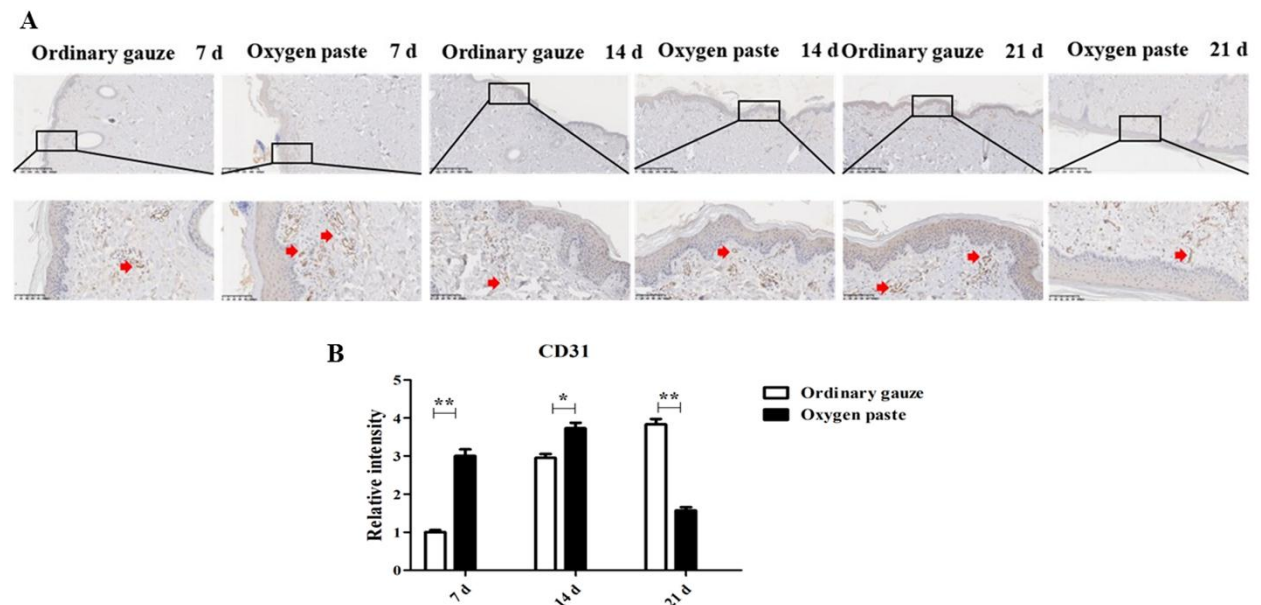
**Oxygenated dressing accelerates blood vessel formation and collagen fiber proliferation:** CD31 refers to the formation of vascular endothelial cells. The results of immunohistochemistry show that the expression intensity of CD31 protein in the experimental group was significantly stronger than the expression intensity of CD31 protein in the control group at 7 and 14 days after the operation. At 21 days after the operation, the expression intensity of CD31 protein in the control group was significantly stronger than the expression intensity of CD31 protein in the experimental group. It shows that oxygenated excipients promoted the formation of vascular endothelial cells in the early stage of treatment and accelerated the formation of local blood vessels and wound healing (Fig. 4, red arrow).

In Masson staining, collagen fibers, mucus and cartilage were blue, cytoplasm, muscle, cellulose and glia were red and nucleus was black and blue. In our results, at 7 and 14 days after the operation, the proliferation of blue collagen fibers in the experimental group was significantly stronger than that in the control group and they were tightly arranged and interwoven into a network on the 14th day, which promoted the repair of the dermis. After 21 days of treatment, collagen fibers proliferated in the control group, while subcutaneous fat had been formed in the experimental group (Fig. 5).

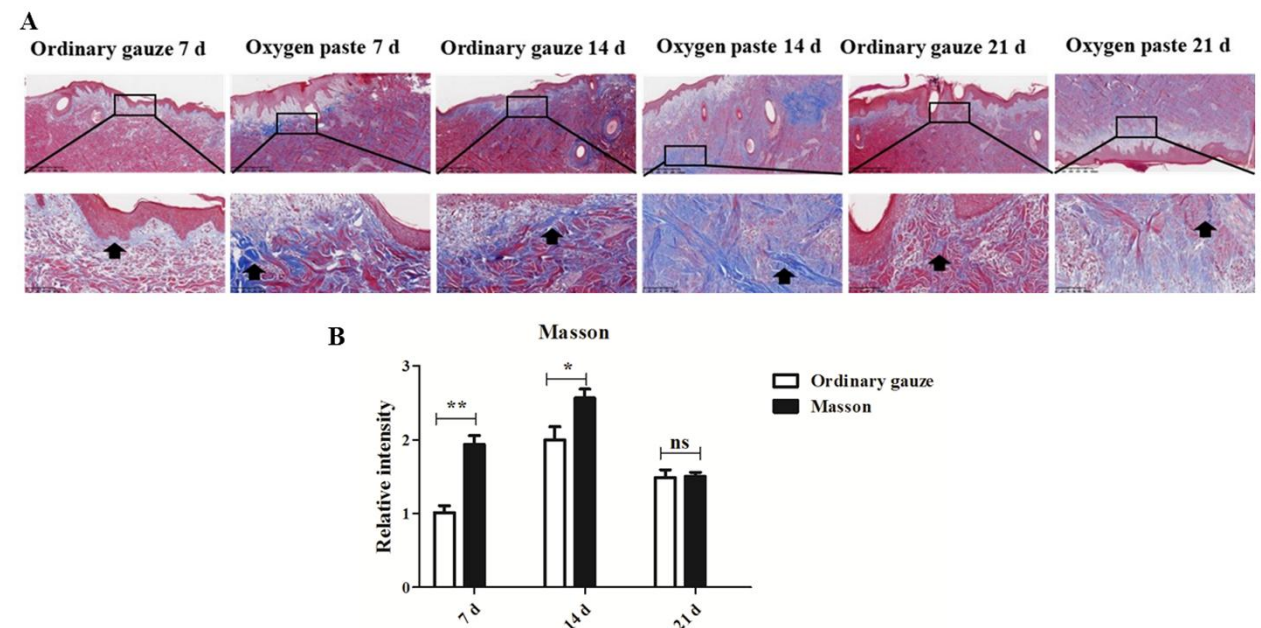
Neovascularization facilitates the uptake and absorption of substances (e.g., oxygen and nutrition) by tissues or cells, thereby promoting tissue regeneration (Chen *et al.*, 2021; Lei *et al.*, 2021b). In

addition, collagen, as a skin component, reflects a status of tissue remodeling by their production amount in wound site (Chen *et al.*, 2018). Therefore, according to the results of CD31 and Masson, the expression intensity of CD31 in the experimental group was significantly stronger than that in the control group and the increment rate of collagen fibers in the experimental group was also significantly faster than that in the control group. At 14 days postoperatively, the collagen fibers in the wounds of the experimental group were already tightly arranged, while those in the control group had not yet begun to proliferate. At 21

days after operation, the subcutaneous fat of the wound in the experimental group had basically formed, while the collagen fibers in the control group had begun to proliferate and the angiogenesis in the experimental group was significantly faster than that in the control group. Based on the above experimental results, the experimental group with oxygen-containing excipients can significantly speed up the skin wound healing of Bama miniature pigs by promoting the synthesis and regeneration of cells and collagen, the proliferation of vascular endothelial cells and collagen fibers.



**Figure 4** Oxygenated dressing promotes blood vessel formation. (A) Observation of CD31 protein expression in full-thickness skin defect wounds of miniature pigs at different time points after operation (Scale bar, 200  $\mu$ m). The red indicates the vascular endothelial cells. (B) Quantification of relative intensity in different groups. \* $P < 0.05$  and \*\* $P < 0.01$ .



**Figure 5** Oxygenated dressing promotes collagen fiber proliferation. (A) Masson staining results of full-thickness skin defect wounds in miniature pigs at different time points after operation (Scale bar, 200  $\mu$ m). The black indicates the proliferation of blue collagen fibers. (B) Quantification of relative intensity in different groups. \* $P < 0.05$  and \*\* $P < 0.01$ .



In summary, the full-thickness skin injury model of the Bama miniature pig has been constructed in this study and the method of homologous self-control was used to study the healing effect of oxygen dressings. The results showed that oxygenated dressings can provide oxygen for the wound and promote the proliferation of fibroblasts and vascular endothelial cells and keep the wound moist and accelerate wound healing.

**Availability of data and materials:** All data generated or analyzed during this study is available from the corresponding author on reasonable request.

**Competing interests:** The authors declare no conflict of interest.

### Acknowledgements

This research was supported by the science and technology innovation voucher project of Beijing Municipal Commission of Science and Technology (thlt-a-2020007).

### References

- Chen, C., Liu, Y., Wang, H., Chen, G., Wu, X., Ren, J., Zhang, H., and Zhao, Y. (2018). Multifunctional Chitosan Inverse Opal Particles for Wound Healing. *ACS Nano* 12, 10493-10500.
- Chen, C., Wang, Y., Zhang, D., Wu, X., Zhao, Y., Shang, L., Ren, J., and Zhao, Y. (2021). Natural polysaccharide based complex drug delivery system from microfluidic electrospray for wound healing. *Applied Materials Today* 23, 101000.
- Dhivya, S., Padma, V.V., and Santhini, E. (2015). Wound dressings - a review. *Biomedicine (Taipei)* 5, 22.
- Guan, G., Qizhuang, L., Liu, S., Jiang, Z., Zhou, C., and Liao, W. (2022). 3D-bioprinted peptide coupling patches for wound healing. *Materials Today Bio* 13, 100188.
- Huang, H., An, Y., Jiao, W., Wang, J., Li, S., and Teng, X. (2018). CHOP/caspase-3 signal pathway involves in mitigative effect of selenium on lead-induced apoptosis via endoplasmic reticulum pathway in chicken testes. *Environ Sci Pollut Res Int* 25, 18838-18845.
- Kamoun, E.A., Kenawy, E.S., and Chen, X. (2017). A review on polymeric hydrogel membranes for wound dressing applications: PVA-based hydrogel dressings. *J Adv Res* 8, 217-233.
- Lei, L., Lv, Q., Jin, Y., An, H., Shi, Z., Hu, G., Yang, Y., Wang, X., and Yang, L. (2021a). Angiogenic Microspheres for the Treatment of a Thin Endometrium. *ACS Biomater Sci Eng* 7, 4914-4920.
- Lei, L., Wang, X., Zhu, Y., Su, W., Lv, Q., and Li, D. (2022). Antimicrobial hydrogel microspheres for protein capture and wound healing. *Materials & Design* 215, 110478.
- Lei, L., Zhu, Y., Qin, X., Chai, S., Liu, G., Su, W., Lv, Q., and Li, D. (2021b). Magnetic biohybrid microspheres for protein purification and chronic wound healing in diabetic mice. *Chemical Engineering Journal* 425, 130671.
- Liu, Y., Zhao, X., Zhao, C., Zhang, H., and Zhao, Y. (2019). Responsive Porous Microcarriers With Controllable Oxygen Delivery for Wound Healing. *Small* 15, e1901254.
- Martin, C., Low, W.L., Amin, M.C., Radecka, I., Raj, P., and Kenward, K. (2013). Current trends in the development of wound dressings, biomaterials and devices. *Pharm Pat Anal* 2, 341-359.
- Qu, J., Zhao, X., Liang, Y., Zhang, T., Ma, P.X., and Guo, B. (2018). Antibacterial adhesive injectable hydrogels with rapid self-healing, extensibility and compressibility as wound dressing for joints skin wound healing. *Biomaterials* 183, 185-199.
- Sarheed, O., Ahmed, A., Shouqair, D., and Boateng, J. (2016). Antimicrobial Dressings for Improving Wound Healing. *InTech*.
- Sun, B.K., Siprashvili, Z., and Khavari, P.A. (2014). Advances in skin grafting and treatment of cutaneous wounds. *Science* 346, 941-945.
- Vowden, K., and Vowden, P. (2014). Wound dressings: principles and practice. *Surgery (Oxford)* 32, 462-467.
- Wang, X., Wu, D., Li, W., and Yang, L. (2021). Emerging biomaterials for reproductive medicine. *Engineered Regeneration* 2, 230-245.
- Yang, L., Liu, Y., Sun, L., Zhao, C., Chen, G., and Zhao, Y. (2021a). Biomass Microcapsules with Stem Cell Encapsulation for Bone Repair. *Nanomicro Lett* 14, 4.
- Yang, L., Sun, L., Zhang, H., Bian, F., and Zhao, Y. (2021b). Ice-Inspired Lubricated Drug Delivery Particles from Microfluidic Electrospray for Osteoarthritis Treatment. *ACS Nano* 15, 20600-20606.
- Zhang, X., Chen, G., Liu, Y., Sun, L., Sun, L., and Zhao, Y. (2020). Black Phosphorus-Loaded Separable Microneedles as Responsive Oxygen Delivery Carriers for Wound Healing. *ACS Nano* 14, 5901-5908.