

9-1-1996

Familial juvenile nephronophthisis with the immune complexdiffuse proliferative glomerulonephritis. A case report

laakchai lungthirapanich

Dhevy Watana

Laddawan Vajragupta

Saowanee Yenrudi

Follow this and additional works at: <https://digital.car.chula.ac.th/clmjournal>



Part of the [Medicine and Health Sciences Commons](#)

Recommended Citation

lungthirapanich, laakchai; Watana, Dhevy; Vajragupta, Laddawan; and Yenrudi, Saowanee (1996) "Familial juvenile nephronophthisis with the immune complexdiffuse proliferative glomerulonephritis. A case report," *Chulalongkorn Medical Journal*: Vol. 40: Iss. 9, Article 7.

DOI: 10.58837/CHULA.CMJ.40.9.6

Available at: <https://digital.car.chula.ac.th/clmjournal/vol40/iss9/7>

This Case Report is brought to you for free and open access by the Chulalongkorn Journal Online (CUJO) at Chula Digital Collections. It has been accepted for inclusion in Chulalongkorn Medical Journal by an authorized editor of Chula Digital Collections. For more information, please contact ChulaDC@car.chula.ac.th.

Familial juvenile nephronophthisis with the immune complex diffuse proliferative glomerulonephritis. A case report.

Jaakchai Jungthirapanich* Dhevy Watana**

Laddawan Vajragupta*** Saowanee Yenrudi****

Jungthirapanich J, Watana D, Vajragupta L, Yenrudi S. Familial juvenile nephronophthisis with the immune complex diffuse proliferative glomerulonephritis. A case report. Chula Med J 1996 Sep;40(9): 737-44

A 4-year-old girl was found to have familial juvenile nephronophthisis. The diagnosis was established by a family history of renal disease, polydipsia, polyuria, growth failure, anemia, a defect in urine concentrating ability, a secretory defect form of distal renal tubular acidosis, the onset of renal failure in childhood, the typical sonographic appearance and the presence of medullary cysts. The unusual findings in this patient were the immune complex diffuse proliferative glomerulonephritis and the progression of renal insufficiency in early childhood.

Key words : *Familial juvenile nephronophthisis, Immune complex diffuse proliferative glomerulonephritis.*

Reprint request: Jungthirapanich J, Department of Pediatrics, Faculty of Medicine, Thammasat University, Pathumthani 12120, Thailand.

Received for publication. August 1, 1996.

* Department of Pediatrics, Faculty of Medicine, Thammasat University.

** Department of Pediatrics, Faculty of Medicine, Chulalongkorn University.

*** Department of Radiology, Faculty of Medicine, Chulalongkorn University.

**** Department of Pathology, Faculty of Medicine, Chulalongkorn University.

จักรชัย จิ๊งิรพานิช, เทวี วัฒนา, ลัดดาวัลย์ วัชรคุปต์, เสาวณีย์ เย็นฤดี. รายงานผู้ป่วย familial juvenile nephronophthisis ร่วมกับไตอักเสบชนิดเพิ่มเซลล์ของ glomerulus จาก immune complex. จุฬาลงกรณ์เวชสาร 2539 ก.ย.; 40(9): 737-44

ผู้ป่วยเด็กหญิงไทยอายุ 4 ปี ได้รับการวินิจฉัยเป็น familial juvenile nephronophthisis โดยมีประวัติโรคไตในครอบครัว ต้มน้ำบ่อย ปัสสาวะมาก การเจริญเติบโตช้า โลหิตจาง ความบกพร่องของการทำให้ปัสสาวะเข้มข้น ความผิดปกติในการขับกรดของไต มีภาวะไตวายในวัยเด็ก การตรวจไตโดยคลื่นเสียงความถี่สูงพบลักษณะเฉพาะของโรค ตรวจชิ้นเนื้อไตพบซิสต์ใน medulla สิ่งผิดปกติในผู้ป่วยรายนี้คือมีภาวะไตวายในอายุน้อย และตรวจพบไตอักเสบชนิดเพิ่มเซลล์ของ glomerulus จาก immune complex.

Familial juvenile nephronophthisis (FJN) is a chronic disease characterised clinically by polyuria, growth failure, and invariable progression to renal failure, leading to death in most cases in childhood or adolescence.⁽¹⁾ The condition is inherited as an autosomal recessive and there may be a family history of consanguinity.^(2,3) The disease is not uncommon. It has been suggested that FJN may account for as much as 10 to 20 percent of renal failure in children.^(4,5) The pathogenesis of FJN is obscure. A defect in production of the tubular basement membrane has been proposed.⁽⁶⁾ The onset of the disease is insidious. The earliest and most consistent findings are polyuria and polydipsia. Afflicted individuals seldom seek medical attention until atrophy of renal tissue is so advanced that intractable uremia has occurred. Thus most patients are not diagnosed until after the onset of renal failure.^(7,8) In the early stages of the disease, there may be little or no morphological abnormality of the kidneys, but later, medullary cysts may form, and biopsy shows noticeable tubular atrophy, severe tubulointerstitial damage and secondary glomerular absolution.^(1-3,9) The cysts are not always localized in the medulla, the most common site being the corticomedullary junction. It has been suggested that the diffuseness of the interstitial fibrosis, lack of glomerular hypercellularity and the tubular dilation were characteristic findings in FJN.⁽¹⁰⁾ The diagnosis is generally based on genetic, clinical and pathological features. However, only a few patients show all three features simultaneously.⁽⁸⁾ The age at the first clinical evaluation for the manifestations of FJN is appro-

ximately 10 years, varying from 3 to 17 years, and the patients develop end stage renal failure within 1-10 years after the first presentation.⁽¹⁻³⁾ Associated abnormalities affecting other systems had been found with FJN. These have included skeletal abnormalities, hepatic fibrosis, tapetoretinal degeneration, cerebellar ataxia, mental retardation,⁽⁸⁾ Jeunes's syndrome⁽¹¹⁾ and nephrogenic diabetes insipidus.⁽¹²⁾

We present the case of a 4-year-old girl who developed the symptoms of FJN and renal failure at early childhood together with the immune complex diffuse proliferative glomerulonephritis and the secretory defect form of distal renal tubular acidosis.

Case report

A 4-year-old girl was referred to Chulalongkorn Hospital for medical assessment because her older sister had died two weeks earlier from chronic renal failure of undetermined cause. The patient had been well but her mother had noticed that her growth was stunted and she displayed excessive thirst. She was the third child of non-consanguineous parents. Her's had been a full-term, normal delivery and she developed mostly well with normal appearances.

On admission, her body weight was 10 kg. (<5th percentile), height 86 cm. (<5th percentile), and head circumference 47 cm. (<5th percentile). Her blood pressure was 140/70 mmHg (severe hypertension). A full ophthalmological review was normal. The patient had neither ascites nor pitting edema of extremities.

Investigation

The hemoglobin concentration was 8.1 g/dl and hematocrit of 24%. Dipstick urinalysis showed 2+ of protein. The urine specific gravity was 1.002, pH 5.5, and no RBC and WBC were detected on microscopic examination. Blood urea nitrogen was 64 mg/dl, serum creatinine 1.3 mg/dl, Na 138 mEq/L, K 3.3 mEq/L, Cl 112 mEq/L, CO_2 16 mEq/L, Ca 9.3 mg/dl, and PO_4 6.2 mg/dl. Total serum protein was 5.2 g/dl and albumin 3.4 g/dl. Serum cholesterol was 242 mg/dl and triglycerides 428 mg/dl. CH_{50} was 16 units/ml (19-40) and β_1 C 90 mg/dl (101-186). Blood gas analysis showed pH 7.328, pO_2 75.1 mmHg, pCO_2 30.4 mmHg, HCO_3^- 15.4 mEq/L and BE -8.8 mEq/L. The 24-hour urine volume was 1800 ml (7.5 ml/kg/hr.), urinary protein 3.18 g/day (282 mg/m²/hr.), and creatinine clearance 38.3 ml/min/1.73m². FE Na 3.2% (<1%), FE uric acid 31.2% (<10%), FE Ca 0.6% (<0.5%), FE PO_4 45.7% (<10%), and FE Mg 21.8% (<2%). Urine

electrolytes revealed Na 21 mEq/L, K 17 mEq/L and Cl 30 mEq/L. Tests of urinary acidification were performed by determining the urine anion gap,⁽¹³⁾ defined as (Na+K)-Cl, which revealed a positive anion gap (21+17)-30. The fractional bicarbonate excretion⁽¹⁴⁾ was 7%. The urine to blood pCO_2 gradient in alkaline urine⁽¹⁵⁾ was 13.1 mmHg. The furosemide test⁽¹⁶⁾ revealed the secretory defect form of distal renal tubular acidosis. Rheumatoid factor test, anti DNA, anti-nuclear antibodies, LE cell, Coomb's test, VDRL, HBsAg and AntiHBs all had negative results.

An ultrasound examination of the urinary tract (Fig. 1) showed normal size and contour of both kidneys. The right and left kidneys were measured as about 6.9 x 2.8 cm. and 7.2 x 3.2 cm. respectively. There was a poorly defined corticomedullary junction, increased echogenicity within the renal parenchyma and small cysts at corticomedullary junction. Mild hepatomegaly but no hepatic fibrosis was seen.

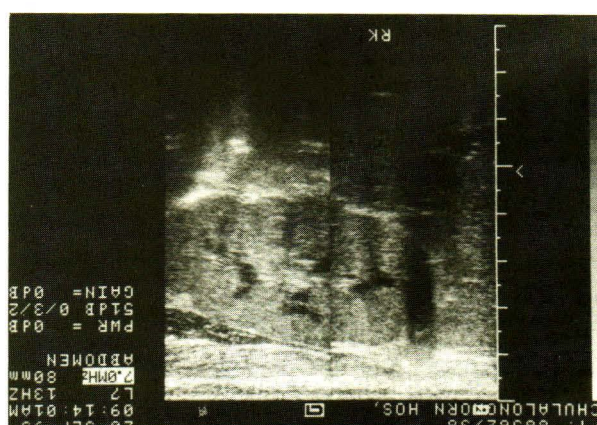
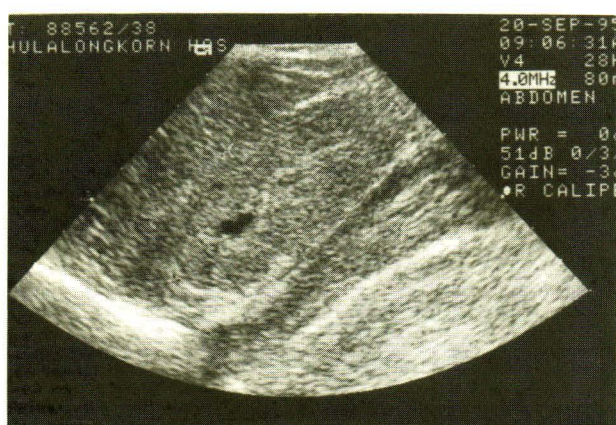

Figure 1. Longitudinal (A) and Transverse (B) supine scans of the right kidney. There was a poorly defined corticomedullary junction, increased echogenicity of renal parenchyma, small cysts located at the corticomedullary junction.

An intravenous urogram showed prompt nephrograms and excretion but faint visualization

of both kidneys. In this test, the size of right and left kidneys were 8x4 cm. and 7.5 x 4 cm.

respectively.

Computerized tomography of the abdomen revealed a normal size liver without space occupying lesions. The intrahepatic bile-ducts, common bile duct, gall bladder, spleen and pancreas were normal. Both kidneys were normal sized with a mild lobulated outline. No cystic lesions were detected in either kidney.

Renal Histology

Light microscopy was conducted on kidney cortical tissue. Few out of 25 glomeruli were undergoing global sclerosis. The remaining glomeruli posed mild to moderate mesangial hypercellularity and thick capillary walls. Multiple foci of hypertrophic tubules were noted mingled with frequent tubulointerstitial changes. Fibrosis around some glomeruli was visible. Cysts of variable sizes were noted occasionally. Few epithelial cells had features similar to proximal tubular epithelium (Fig. 2).

Intimal thickening of intralobular arteries and myointimal proliferation of the arterioles were observed (Fig 3A). A fluorescent antibody study

showed granular deposits of IgG (2+), IgA (2+), IgM (1+), C₃(1+) and C1q (1+) along capillary walls. (Fig 3B, 3C).

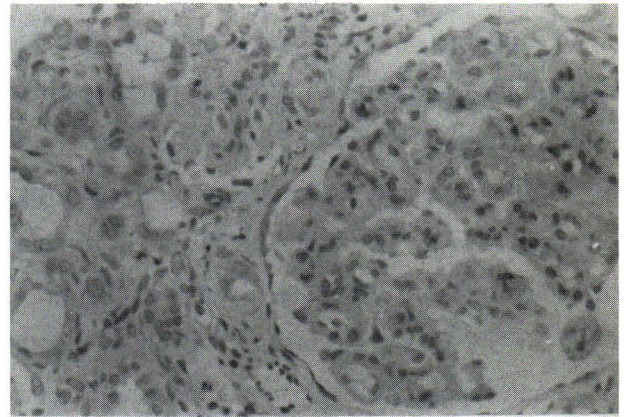


Figure 3A. A glomerulus showing thick capillary wall and mesangial proliferation. (H & E x 200)

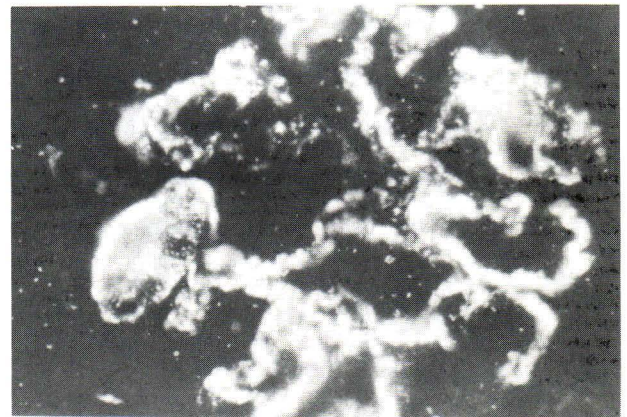


Figure 3B. Granular fluorescent deposits along capillary wall. Antihuman IgG. (x 400)

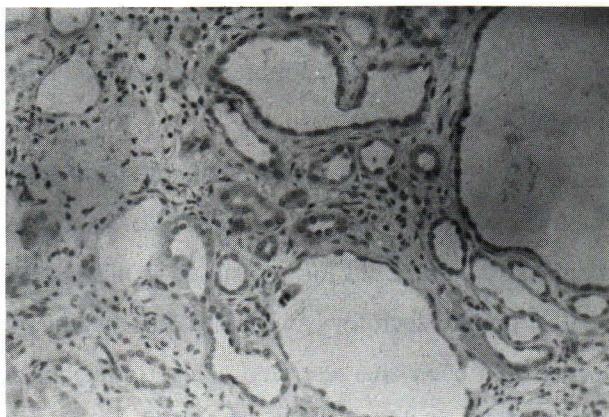


Figure 2. Picture showing few cysts, dilated tubules and diffuse chronic tubulointerstitial change. (H & E x 200)

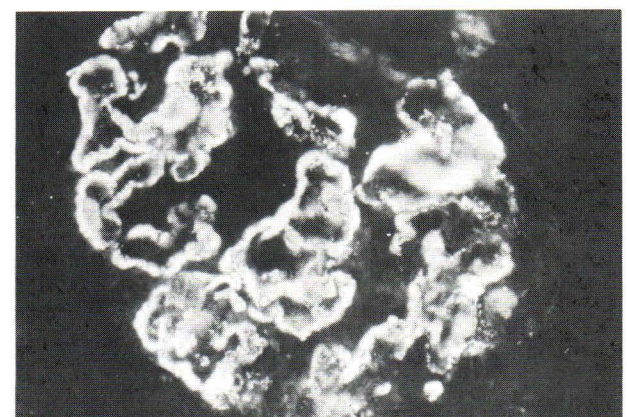


Figure 3C. Granular fluorescent deposits along capillary wall. Antihuman C3 (x 400)

The patient was diagnosed as FJN with immune complex diffuse proliferative glomerulonephritis and the secretory defect form of distal renal tubular acidosis. The patient was discharged with supportive therapy of calcium blocker (isradipine), ACE-inhibitor (Enalapril), modified Shohl solution, calcium carbonate and 1,25-dihydroxycholecalciferol. Prednisolone (2 mg/kg/day) was given for treatment of the immune complex diffuse proliferative glomerulonephritis.

The patient was followed up for 10 months after admission. At the last examination, her body weight was 12 kg. (< 5th percentile), and blood pressure was 115/70 mmHg (95 percentile). The urinalysis revealed a specific gravity of 1.004, pH 5 and 1+ of protein. Blood urea nitrogen was 44 mg/dl, serum creatinine 1.1 mg/dl, Na 136 mEq/L, K 3.7 mEq/L, Cl 102 mEq/L and CO₂ 23 mEq/L. The prednisolone was gradually reduced and discontinued after a 10-month course of treatment.

Discussion

The findings in this case are typical of FJN. Noteworthy observations were the family history of renal disease, and the patient's polydipsia, polyuria, growth failure, anemia, defect in urine concentrating ability and distal acidification. The onset of renal failure in childhood, the typical sonographic appearance⁽¹⁷⁾ and the presence of medullary cysts are characteristic. Medullary cystic disease is a distinct clinicopathological entity that is part of a group of congenital tubulointerstitial nephropathies known as the juvenile nephronophthisis-medullary cystic disease (JN-MCD) complex. All diseases of the JN-MCD

share common morphologic and functional renal alterations, which lead to similar clinical features and clinical courses but genetically heterogeneous.^(18,19) Medullary cystic disease is an autosomal dominant inherited disease whereas juvenile nephronophthisis is an autosomal recessive transmission. From the data available in this case, a definite conclusion for the mode of transmission could not be made but it suggested an autosomal recessive inheritance. However, there were two unusual findings for the FJN in this patient. The first was the immune complex diffuse proliferative glomerulonephritis and the second was the progression of renal insufficiency in early childhood. The patient showed neither clinical nor serologic abnormalities of systemic lupus erythematosus, and the hepatitis-B profiles were negative. Because of the low socioeconomic status, the poor sanitation, and the low serum complement activity of this patient, a glomerulonephritis of chronic infection was considered.

FJN may present in early childhood, although it typically becomes manifest after 6 years of age through adolescence.^(1,8) The immune complex diffuse proliferative glomerulonephritis may be the factor which caused the early onset of symptoms and the development of chronic renal failure in this patient.

The secretory defect form of distal renal tubular acidosis denoted a defect to the distal nephron which could have resulted from damage to the proton secretory pumps in this segments, which had been characterized as cystic lesions in the medulla of this patient.

Garel LA et al⁽¹⁷⁾ had reviewed the sonograms in 15 cases of FJN and concluded that

the presence of a few small medullary or corticomedullary cysts in normal-sized or moderately small kidneys, coupled with loss of corticomedullary differentiation and increased parenchymal echogenicity, should be considered diagnosis of FJN.

McGregor AR⁽²⁰⁾ reported that computerized tomography of the kidneys in a 19 year old man with FJN revealed multiple small cysts up to 5 mm. in diameter throughout the medulla of both kidneys. Our patient had the abnormal sonogram as described by Garel LA but the computerized tomography of the kidneys could not demonstrate cystic lesions in either kidney so the ultrasonography may be more sensitive than the computerized tomography in the diagnosis of this disease. Renal biopsy may not be specific for FJN since medullary cysts are not always present or may be missed on random sampling.^(3,9) Renal medullary cysts are present in two thirds of patients with terminal uremia. They may not be present initially but may develop as the disease progress. The cysts vary from microscopic size to several centimeters in diameter. Microscopically, they are seen to be located within the distal convolutions and collecting ducts, although cortical cysts can also occasionally be found.⁽⁶⁾ Our patient showed cysts of variable sizes with tubulointerstitial changes and glomerulosclerosis which is compatible with FJN. We did not find associated abnormalities in our patient such as hepatic fibrosis, ophthalmic, skeletal and central nervous system abnormalities. The unusual finding in this patient was the immune complex diffuse proliferative glomerulonephritis which had never been mentioned in any previous reports of FJN.

References

1. Bernstein J, Gardner KD. Familial juvenile nephronophthisis: medullary cystic complex. In: Edelmann CM, ed. Pediatric kidney disease. 2nd ed. Boston: Little Brown, 1992: 1171-80
2. Van Collenburg JJM, Thompson MW, Huber J. Clinical, pathological and genetic aspects of a form of cystic disease of the renal medulla: familial juvenile nephronophthisis (FJN). *Cline Nephrol* 1978 Feb; 9(2): 55-62
3. Waldherr R, Lennert T, Weber HP, Fodisch HJ, Scharer K. The nephronophthisis complex. A clinicopathologic study in children. *Virchow Arch (Pathol Anat Histol)* 1982; 394(3): 235-54
4. Betts PR, Forrest-Hay I. Juvenile nephronophthisis. *Lancet* 1973 Sep 1; 2(827): 475-8
5. Helin J, Winberg J. Chronic renal failure in Swedish children. *Acta Paediatr Scand* 1980 Sep; 69(5): 607-11
6. Cohen AH, Hoyer JR. Nephronophthisis. A primary tubular basement membrane defect. *Lab Invest* 1986 Nov; 55(5): 564-72
7. Gibson AAM, Arneil GC. Nephronophthisis. Report of 8 cases from Britain. *Arch Dis Child* 1972 Feb; 47(251): 84-9
8. Cantani A, Bamonte G, Ceccoli D, Biribicchi G, Farinella F. Familial juvenile nephronophthisis. A review and differential diagnosis. *Clin Pediatr* 1986 Feb; 25(2): 90-5
9. Sherman FE, Studnicki FM, Fetterman GH. Renal lesions of familial juvenile nephro-

- nephthisis examined by micro-dissection. *Am J Clin Pathol* 1971 Apr; 55(4): 391-400
10. Steele BT, Lirenman DS, Beattie CW. Nephronophthisis. *Am J Med* 1980 Apr; 88(4): 531-8
11. Donaldson MDC, Warner AA, Trompeter RS, Haycock GB, Chantler C. Familial juvenile nephronophthisis, Jeune's syndrome, and associated disorders. *Arch Dis Child* 1985 May; 60(5): 426-34
12. Oner A, Demircin G. A case with nephronophthisis complex or a variant of the disease. *Nephron* 1995; 70(2): 260-1
13. Batlle DC, Hizon M, Cohen E, Gutterman C, Gupta R. The use of the urine anion gap in the diagnosis of hyperchloremic metabolic acidosis. *N Engl J Med* 1988 Mar 10; 318(10): 594-9
14. Kurtzman NA. Disorders of distal acidification. *Kidney Int* 1990 Oct; 38(4): 724-7
15. DuBose TD Jr. Hydrogen ion secretion by collecting duct as a determinant of urine to blood $p\text{CO}_2$ gradient in alkaline urine. *J Clin Invest* 1982 Jan; 69(1): 145-56
16. Rastogi SP, Crawford C, Wheeler R, Flanigan W, Arruda JAL. Effect of furosemide in urinary acidification in distal renal tubular acidosis. *J Lab Clin Med* 1984 Aug; 104(2): 271-82
17. Garel LA, Habib R, Pariente D, Broyer M, Sauvegrain J. Juvenile nephronophthisis: sonographic appearance in children with severe uremia. *Radiology* 1984 Apr; 151(1): 93-5
18. Gardner KD. Medullary and miscellaneous renal cyst disorders. In: Schrier RW, Gottschalk CW, eds. *Disease of the Kidney*. 5th ed. Boston: Little, Brown, 1993: 513-23
19. Sensirivatana R, Watana D, Vatanatumrak B, Benjavonkulchai S. Uremic infant with medullary cystic disease of kidney. *J Med Assoc Thai* 1980 Nov; 63(11): 617-20
20. McGregor AR, Bailey RR. Nephronophthisis-cystic renal medulla complex: diagnosis by computerized tomography. *Nephron* 1989; 53(1): 70-2