

12-1-2021

## Successful treatment of demodicosis due to *Demodex cati* in a cat using spot – on formulation of fluralaner

Piyarat Chansiripornchai

Niwat Chansiripornchai

Follow this and additional works at: <https://digital.car.chula.ac.th/tjvm>



Part of the [Veterinary Medicine Commons](#)

---

### Recommended Citation

Chansiripornchai, Piyarat and Chansiripornchai, Niwat (2021) "Successful treatment of demodicosis due to *Demodex cati* in a cat using spot – on formulation of fluralaner," *The Thai Journal of Veterinary Medicine*: Vol. 51: Iss. 4, Article 22.

Available at: <https://digital.car.chula.ac.th/tjvm/vol51/iss4/22>

This Report is brought to you for free and open access by the Chulalongkorn Journal Online (CUJO) at Chula Digital Collections. It has been accepted for inclusion in The Thai Journal of Veterinary Medicine by an authorized editor of Chula Digital Collections. For more information, please contact [ChulaDC@car.chula.ac.th](mailto:ChulaDC@car.chula.ac.th).

## Successful treatment of demodicosis due to *Demodex cati* in a cat using spot – on formulation of fluralaner

Piyarat Chansiripornchai<sup>1\*</sup> Niwat Chansiripornchai<sup>2</sup>

### *Abstract*

This case report describes the successful use of fluralaner in treating demodicosis caused by *Demodex cati* in a cat. A 4.2 kg 10 – year – old spayed female Siamese short – haired cat was presented with a 5 – month history of severe dermatitis. The cat had been treated at previous animal hospitals with a variety of drugs such as antimicrobials, glucocorticoids and ectoparasiticides on separate occasions but the clinical signs remained severe. Microscopic examination of skin samples revealed the presence of *D. cati*. The cat was treated with a single dose of spot – on formulation of fluralaner at the minimum dosage of 25 mg/kg. The cat’s skin lesions decreased by day 21 and the skin lesions were resolved by day 56. There were no clinical abnormalities in a cat throughout the treatment.

---

**Keywords:** cat, *Demodex cati*, demodicosis, fluralaner

<sup>1</sup>Department of Veterinary Pharmacology, Faculty of Veterinary Science, Chulalongkorn University, Bangkok 10330, Thailand

<sup>2</sup>Department of Veterinary Medicine, Faculty of Veterinary Science, Chulalongkorn University, Bangkok 10330, Thailand

\*Correspondence: Piyarat.c@chula.ac.th (P. Chansiripornchai)

Received: May 18, 2021

Accepted: July 22, 2021

<https://doi.org/10.14456/tjvm.2021.97>

## Introduction

Feline demodicosis (FD) is a parasitic disease affecting cats' skin. Although FD is rare in general practice but should not be disregarded as a possible cause of skin disease. Siamese and Burmese cats are the breed predisposition for FD. *Demodex cati*, *D. gatoi* and a third unnamed species are the cause of the disease (Ferreira *et al.*, 2015). *D. cati* is the most common demodex mites found in the cats (Matricoti and Maina, 2017). *D. cati* is a follicular mite with similar morphology to the canine follicular mite, *D. canis* (Neel *et al.*, 2007). However, *D. cati* has a greater length to width ratio than *D. canis* resulting in more slender shape with the body length is 182 µm for male and 291 µm for female (Beale, 2012). FD is thought to be triggered by drugs or diseases that alter the immune response, similar to adult - onset demodicosis in dogs. The disease can be localised or generalised with pruritus ranging from mild to very severe. Generalised form commonly is associated with an underlying diseases such as feline immunodeficiency virus (FIV) infection, feline leukemia virus (FeLV) infection, diabetes mellitus, systemic lupus erythematosus, hyperadrenocorticism, xanthoma and prior immunosuppressive therapy (Mueller *et al.*, 2020; Neel *et al.*, 2007). Clinical symptoms from *D. cati* infection are variable and include alopecia, seborrhea, scale, papules, crusts, military dermatitis, erosions and ulceration on head, neck, eyelids and periocular area (Mueller *et al.*, 2020). The diagnosis of *D. cati* infection is based on history taking, physical examination, deep skin scrapings and trichograms (Beale, 2012; Mueller *et al.*, 2020).

Proper treatment of FD are required, including the use of efficacious and safe parasiticides. Effective parasiticides, alone or in combination, have been formulated in the last decades for cats. Although, several drugs, including organophosphates, rotenone, lime sulphur, amitraz, ivermectin, selamectin, milbemycin oxime, moxidectin / imidacloprid and fluralaner have been indicated for the treatment of FD, treatment failures and central nervous system toxicity have been reported (Beale, 2012; Mueller *et al.*, 2020). Lime sulphur dips and amitraz rinses are the most frequent therapy for treating FD but both treatments are not always well tolerated by the affected cats (Mueller *et al.*, 2020). Fluralaner is a drug in the isoxazolines which is the newest class of ectoparasiticides. Isoxazolines inhibit insect and acarine chloride channels, thereby induced hyperexcitation and results in uncontrolled activity of the central nervous system and death of the parasites (Gassel *et al.*, 2014). To date, the four isoxazolines including afoxolaner, fluralaner, sarolaner and lotilaner are marketed worldwide. In Thailand, fluralaner for cats is available in a topical spot - on formulation and licensed for ectoparasite control. Recently, there was a case report on the successful treatment of FD caused by *D. cati* using oral fluralaner (Matricoti and Maina, 2017). Successful treatment of FD caused by *D. cati* can be achieved using a spot - on formulation of fluralaner as well (Beccati *et al.*, 2019). However, among the parasiticides available, spot - on formulations are very popular because of the ease of

application in feline animal patients those easily be stressed by human restraint. Spot - on parasiticides are often well tolerated by cats and hence easier for owners to administer compared to oral medication and to products that must be applied directly to an affected area such as rinses or dips (Chansiripornchai and Jantanawaranon, 2020).

This case report described the successful treatment of FD caused by *D. cati*, with a topical spot - on formulation of fluralaner. As far as we know, this is the first report on the use of this drug formulation for treating FD caused by *D. cati* in Thailand.

## Case description

A 4.2 kg 10 - year - old spayed female Siamese short - haired cat was presented at the skin clinic at Animal Hospital, Bangkok, Thailand with a 5 - month history of severe dermatitis. The cat had been treated at previous animal hospitals with a variety of drugs such as antimicrobials, glucocorticoids and ectoparasiticides on separate occasions but the clinical signs remained severe.

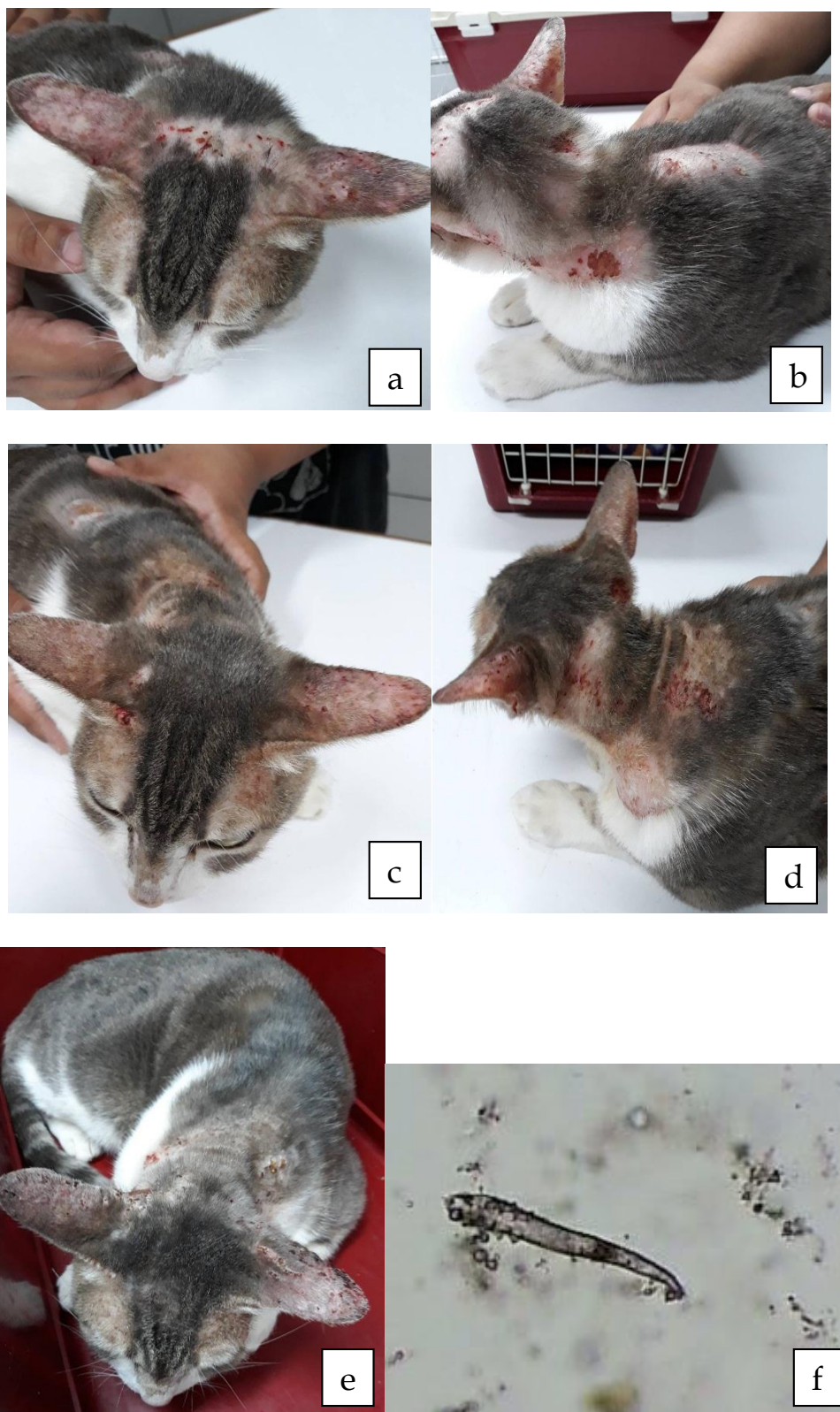
On clinical presentation, alopecia, scaling, marked erythema and deep folliculitis with hemorrhagic exudate were found on the head, neck and along the back of the cat (Fig. 1a, b).

The level of pruritus observed by the cat's owner was 8 (from level 1 to 10). For skin cytology evaluation, multiple skin scrapings from the cat were taken and examined both microscopically in paraffin oil and Gram's staining. The microscopic examination revealed the presence of a long, slender *Demodex* mite consistent with *D. cati* and a number of cocci bacteria (Fig. 1f). Moreover, hair and scale from the margins of lesions were collected for fungal culture in dermatophyte test media containing Sabouraud's dextrose agar (Megacor<sup>®</sup>, Austria) and incubated for 21 days at 25 C. From the result of fungal culture, no colony was found in dermatophyte test medium. Haematology and blood chemistry were in the normal range (Table 1). Based on the treatment histories and clinical findings, a diagnosis of FD caused by *D. cati* was made for the cat.

The cat was treated with a single dose of a spot - on formulation of fluralaner (Bravecto<sup>®</sup>, MSD, USA) at the minimum dosage of 25 mg/kg on day 0. Marbofloxacin (Marbocyl<sup>®</sup>, Vetoquinol, France) at 2 mg/kg PO q 24 h was prescribed for 14 days. Chlorpheniramine maleate (New Life Pharma Co.LTD, Thailand) at 0.5 mg/kg PO q 12 h was also prescribed for 7 days. Skin scrapings, haematology and blood chemistries of the cat were determined at interval of 1 - 3 weeks.

At the 3 - day follow - up examination of the cat, the pruritus was decreased from level 8 to level 2 and the skin erythema was also decreased. A typical treatment outcome was observed after day 21 of treatment with improved skin lesions and regrowth of hair (Fig. 1c, d, e). Microscopic examination of multiple skin scrapings from the lesions at 7 - day interval did not revealed *Demodex* mites from day 7. The skin lesions were completely resolved by day 56. There were no clinical abnormalities in the cat throughout the 6 - month follow - up period. Haematology and blood chemistry were also in the normal range (Table 1).

Although the increasing of ALP was detected on day 21 and 49, it was decreased to normal range on day 84.



**Figure 1** Macroscopic lesions on the head, neck and back in a cat. a and b, before treatment; c and d, on day 21 of treatment; e, on day 49 of treatment; f, adult *D. cati* from skin scraping (10x).

**Table 1** Haematology and blood chemistry profiles in the cat on day 0, day 21 and day 49 of treatment.

Parameters	Day 0	Day 21	Day 49	Reference*
RBC ( $\times 10^6/\mu\text{l}$ )	9.8	7.18	6.44	5.8 - 11
Hb (g/dl)	15.2	10.8	9.9	8.6 - 16
Hct (%)	42	34.6	28.4	28 - 47
MCV (fl)	43.6	48.2	46.8	37.7 - 50
Platelet ( $\times 10^3/\mu\text{l}$ )	332	168	228	160 - 660
WBC ( $\times 10^3/\mu\text{l}$ )	7.4	9.58	7.2	3.7 - 20.5
Neutrophil ( $\times 10^3/\mu\text{l}$ )	11.2	10.8	8.7	1.3 - 15.7
Eosinophil ( $\times 10^3/\mu\text{l}$ )	1	0.9	0.2	0.1 - 2
Lymphocyte ( $\times 10^3/\mu\text{l}$ )	5.03	3.8	1.04	1 - 7.9
ALT (U/L)	69	47	42	23 - 145
Creatinine (mg/dl)	1.6	1.2	0.9	0.5 - 2.5
BUN (mg/dl)	22.1	19.8	20.3	13 - 36
ALP (U/L)	42	295	232	8 - 115
Glucose (mg/dl)	99	104	76	65 - 155

\*Plumb, 2015

### Discussion

This case report represented the successful treatment of FD caused by *D. cati* using a single dose of a topical spot - on formulation of fluralaner. FD is an uncommon parasitic skin disease in cats with a possible consequence of immunosuppressive conditions such as diseases or drugs induced. In the present report, no underlying disease was found in this cat. Possibly, glucocorticoids previously administered for antipruritic purpose may have predisposed the cat to demodicosis. Until now, the drug of choice for treating FD has not resolutely been indicated. General regimens comprise of long - term treatment based on rinses, subcutaneous injections, oral drug administration or repeated spot - on formulation are recommended for treatment of FD. However, the efficacy of most of these treatments is unclearly achieved (Matricoti and Maina, 2017). Moreover, many of these medications have been associated with adverse drug reactions (ADRs) and may be difficult to administer in cats, leading to poor owner compliance and treatment failure. Despite the fact that a present standard protocol for the treatment of FD such as weekly lime sulphur dips at a concentration of 2% or amitraz baths at a concentration of 0.0125% has been recommended, both treatments are not always well tolerated by the infested cats (Mueller *et al.*, 2020). On the other hand, extralabel use of a single oral dose of fluralaner against FD caused by *D. cati* has been published (Matricoti and Maina, 2017). From the previous report, a single dose regimen is a practicable drug administration for cats, which are often suffer from long - lasting treatment with other regimens such

as rinses, injection, daily oral drug and repeat spot - on for long period (Matricoti and Maina, 2017).

In our report, FD caused by *D. cati* was diagnosed by skin scrapings which is considered to be the diagnostic method of choice for demodicosis in cats and dogs (Mueller *et al.*, 2020). A long - bodied mange morphologically consistent with *D. cati* was found in the skin lesion samples. A single dose of a spot - on formulation of fluralaner at a minimum dosage of 25 mg/kg was used as paraciticides for this cat. According to the present results, skin lesions including alopecia, scaling, erythema and deep folliculitis with hemorrhagic exudation on the head, neck and back of the cat were decreased by day 21 of the treatment. Microscopic examination of deep skin scrapings from the lesions at 7 - day interval did not revealed *D. cati* from day 7. Resolution of the condition was complete by day 56 and ADRs did not occur. This report is in agreement with the previous study that revealed the efficacy of fluralaner spot - on in seven cats infested with generalised demodicosis caused by *D. cati* (Beccati *et al.*, 2019). Moreover, successful treatment of otodemodicosis due to *D. cati* with a topical spot - on solution composed of isoxazoline was also reported (Simpson, 2021). Therefore, our report and the previous reports confirm high efficacy and easy to use of spot - on formulation of isoxazoline parasiticide against *D. cati* in cats. Spot - on formulation is one of the most popular parasiticides in veterinary practice for local treatment of skin diseases or for transdermal absorption of drugs into systemic circulation (Kathe and Kathpalia, 2017).

This reported cat also suffered from severe pruritus, eventhough antipruritic drugs including;

hydroxyzine and prednisolone had been prescribed in the previous animal hospitals. Therefore, we selected to dispense chlorpheniramine maleate (CPM) as an antipruritic drug for this cat. As a result, pruritus was decreased from level 8 to level 2 on day 3 of the treatment. This finding was consistent with previous data that CPM can be prescribed as an antipruritic drug for cats without causing the excitement that often occurs with other antihistamines (Boothe, 2012). However, the level of pruritus in the cat not only decreased by CPM alone, but also by the concurrent used of spot - on formulation of fluralaner.

In conclusion, the results of this report confirm the efficacy and safety of a single dose of a spot - on formulation of fluralaner for the treatment of FD caused by *D. cati*. This drug regimen is comfortable for the cats as well as the cats' owner.

**Authors contribution:** Piyarat Chansiripornchai contributed to the design, performed clinical study, analysed the data and prepared the manuscript. Niwat Chansiripornchai approved the data and read the final manuscript.

### Acknowledgements

The authors would like to thank Associate Professor Dr. Piyanan Taweethavonsawat and Associate Professor Dr. Sonthaya Tiawsirisup, the Department of Pathology, Faculty of Veterinary Science, Chulalongkorn University for identification of *D. cati*.

### References

- Beale K 2012. Feline demodicosis: a consideration in the itchy or overgrooming cat. *J Feline Med Surg.* 14: 209 - 213.
- Beccati MB, Pandolfi PP and DiPalma AD 2019. Efficacy of fluralaner spot - on in cats affected by generalized demodicosis: seven cases. *Vet Dermatol.* 30: 454.
- Boothe DM 2012. Dermatologic therapy. In: *Small Animal Clinical Pharmacology and Therapeutics* 2<sup>nd</sup> ed, St.Louis: Elsevier Saunders. 865 - 866.
- Chansiripornchai P and Jantanawaranon T 2020. Usability comparison study of spot - on formulations of parasiticides in cats. *Curr Tr Clin Med Sci* 2: DOI: 10.33552/CTCMS.2020.02.000528.
- Ferreira D, Sastre N, Ravera I, Altet L, Francino O, Bardag M and Ferrer L 2015. Identification of a third feline *Demodex* species through partial sequencing of the 16S rDNA and frequency of *Demodex* species in 74 cats using a PCR assay. *Vet Dermatol.* 26: 239 - e53.
- Gassel M, Wolf C, Noack S, Williams H and Ilg T 2014. The novel isoxazoline ectoparasiticide fluralaner: selective inhibition of arthropod aminobutyric acid and glutamate - gated chloride channels and insecticidal / acaricidal activity. *Insect Biochem Mol Bio.* 45: 111 - 124.
- Kathe K and Kathpalia H 2017. Film forming systems for topical and transdermal drug delivery. *Asian J Pharm Sci.* 12: 487 - 497.
- Matricoti I and Maina E 2017. The use of oral fluralaner for the treatment of feline generalised demodicosis: a case report. *J Small Anim Pract.* 58: 476 - 479.
- Mueller RS, Rosenkrantz W, Besignor E, Karas - Tecza J, Paterson T and Shipstone MA 2020. Diagnosis and treatment of demodicosis in dogs and cats: Clinical Consensus Guidelines of the World Association for Veterinary Dermatology. *Vet Dermatol.* 31: 4 - e2.
- Neel JA, Tarigo J, Tater KC and Grindem CB 2007. Deep and superficial skin scrapings from a feline immunodeficiency virus - positive cat. *Vet Clin Pathol.* 36: 101 - 104.
- Plumb DC 2015. Reference laboratory Ranges. In: *Plumb's Veterinary Drug Handbook* 8<sup>th</sup> eds, Ames, Iowa: Willey Blackwell. 1250 - 1251.
- Simpson AC 2021. Successful treatment of otodemodicosis due to *Demodex cati* with sarolaner / selamectin topical solution in a cat. *J Feline Med Surg Open Report.* 1 - 4: DOI: 10.1177/2055116920984386